Dental/Body Connection

Conflicts of Interest

Conflict of Interest

- I do not own, have stock in, or have a fiduciary agreement with any company or individual that would pose a conflict of interest with anything I teach.
- I do not get kickbacks or any other perks from any products that I may mention.

Conflict of Interest

- I live in my own body. The things I talk about appear to my eyes to work for me. I do my best to test them often and keep the things that work and discard the rest.

- However, since I can’t leave my body and see if what I do works from the outside, I can’t give you an unbiased view of what I teach. I leave that to you.

- Please keep that in mind and test these things for yourself to see if they work for you and have validity/truth in your worldview.

Just Plain Conflict

- There is/was a LOT of push back against this course. I interpret that to mean that either:
  - a) I am off my rocker and know not of what I speak.
  - b) We have discovered something that scares the opposition and they want it shut down.

Me trying to pull out the new information for this course

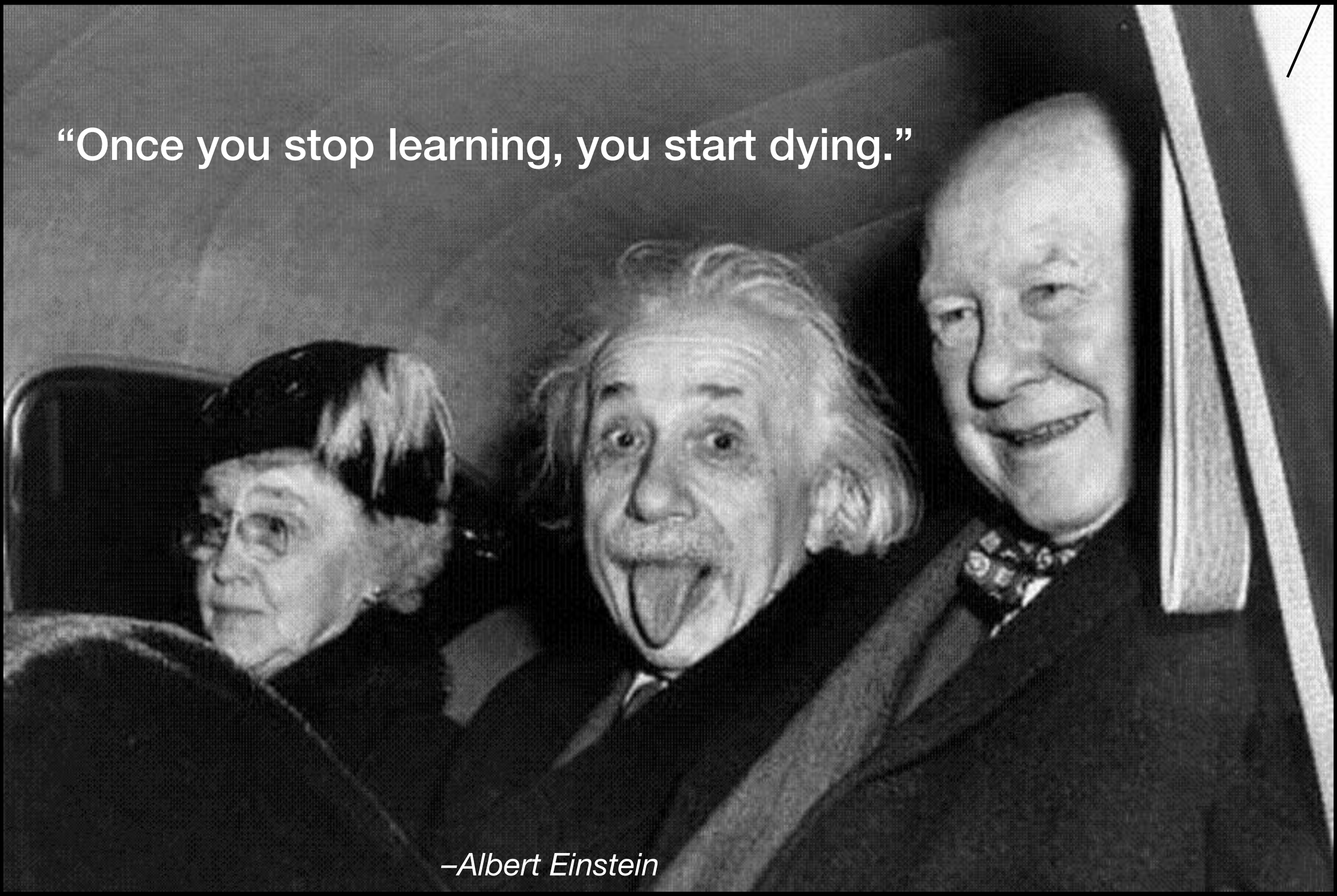
“Once you stop learning, you start dying.”
–Albert Einstein

Osteopathic Tenets

No matter what your degree, this is the way we teach students.

The body is a unit, and the person represents a combination of body, mind and spirit.

With the Dental TEAM approach,

RATIONAL TREATMENT

is the KEY!

Rational treatment is based on an understanding of these principles

"When we use the word "disease", we mean anything that makes an unnatural showing in the body."

- A.T. Still

Somatic Dysfunction

is impaired or altered function

- Somatic dysfunction may manifest as a localized area of palpatory change in the muscles and fascia adjacent to the spine.
- These changes include tissue swelling or edema, increased or decreased temperature, and stiffness or loss of tone.
- Tissue texture changes represent localized areas of inflammation that can occur in response to direct insult.
- They may also arise in response to damage or irritation to distal tissues through viscerosomatic reflexes.

Somatic Dysfunction

Comes in 4 Classical Versions

- Somato-Somato - a vertebra triggers another vertebra
- Somato-Visceral - a vertebra triggers an organ
- Viscero-Somato - an organ triggers a vertebra
- Viscero-Visceral - one organ triggers another organ

Copyright 2001 by Randy Glasbergen.
www.glasbergen.com

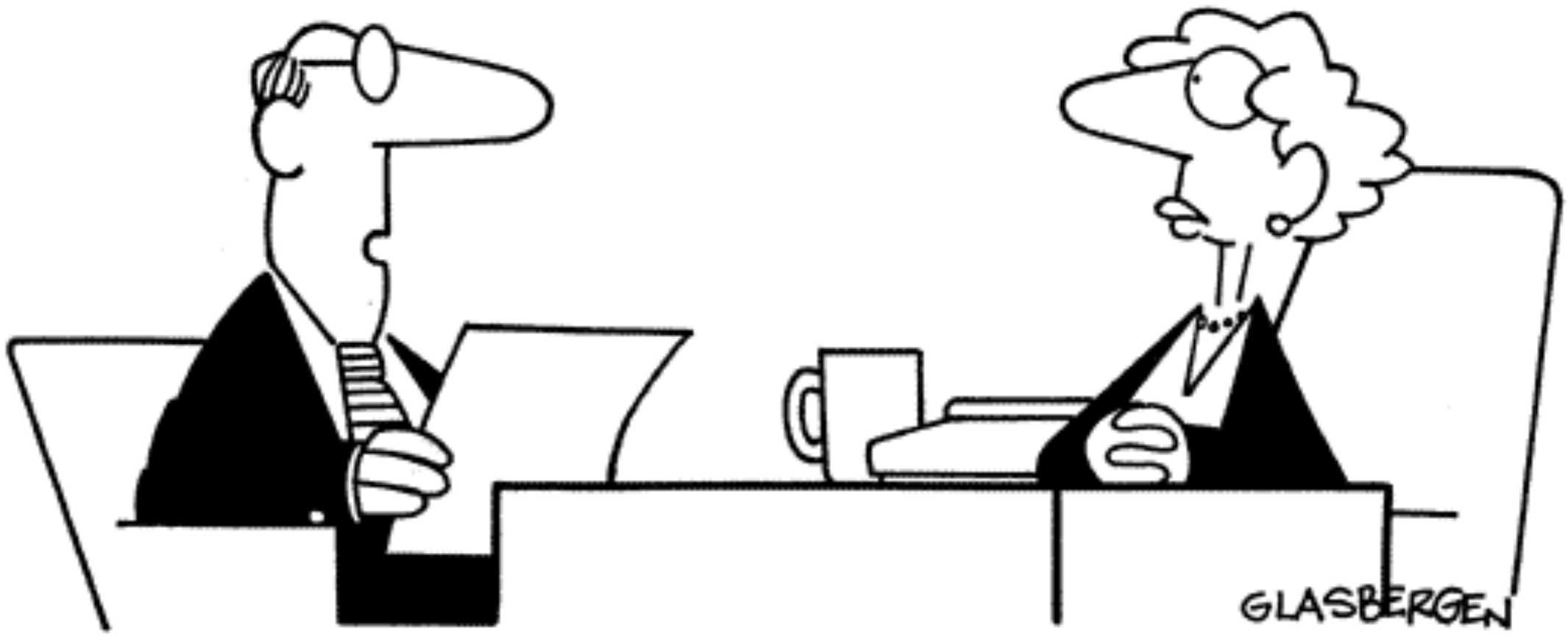

"My team is having trouble thinking outside the box. We can't agree on the size of the box, what materials the box should be constructed from, a reasonable budget for the box, or our first choice of box vendors."

These kinds of issues will tend to stop further thinking…

Somatic Dysfunction

And a Few New Variations

- Visual Somatic Strain - somatic dysfunction caused by vision - if you remove visual input (close your eyes), this strain goes away. It returns when visual input resumes.

From Paul Dart, MD, FCA

Somatic Dysfunction

And a Few New Variations

- Dental Somatic Strain - somatic dysfunction caused by the teeth/oral structures.
- This can further be divided into:
  - Dental Occlusal Somatic Strain - these strains occur when the teeth occlude. They are not present when the biting surfaces of the teeth are not together.
  - Non-Occlusal Dental Somatic Strain - these occur independent of occlusion and are dental in origin.

Biologic Tenet

ANATOMY ⟷ PHYSIOLOGY

Biologic Tenet

But which do we tr

How far/fas

Wh pping point?

t about the tongue?

How do I know I'm doing it right ?

There is a big part of us that wants answers.

How do we get them in a way that is consistent?

Biologic Tenet

FORM ⟷ **FUNCTION**

Who Wins?

ANATOMY ⟷ **PHYSIOLOGY**

SO... I'M OUTSIDE THE BOX...
...THINKING...
NOW WHAT?

"If you don't get out of the box you were raised in, you won't understand how much bigger the world is."

-Angelina Jolie

We begin this course with the idea that everything we have learned up to this point in our careers could be: incorrect, incomplete, poorly explained, misunderstood, or just plain propaganda designed to deceive.

Biologic Laws



"Whenever you find yourself on the side of the majority, it is time to pause and reflect."

–Mark Twain

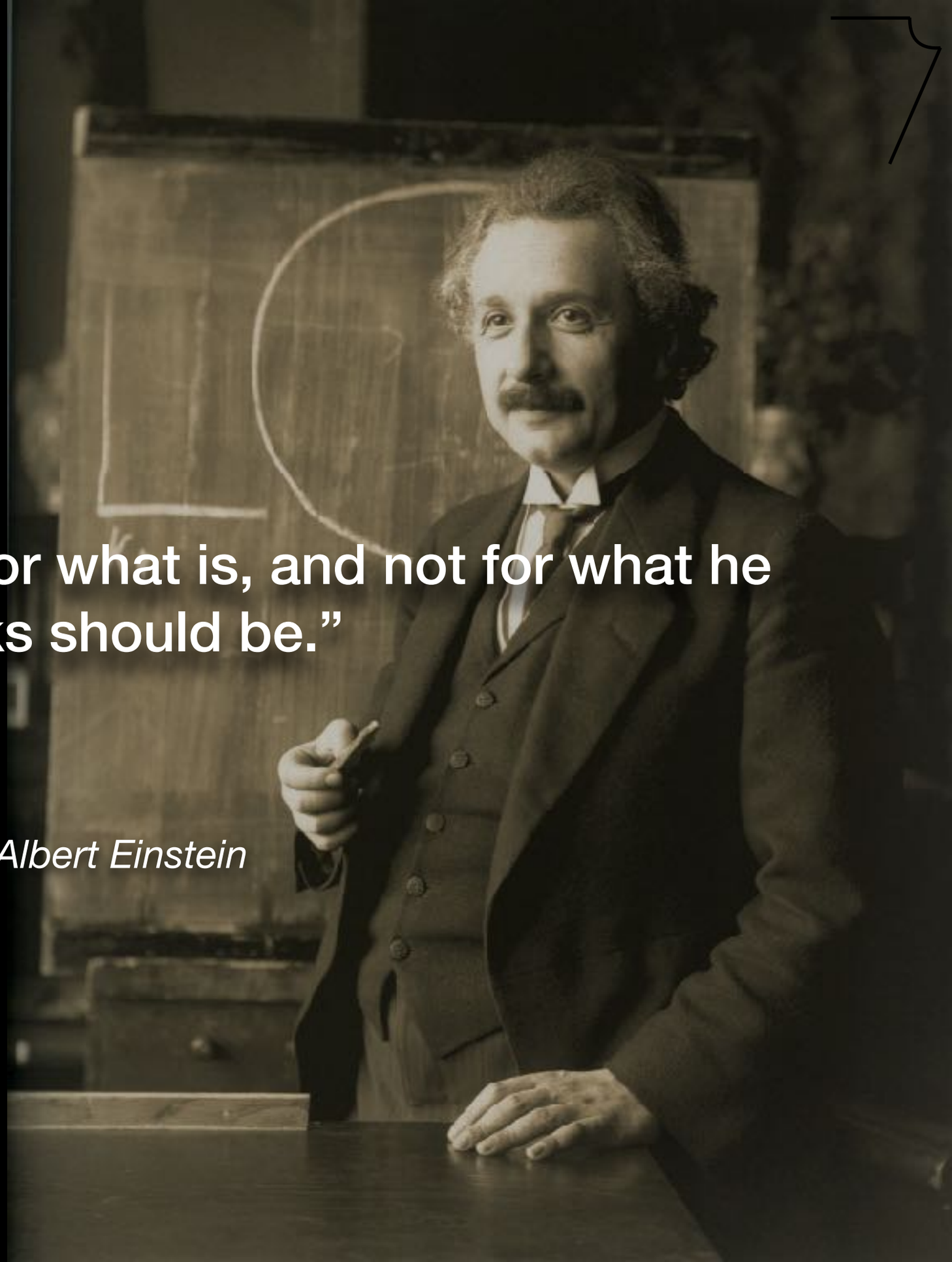

“A man should look for what is, and not for what he thinks should be.”

–Albert Einstein

"Just because something has always been done in a certain way is never a sufficient reason for continuing to do it that way."

-Clarence Birdseye
founder of the modern frozen food industry

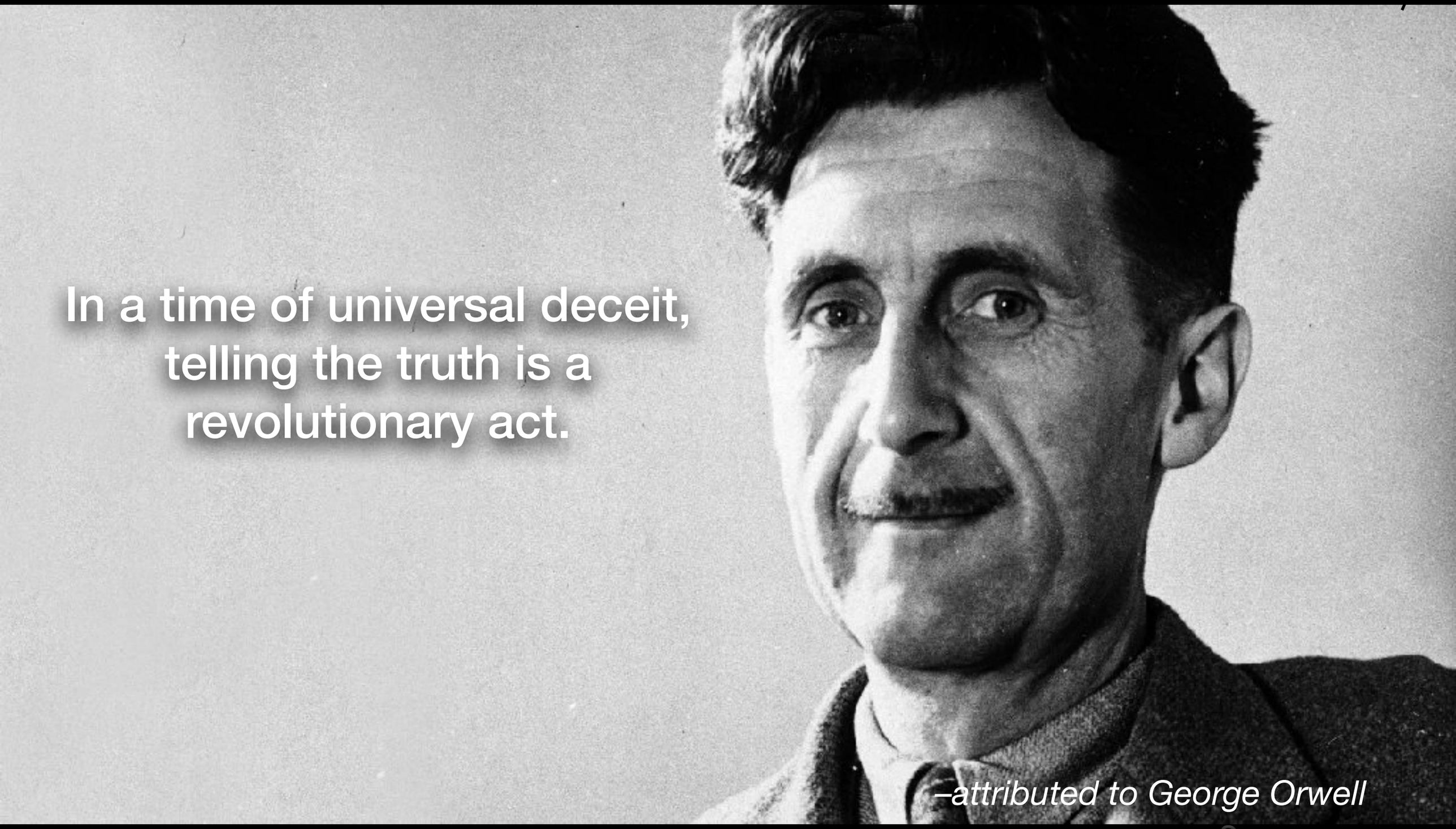
In a time of universal deceit,
telling the truth is a
revolutionary act.
–attributed to George Orwell

"An osteopath is only a human engineer, who should understand all the laws governing his engine and thereby master disease."

–A. T. Still

Definition of a Scientific Law

- A scientific law is a statement that describes an observable occurrence in nature that appears to always be true.
- In scientific jargon, law describes a true, absolute and unchanging relationship among interacting elements.
- The rules of biology and science cannot be broken.

Definition of a Scientific Law

- A scientific law, no matter how many times we test it (and no matter how many investigators), always seems to hold true.

How It All Works

- A hypothesis is a tentative explanation that can be tested by further investigation.
- A theory is a well-supported explanation of observations.
- A scientific law is a statement that summarizes the relationship between variables.
- An experiment is a controlled method of testing a hypothesis. (This is where we gather the “data” for “evidence” based medicine.)

Law of Conservation of Energy

- States that energy can neither be created nor destroyed but it can be transformed from one form to another.

The First Law of Biology

- All living organisms obey the laws of thermodynamics.

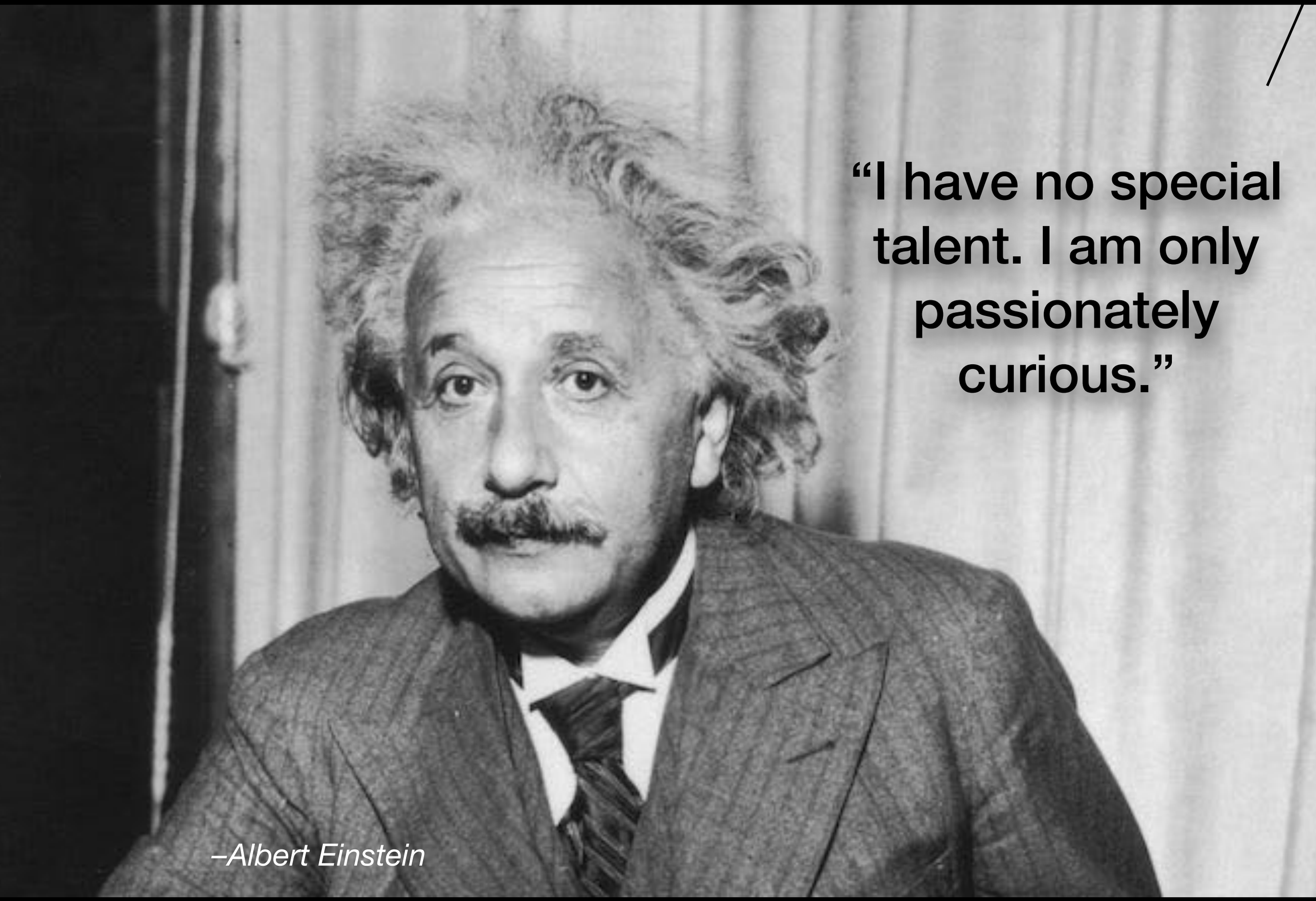
“I have no special talent. I am only passionately curious.”
–Albert Einstein

Law of Gravity

- Gravity always pulls toward the center of the earth. That almost always translates to a downward force. That means there is a difference in gravitational pull between a patient that is supine vs one that is upright.

That means that taking an impression with the patient seated vs partially or completely supine will likely give you different results because of how gravity impacts the body.

“Get your facts first, then you can distort them as you please.”

–Mark Twain



Newton’s First Law of Motion

- Every object will remain at rest or in uniform motion in a straight line unless compelled to change its state by the action of an external force.

Newton’s Second Law of Motion

Force = mass x acceleration

- For an external applied force, the change in velocity depends on the mass of the object. A force will cause a change in velocity; and likewise, a change in velocity will generate a force. The equation works both ways

Newton’s Third Law of Motion

- For every action there is an equal and opposite reaction.

The position of the teeth in the mouth is an expression of this law.

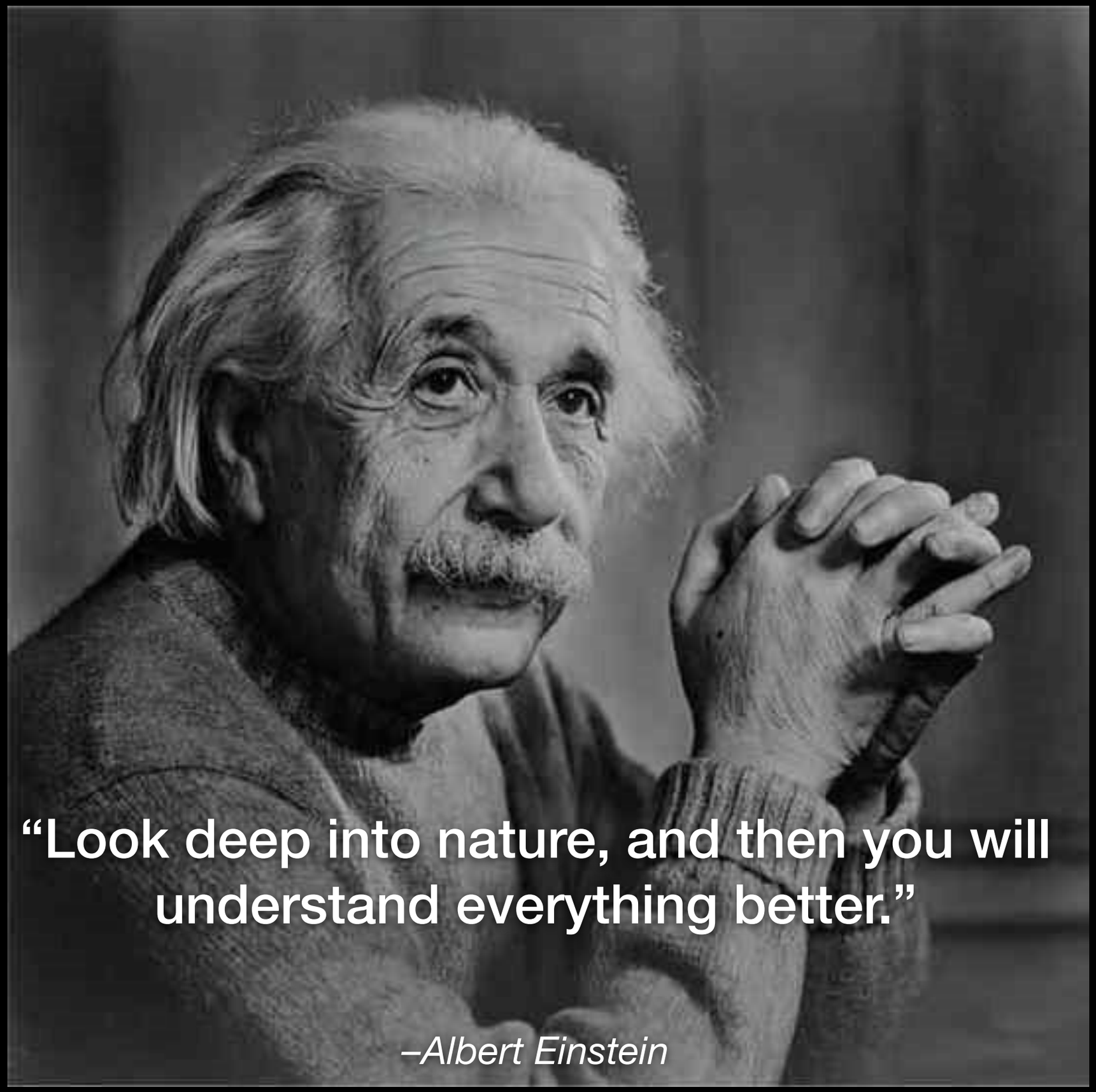
“Look deep into nature, and then you will understand everything better.”
–Albert Einstein

Heisenberg's Uncertainty Principle

- Heisenberg realized that it was impossible to simultaneously know, with a high level of precision, two properties of a particle. In other words, you can know the position of an electron with a high degree of certainty, but not its momentum and vice versa.

Hilton’s Law

- John Hilton, F.R.S., F.R.C.S. between 1860-62 proposed the following in his book *Rest and Pain*:

  ”The same trunks of nerves whose branches supply the groups of muscles moving a joint, furnish also a distribution of nerves to the skin over the insertion of the same muscles, and the interior of the joint receives its nerves from the same source.”

Hilton's Law

- Hilton goes on to say:

  "Every fascia of the body has a muscle attached to it, and that every fascia throughout the body must be considered as a muscle."

- Charles H. Murray states in his book *Osteopathic Gynecology (1915)*:
  - "…any inflammation of the viscera will be reflected in the tenderness and tension of the integument over that viscera."

Hilton’s Law

Clin Anat. 2014 May;27(4):548-55. doi: 10.1002/ca.22348. Epub 2013 Nov 22.

Hilton's law revisited.

Hébert-Blouin MN[1], Tubbs RS, Carmichael SW, Spinner RJ.

Author information

Abstract

Hilton's Law, put forth 150 years ago, is well known and frequently taught in anatomy courses. We critically analyzed the complex description of associated muscular, cutaneous, and articular innervations in order to assess the general applicability of Hilton's Law. We applied rules for interpretation of the Law extrapolated upon but based on Hilton's original writings, and excluded obscure supplementary clauses not considered as part of the Law. We found the Law, as originally written and as we interpreted with some latitude, to be reliable and applicable to all cranial and peripheral nerves. Hilton's Law is a powerful springboard to understand articular anatomy and pathophysiology.

KEYWORDS: arthrology; articular branch; bone; joint innervation; nerve

PMID: 24272922 DOI: 10.1002/ca.22348

[Indexed for MEDLINE]

Hilton’s Law

- Hilton’s Law and Murray’s observation allow us to base in science WHY Jones’ tender points (strain/counterstrain) and Chapman’s reflex points work.

- Together, they also correlate that everything along a nerve pathway is connected and that any perturbation of any part effects *everything* along that path in some way.



“Education is what remains after one has forgotten what one has learned in school.”

–Albert Einstein

Hooke’s Law

- Tissue strain (i.e. change in length) is directly proportional to applied compressive or stretching stress, so long as tissue elasticity (recoil ability) is not exceeded.

Too much, too fast is bad…

Hooke’s Law

- If we are working with the body, we need to have the end goal in sight and have a plan to reach that goal.

- In order to keep Hooke’s Law from being inadvertently exceeded, we need to TEST the patient’s body repeatedly to make sure we are not making mistakes.

If you exceed Hooke’s Law if takes effort to return to balance.

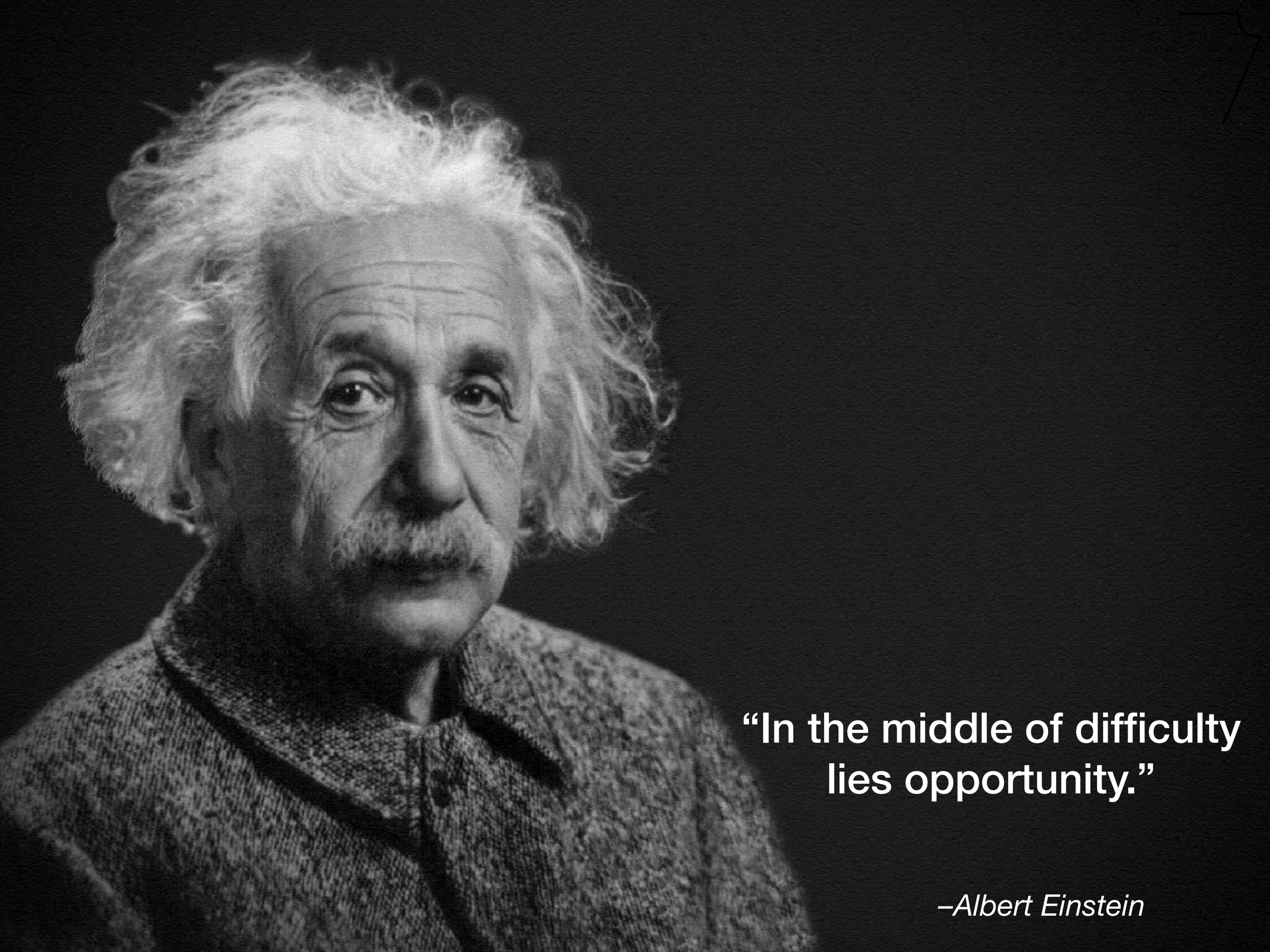
“In the middle of difficulty
lies opportunity.”
–Albert Einstein

Law of Hormesis

- Hormesis is a dose response phenomenon characterized by a low dose stimulation, high dose inhibition, resulting in either a J-shaped or an inverted U-shaped dose response

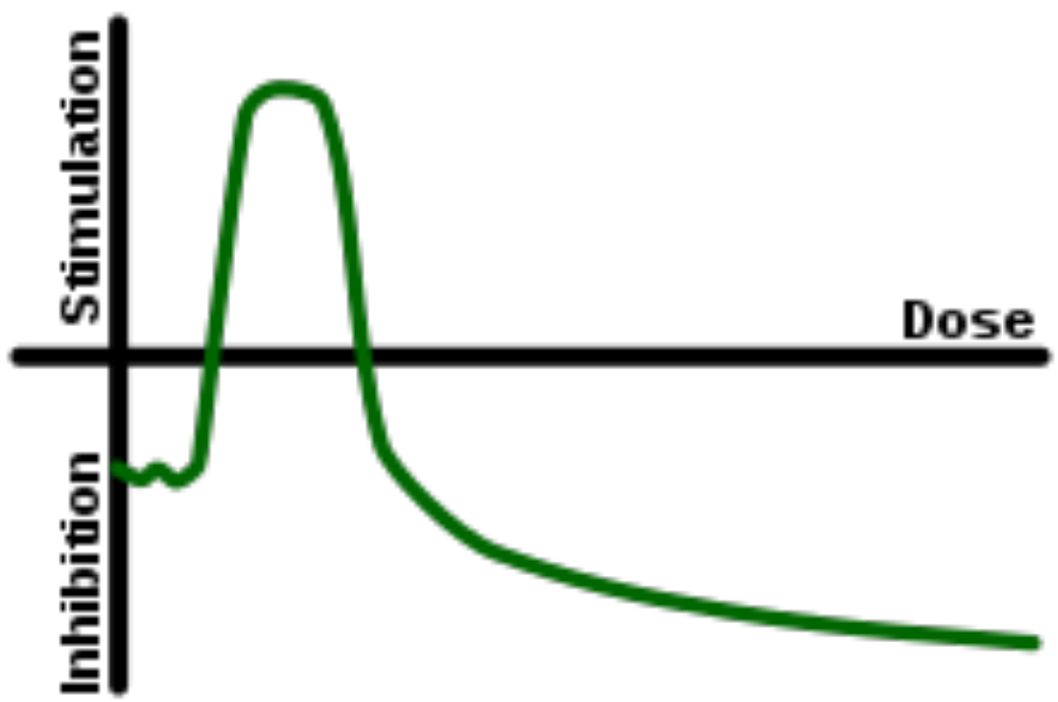

Law of Thixotropy

- Thixotropy is a time-dependent shear thinning property. Certain gels or fluids that are thick or viscous under static conditions will flow (become thinner, less viscous) over time when shaken, agitated, shear-stressed, or otherwise stressed (time dependent viscosity). They then take a fixed time to return to a more viscous state.

Von Baer's Law

- Embryos start from a common form and develop into increasingly specialized forms, so that the diversification of embryonic form mirrors the taxonomic and phylogenetic tree.

Embryo's development becomes increasingly diverse

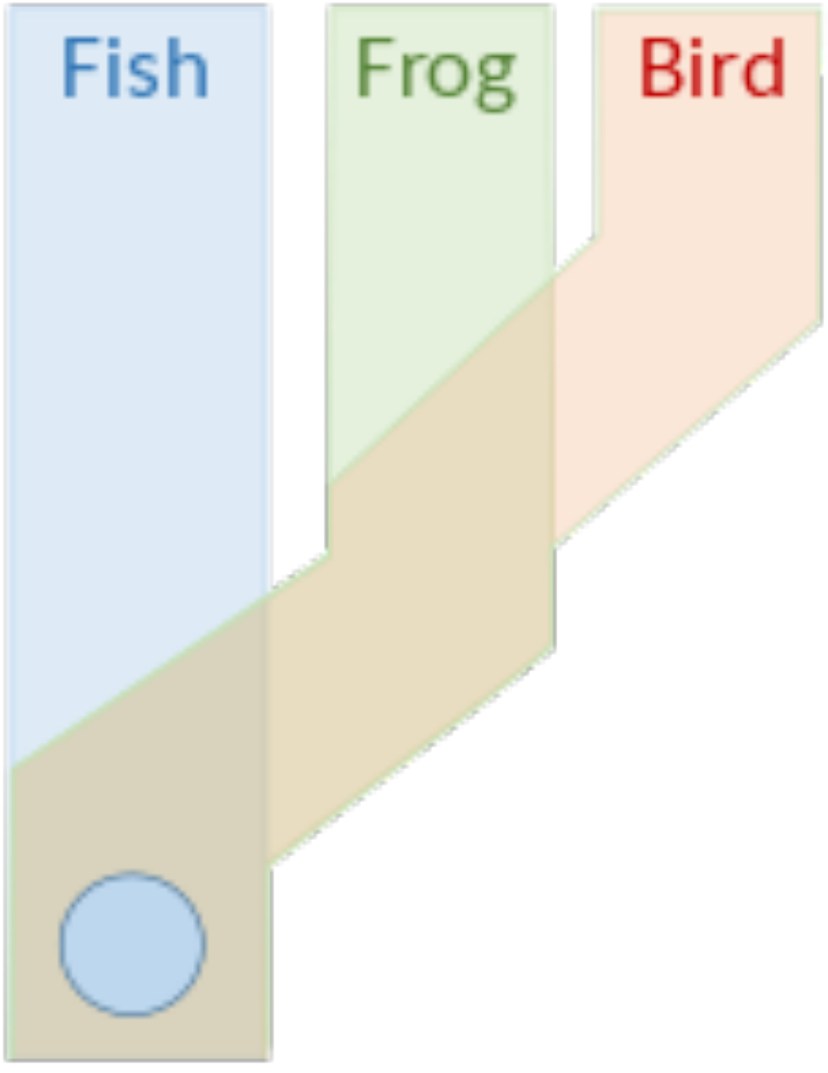

Pfluger's Laws (1)

- Law of Unilaterality - if mild irritation is applied to one or more sensory nerves, the movement will take place usually on one side only, on that side which is irritated.

Pfluger's Laws (2)

- Law of Symmetry - if the stimulation is sufficiently increased, motor reaction is manifested, not only by the irritated side, but also in similar muscles on the opposite side of the body.

Pfluger's Laws (3)

- Law of Intensity - Reflex movements are usually more intense on the side of irritation; at times the movements of the opposite side equal them in intensity, but they are usually less pronounced.

Pfluger's Laws (4)

- Law of Radiation - If the excitation continues to increase, it is propagated upward, and reactions take place through centrifugal nerves coming from the cord segments higher up.

Pfluger's Laws (5)

- Law of Generalization - When the irritation becomes very intense, it is propagated to the medulla oblongata, which becomes a focus from which stimuli radiates to all parts of the cord, causing a general contraction of all muscles of the body. The body is said to become "generalized".

Davis' Law

- Soft tissues tend to shorten and contract unless subject to frequent stretching (use it or lose it).

All Or None Law

- The weakest stimulus capable of producing a response causes skeletal muscle *fibers* to contract maximally.

Pascal’s Law

- A fluid at rest transmits pressure equally in every direction.

Head’s Law

- If painful stimulus is applied to areas of low sensibility in close central connection with areas of high sensibility, pain may be felt where sensibility is high.

Beevor’s Axiom

Axiom - a statement or proposition which is regarded as being established, accepted, or self-evidently true.

- The brain knows nothing of individual muscles, but thinks only in terms of movement.

Weigert's Law

- The loss or destruction of living tissue is apt to be followed by overproduction of such tissue during the process of wound healing.

Poiseuille's Law

- Vascular blood flow is inversely proportional to fourth power of vessel radius (i.e. the narrower the vessel, the greater the resistance to flow)

This is the basis for airway centered dentistry.

Meltzer’s Law

- Law of Contrary Innervation

- All living functions are continually controlled by two opposing forces.

Law of Facilitation

- "When an impulse has passed once through a certain set of neurons to the exclusion of others, it will tend to take the same course on future occasions, and each time it traverses this path the resistance will be smaller; the passage of these neural impulses become even easier for all succeeding impulses."

Wolff’s Law

- “Every change in the function of a bone is followed by certain definite changes in its internal architecture and its external conformation.”

Sutton’s Law

- A method of diagnostic reasoning that states one should look for diseases where they are most likely to be (such as malaria in tropical areas that harbor Anopheles mosquitoes; atherosclerosis in patients who are smokers, hypertensives, or diabetics). The law is attributed to Willie Sutton, who, when asked why he robbed banks, said, “Because that's where the money is.”



“The important thing is to not stop questioning. Curiosity has its own reason for existing.”

–Albert Einstein

Schmalhausen’s Law

- Named after Ivan Schmalhausen, states that a population at the extreme limit of its tolerance in any one aspect is more vulnerable to small differences in any other aspect. Therefore, the variance of data is not simply noise interfering with the detection of so-called "main effects", but also an indicator of stressful conditions leading to greater vulnerability.

As you continue to watch your patents come in, ask yourself if this law may be coming true.



“Any intelligent fool can make things bigger and more complex… It takes a touch of genius—and a lot of courage—to move in the opposite direction.”

–Albert Einstein

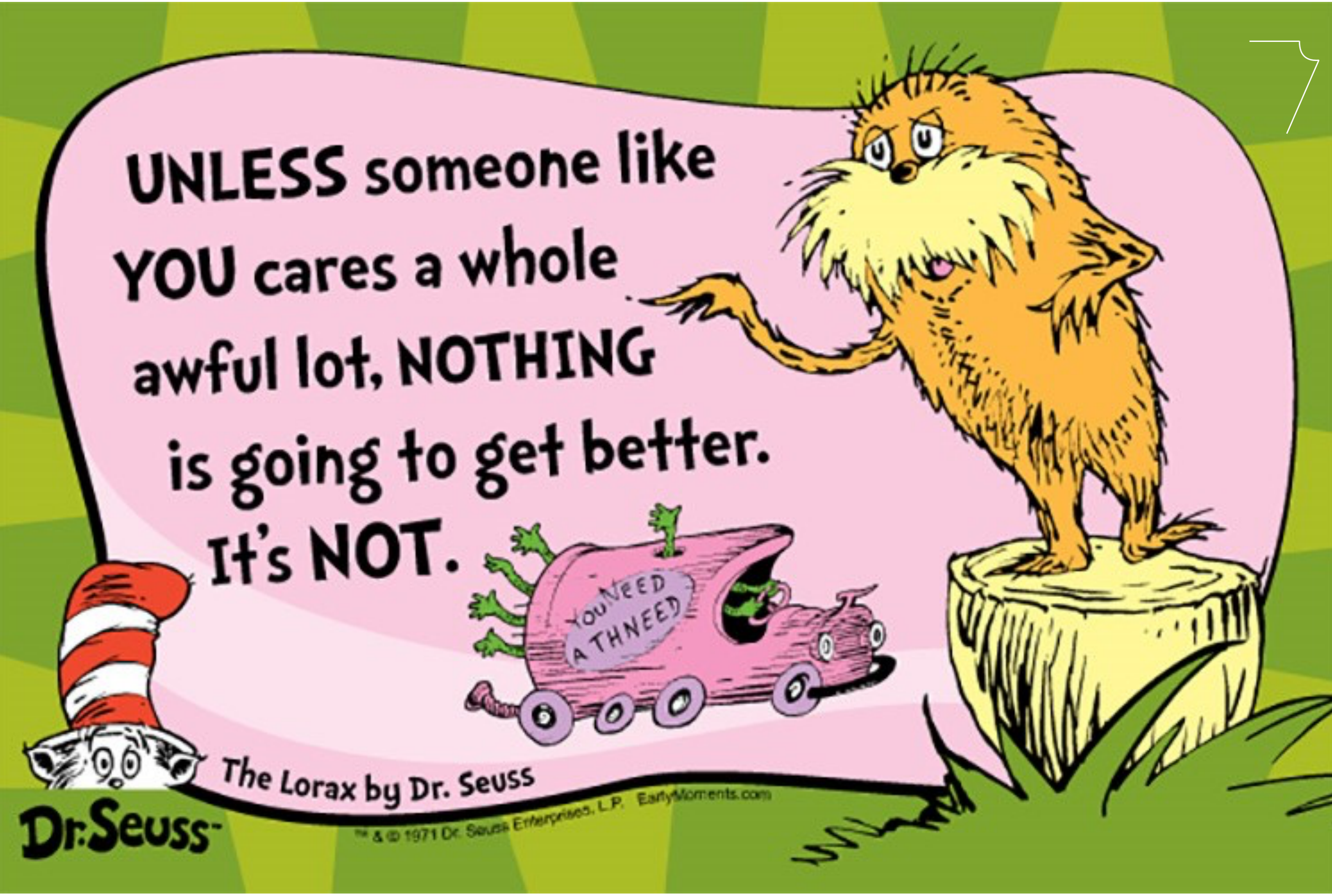
UNLESS someone like
YOU cares a whole
awful lot, NOTHING
is going to get better.
It's NOT.
YOU NEED A THNEED
The Lorax by Dr. Seuss
Dr. Seuss
™ & © 1971 Dr. Seuss Enterprises, L.P.
EarlyMoments.com



“He who can no longer pause to wonder and stand rapt in awe, is as good as dead; his eyes are closed.”

–Albert Einstein

What we are taught about the head…

Myths…

- All the bones of the head fuse at adulthood, right? (therefore, we can push and pull and drill and bang with absolutely NO repercussions…)
- At least that is what they teach in MD school and Dental school…still…

Myths…

- The idea that the bones of the head fuse was put forth by the British (anatomists), and because the Brits ruled the world, that idea was spread and accepted as true in the training of the dentists and doctors that are trained in that tradition.

- The Italians always thought that the bones rarely fuse… (because they could go in to the catacombs and see the evidence).

This is a Beauchene mounted or exploded skull. To make one, you take a skull, place beans inside the calvaria, place it under water and let the beans expand… Then you mount the bones in their 3D location with some space between them.

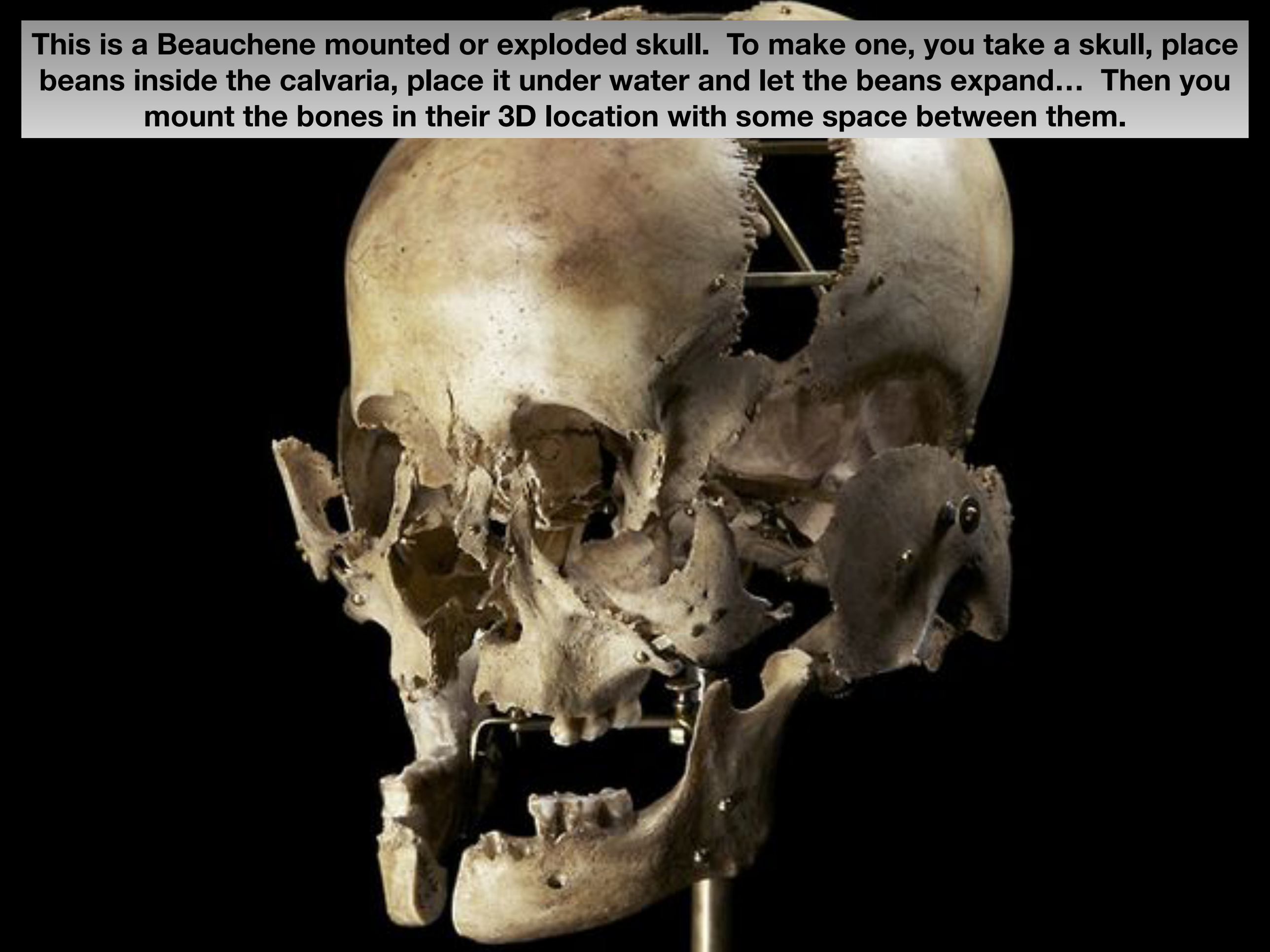

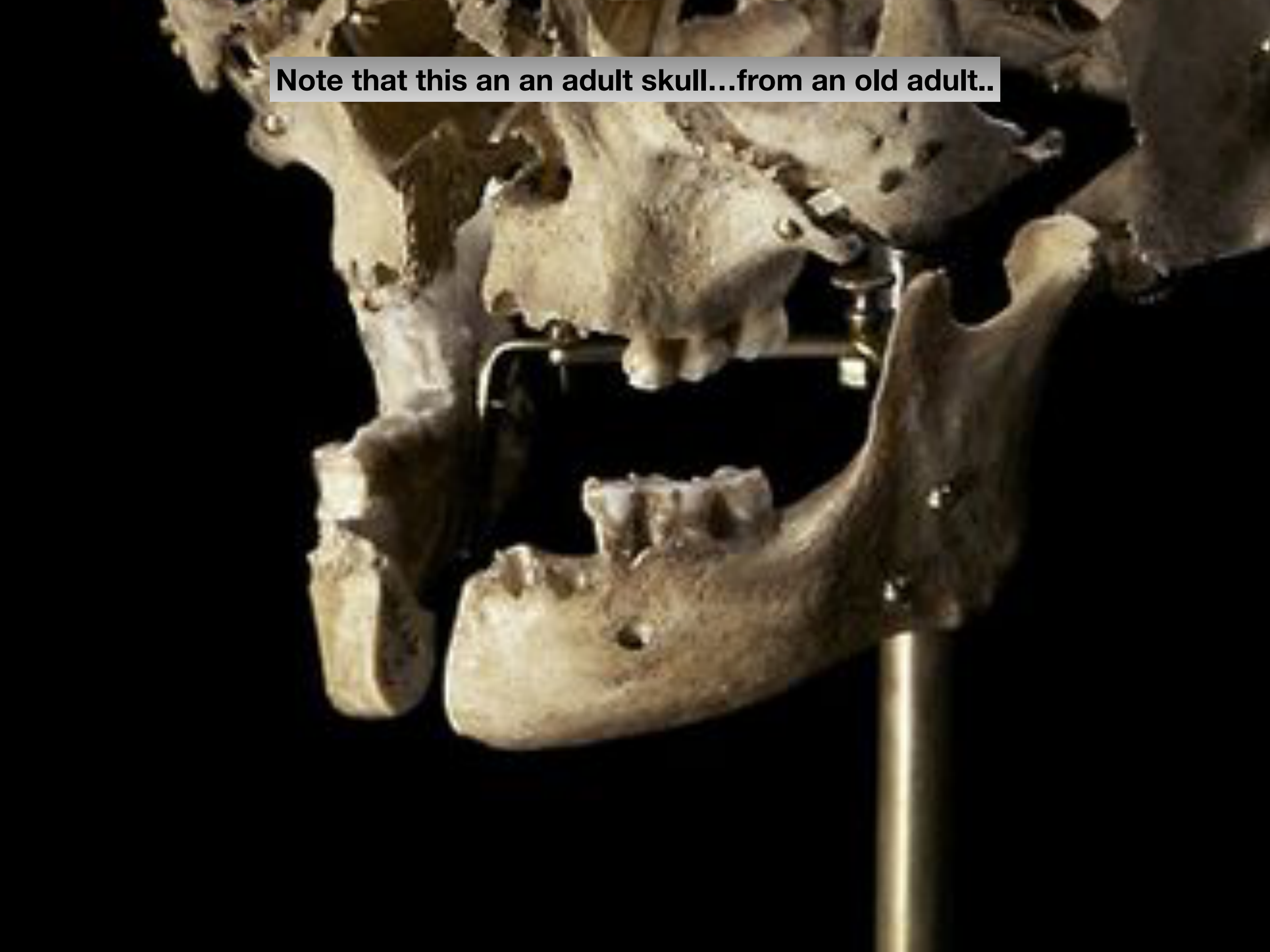
Note that this an an adult skull…from an old adult..

And yet, the sutures come apart beautifully…

Here too…

Myths…

- So, if the bones don’t fuse, and still have the capability of movement, what else might be a myth?
- And does that now mean that the things we ASSUMED we could do with no repercussions now need to be reevaluated???

Facial Growth Patterns

In 75 years, we have gone from this…

To this…





Facial Symmetry

To Be or Not to Be





Flat Ear



Not So Flat Ear

A Bit of Anatomy

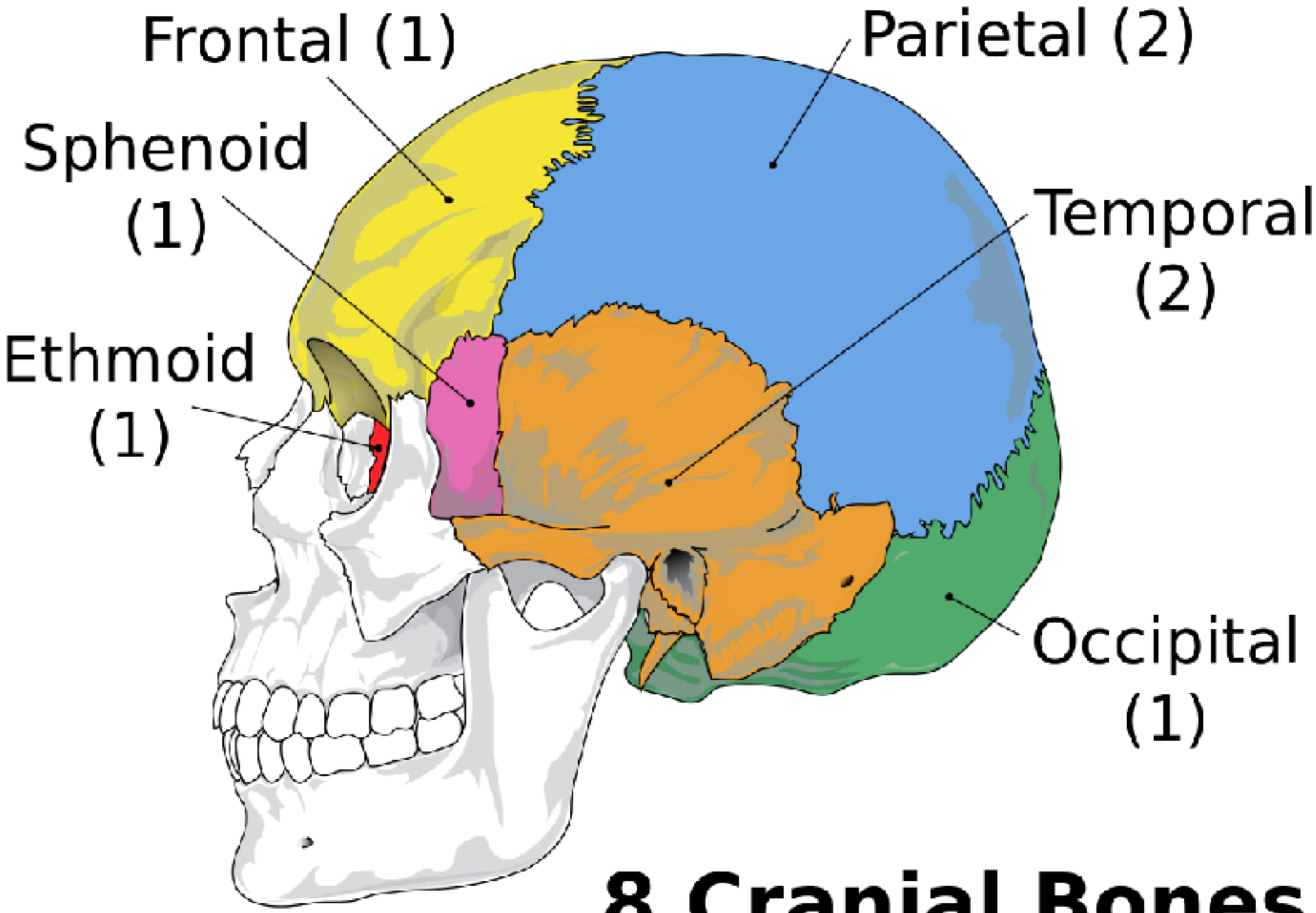

8 Cranial Bones

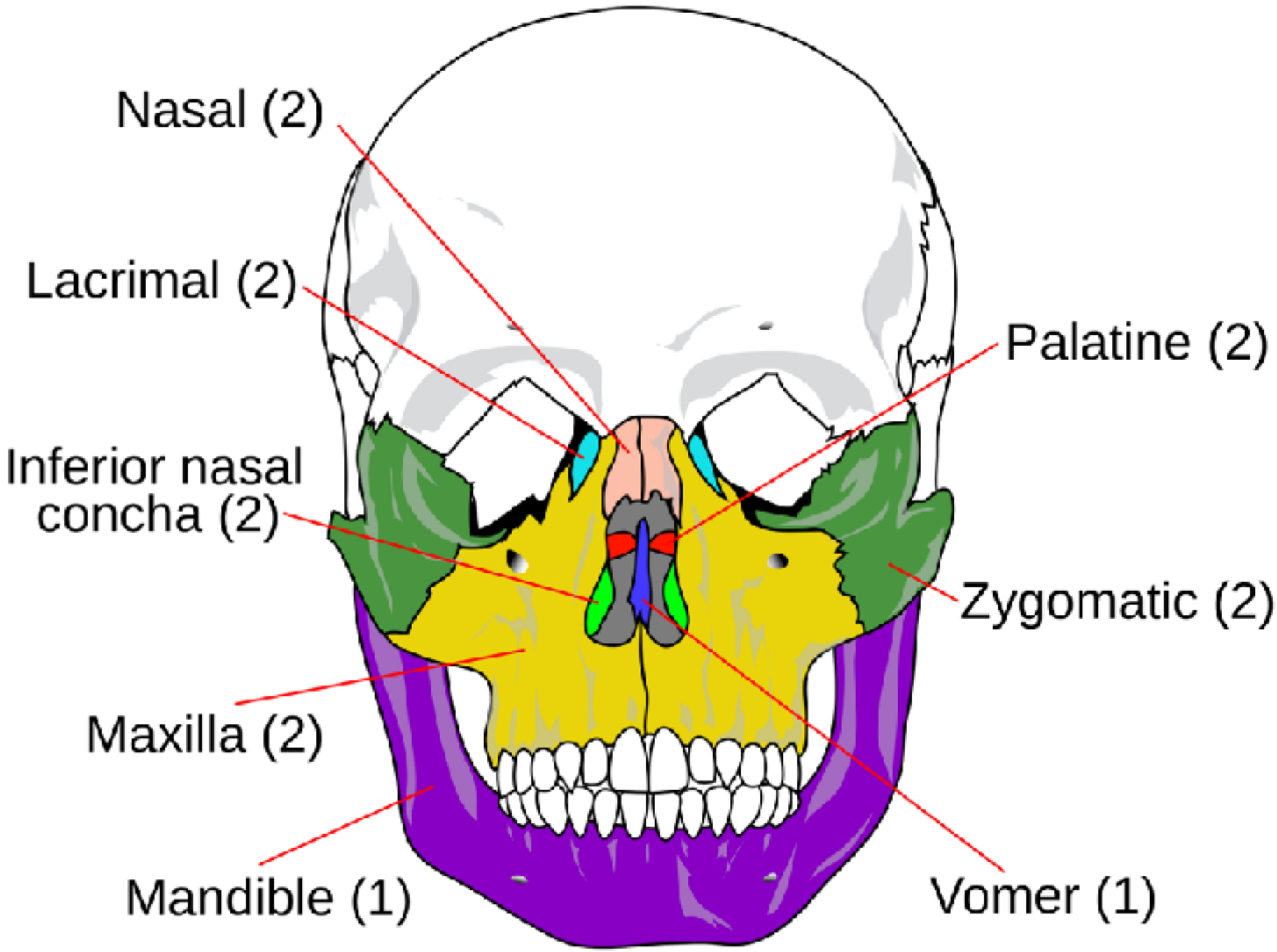

14 Facial Bones

Cranial Strain Patterns

Flexion - Inhalation Phase

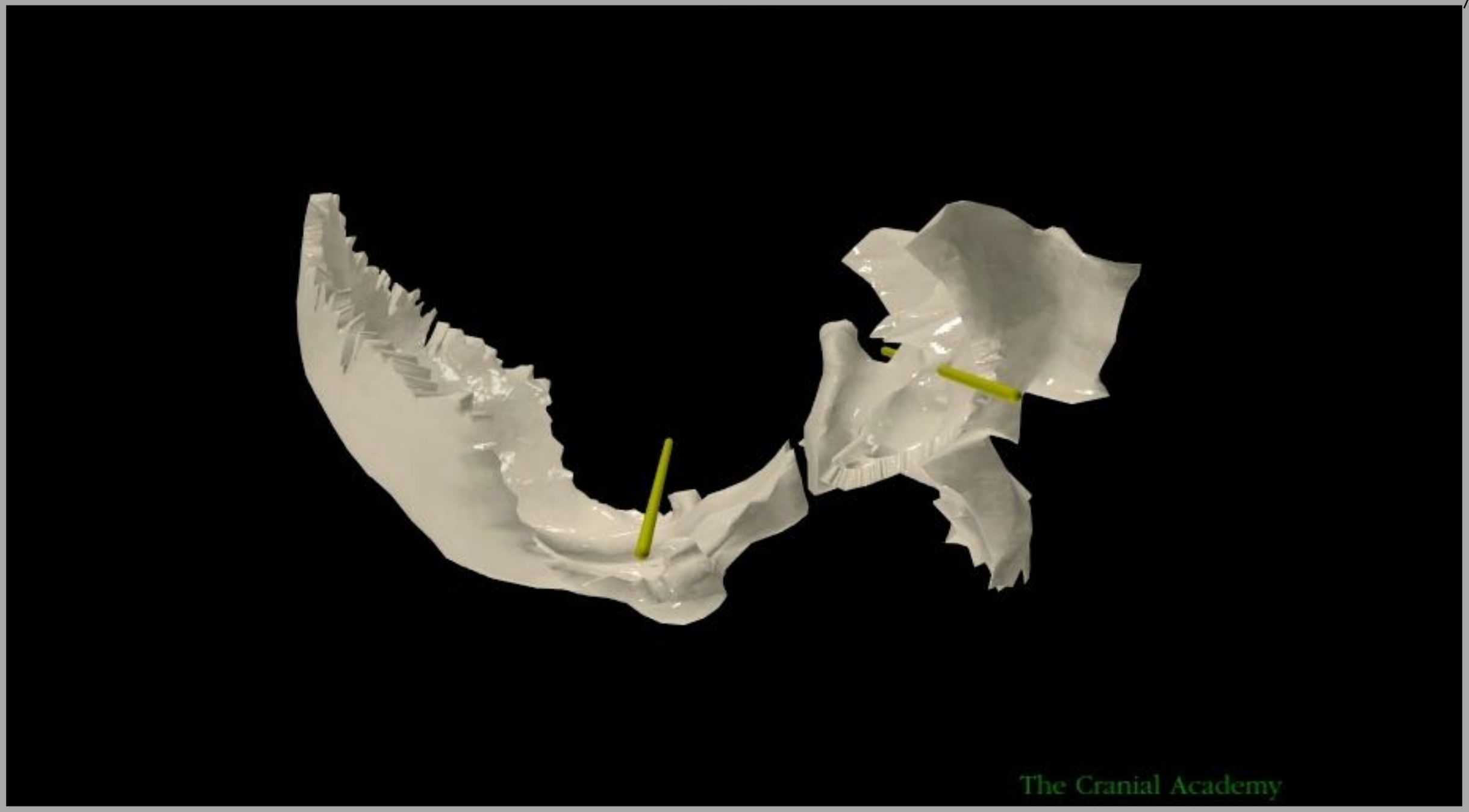

Extension - Exhalation Phase

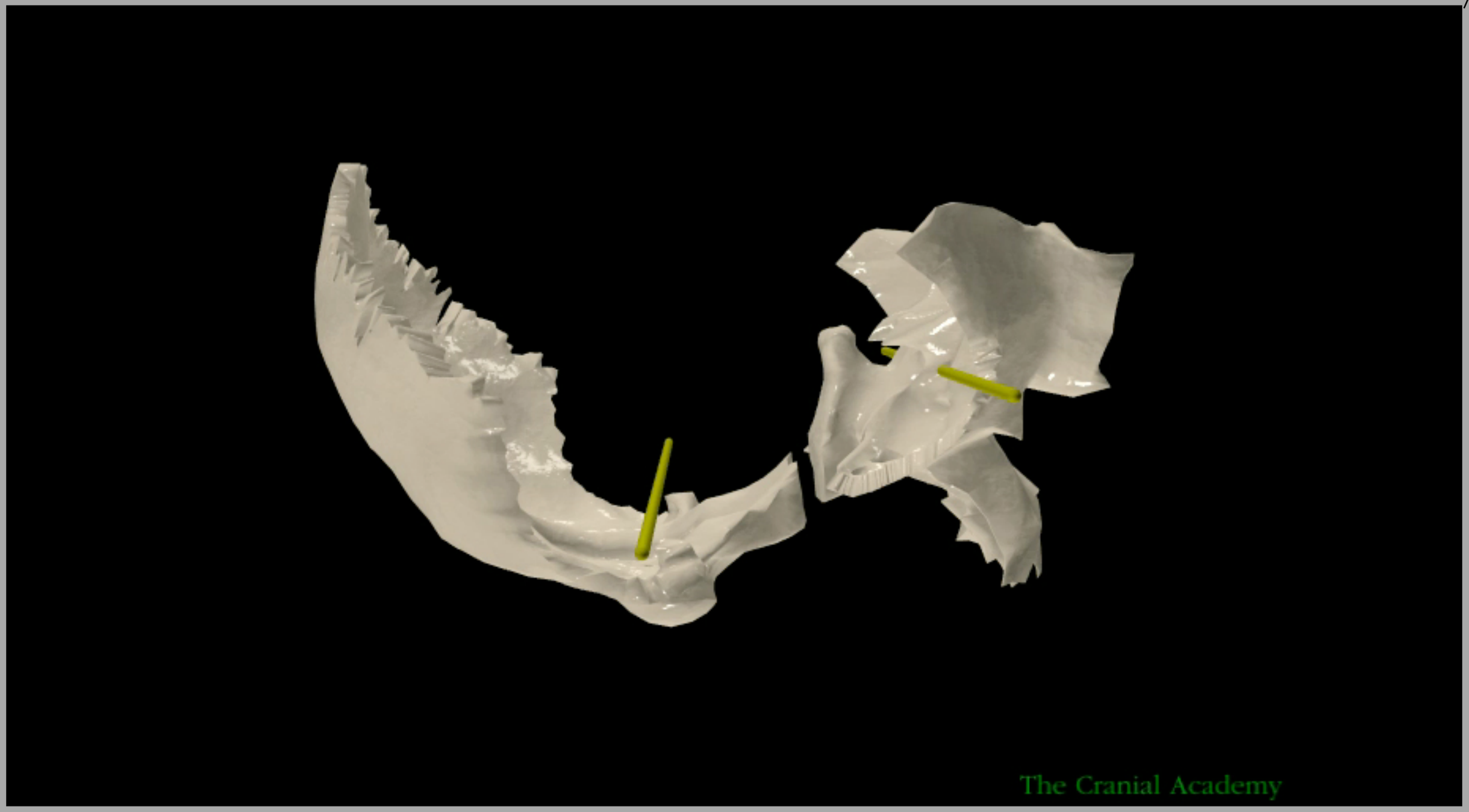

Cervical/Mandibular Relationships

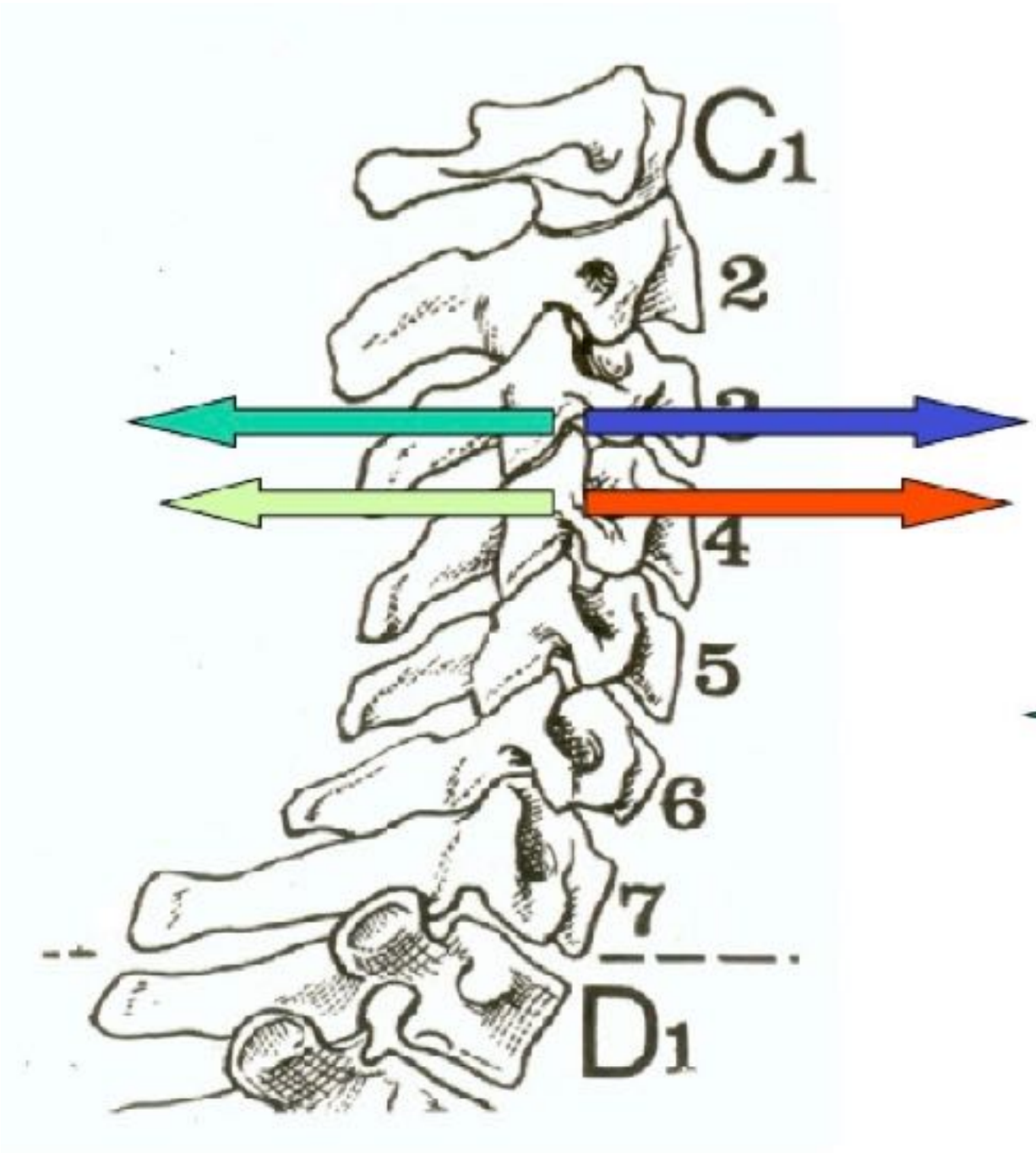

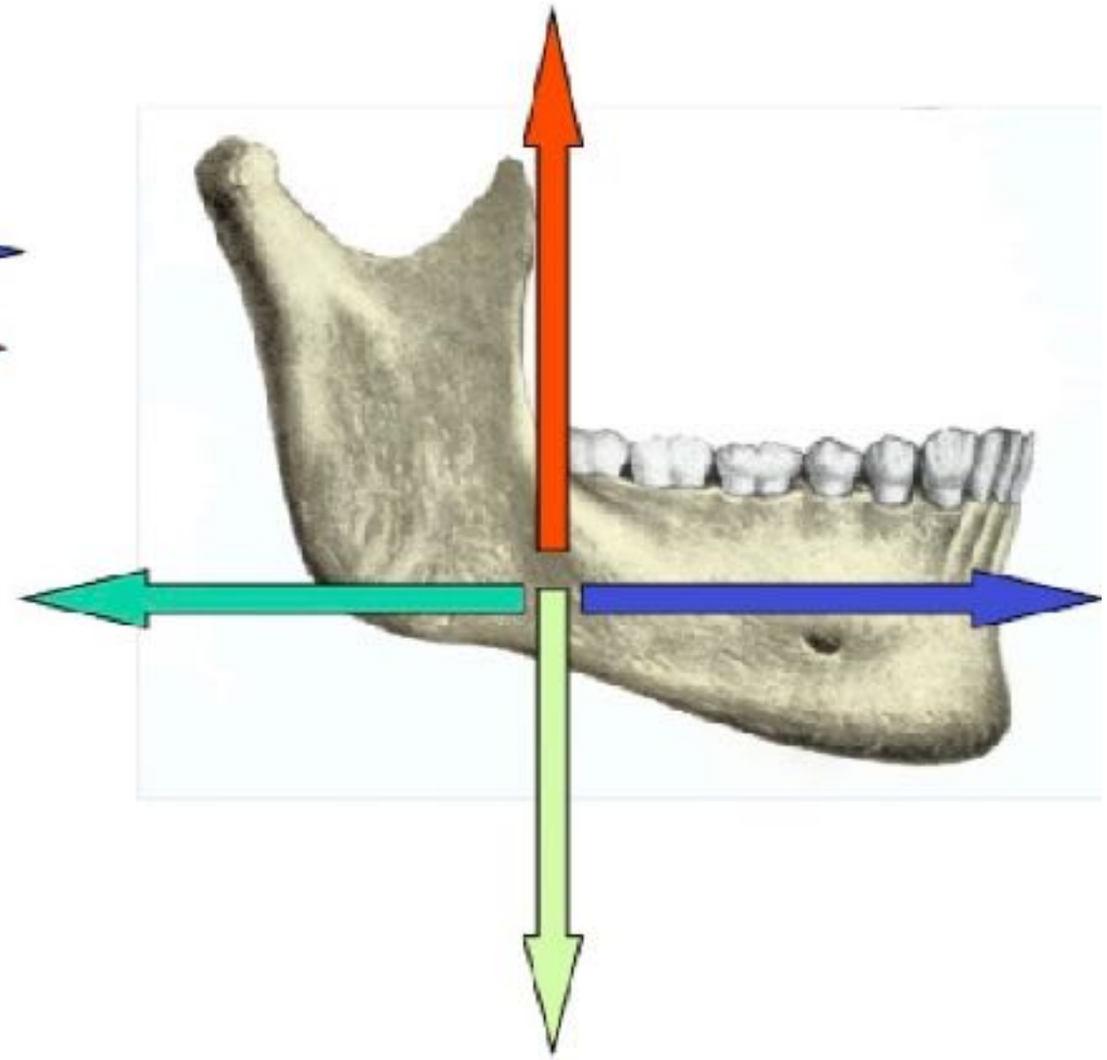

Flexion

Flexion

All paired bones externally rotate
All midline bones flex

- Findings - all quadrants in external rotation
  - Wide and sloping Head
  - Increased transverse diameter
  - Forehead Receding and Brow Prominent
  - AP diameter equal on both sides
  - Sagittal suture flattened or depressed
- Sphenoid
  - Superomedial inferolateral diameter greater
  - Increased fronto zygomatic angle
  - Orbits wider
  - Eyeballs protuberant
  - Frontal processes of maxillae are nearly in coronal plane
  - Maxillary palantine processes flattened
- Occiput
  - Protruding ears
  - Mastoid tips posteromedial
- Maxillae
  - Nasolabial crease deeper

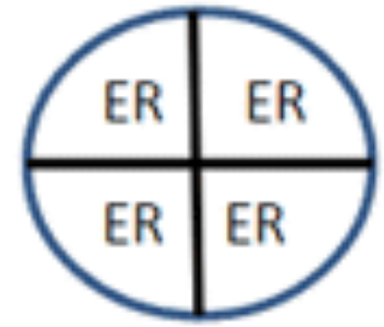

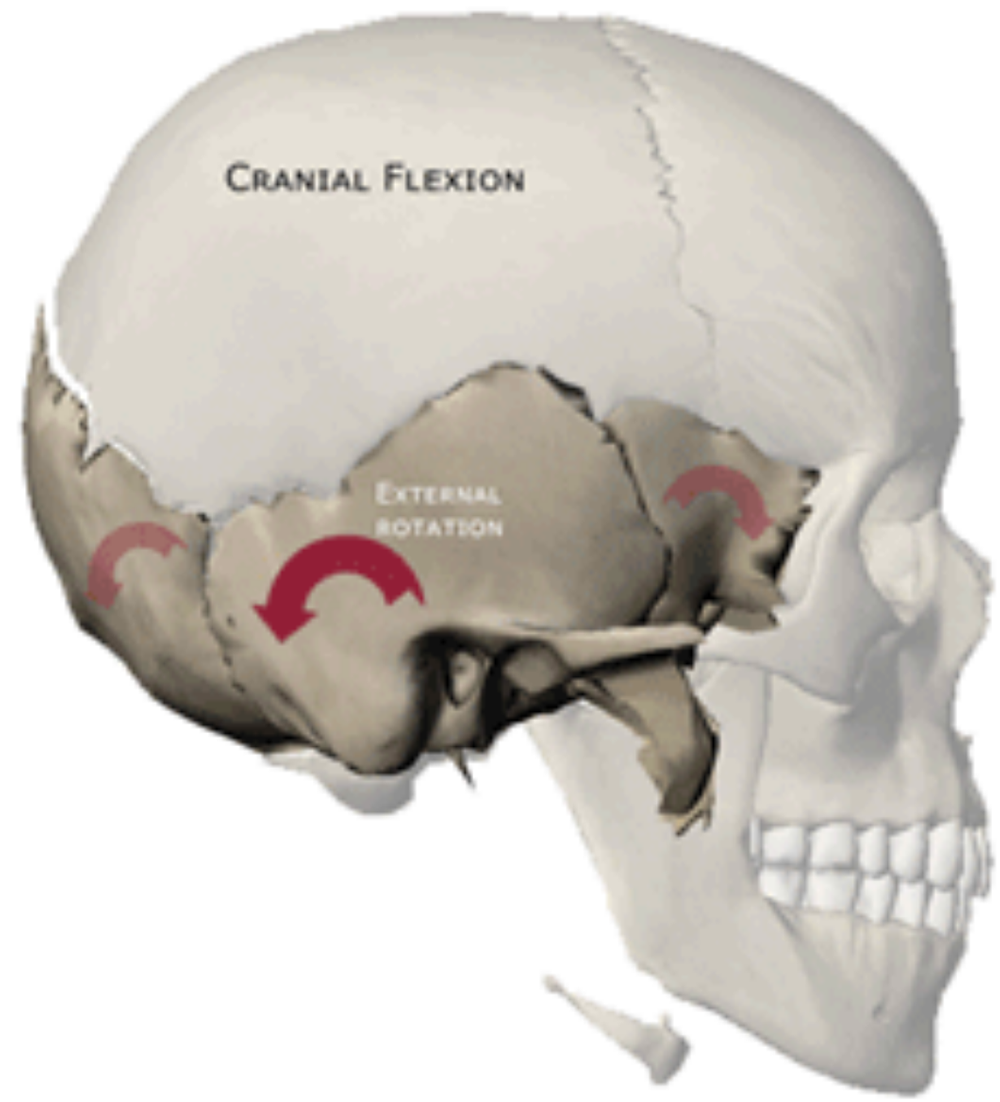

Flexion

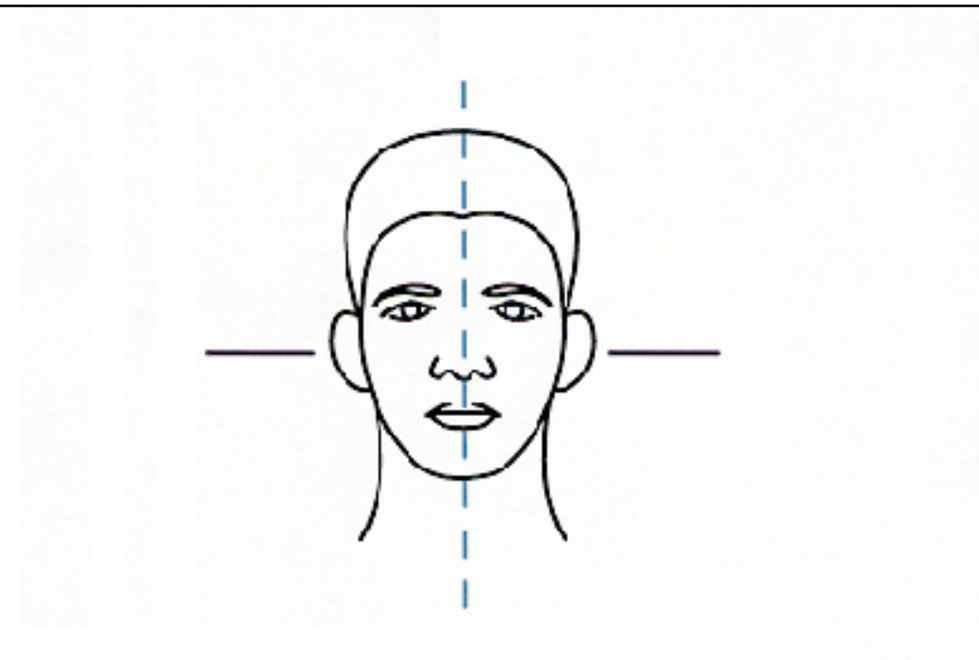

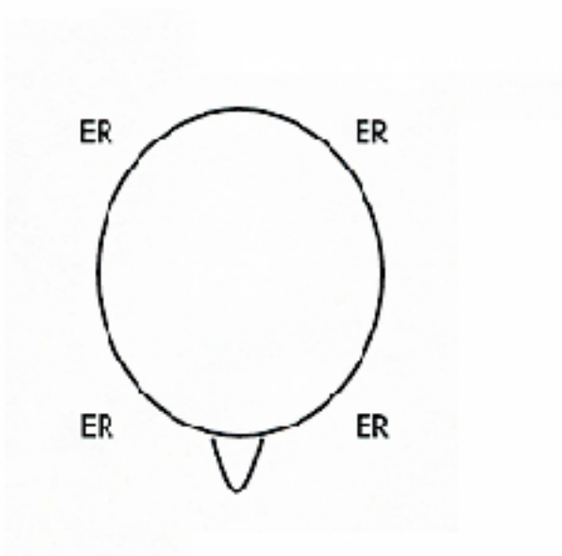

diagrams © James/Strokon Seminars.Used with permission.

Flexion

Flexion

Flexion

Extension

FX

Extension

All paired bones internally rotate
All midline bones extend

° Findings - all quadrants in Internal Rotation
- Long narrow head
- Decreased transverse diameter
- Forehead prominent with Brow receding

° Sphenoid
- Superomedial inferolateral diameter decreased
- Decreased frontozygomatic angle
- Orbit narrowed
- Eyeballs retruded
- Frontal processes of the maxillae are nearly in sagittal plane
- Maxillary palantine processes arched

° Occiput
- Ears close to head
- Mastoid tips anterolateral

° Maxillae
- Nasolabial crease shallow

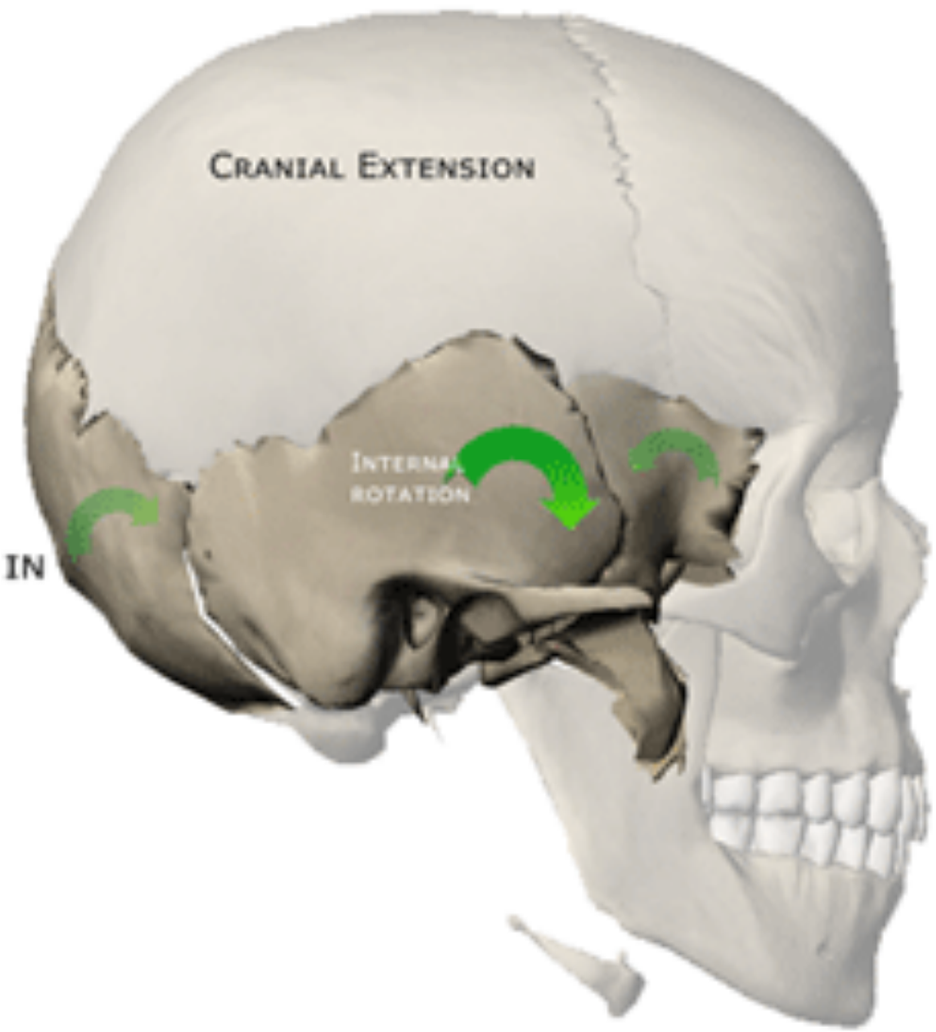

Extension

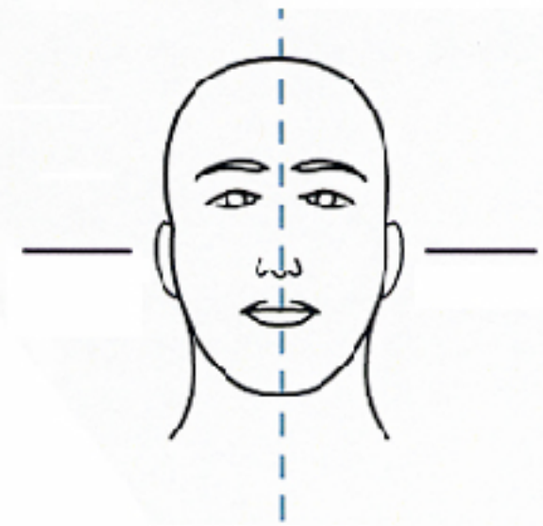

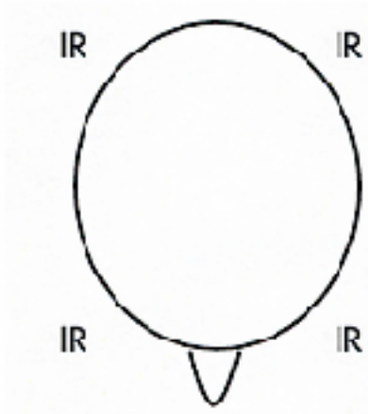

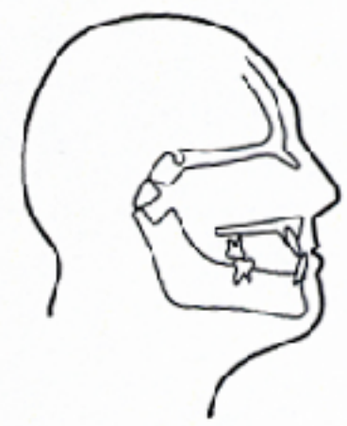

diagrams © James/Strokon Seminars.Used with permission.

Extension

Extension

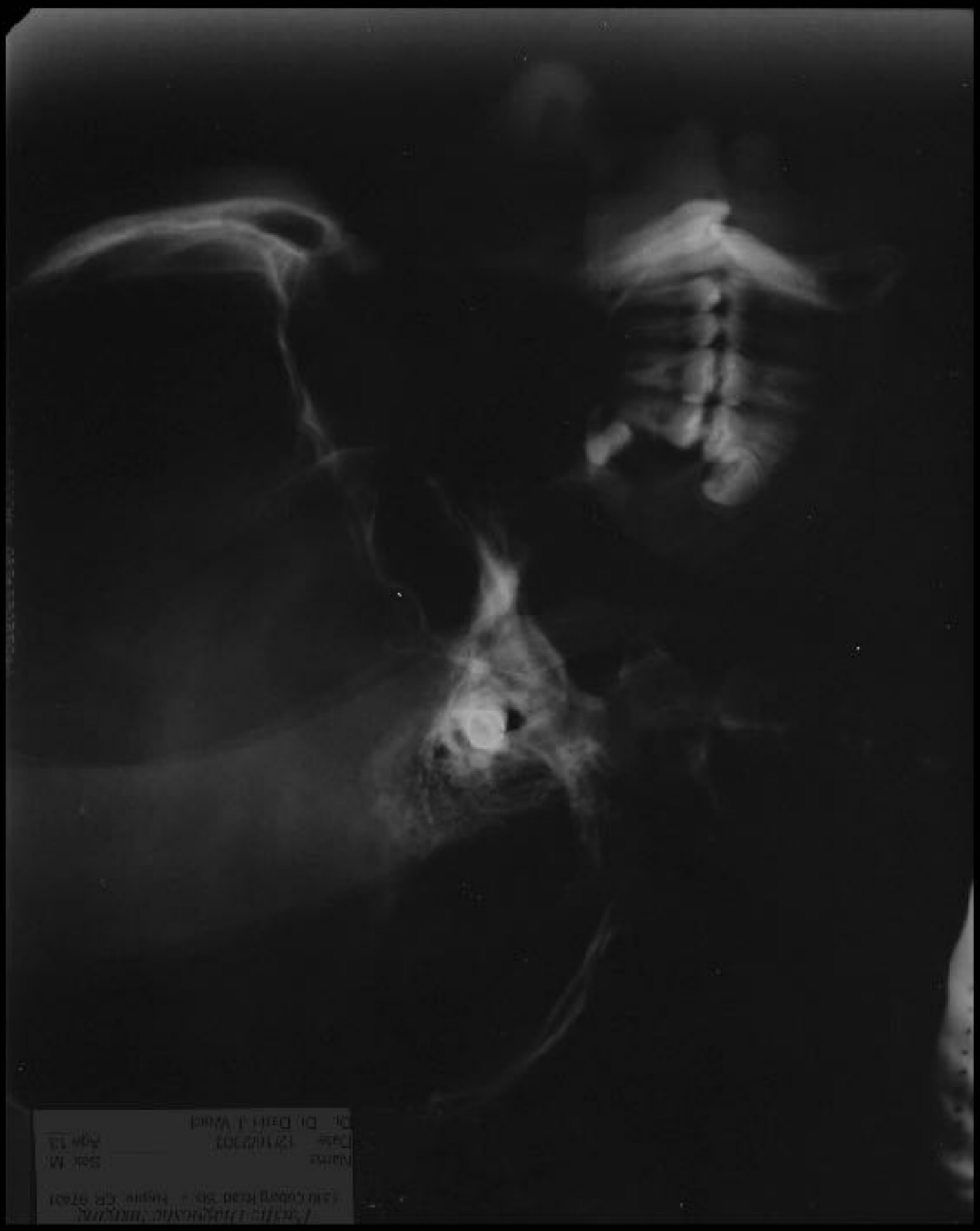

12/10/2003
13 YO M
D. WARD DDS



Extension

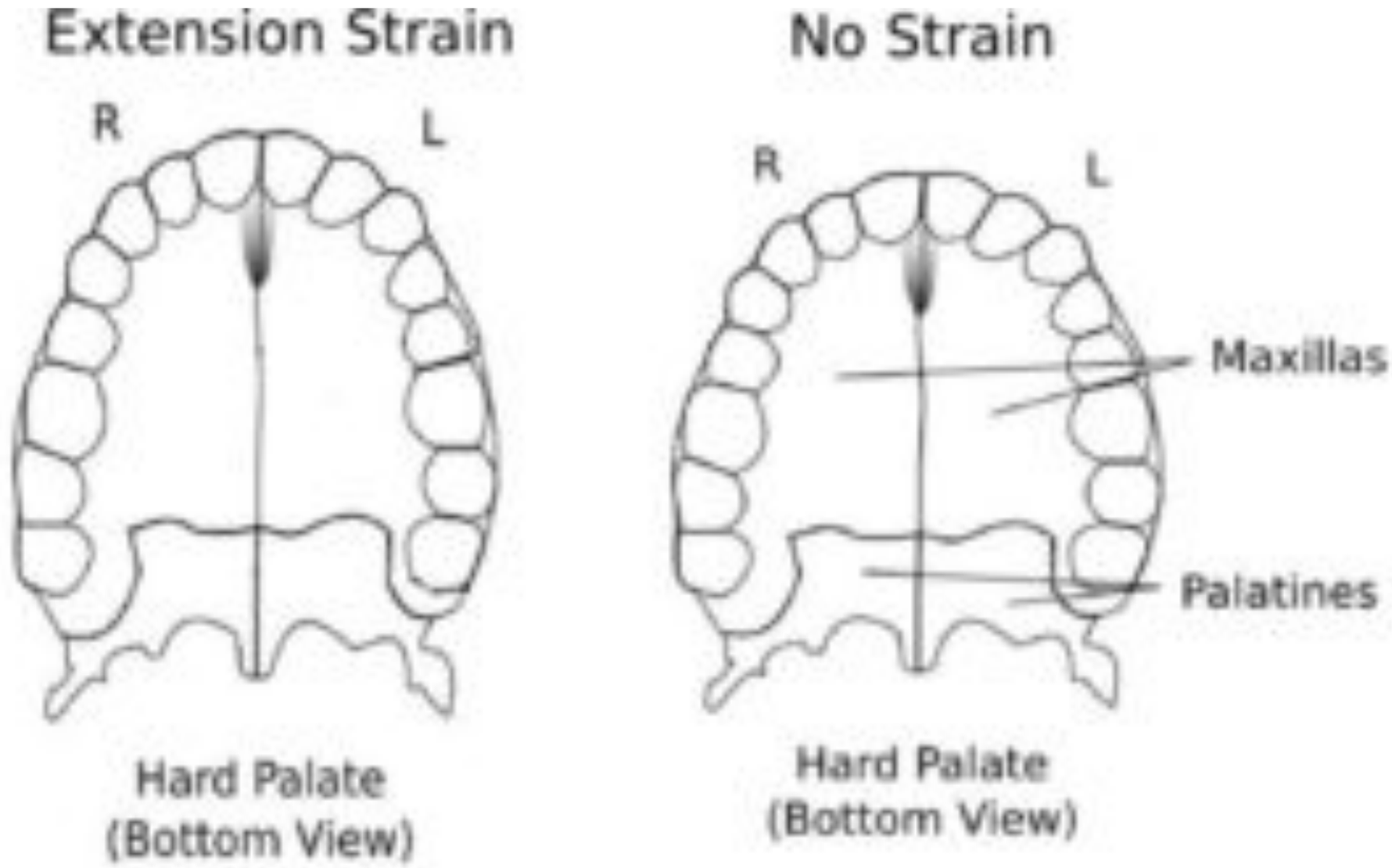
Extension Strain
R
L
Hard Palate
(Bottom View)
No Strain
R
L
Maxillas
Palatines
Hard Palate
(Bottom View)

A Bit More Anatomy

WebDonuts.com

The Trigeminal Nerve

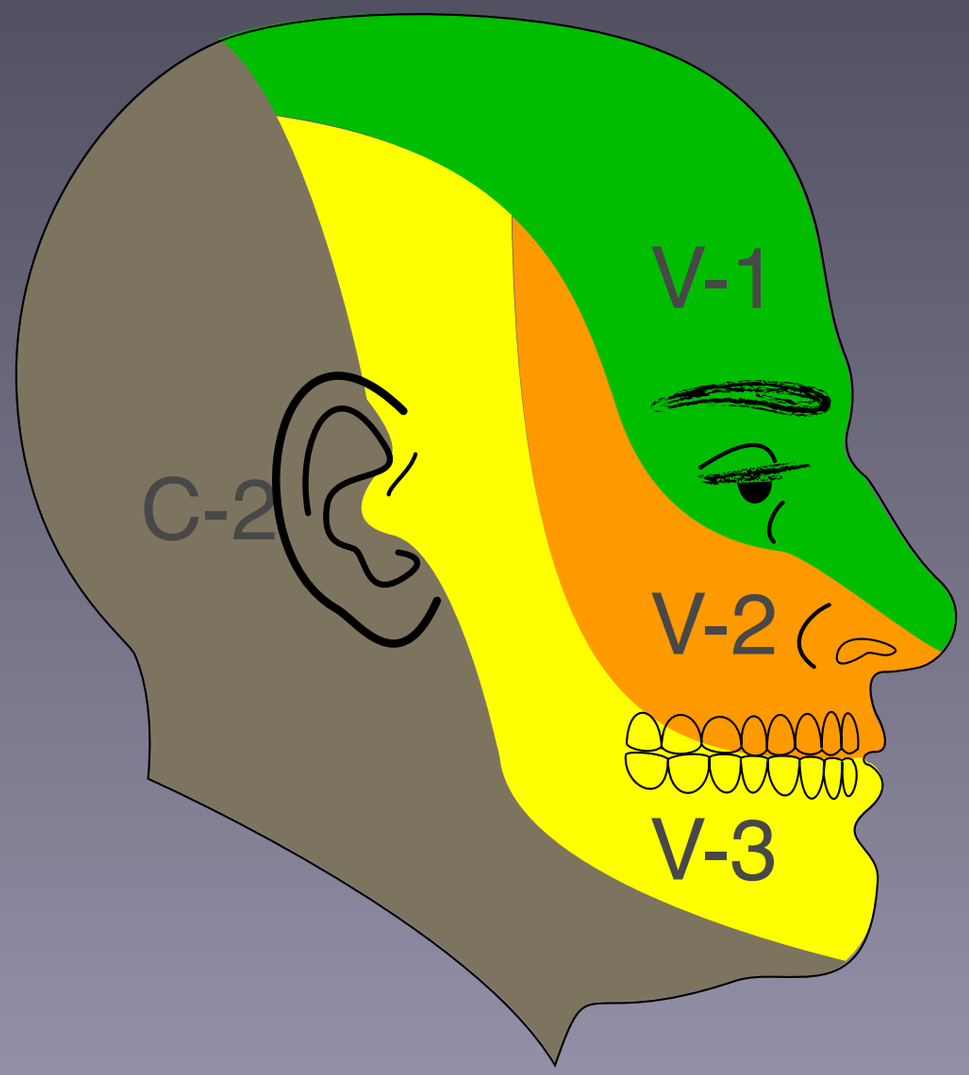

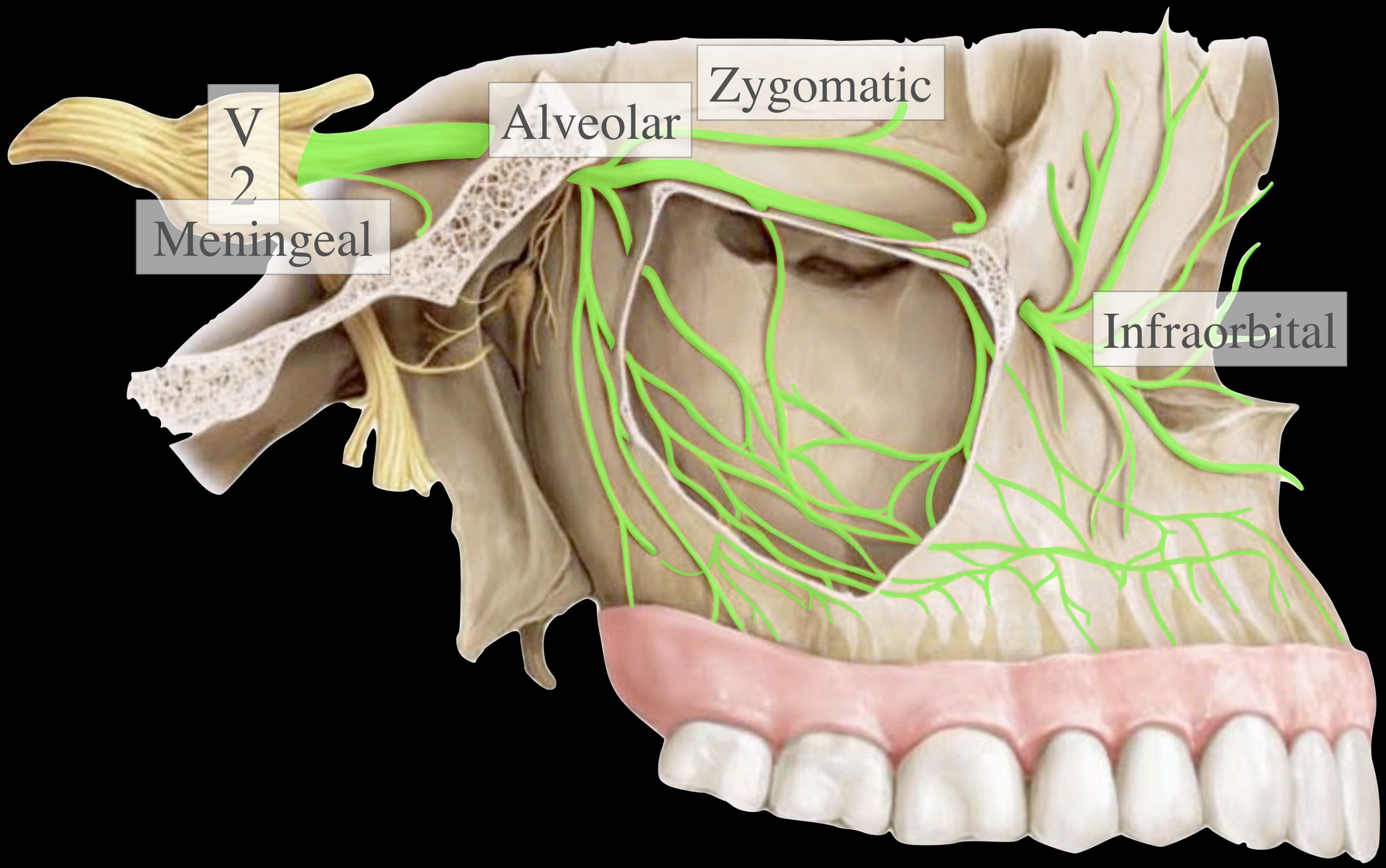
V
2
Meningeal
Alveolar
Zygomatic
Infraorbital

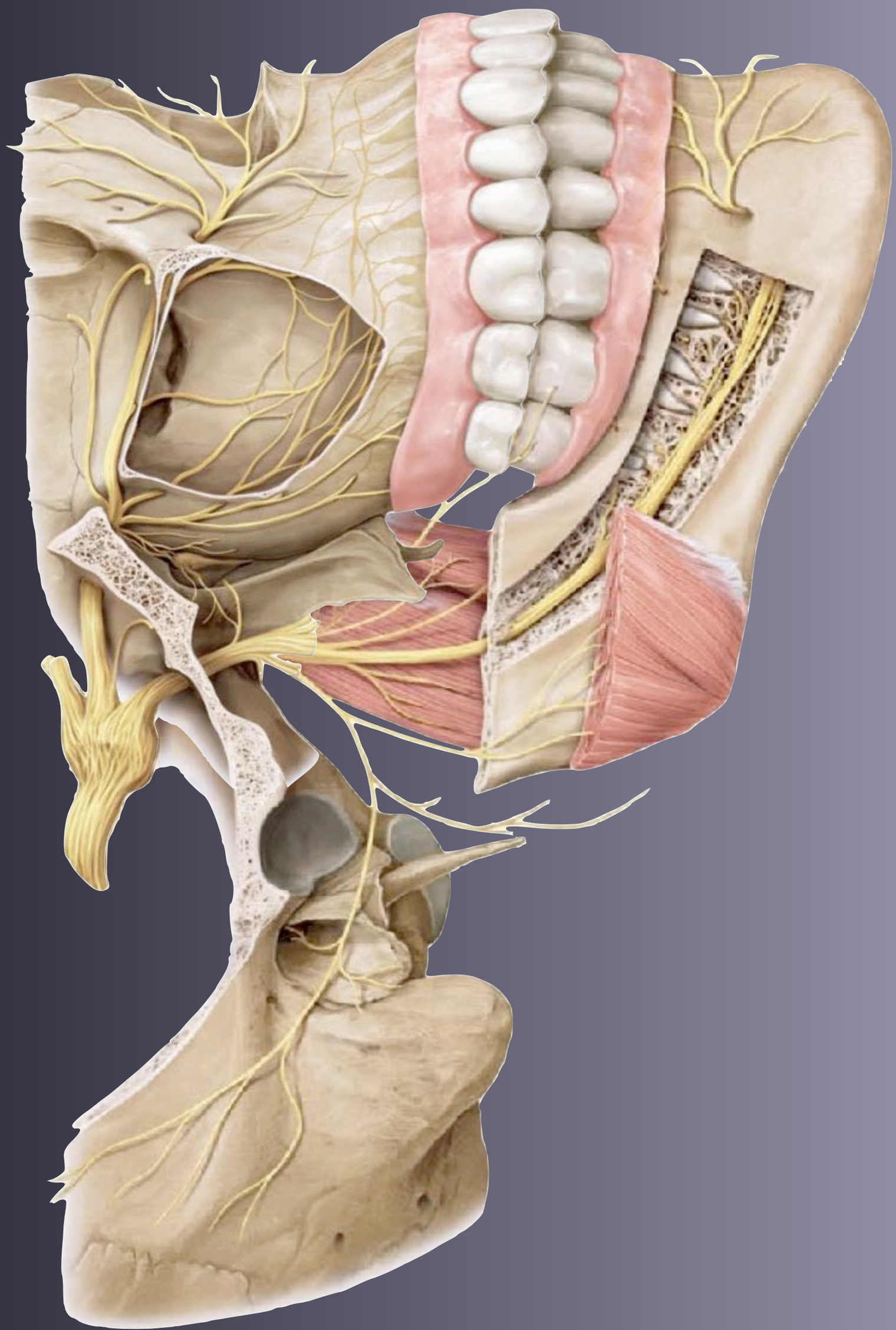

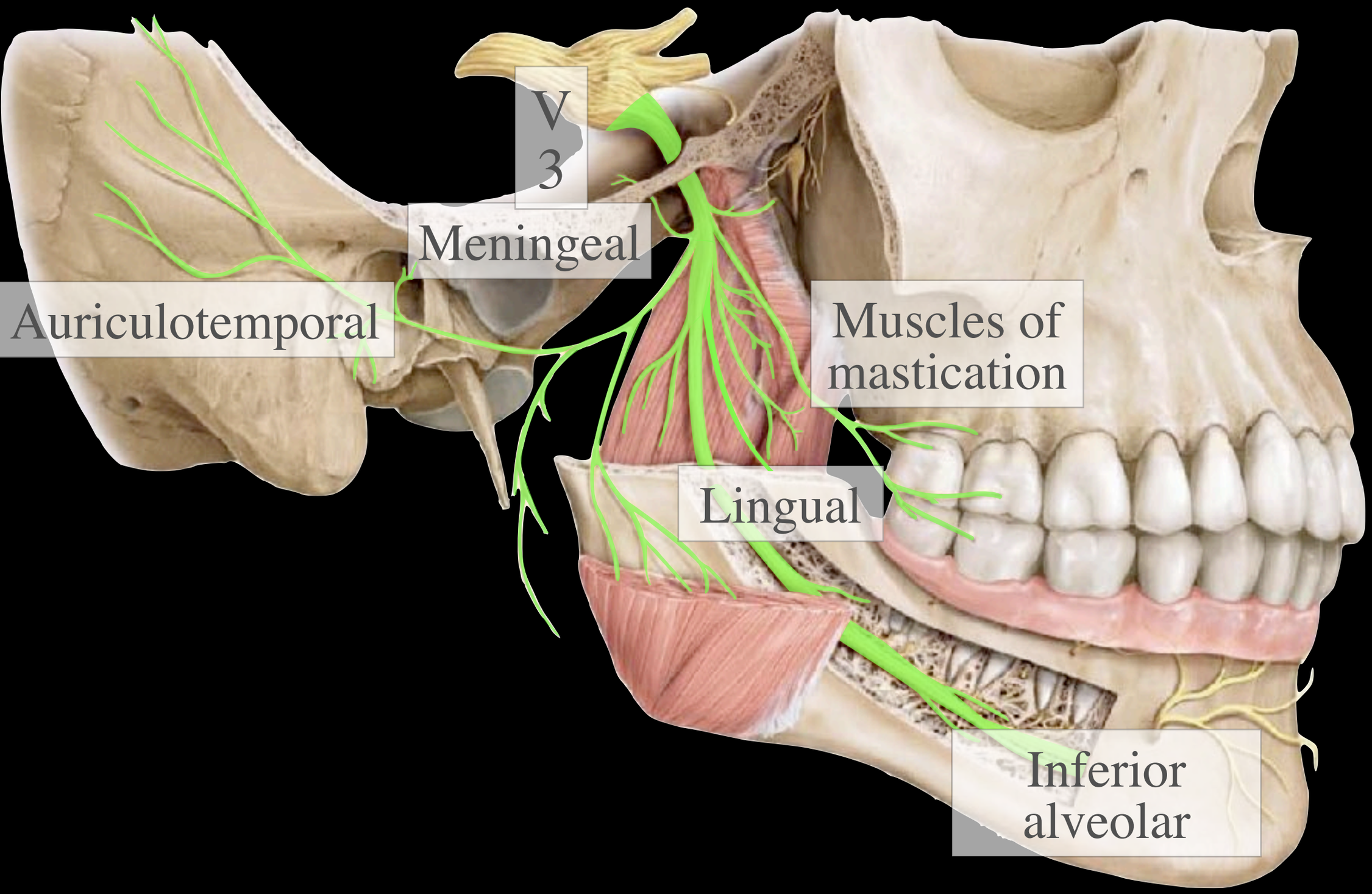
V
3
Meningeal
Auriculotemporal
Muscles of
mastication
Lingual
Inferior
alveolar

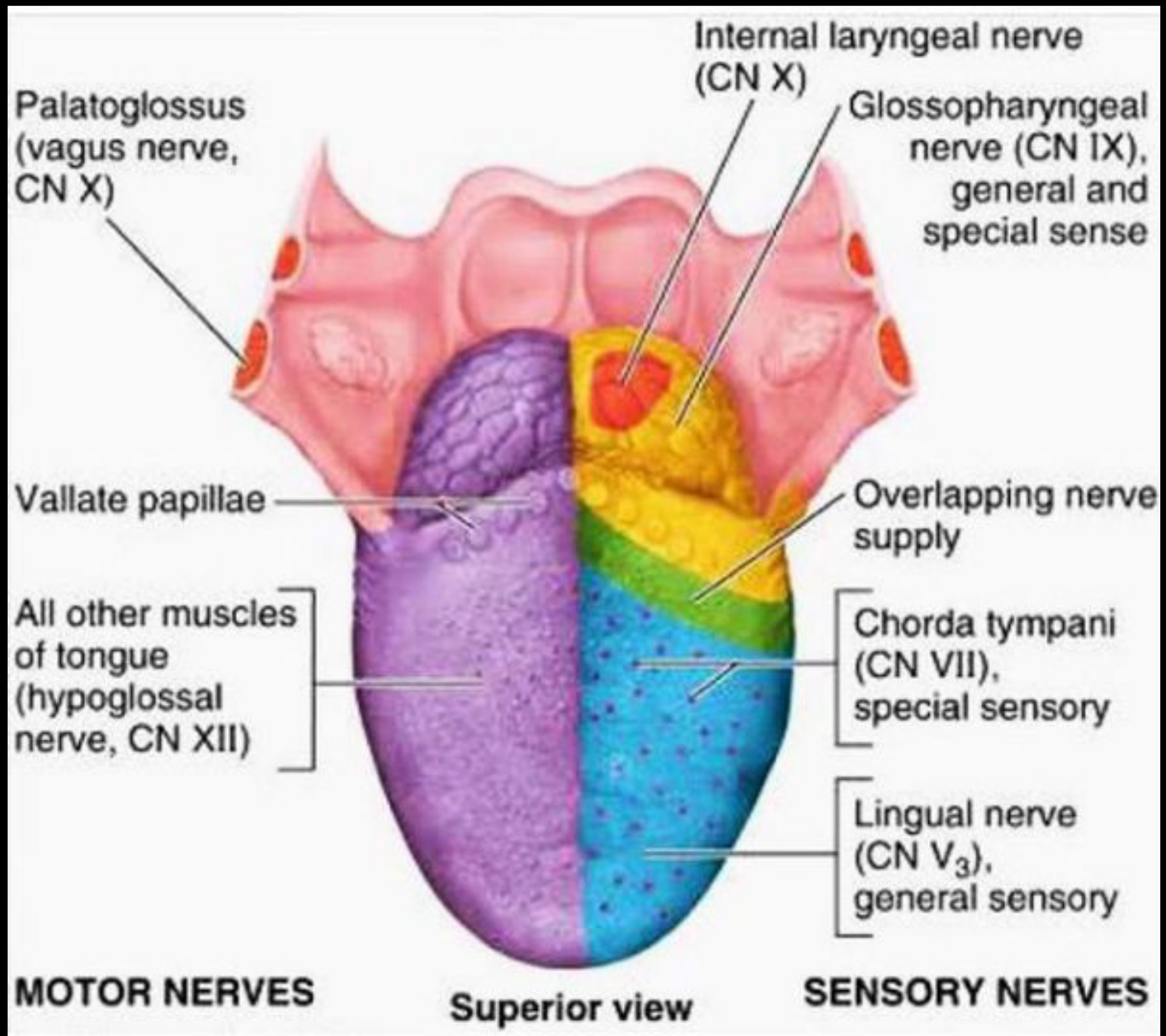
Internal laryngeal nerve (CN X)
Palatoglossus (vagus nerve, CN X)
Glossopharyngeal nerve (CN IX), general and special sense
Vallate papillae
Overlapping nerve supply
All other muscles of tongue (hypoglossal nerve, CN XII)
Chorda tympani (CN VII), special sensory
Lingual nerve (CN V3), general sensory
MOTOR NERVES
Superior view
SENSORY NERVES

V1- anterior and middle cranial fossae

V2- anterior and middle cranial fossae

V3- middle cranial fossa

Vagus, Hypoglossal, Upper 3 Cervical Vertebra - posterior cranial fossa

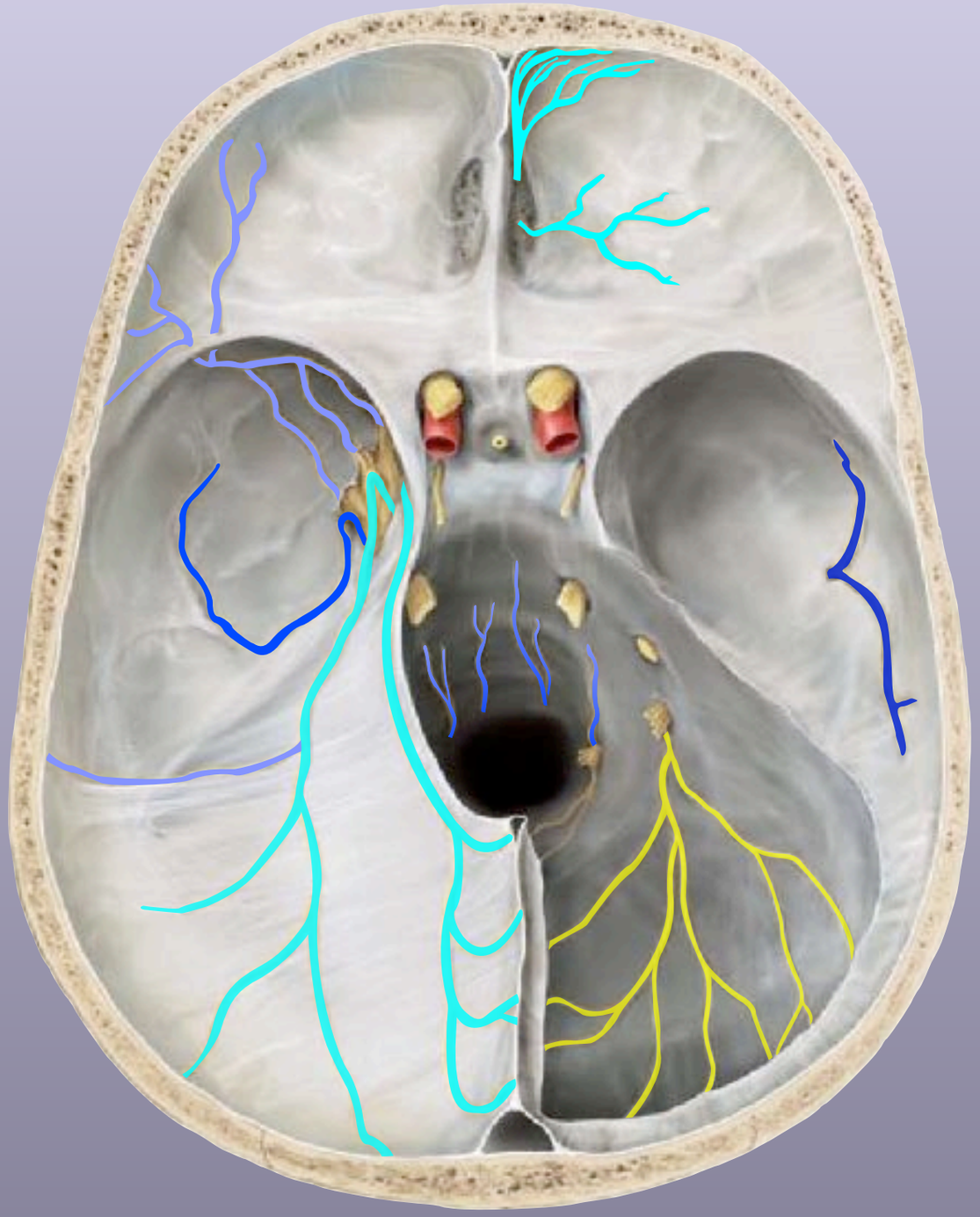

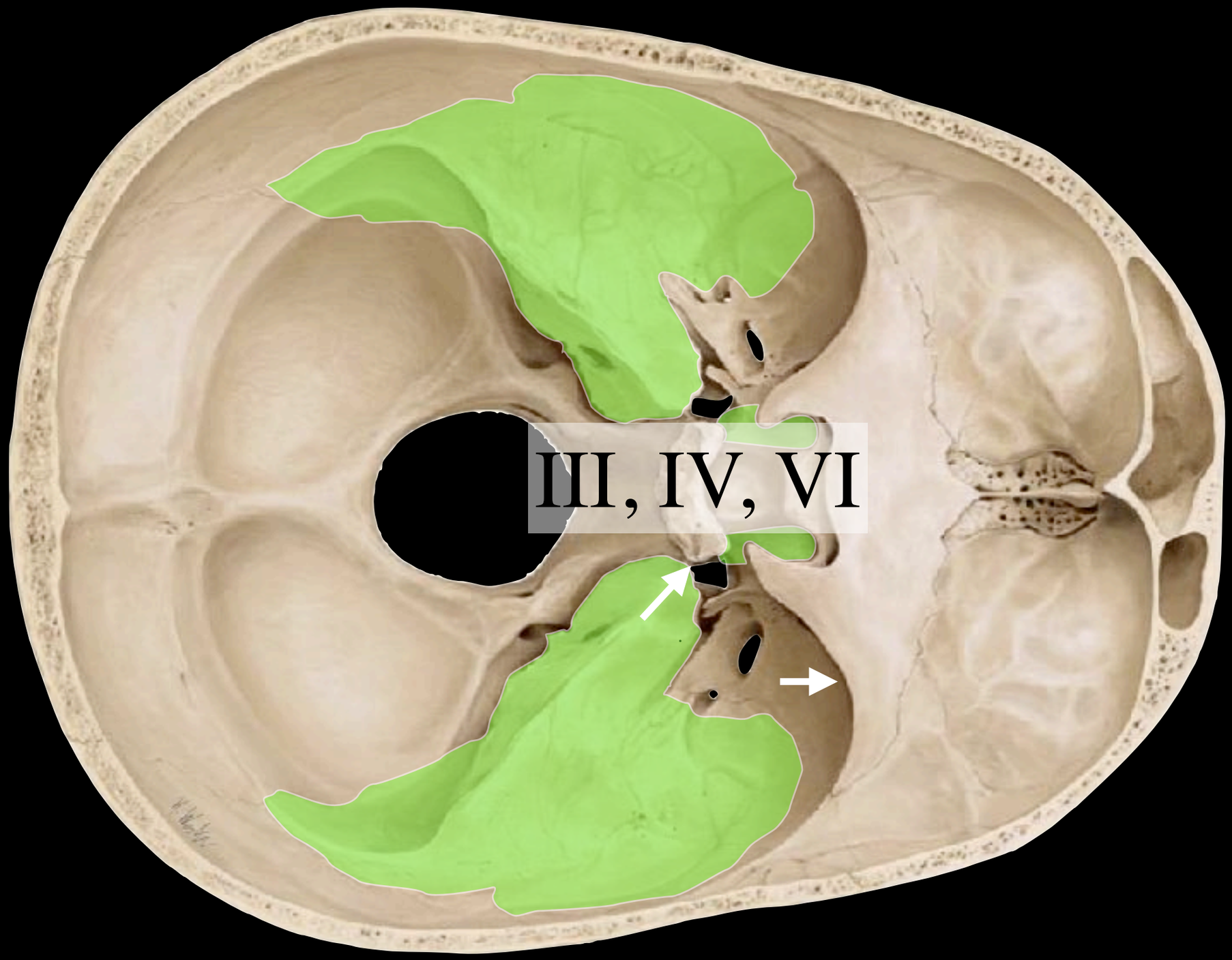
III, IV, VI

WebDonuts.com

Cranial Torsion

TORSION

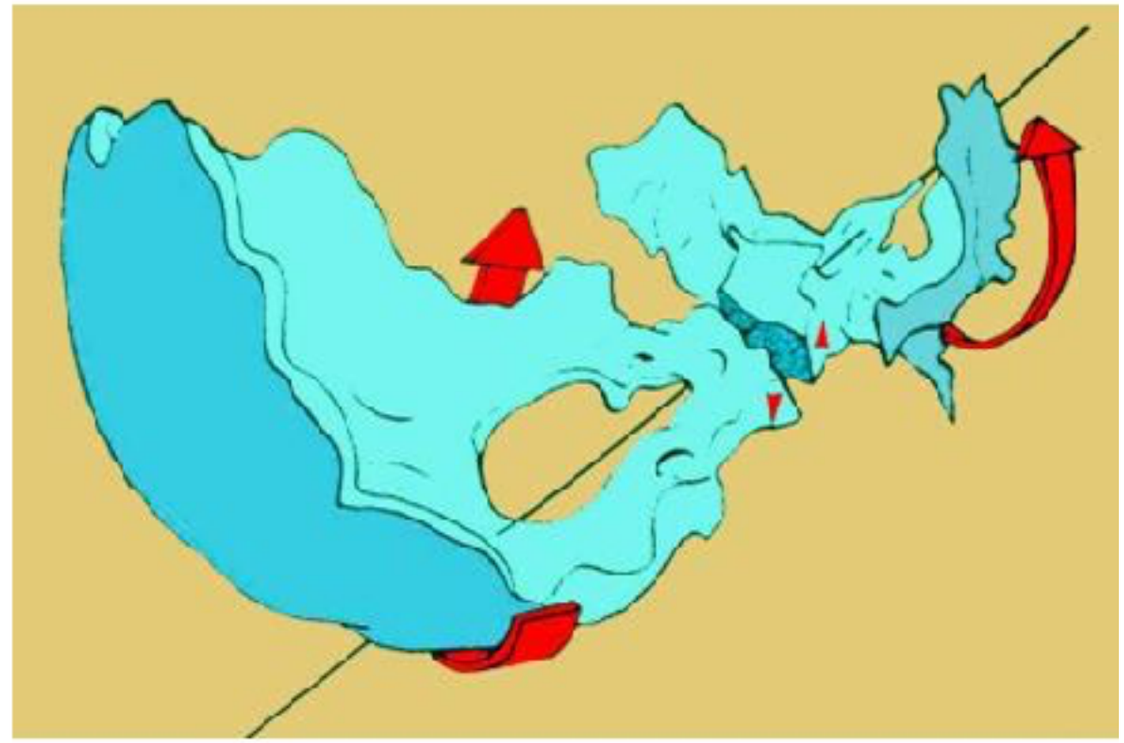

One axis

- Antero-superior to Infero-posterior
- Sphenoid and occiput rotate in opposite directions
- Named for superior great wing of sphenoid

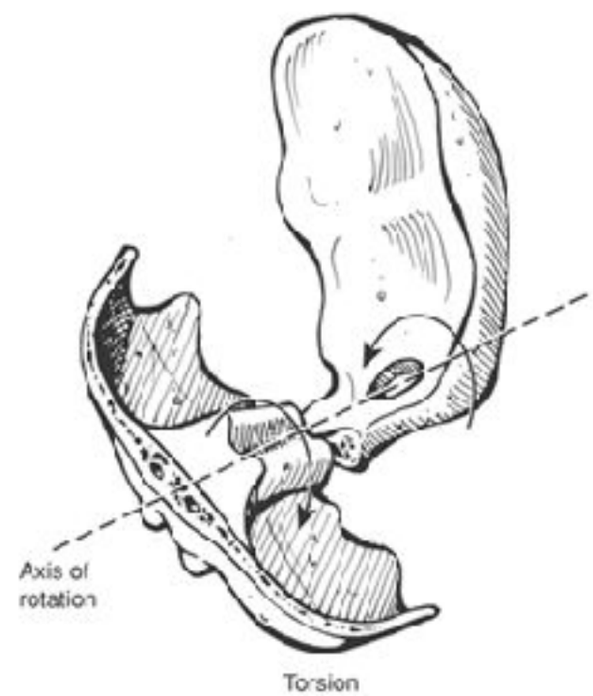

Torsion - Left

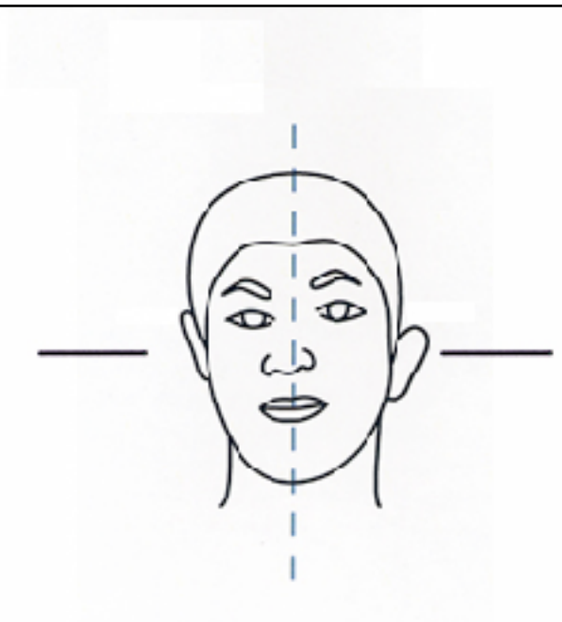

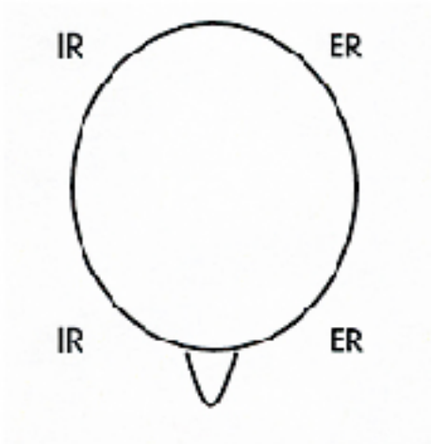

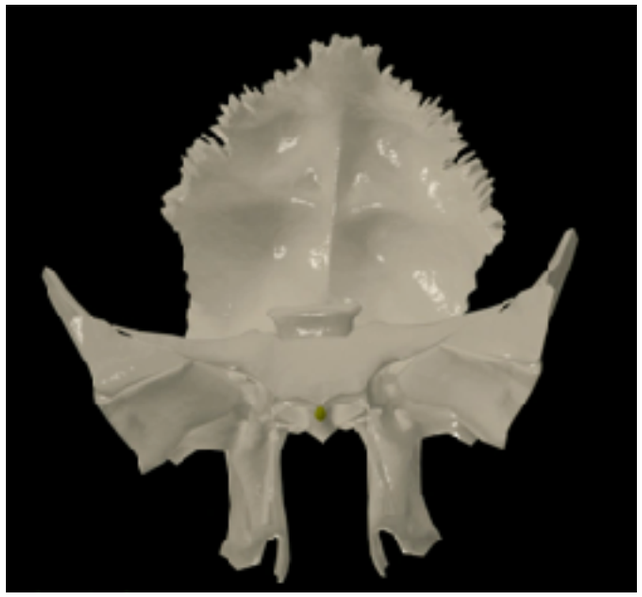

diagrams © James/Strokon Seminars.Used with permission.

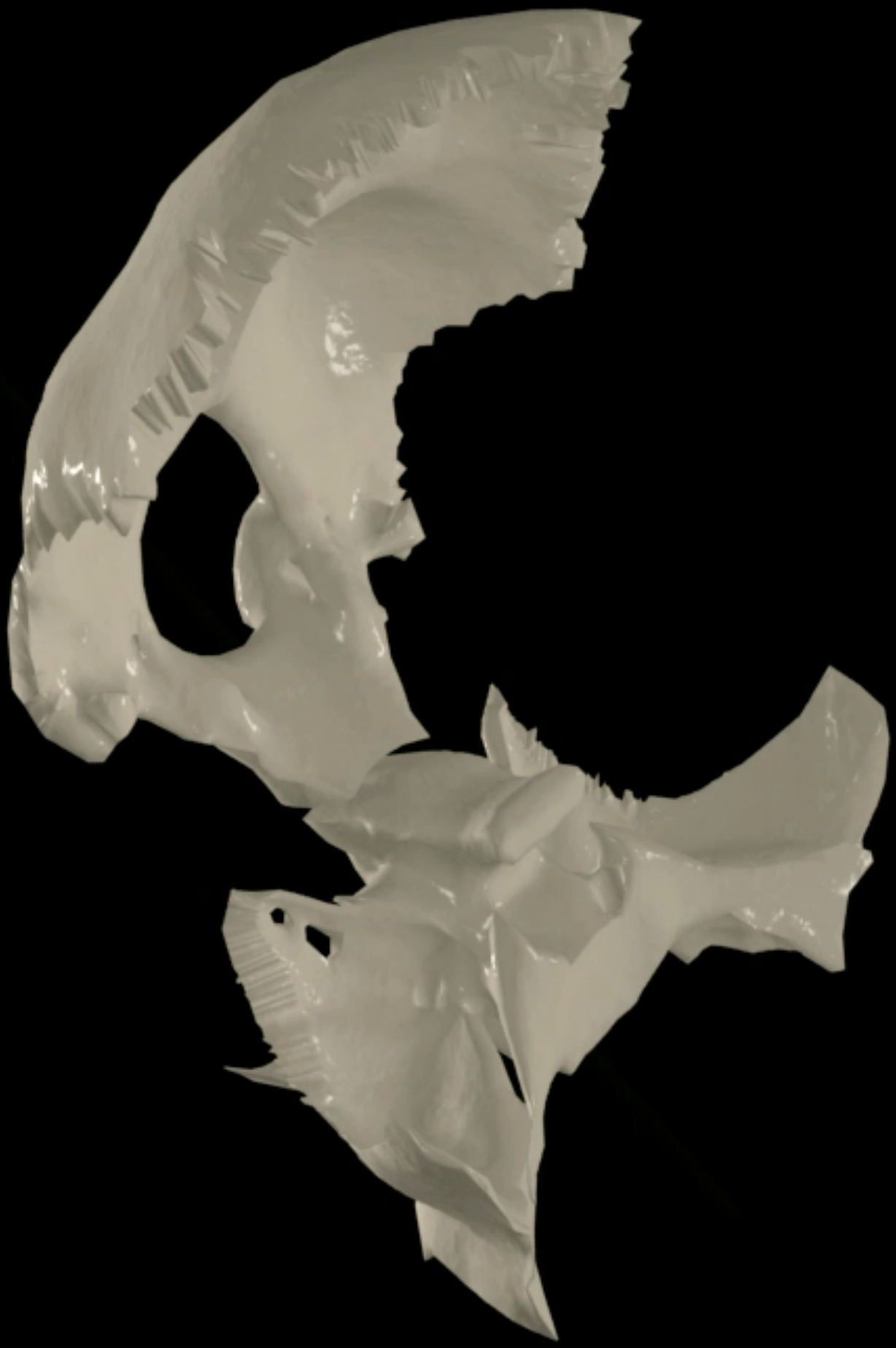

Left Torsion

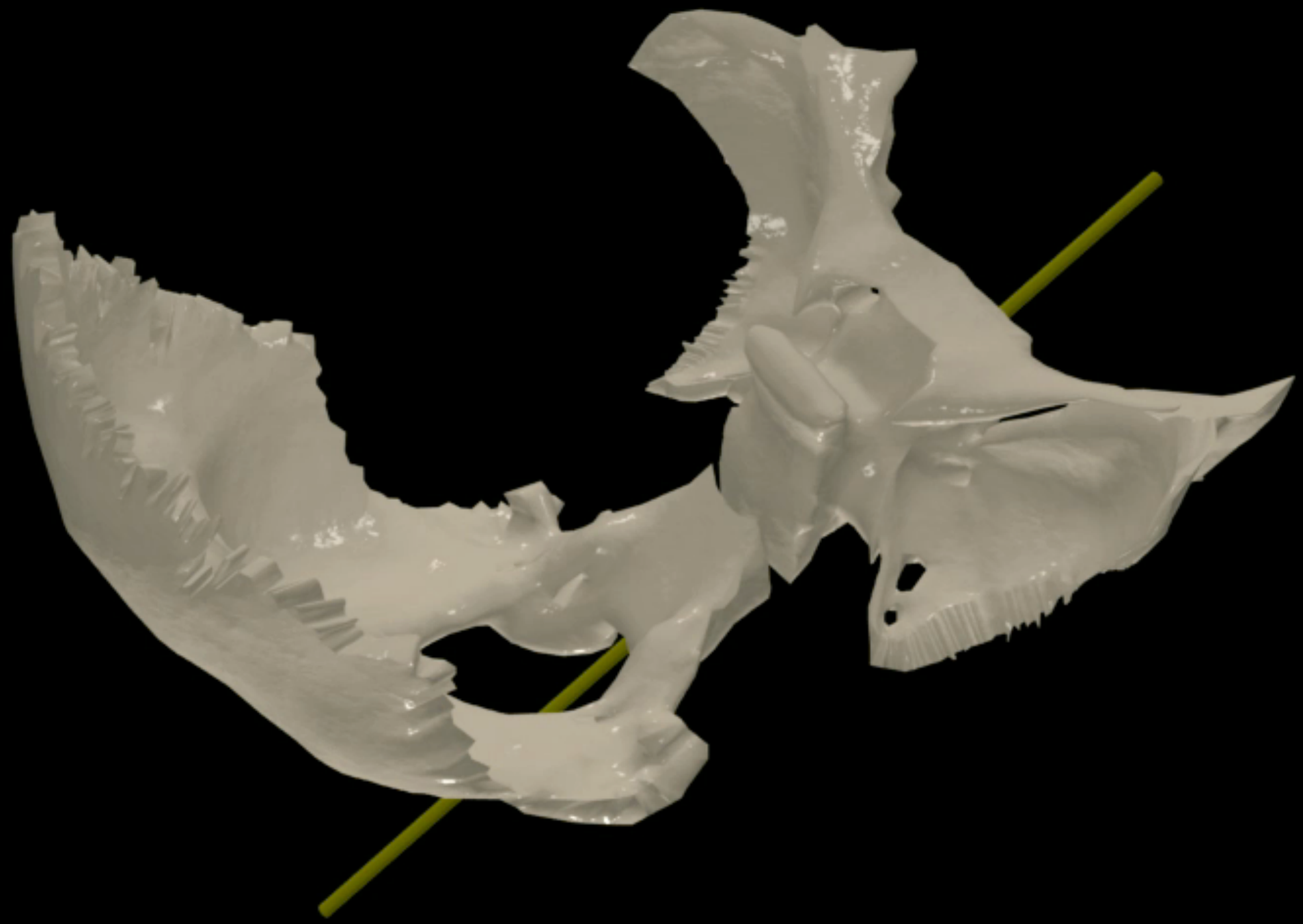

Left Torsion

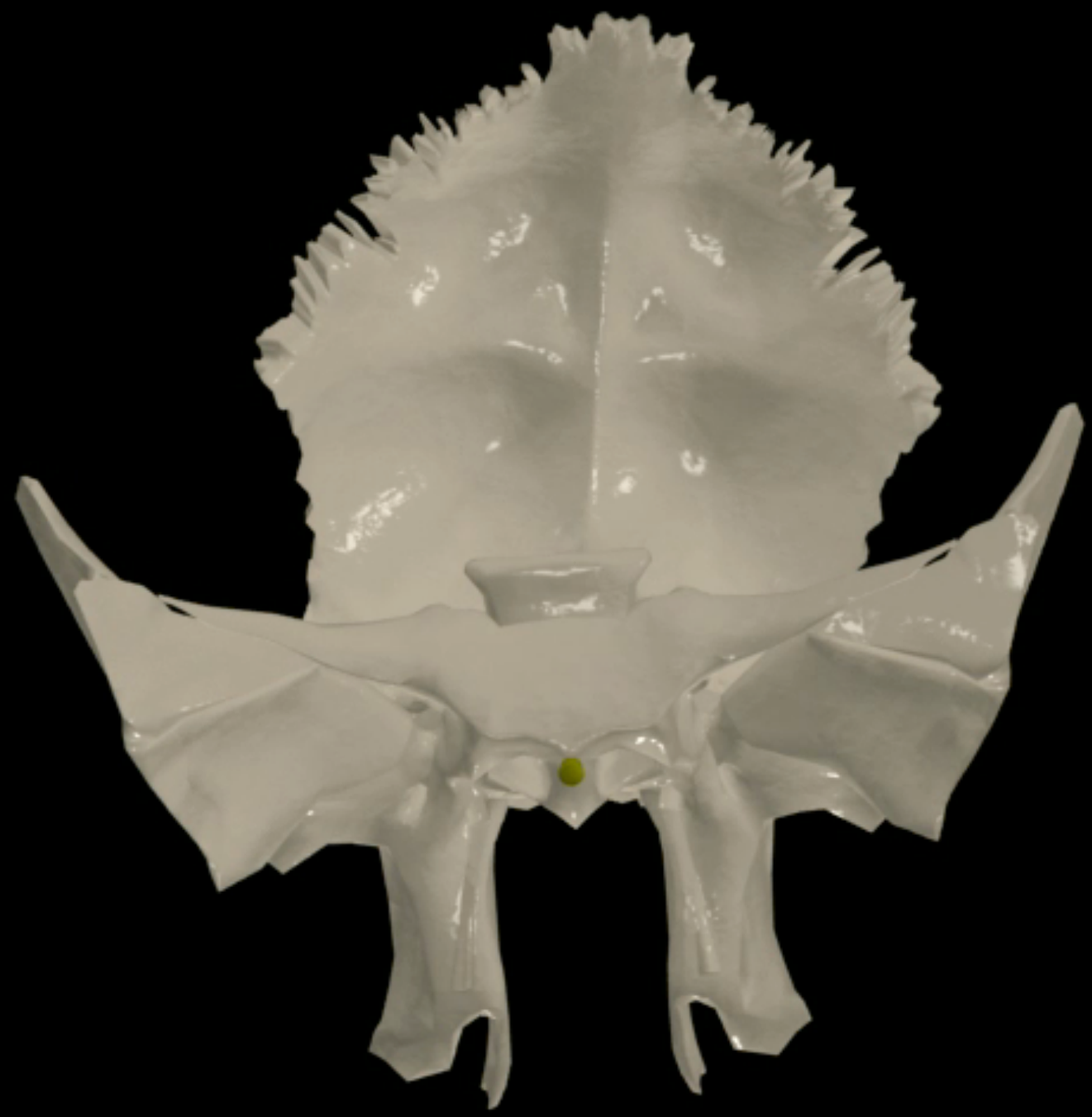

Torsion - Left

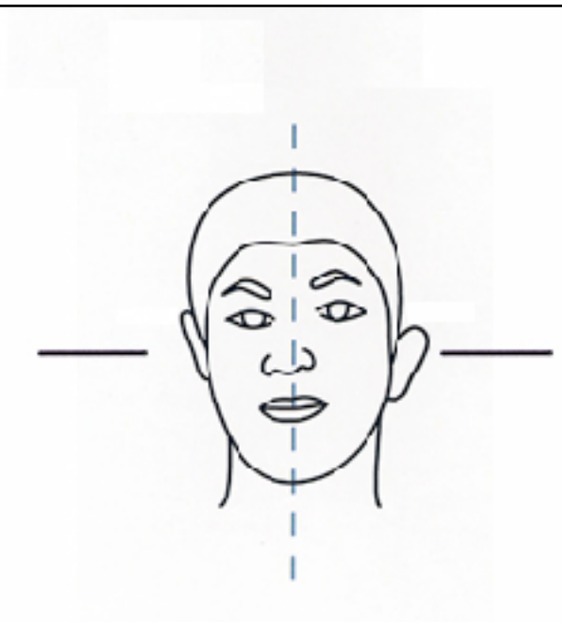

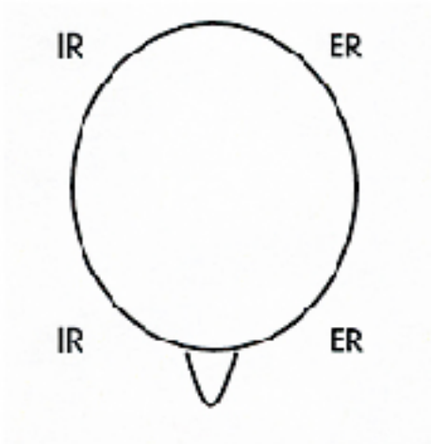

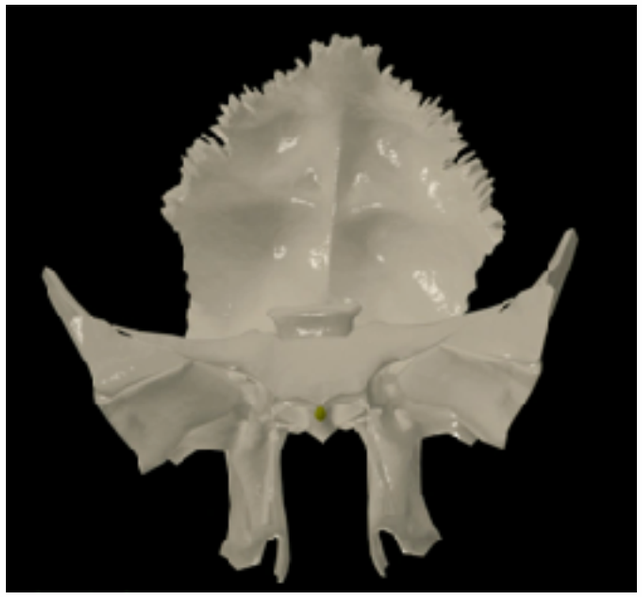

diagrams © James/Strokon Seminars.Used with permission.

Torsion - Right

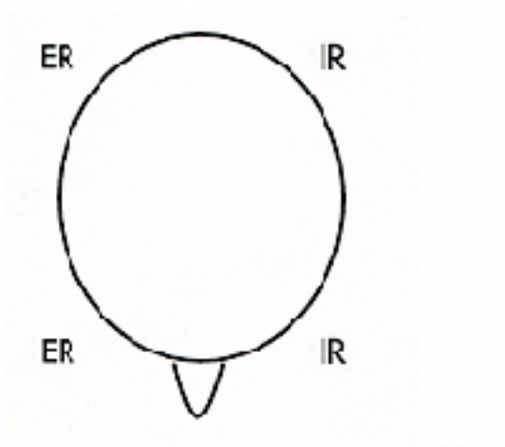

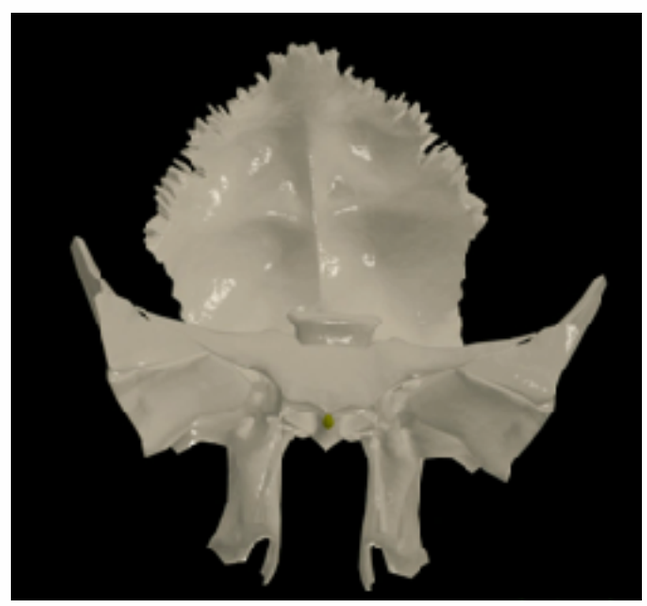

diagrams © James/Strokon Seminars.Used with permission.

Torsion - Left

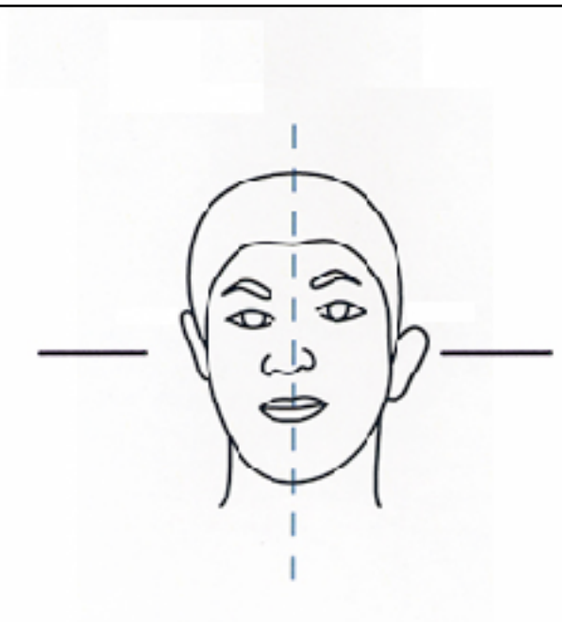

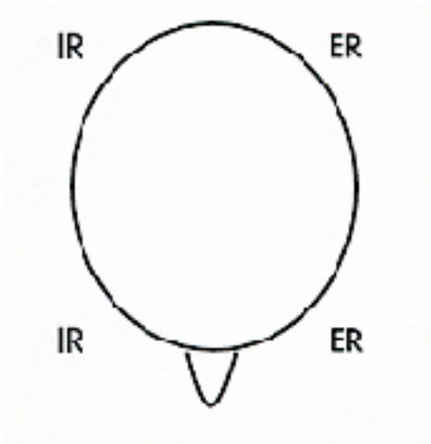

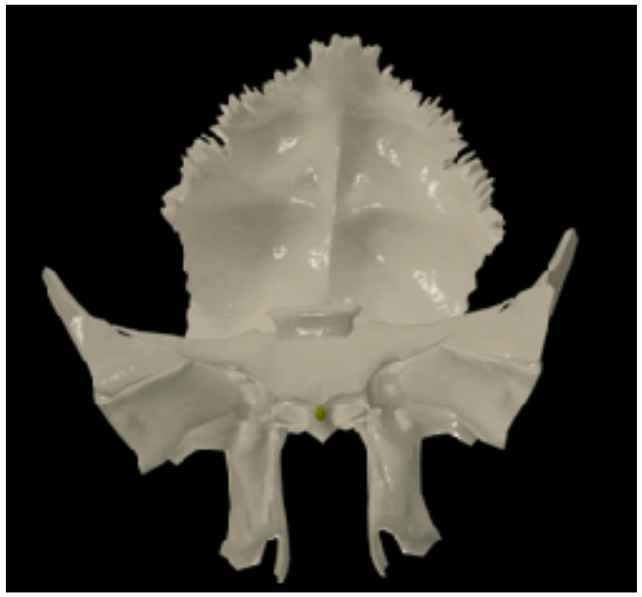

diagrams © James/Strokon Seminars.Used with permission.

Torsion – LEFT



Torsion – LEFT

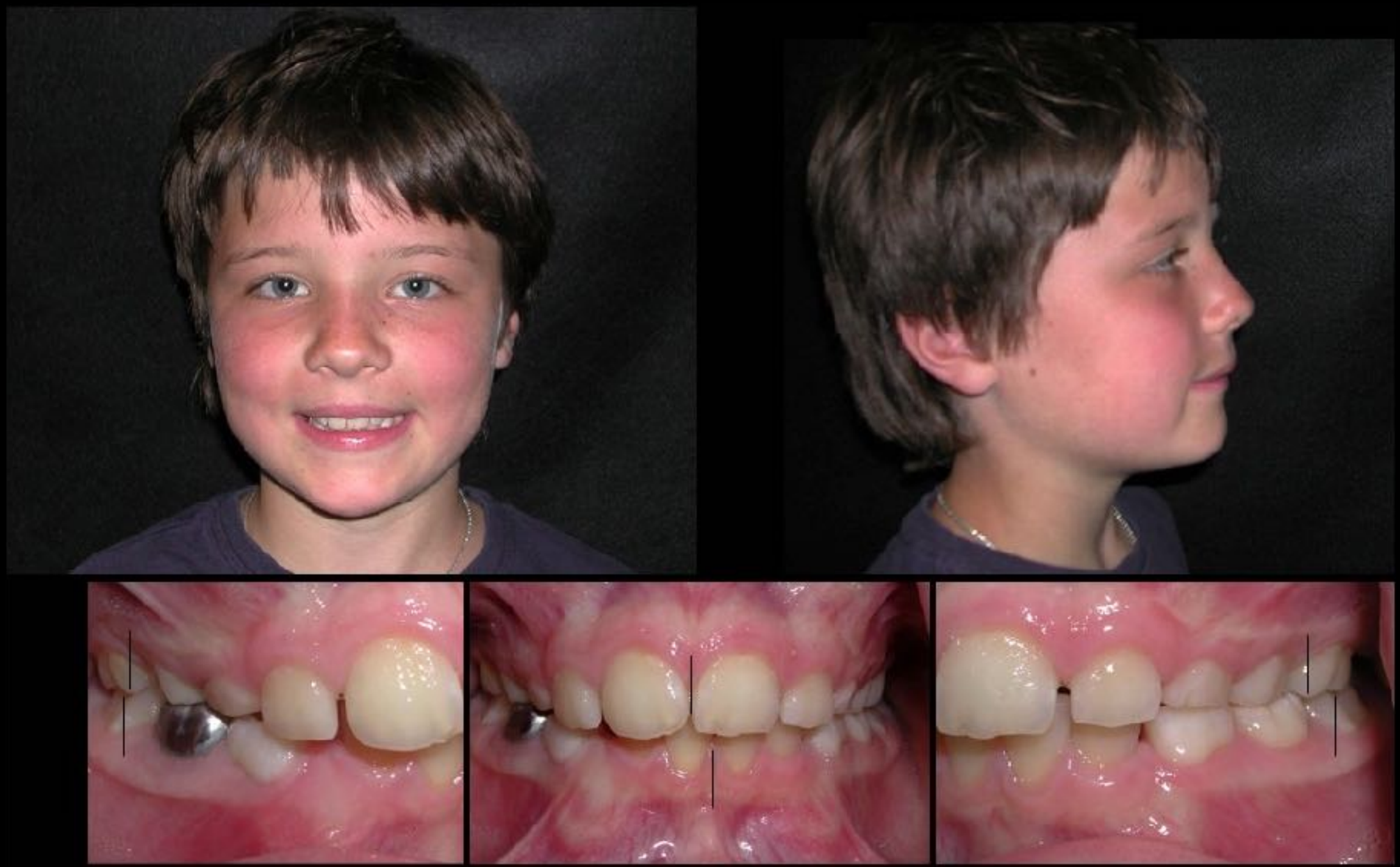

(reversed)



Torsion

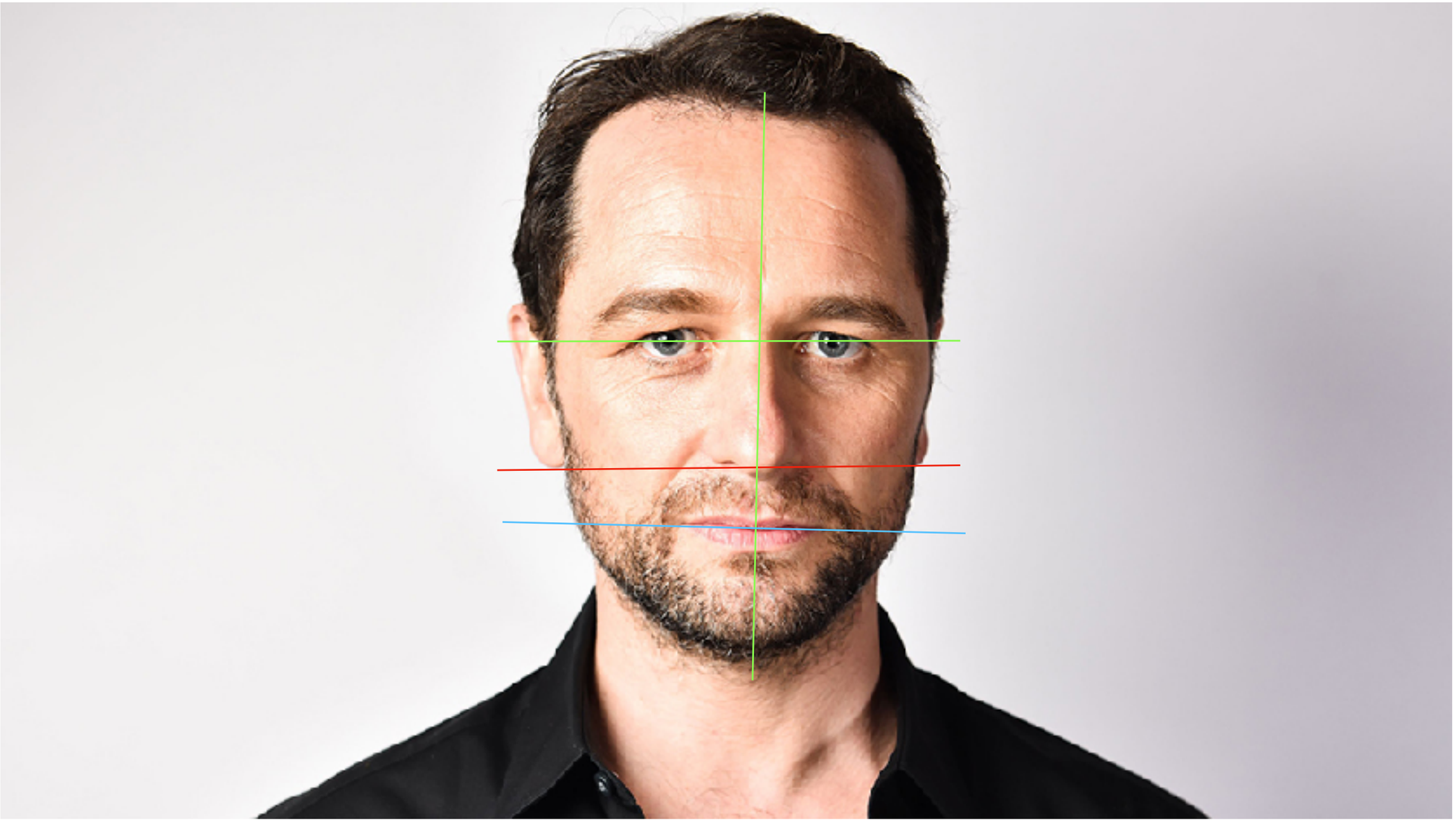

Side Bending/Rotation

Sidebending – Rotation Strain

- Occurs around an AP axis & around 2 parallel vertical axes: one through the body of the sphenoid & one through the foramen magnum, perpendicular to the physiologic transverse axes & the A-P axis
- As the SBS sidebends, it also rotates inferiorly to the convex sidebending side (coupled motion)
- Named for the convex side of sidebending

Lt Sidebending – Rotation Strain

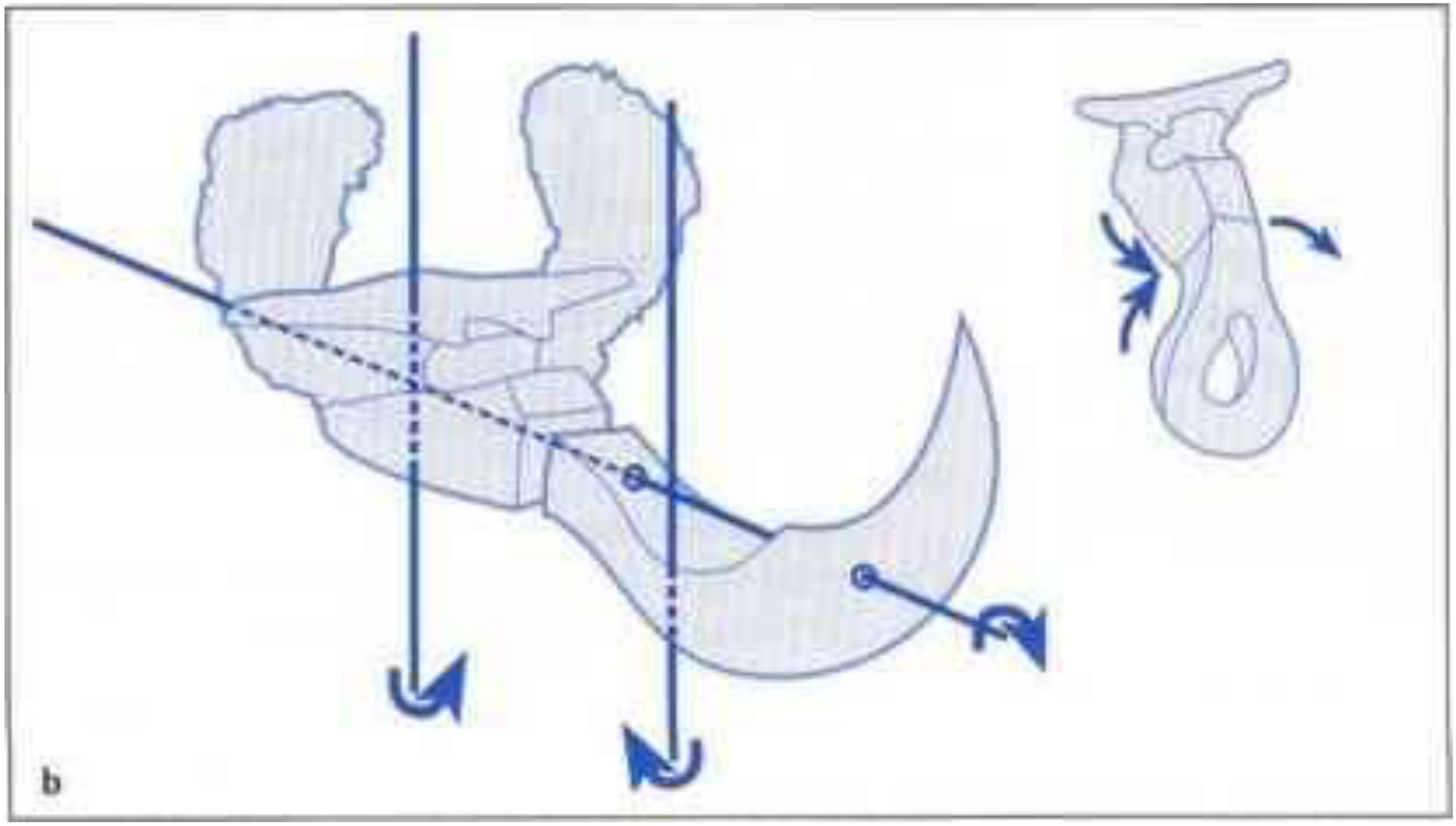

b

Right Sidebending Rotation

- **Findings-** 1 side of face full and convex with the opposite side flattened (side of the lower greater wing of the sphenoid)
- **Sphenoid-**
  - Side of low greater wing in internal rotation
    - Lateral fontal angle posterior
    - Orbit narrower
    - Eyeball retruded
    - Frontozygomatic angle lessened
    - Zygomatic tuberosity prominent
    - Maxillary frontal process more sagittal
    - Maxillary palantine process more arched
- **Occiput**
    - Mastoid tip –posteromedial
    - Ear protruding

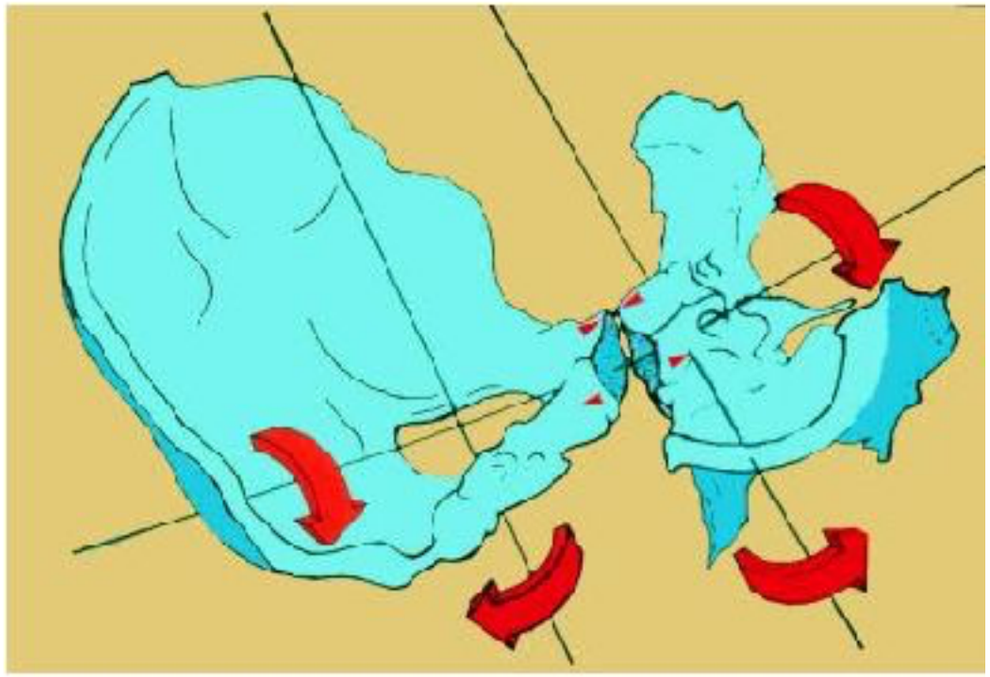

Sidebending/Rotation - Left

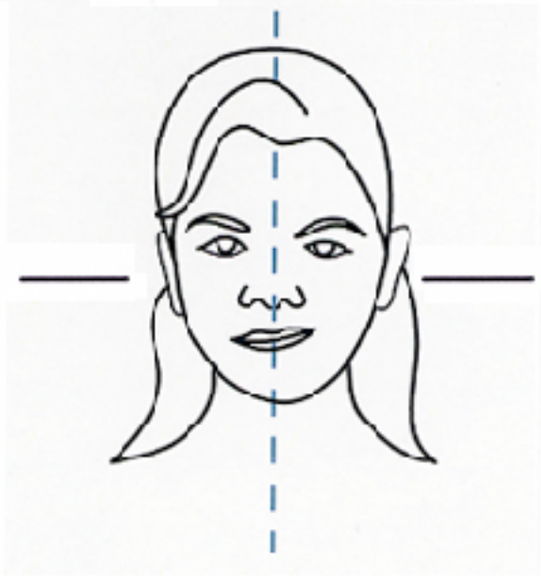

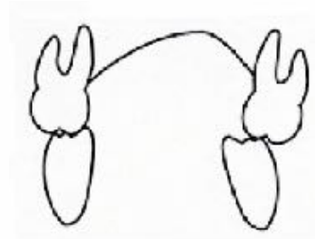

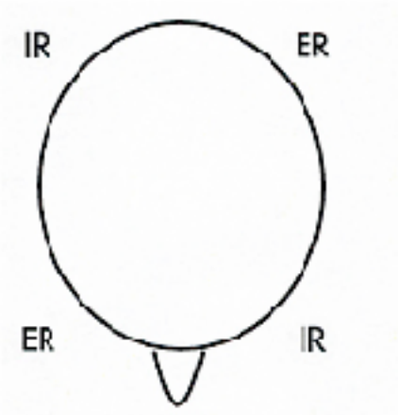

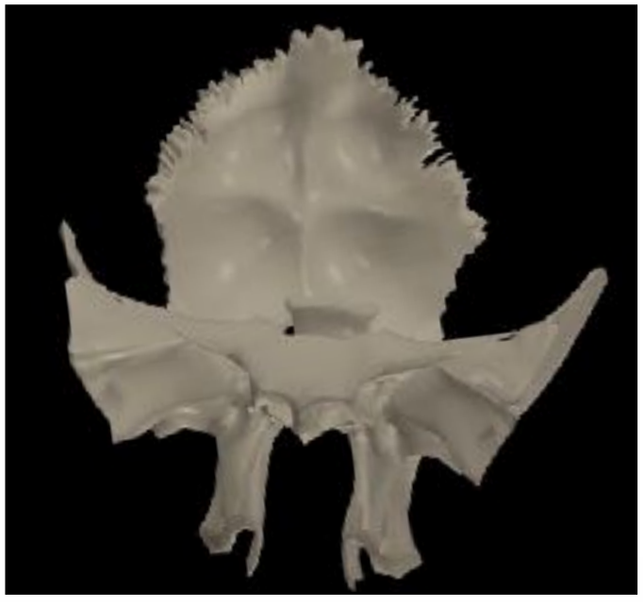

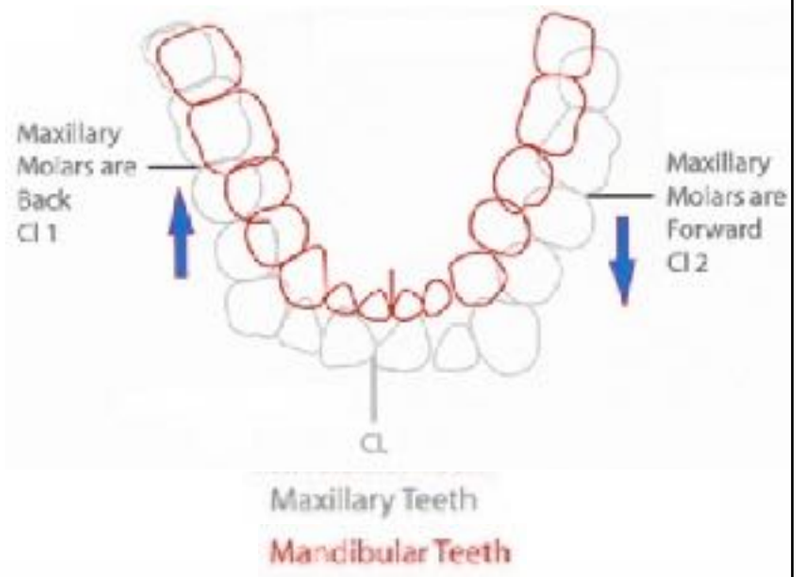

diagrams © James/Strokon Seminars.Used with permission.

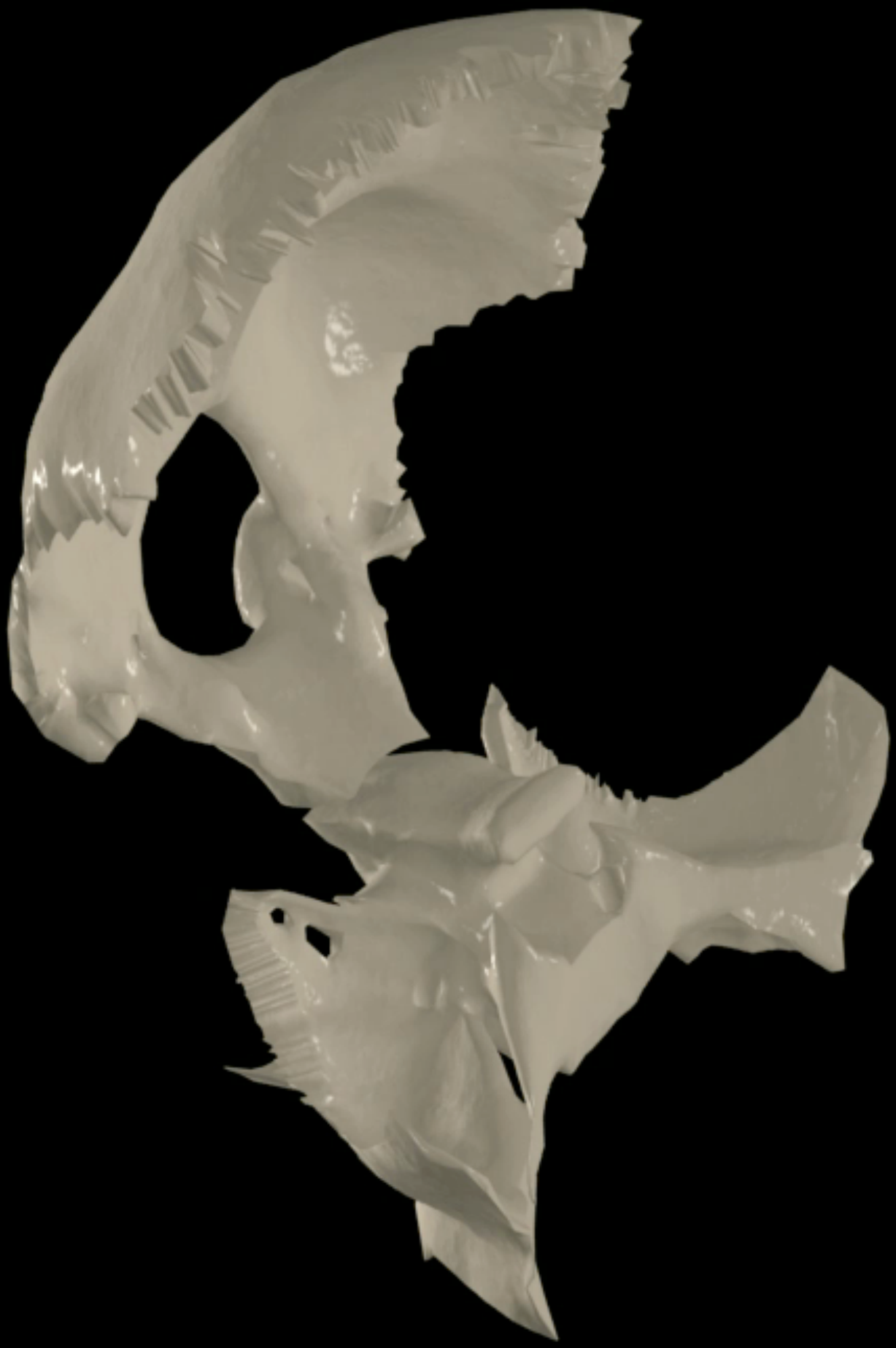

Left Sidebending/Rotation

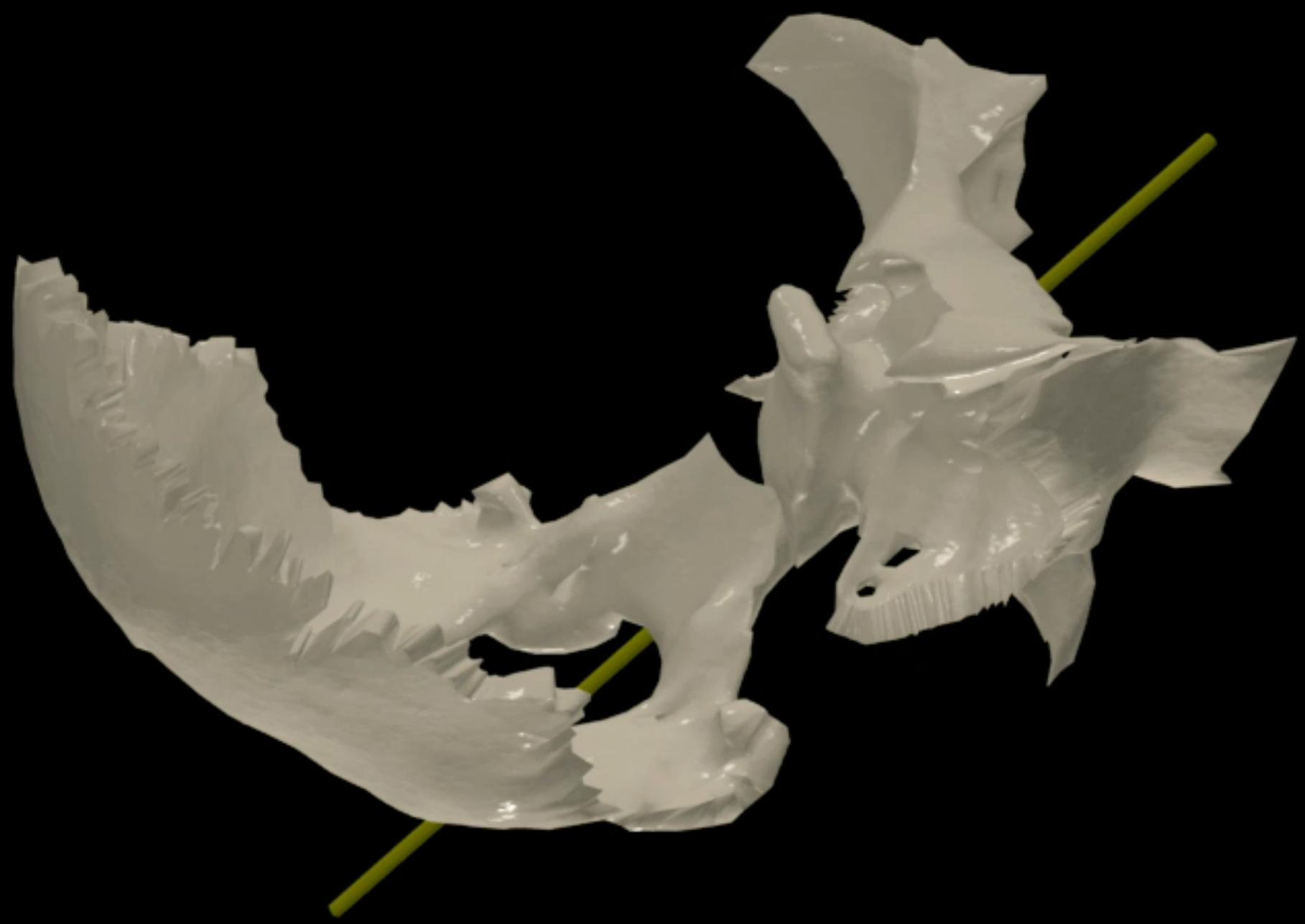

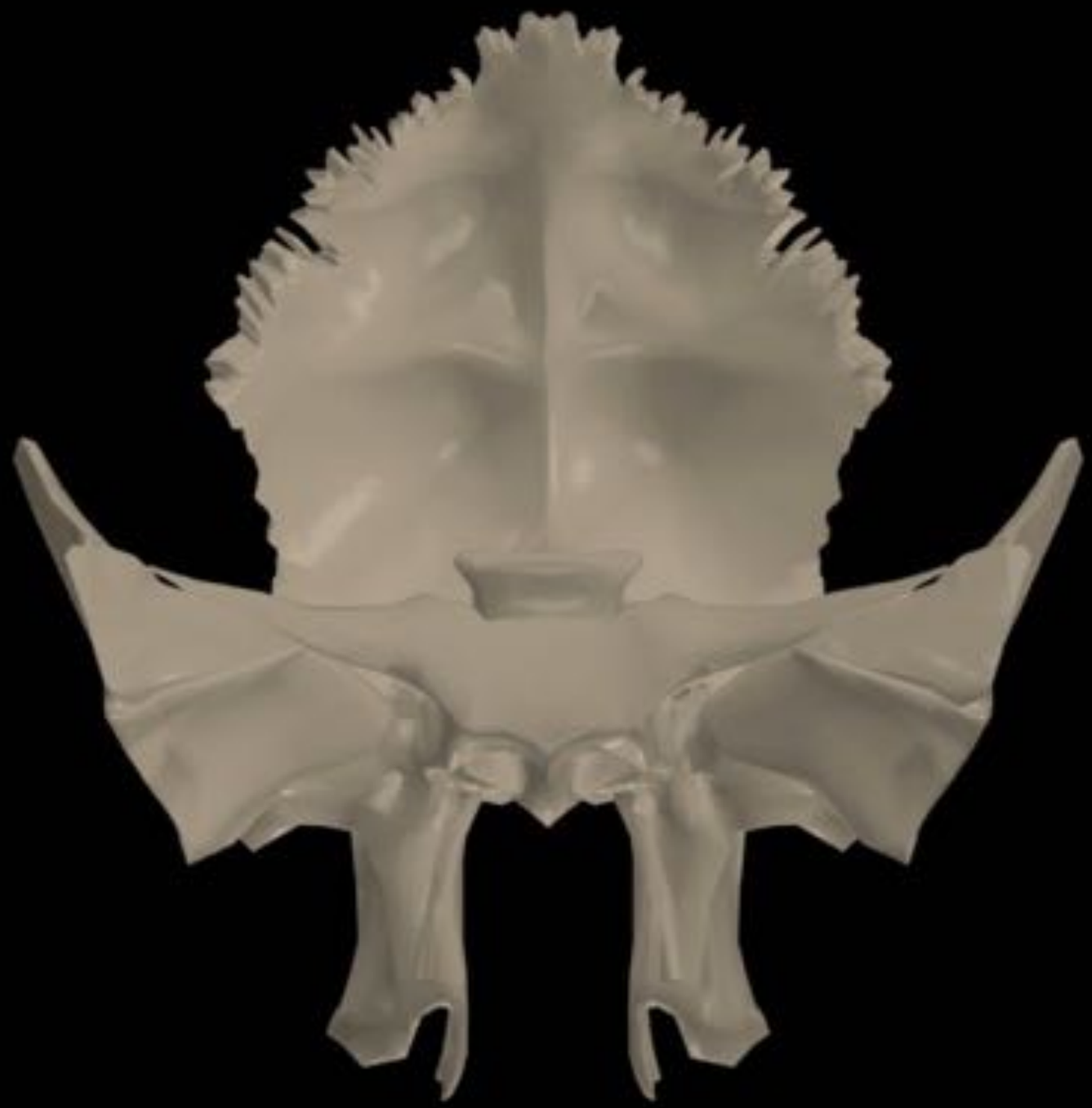

Left Sidebending/Rotation

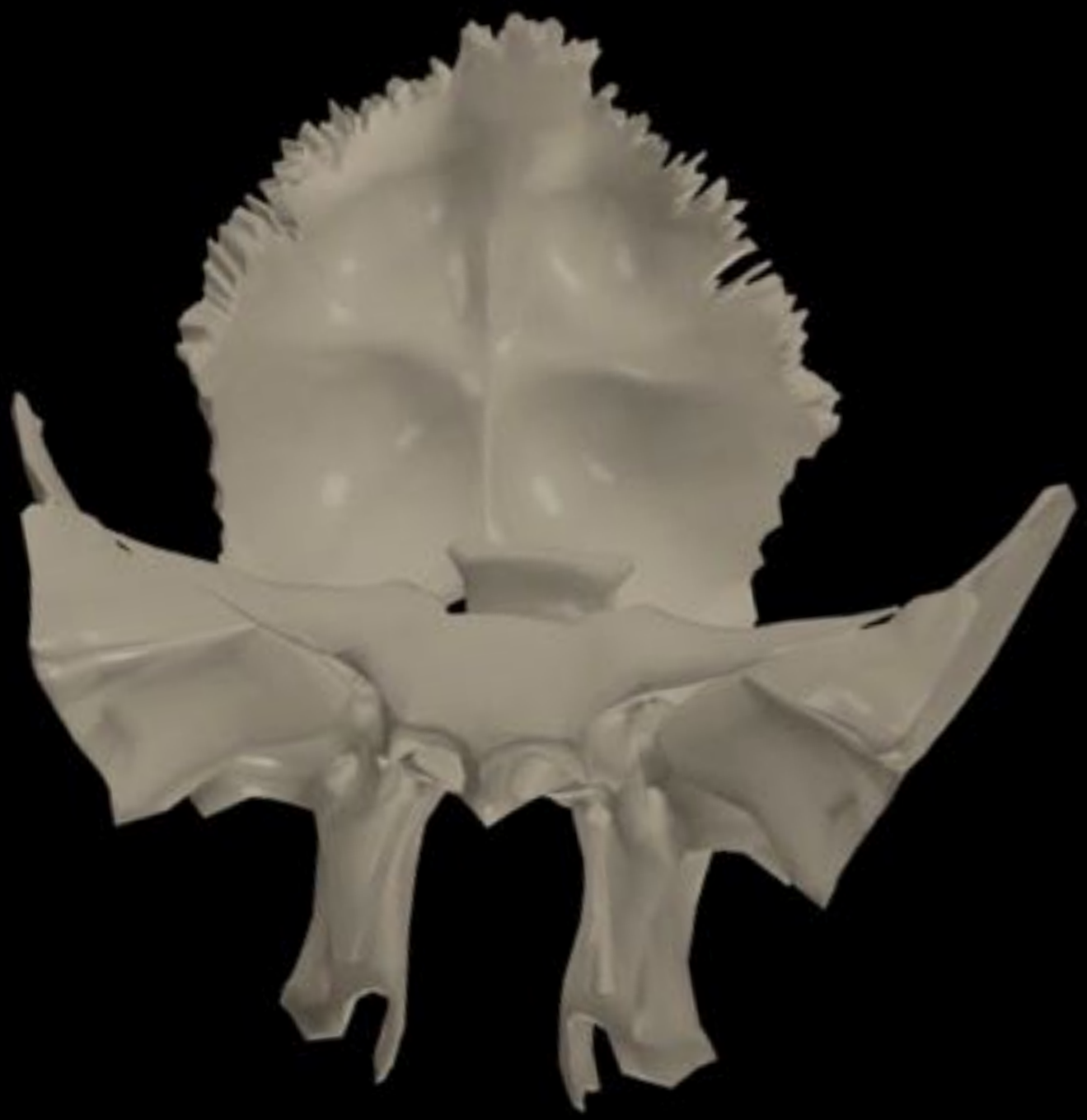

Sidebending/Rotation - Left

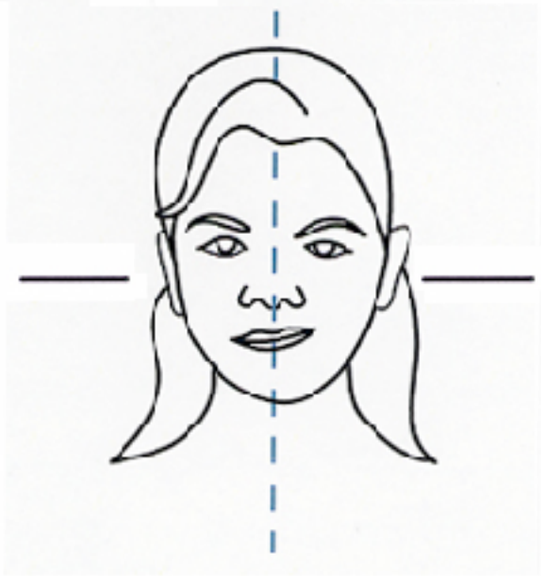

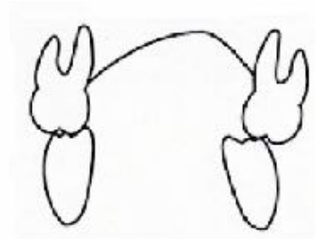

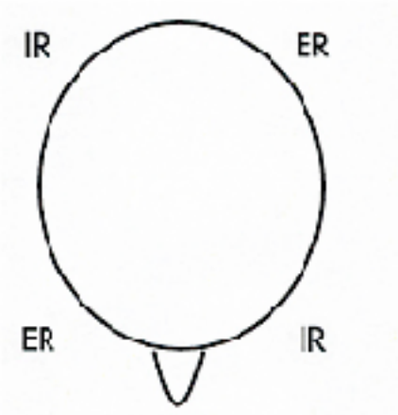

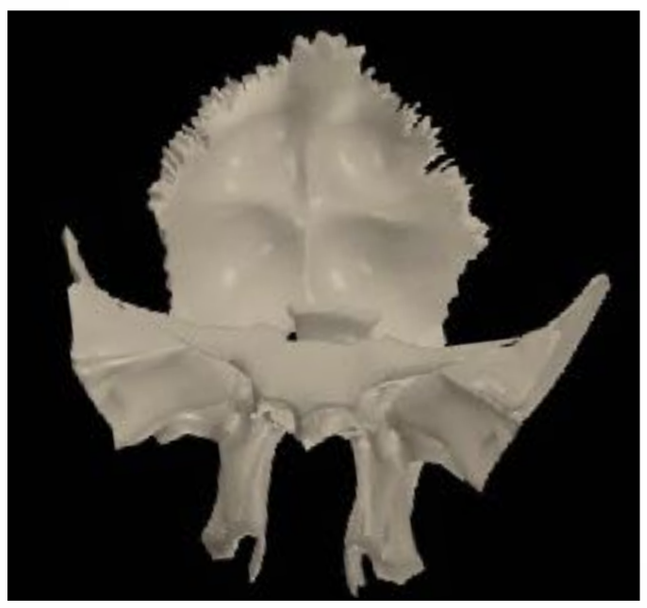

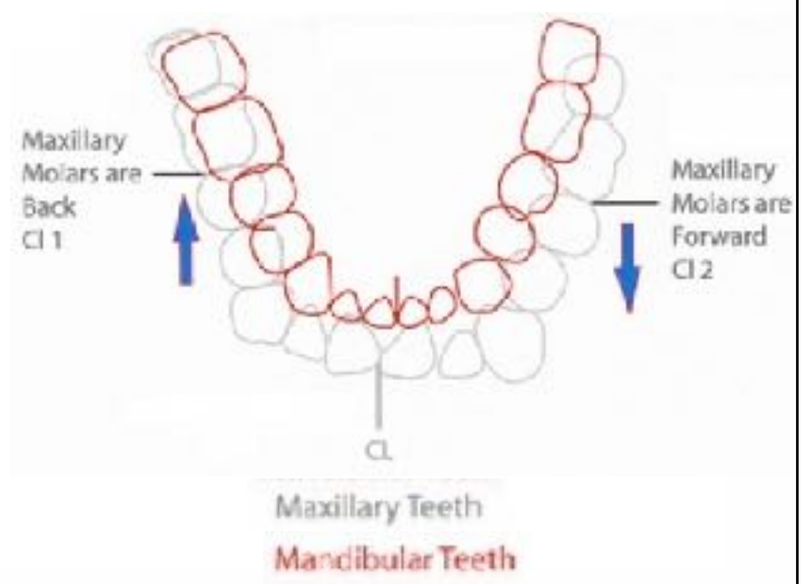

diagrams © James/Strokon Seminars.Used with permission.

Sidebending/Rotation - Right

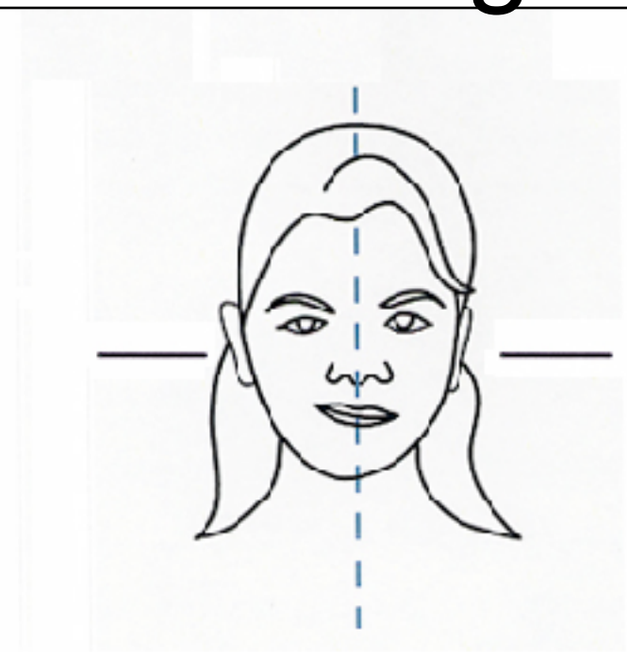

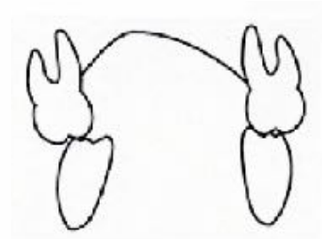

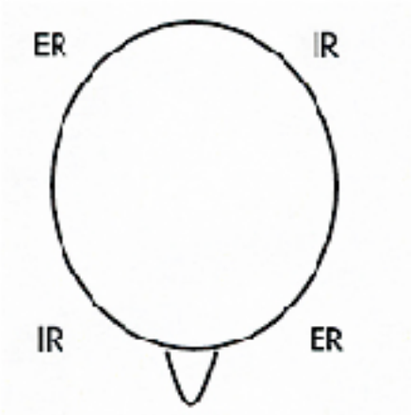

diagrams © James/Strokon Seminars.Used with permission.

Sidebending/Rotation - Left

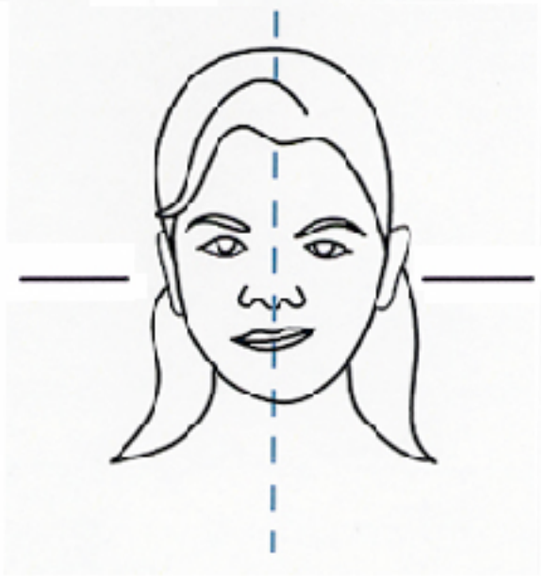

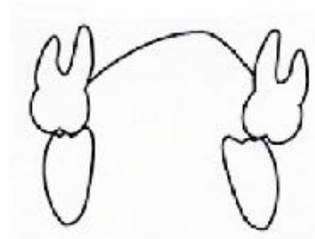

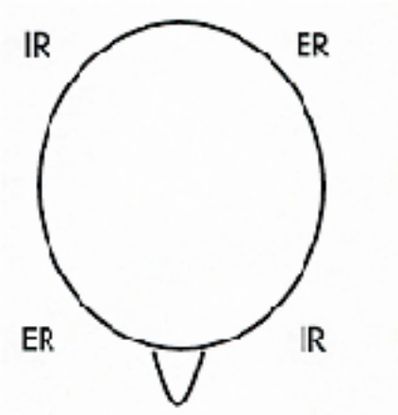

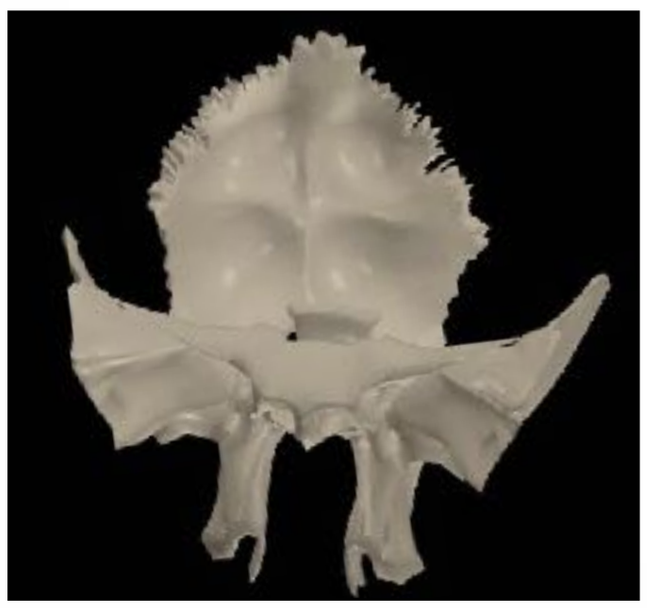

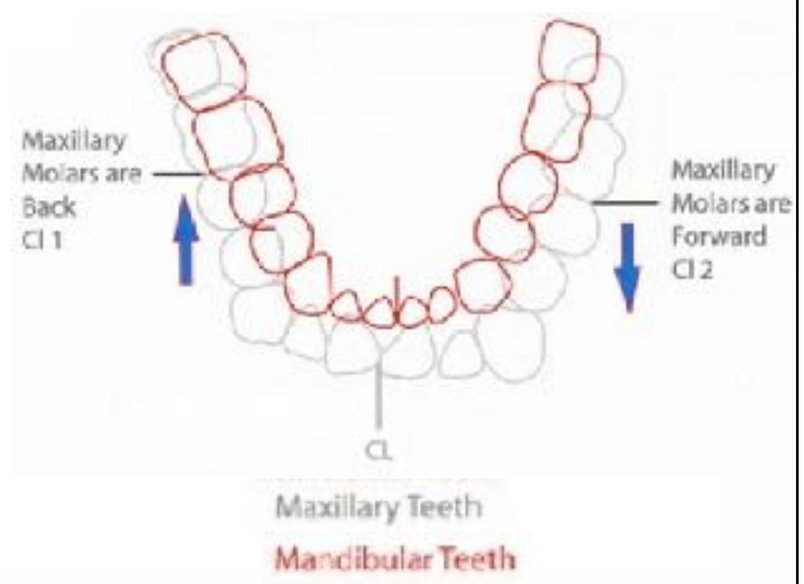

diagrams © James/Strokon Seminars.Used with permission.

Sidebending/Rotation – LEFT

Sidebending/Rotation – LEFT

Sidebending/Rotation - Right

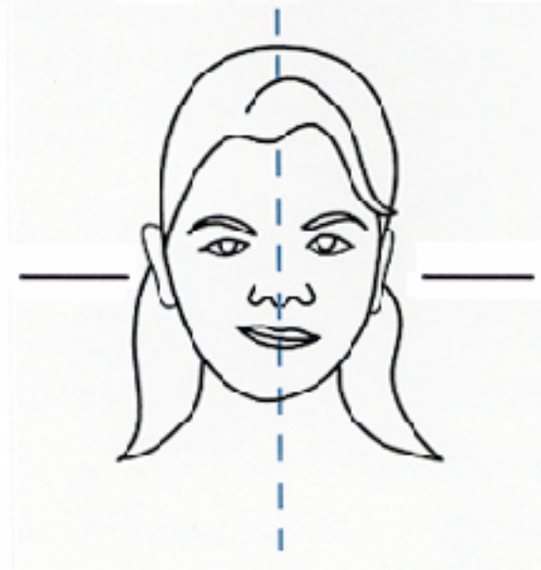

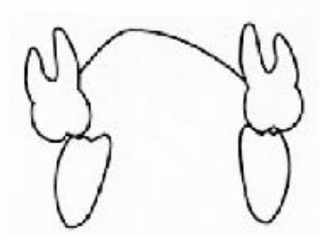

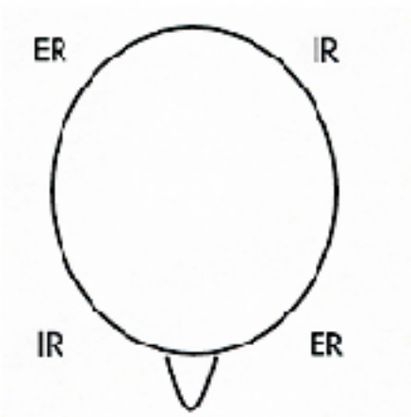

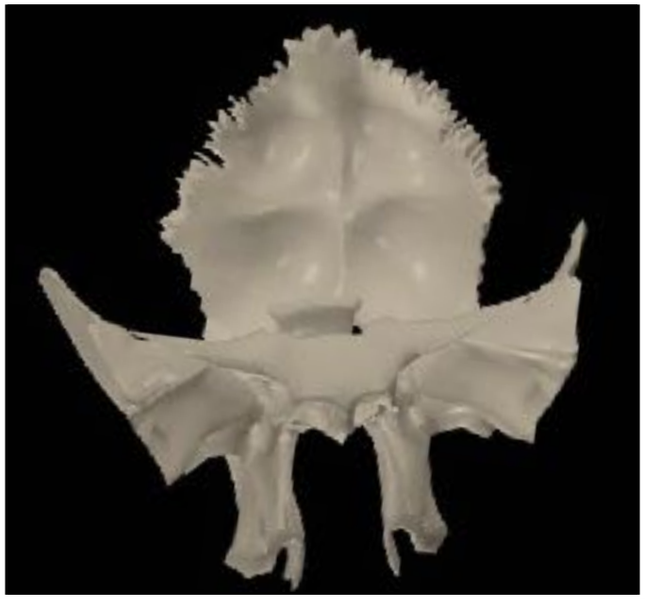

diagrams © James/Strokon Seminars.Used with permission.

Sidebending/Rotation – Right

(reversed image)

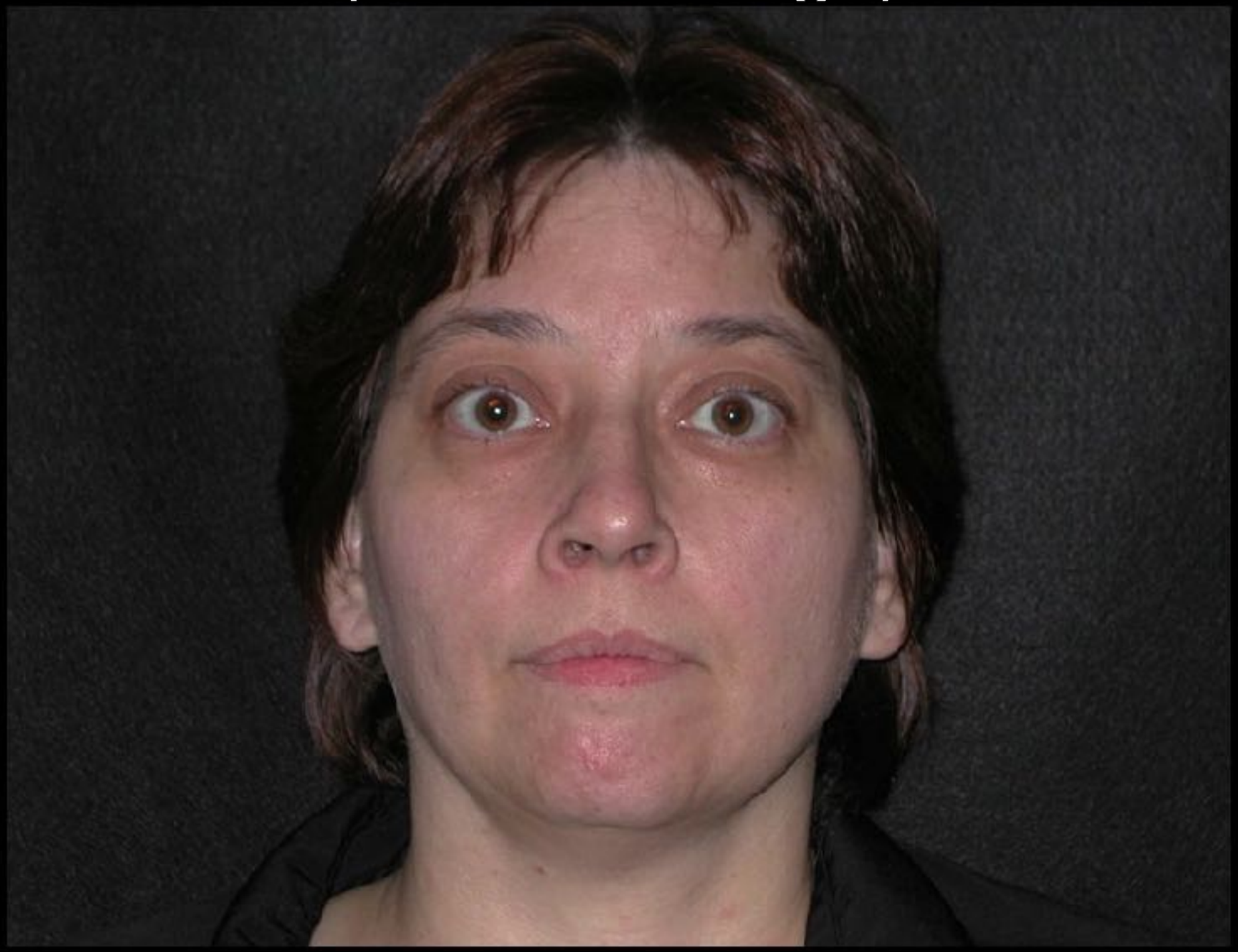

Sidebending/Rotation – Right

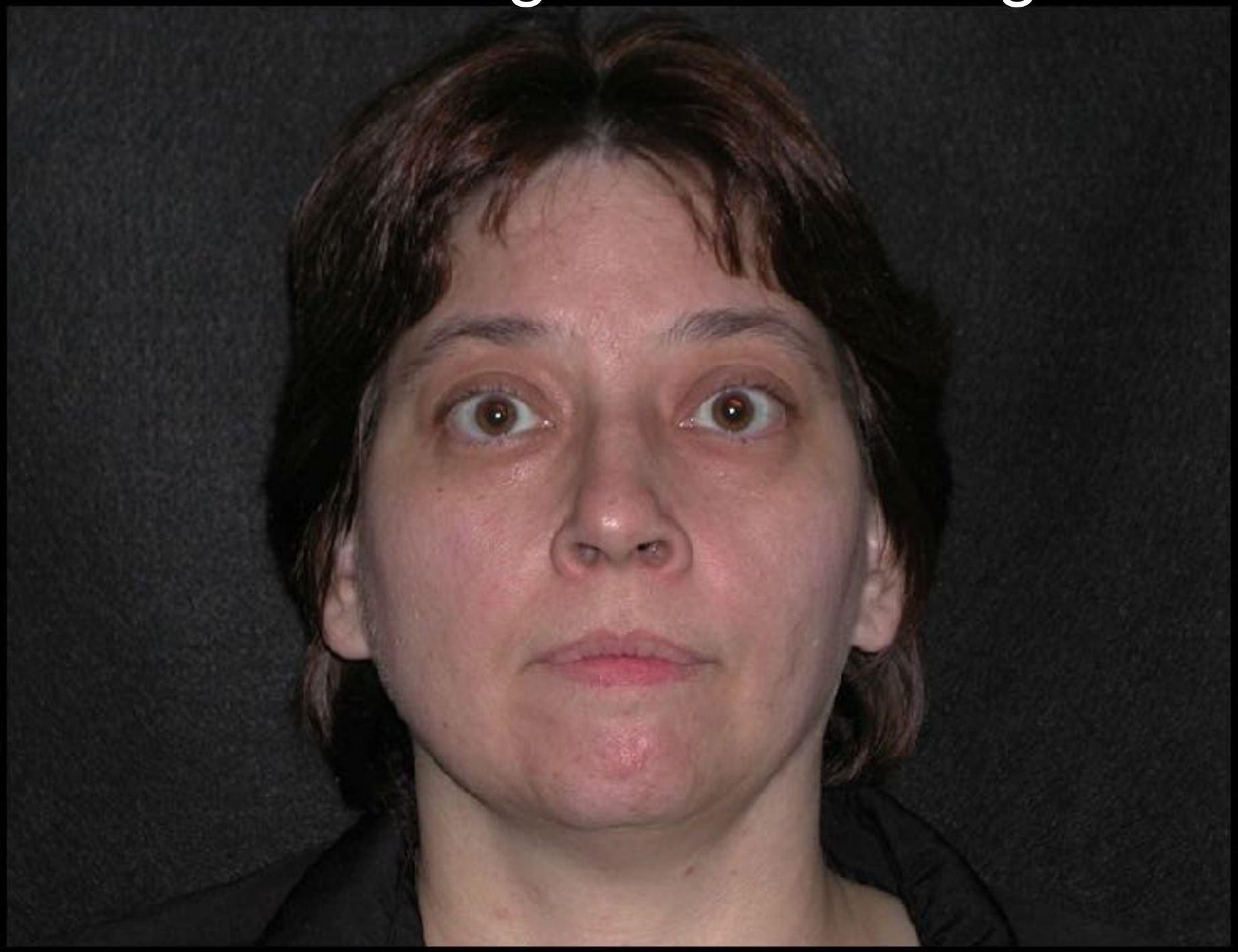

Sidebending/Rotation – Right

Sidebending/Rotation – Right

Sidebending/Rotation – Right

Side Bending / Rotation





Vertical Strain

Vertical Strain -Superior/Inferior

- Sphenoid and occiput have the same rotation about a transverse axis, resulting in a vertical strain pattern
- Named for the position of the base of the sphenoid, relative to the occiput at the SBS

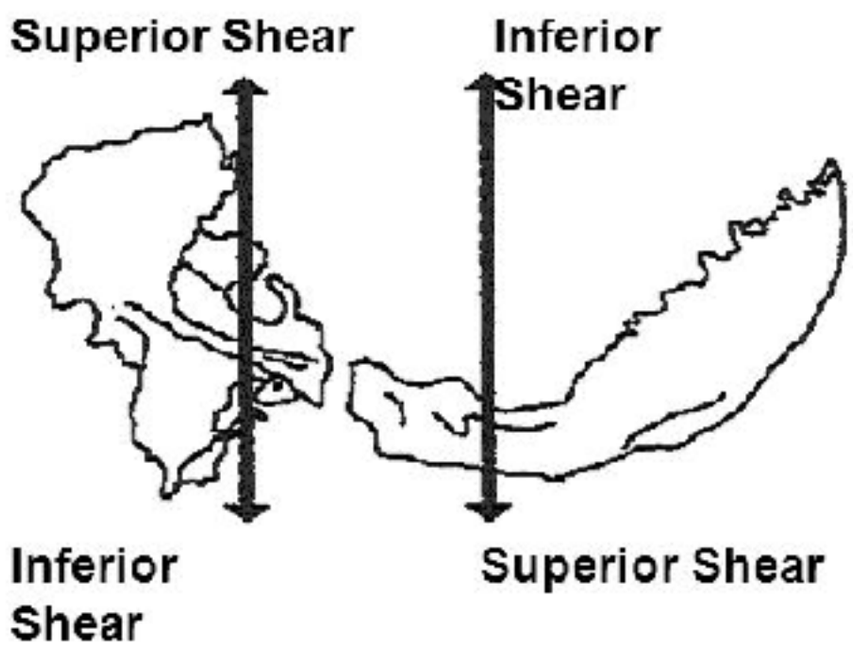

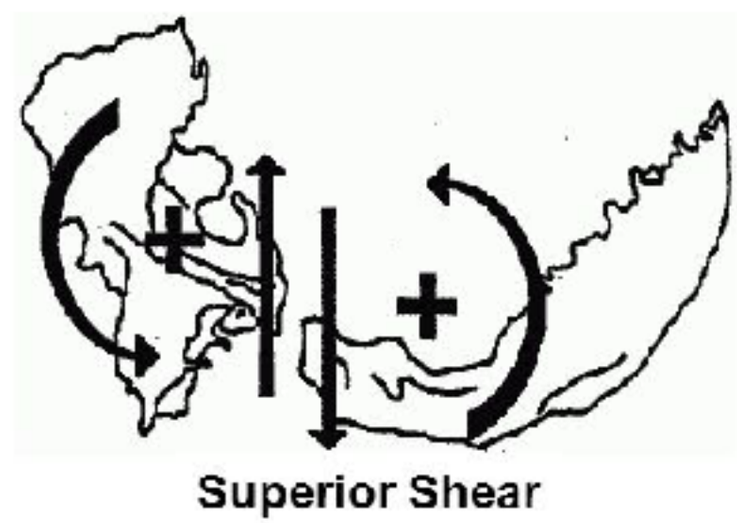

Inferior Vertical Strain

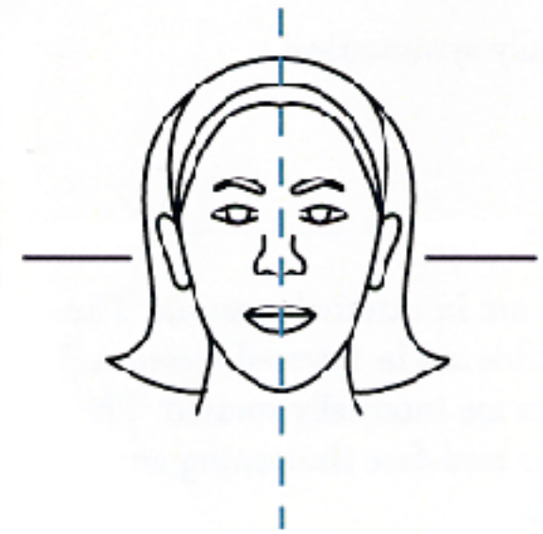

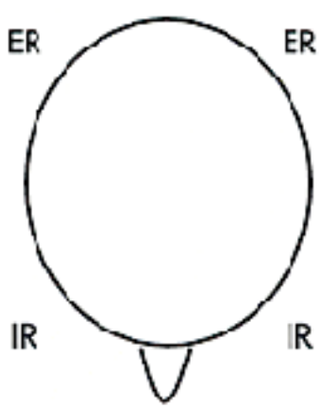

diagrams © James/Strokon Seminars.Used with permission.

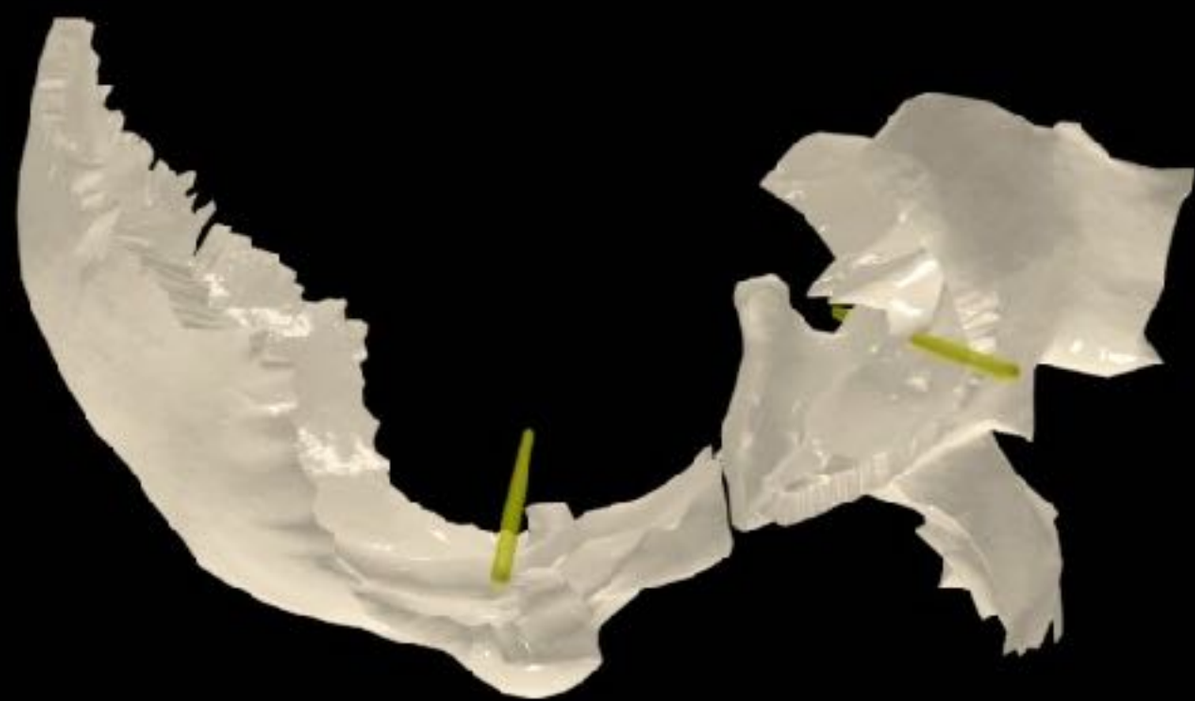

The Cranial Academy

INFERIOR VERTICAL STRAIN

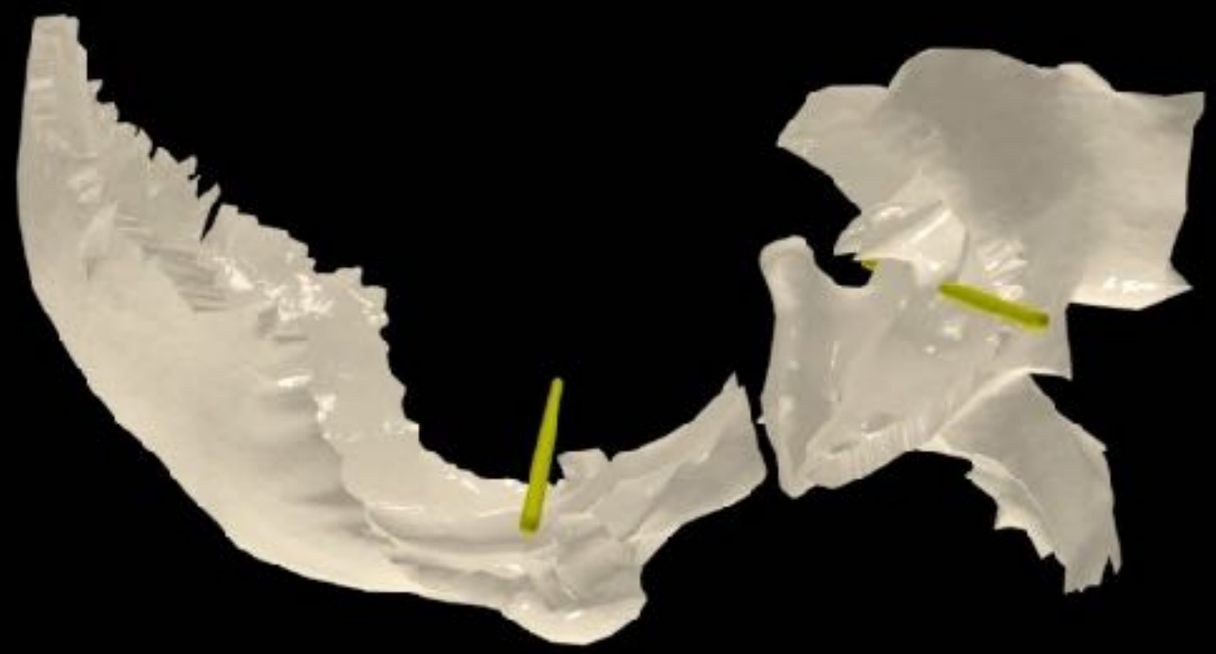

The Cranial Academy

Inferior Vertical Strain

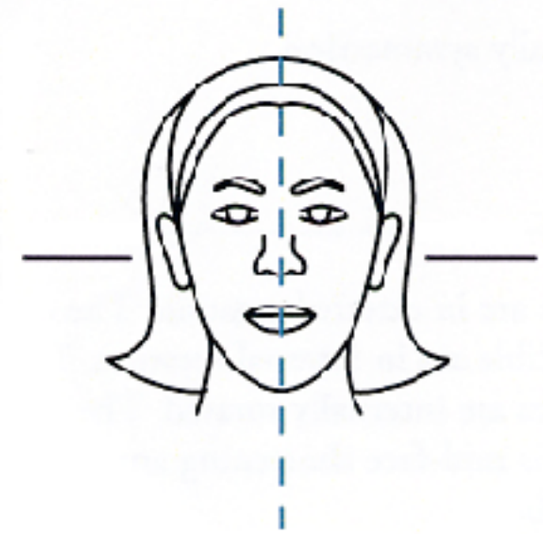

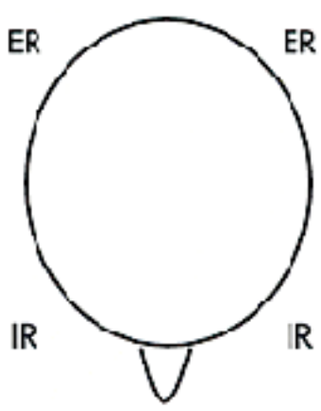

diagrams © James/Strokon Seminars.Used with permission.

Inferior Vertical Strain

(flipped)

Inferior Vertical Strain

Inferior Vertical Strain

Inferior Vertical Strain

Inferior Vertical Strain

Superior Vertical Strain

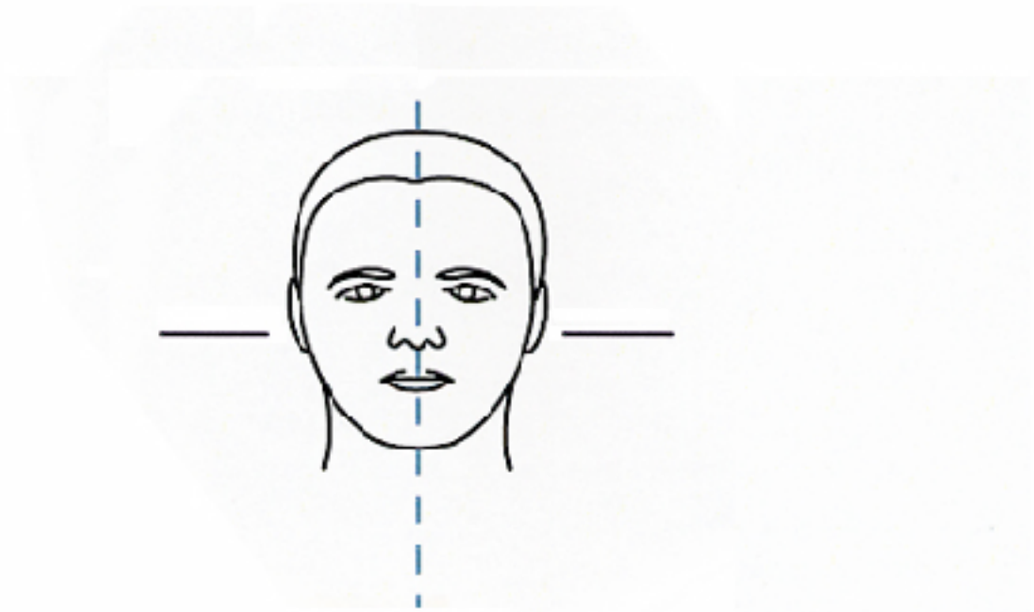



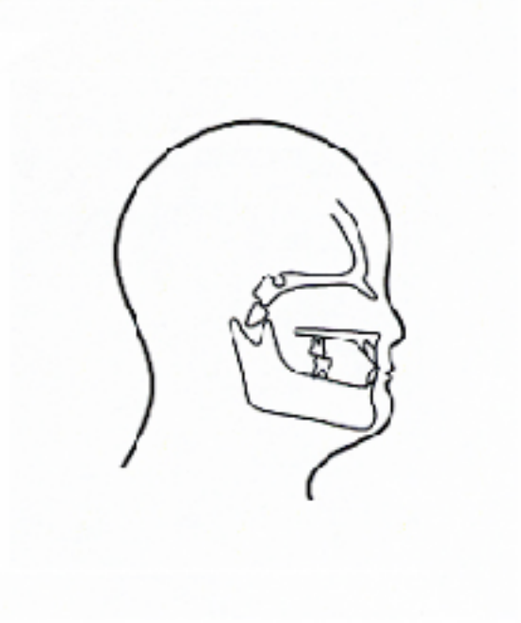

diagrams © James/Strokon Seminars.Used with permission.

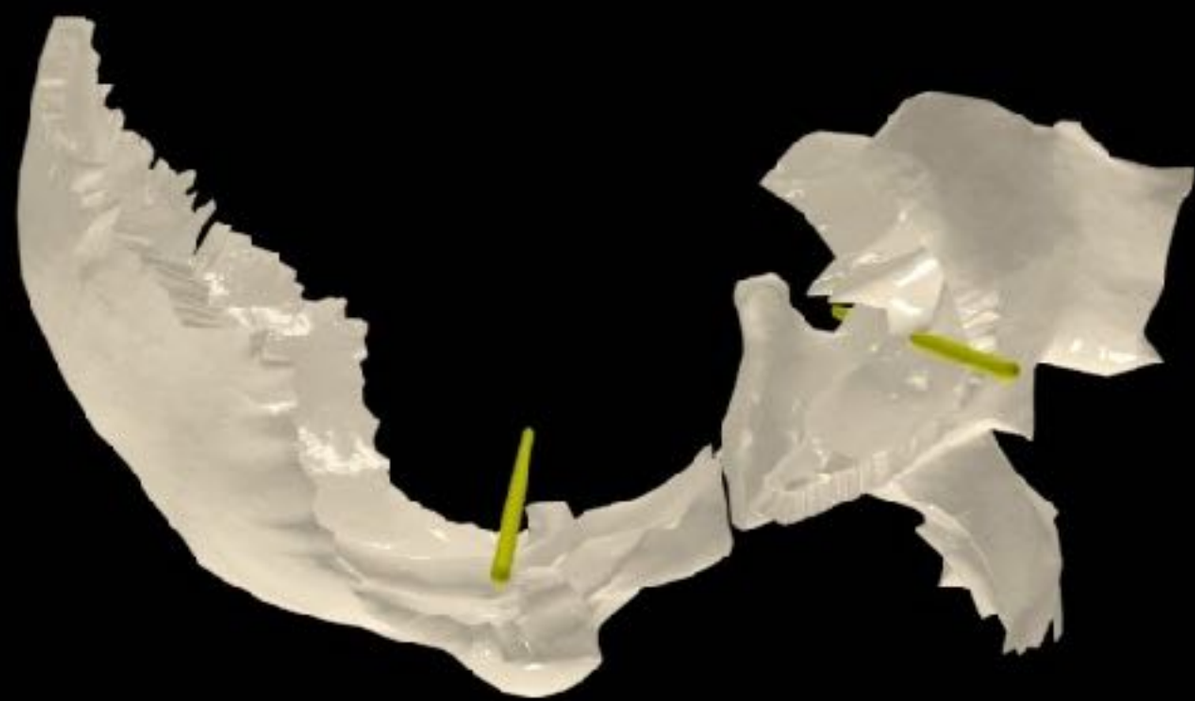

The Cranial Academy

SUPERIOR VERTICAL STRAIN

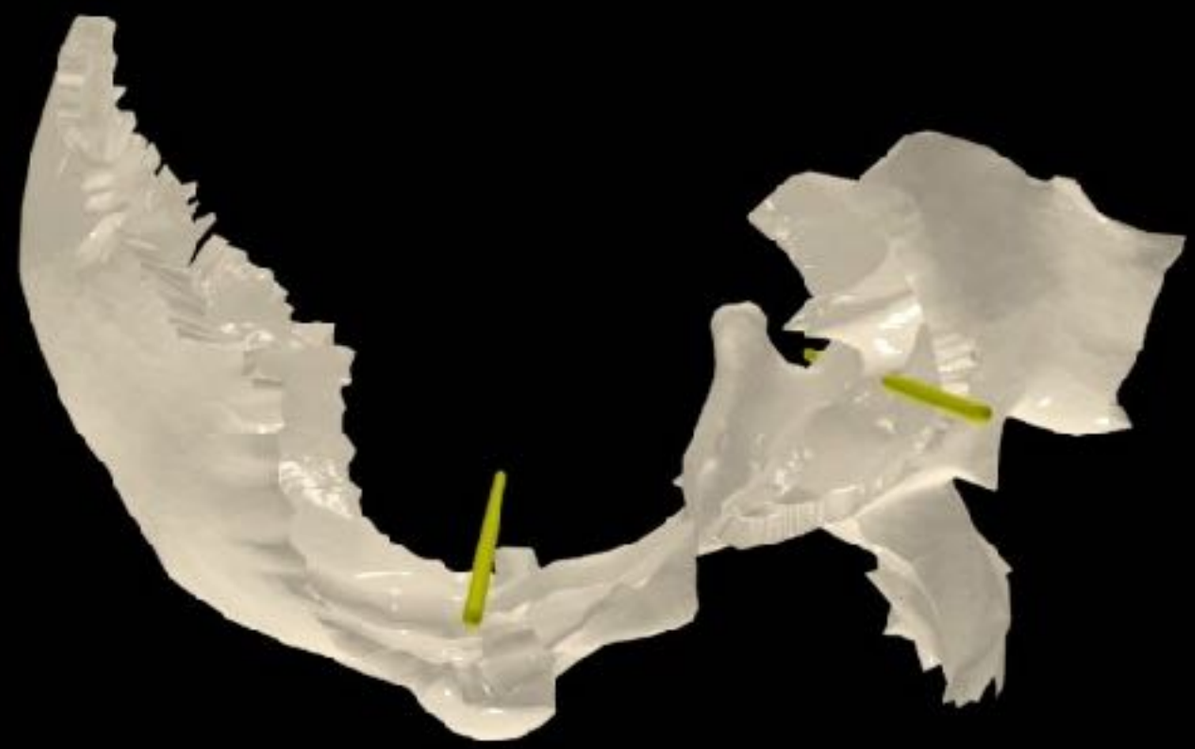

The Cranial Academy

Superior Vertical Strain

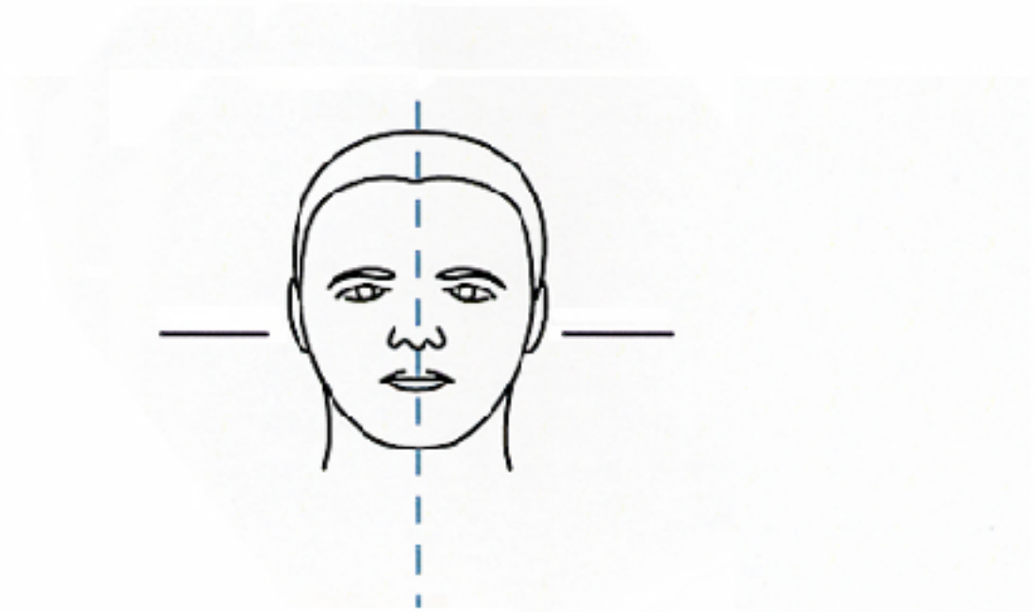



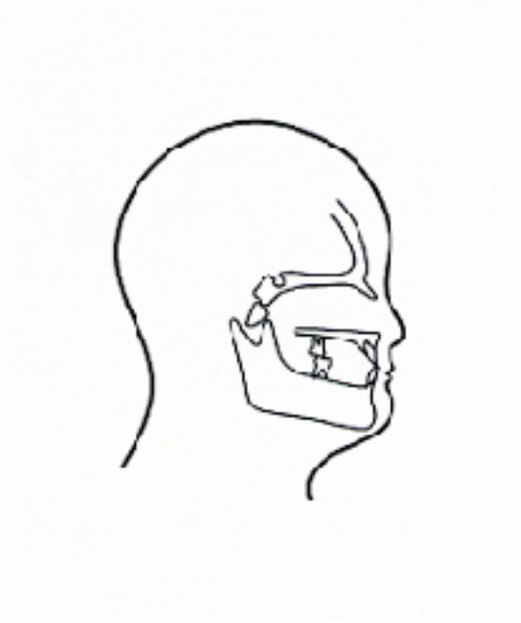

diagrams © James/Strokon Seminars.Used with permission.

Inferior Vertical Strain

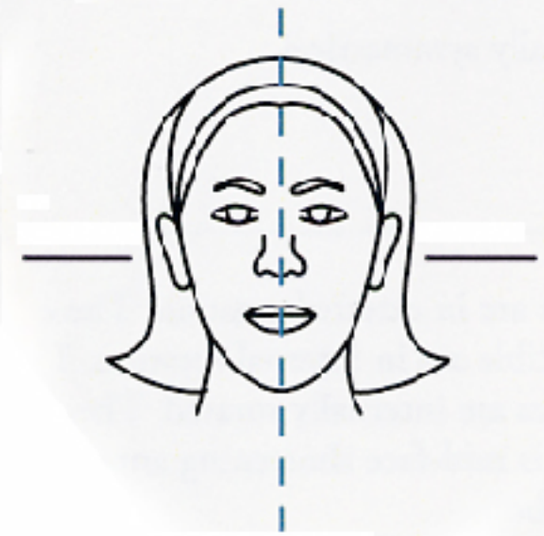

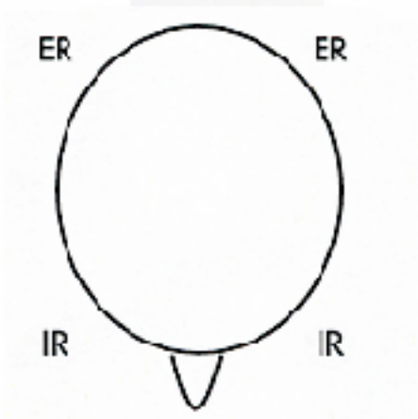

Superior Vertical Strain

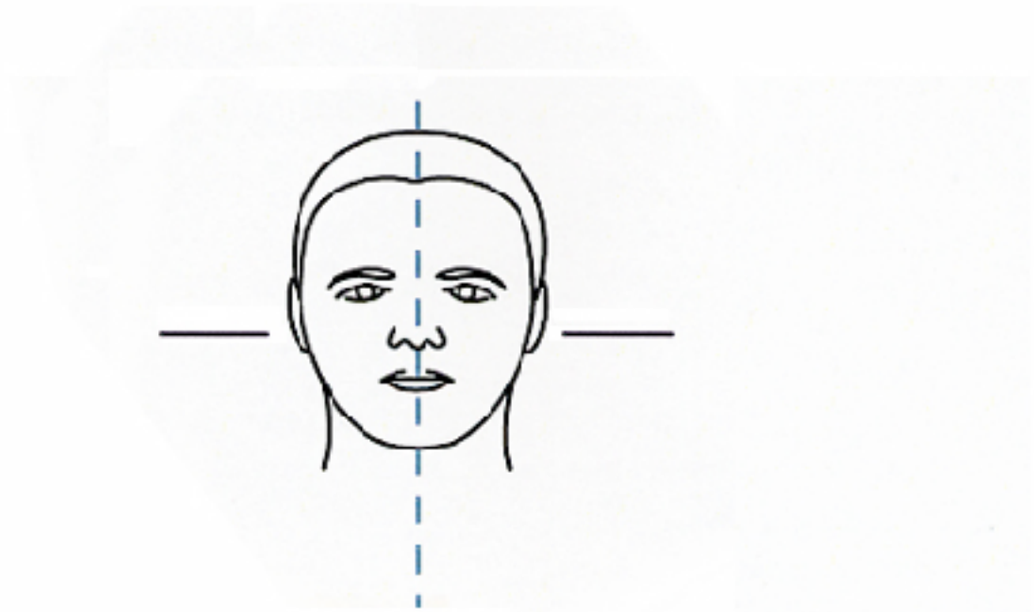



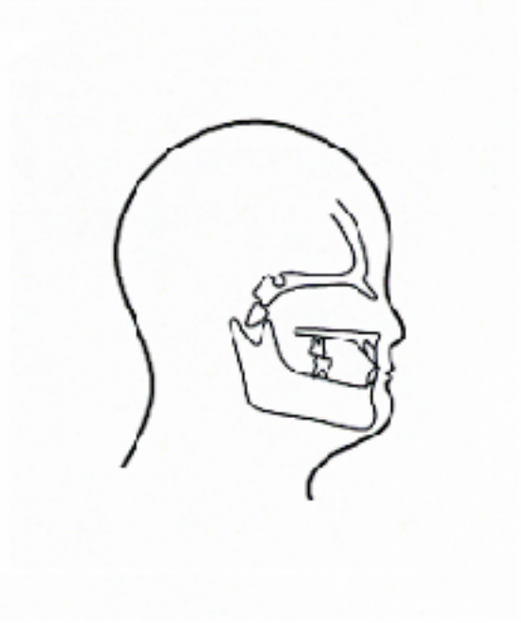

Superior Vertical Strain

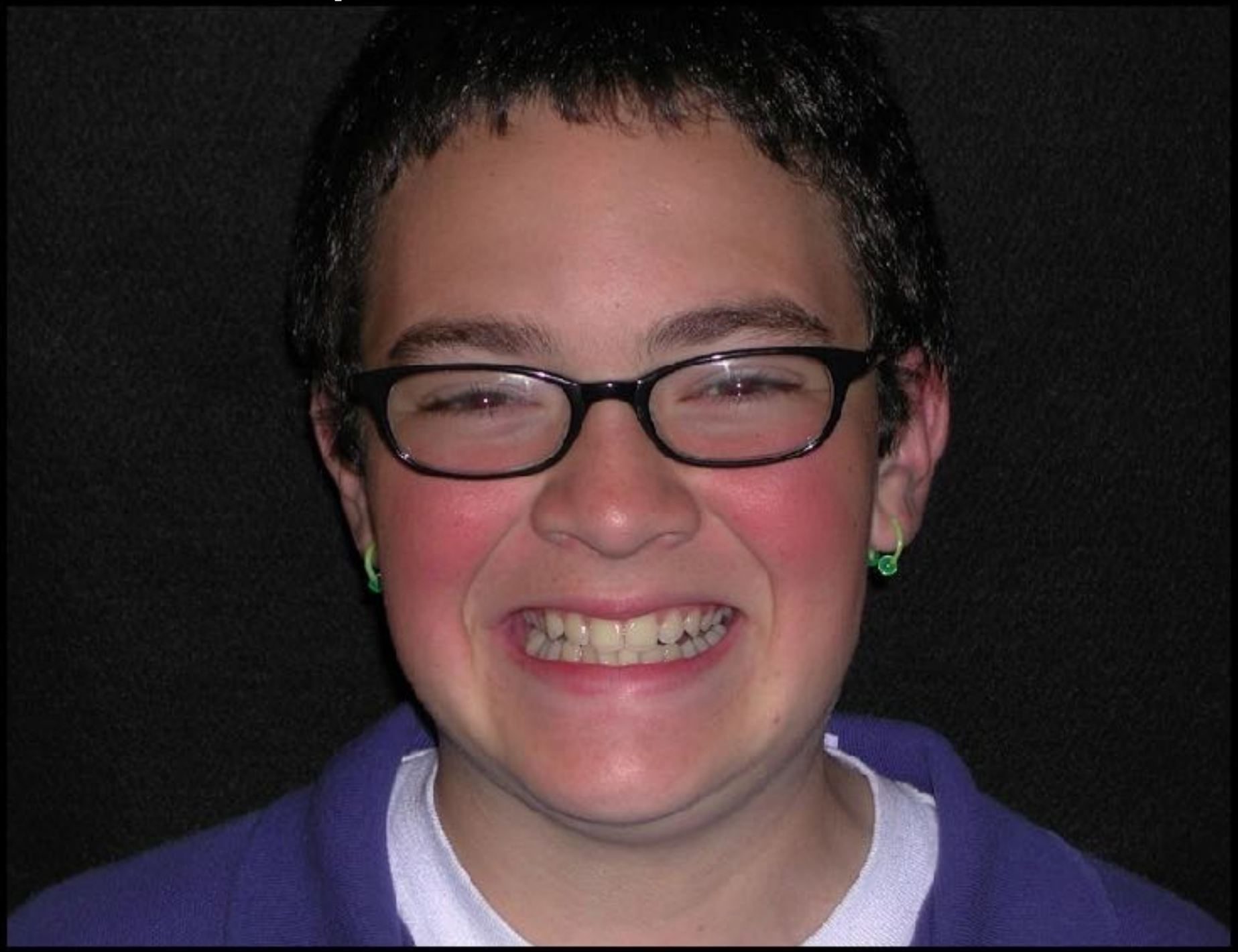

Superior Vertical Strain

Inferior Vertical Strain

Superior Vertical Strain

Vertical Strain

Lateral Strain

Cranial and Dental Occlusal Habitus III

LATERAL STRAIN

- Bilateral vertical axes
- Shearing force at SBS causing Sphenoid and Occiput to rotate same direction on axes
- Named for position of basisphenoid
- **Head appears "parallelogram"**

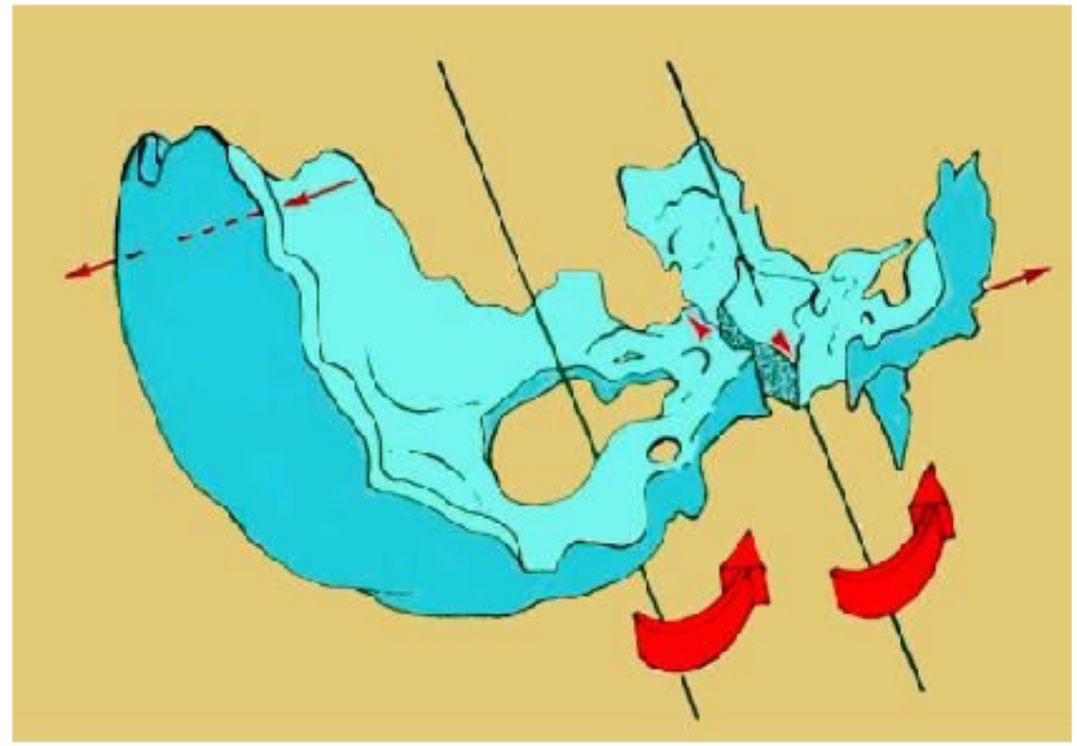

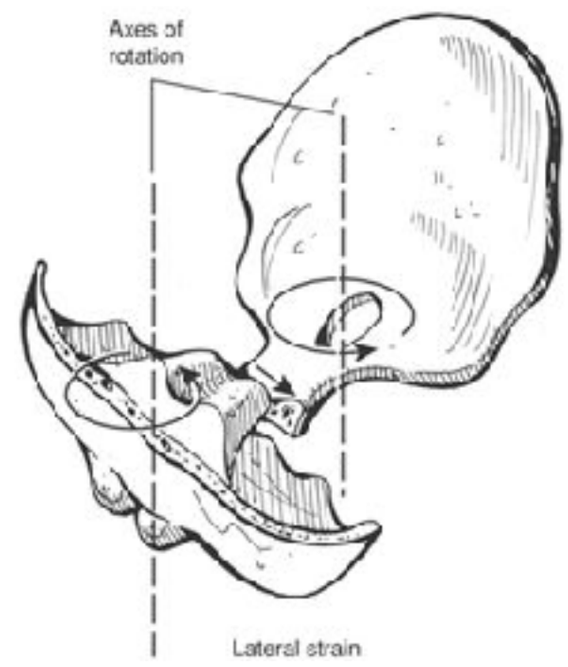

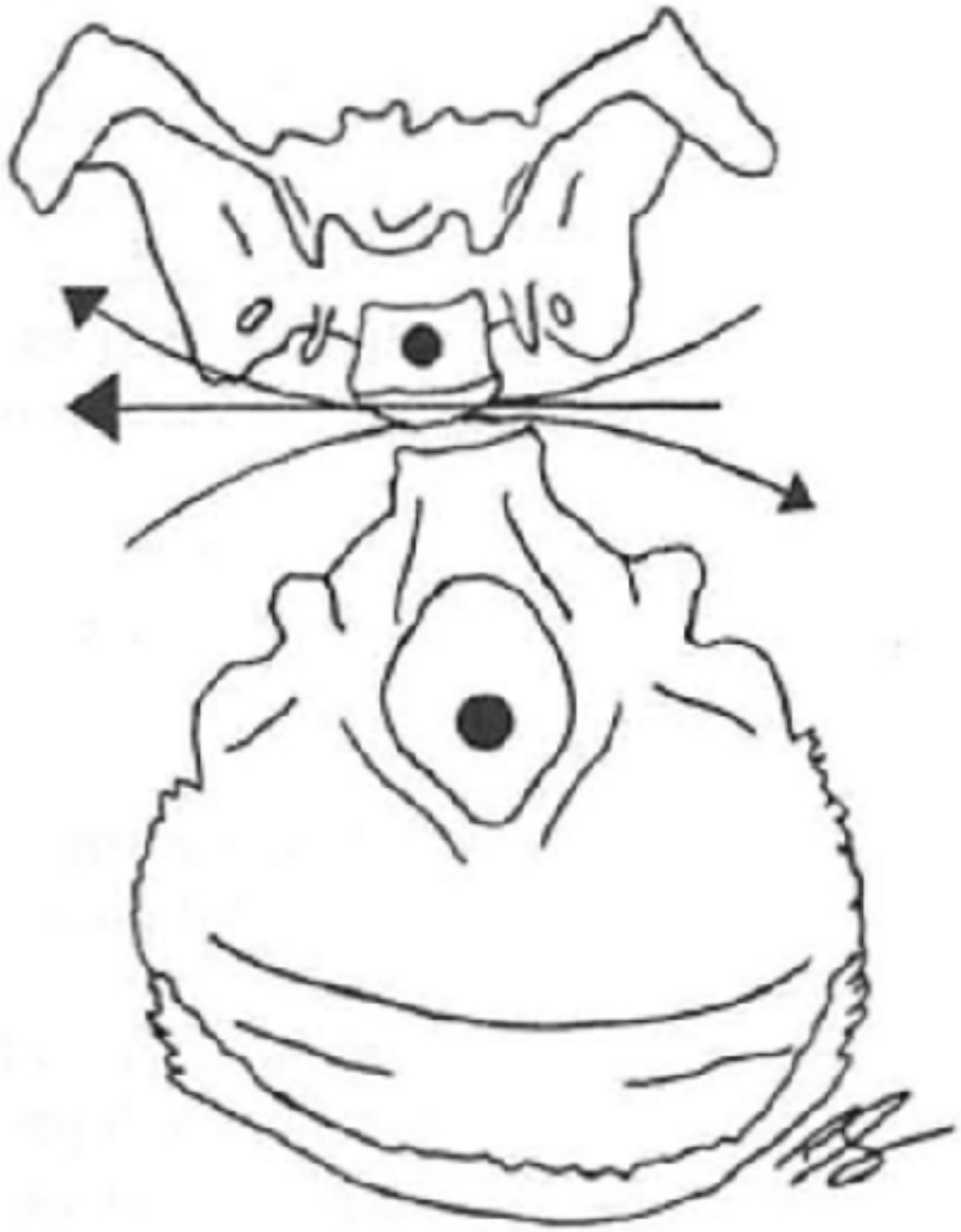

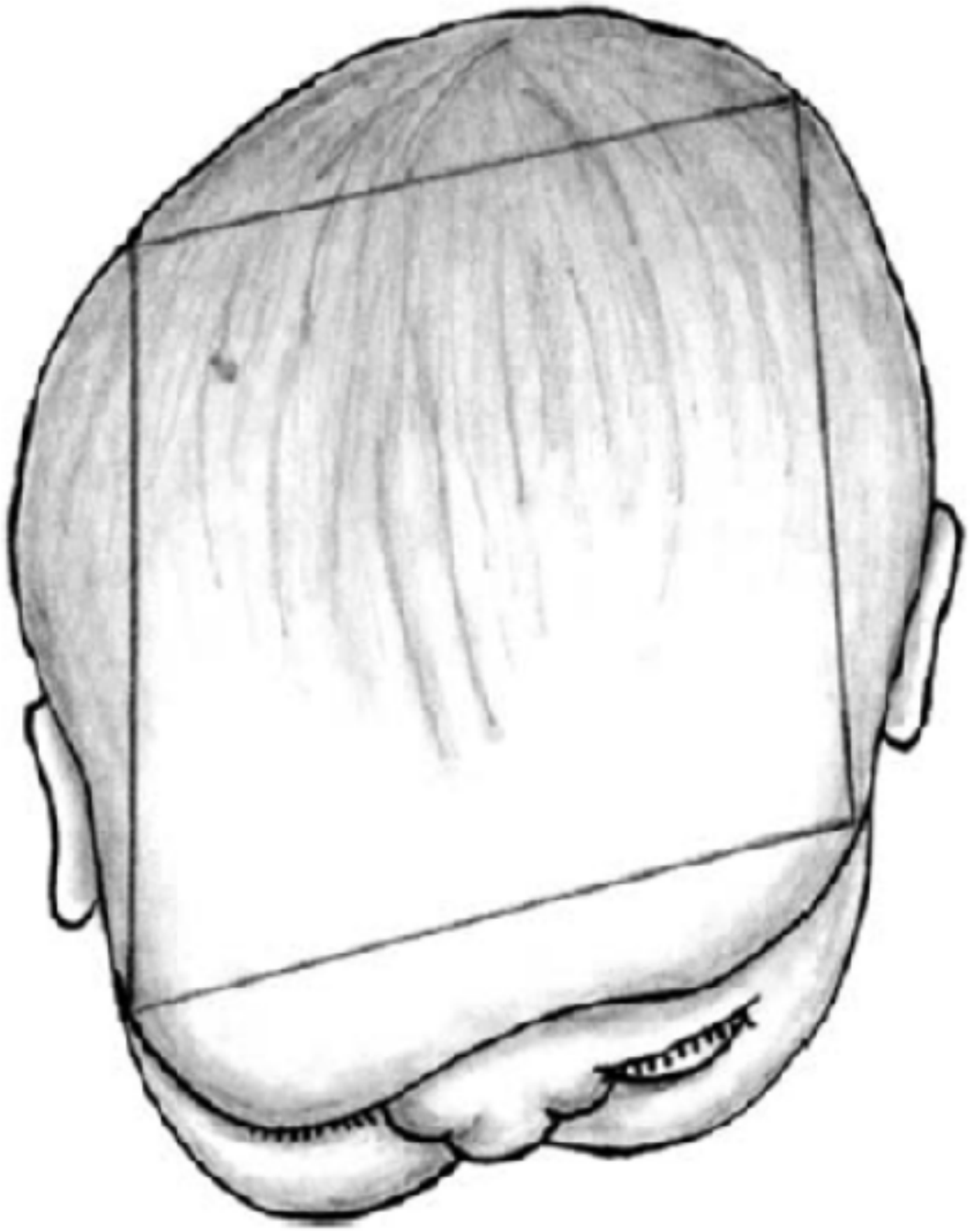

Parallelogram head.

CROOKED TEETH MAY INCREASE

HEADACHES

Can You Identify the Strain?

ackBerry

DEN OF THIEVES

FaceLiftDentistry.com
© Sam Muslin, DDS
Photo taken 3 years after treatment was completed
Copyright Sam Muslin DDS

A Different Look At Angle Classification

Angle Classification

- As you look at the upcoming pictures, try to look PAST the tooth position in the mouth and see the FORCES that come into the teeth and how the head and body must then adapt to those forces.

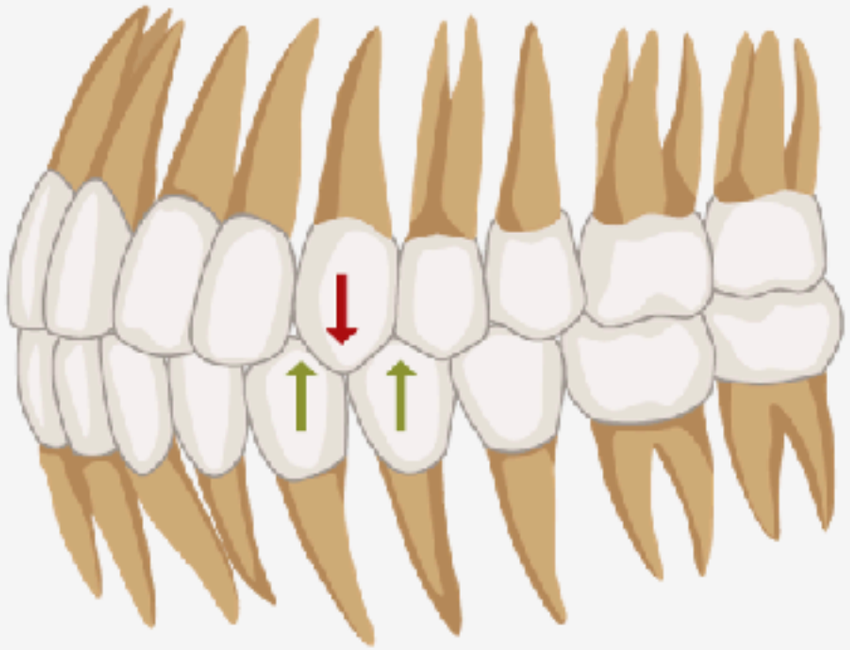

Class 1

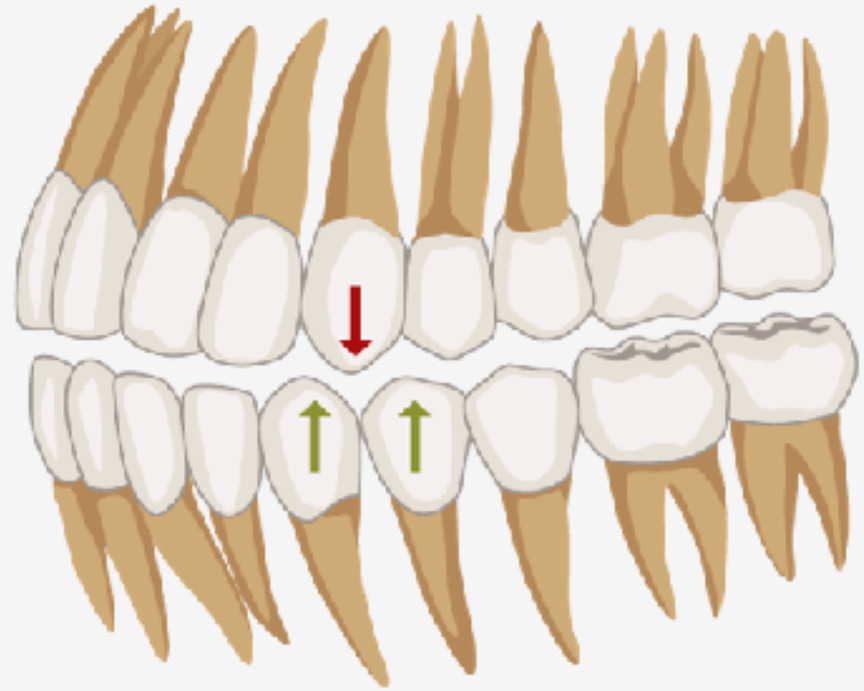

Class 1

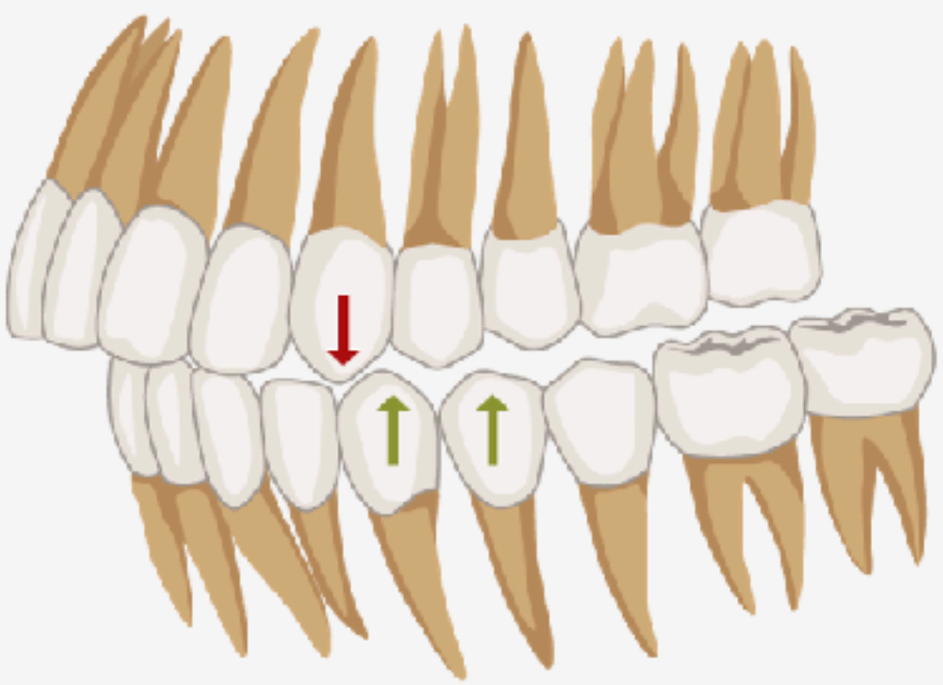

Class 2

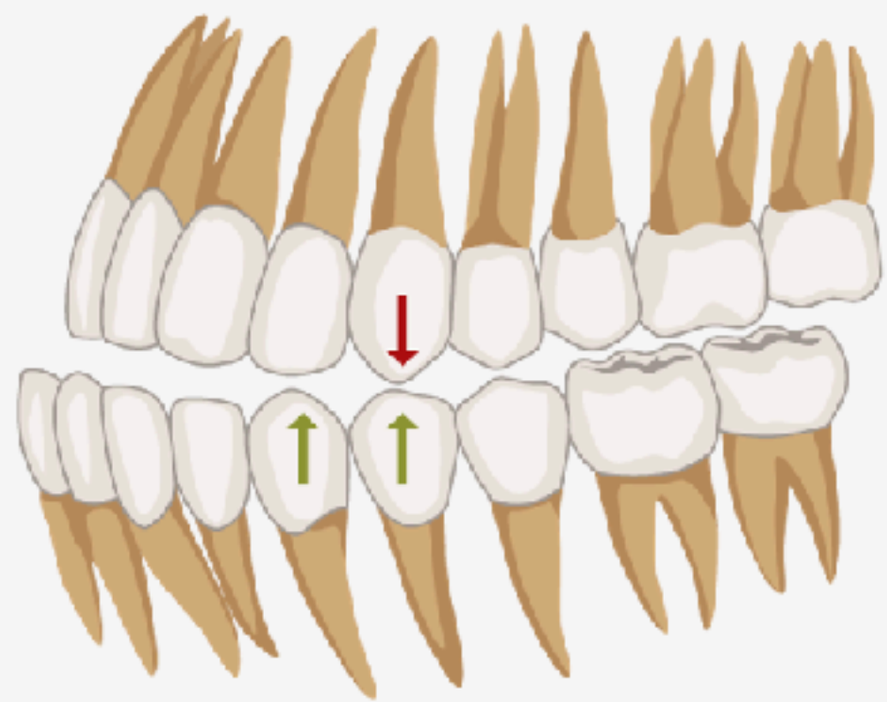

Class 3

Class 1 Class 2, Div 1 Class 2, Div 2 Class 3

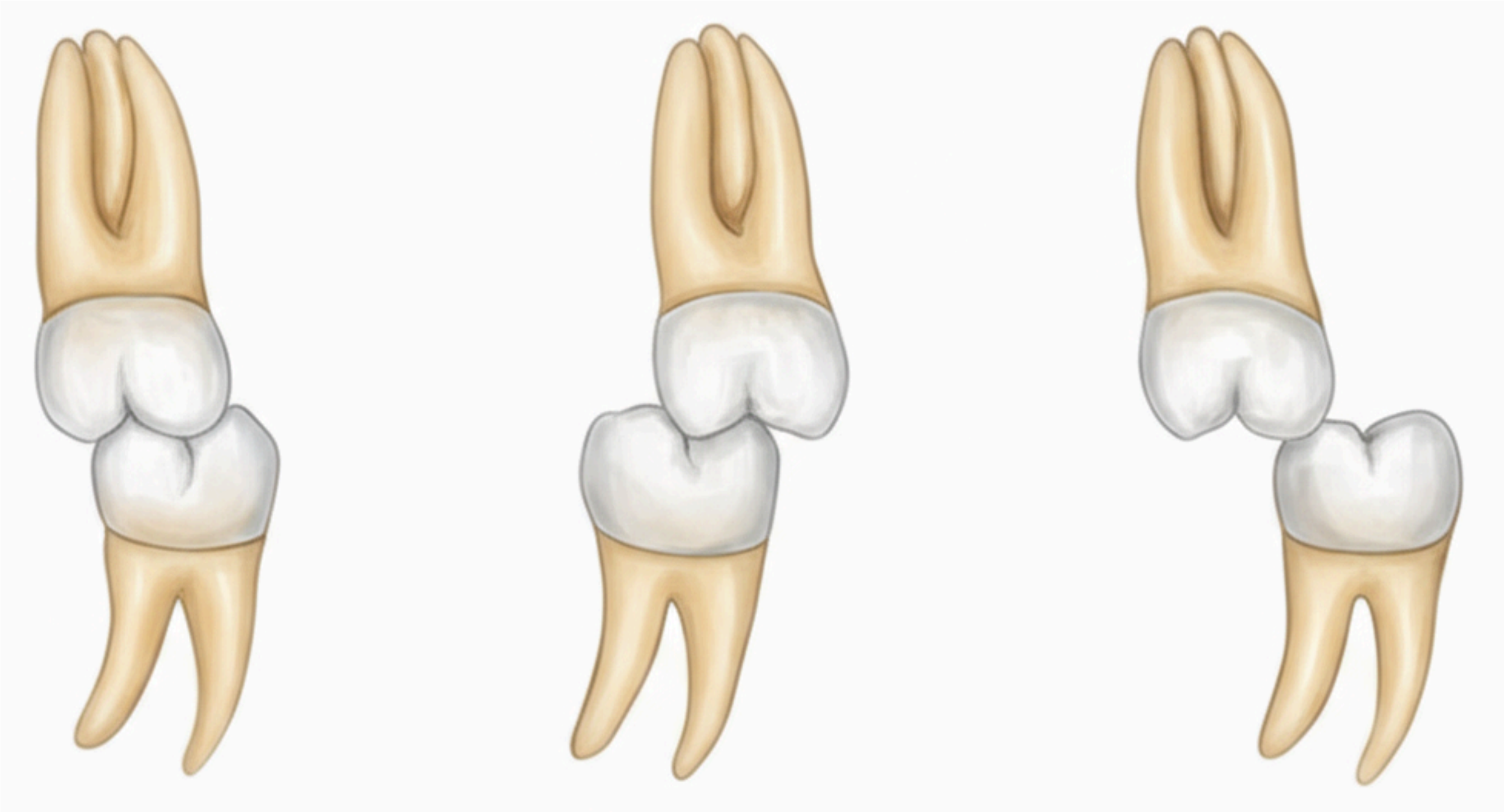

Class 1 Class 2 Class 3

Angle Classification

- Could any of these forces cause the tooth to fracture? To wiggle in its socket (causing the tooth to loosen or gum loss)? To wear in uncommon patterns?

- With the knowledge that you have right now, what would you do about that to correct it? What would the BODY impact of that be (because if the TEETH show abnormal forces (and they are sensory organs) then the body must also show evidence of the same forces).

Bone Loading Forces

DECIDUOUS
DANCE
2012
NO GRINDING!

“All religions, arts and sciences are branches of the same tree.”



–Albert Einstein

The Effect of Force Placed Upon Bone

Mechanical Loading of Bone

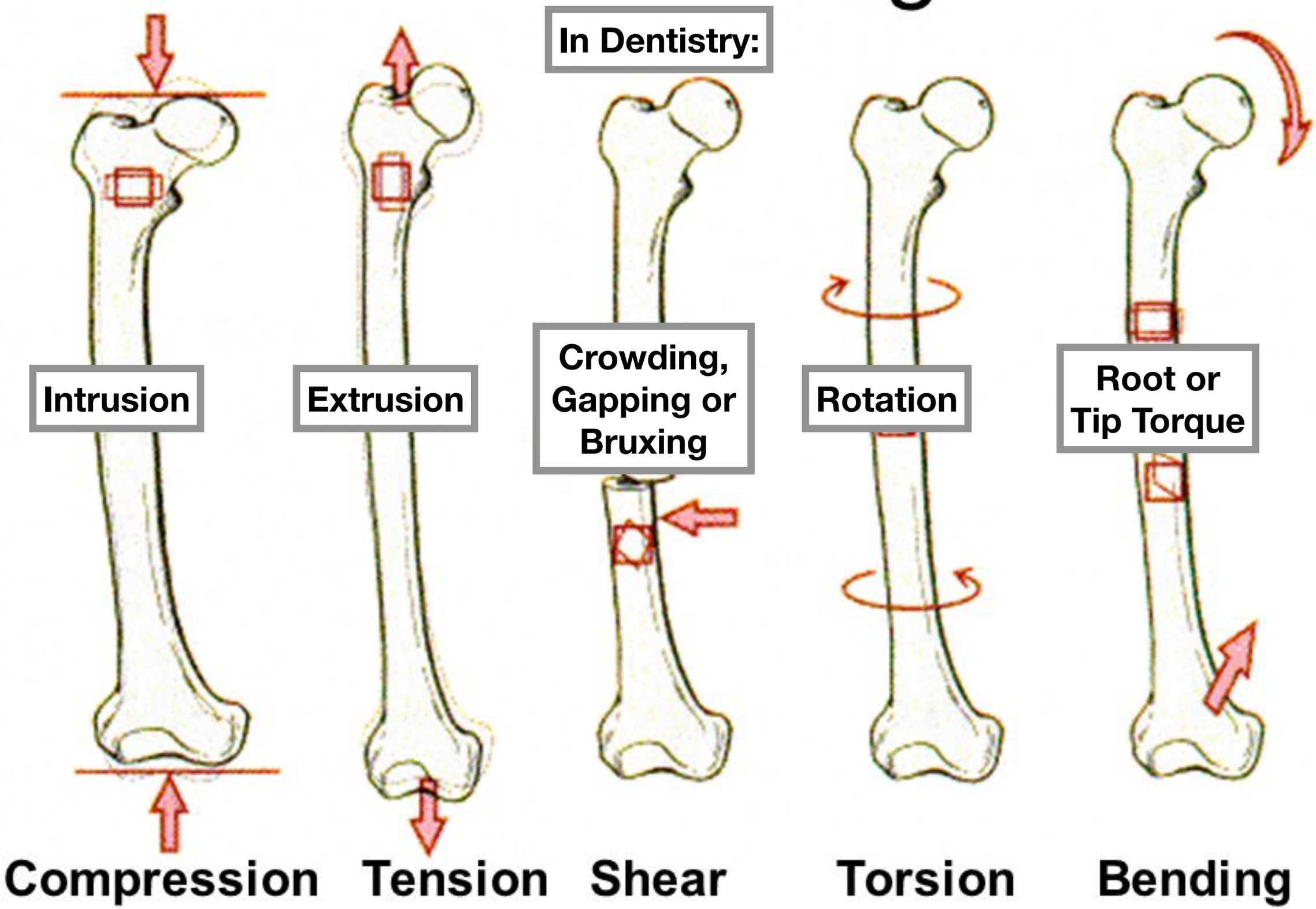

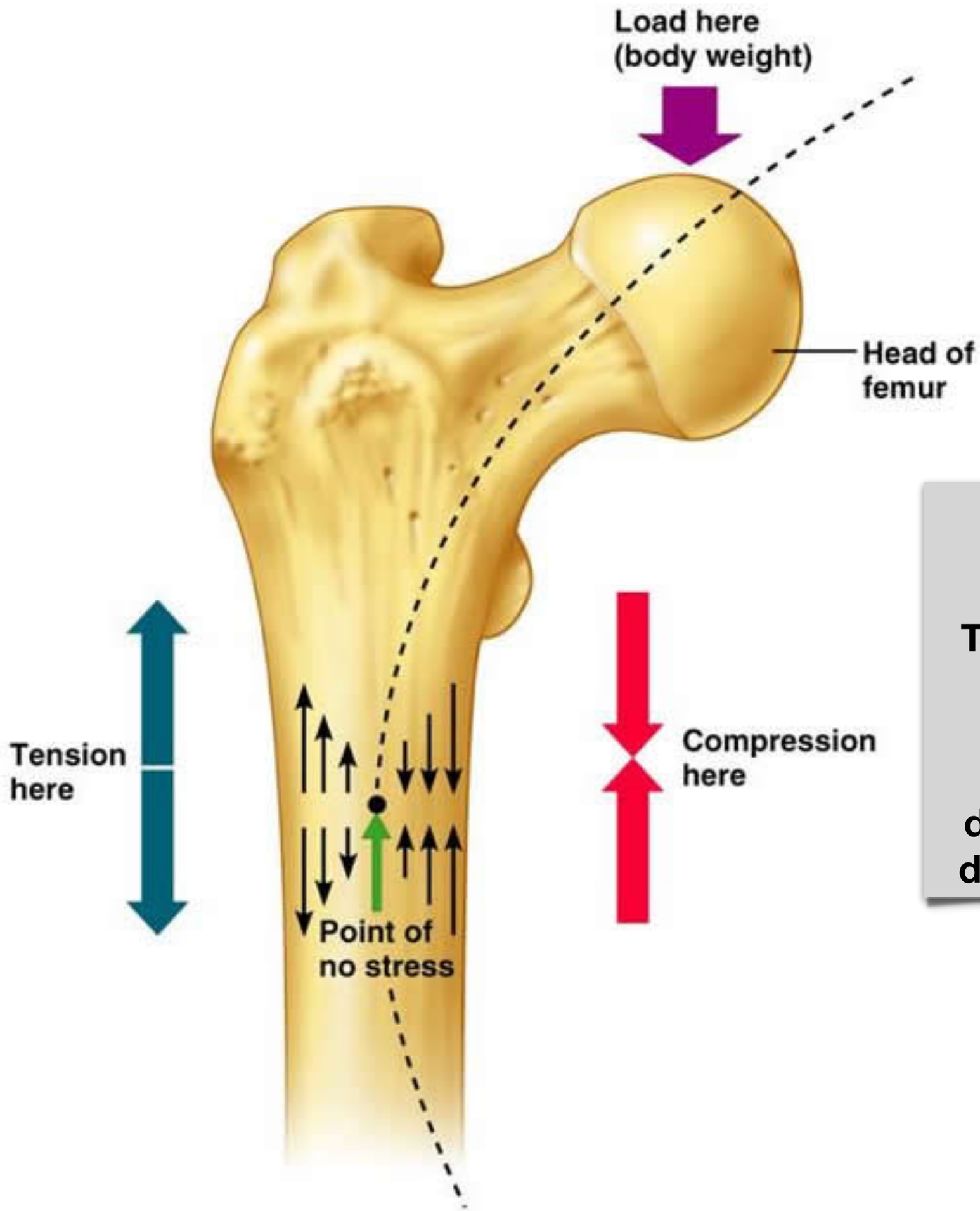

Wolff's Law

Tension and compression cycles create a small electrical potential that stimulates bone deposition and increased density at points of stress

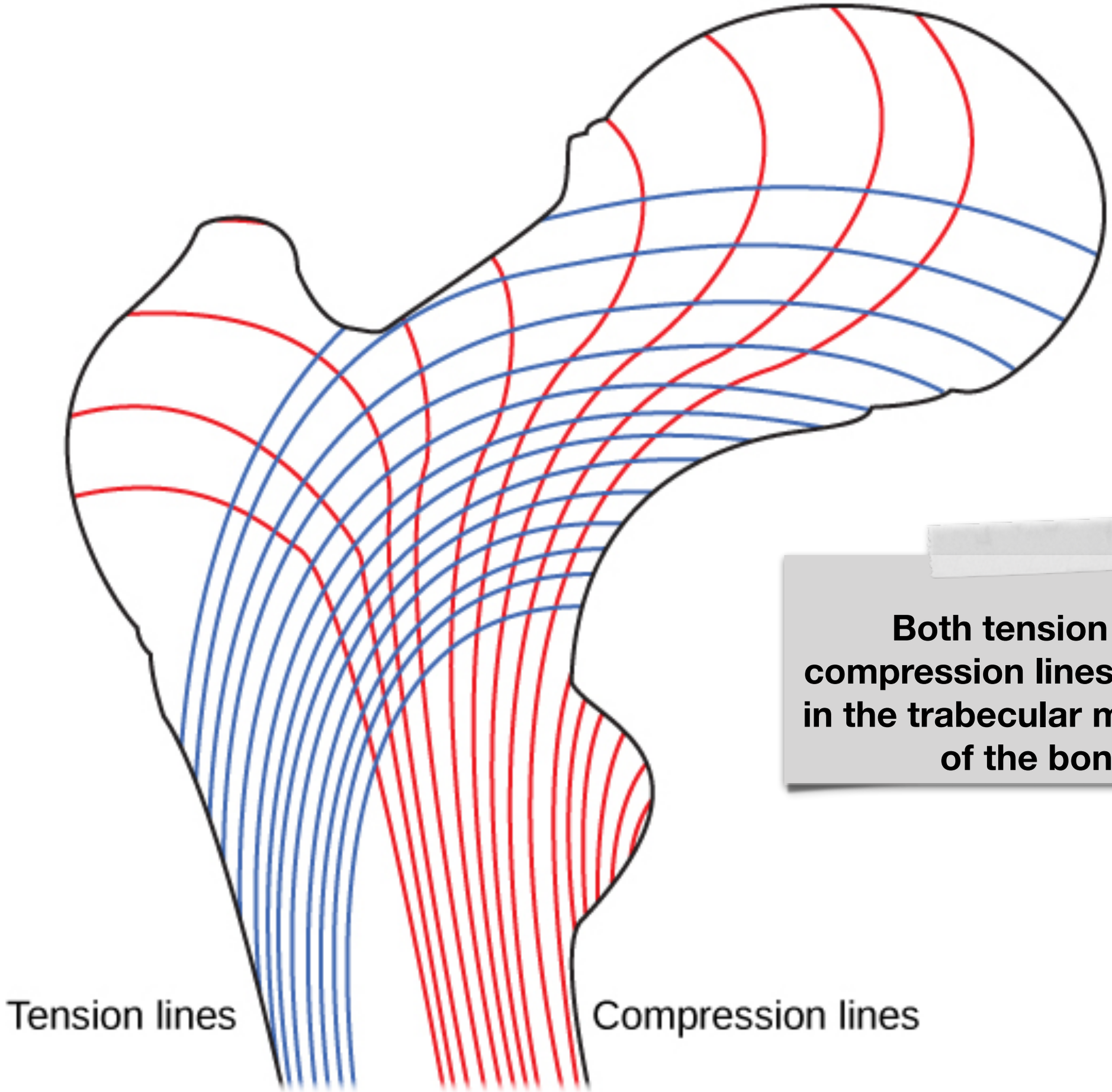

Both tension and compression lines are seen in the trabecular meshwork of the bone

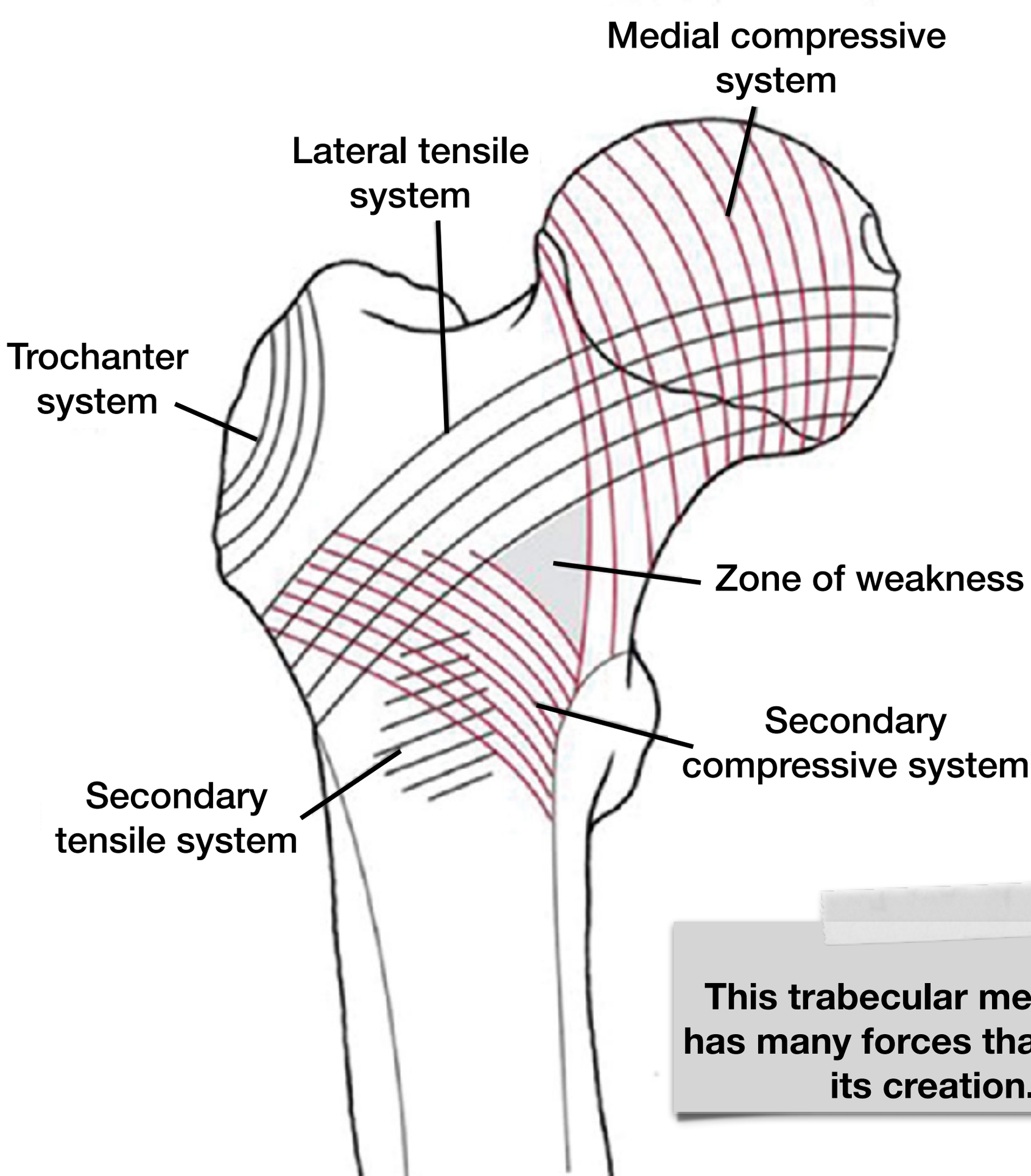

This trabecular meshwork has many forces that go into its creation.

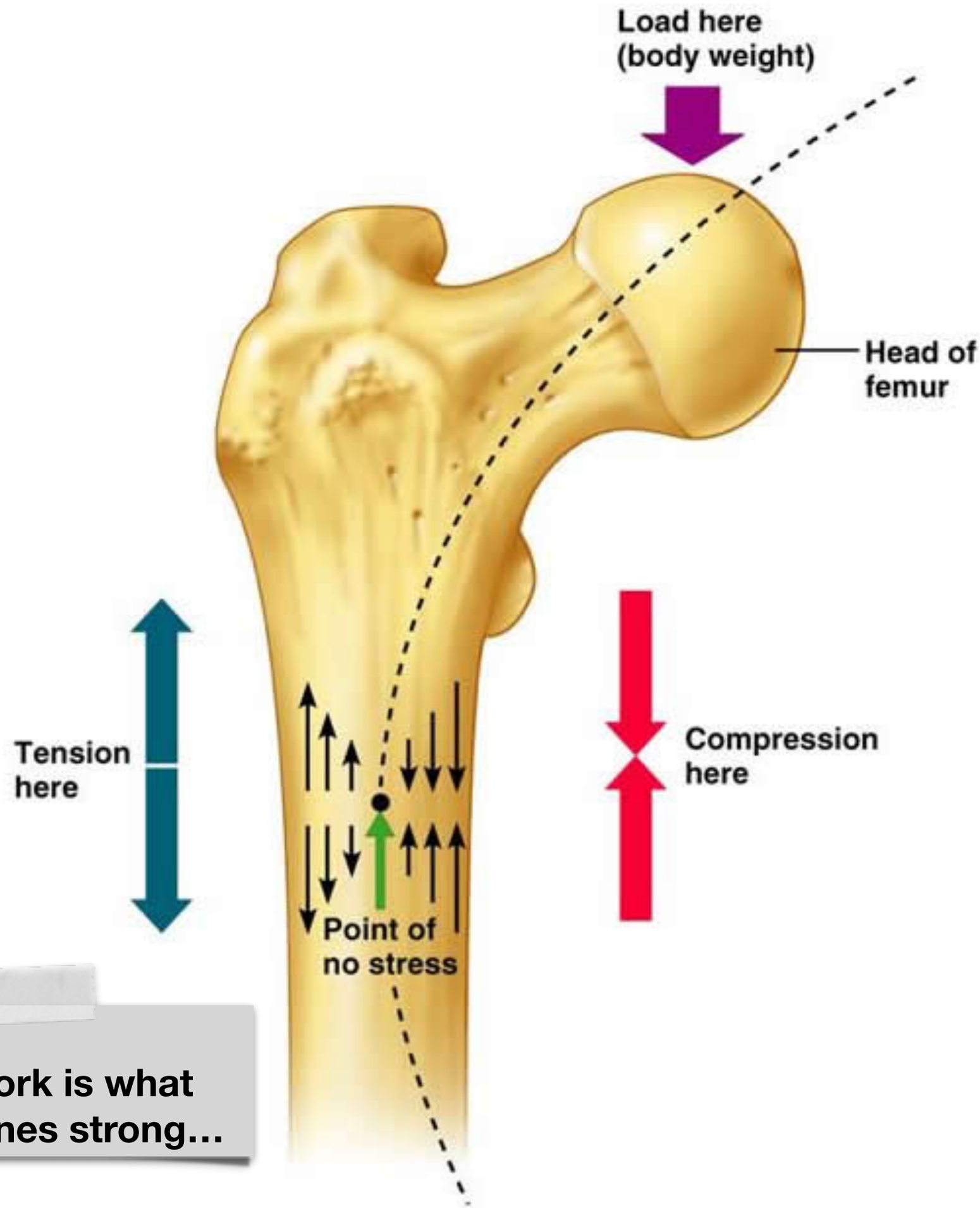

This meshwork is what makes our bones strong…

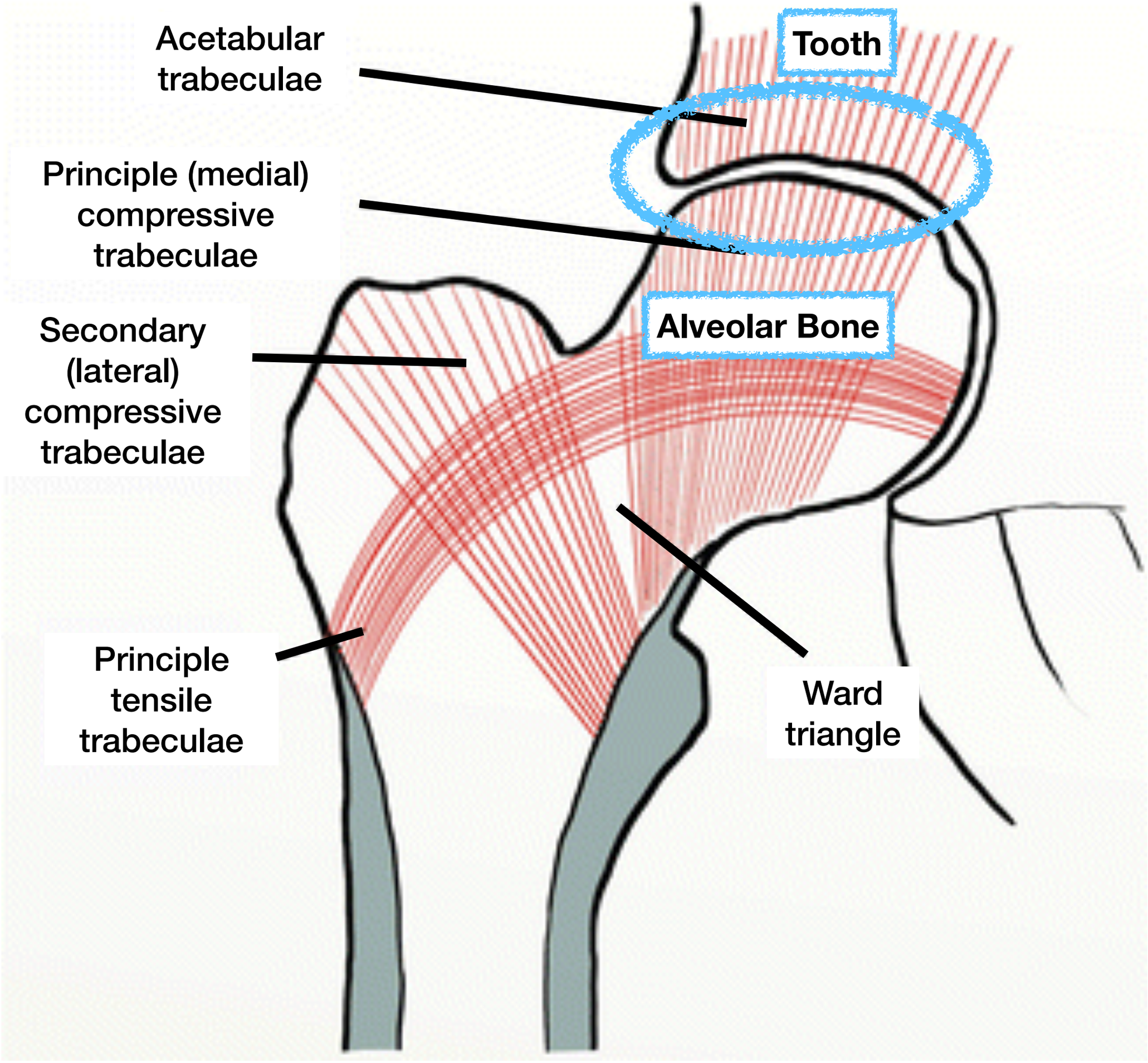
Acetabular trabeculae
Tooth
Principle (medial) compressive trabeculae
Alveolar Bone
Secondary (lateral) compressive trabeculae
Principle tensile trabeculae
Ward triangle

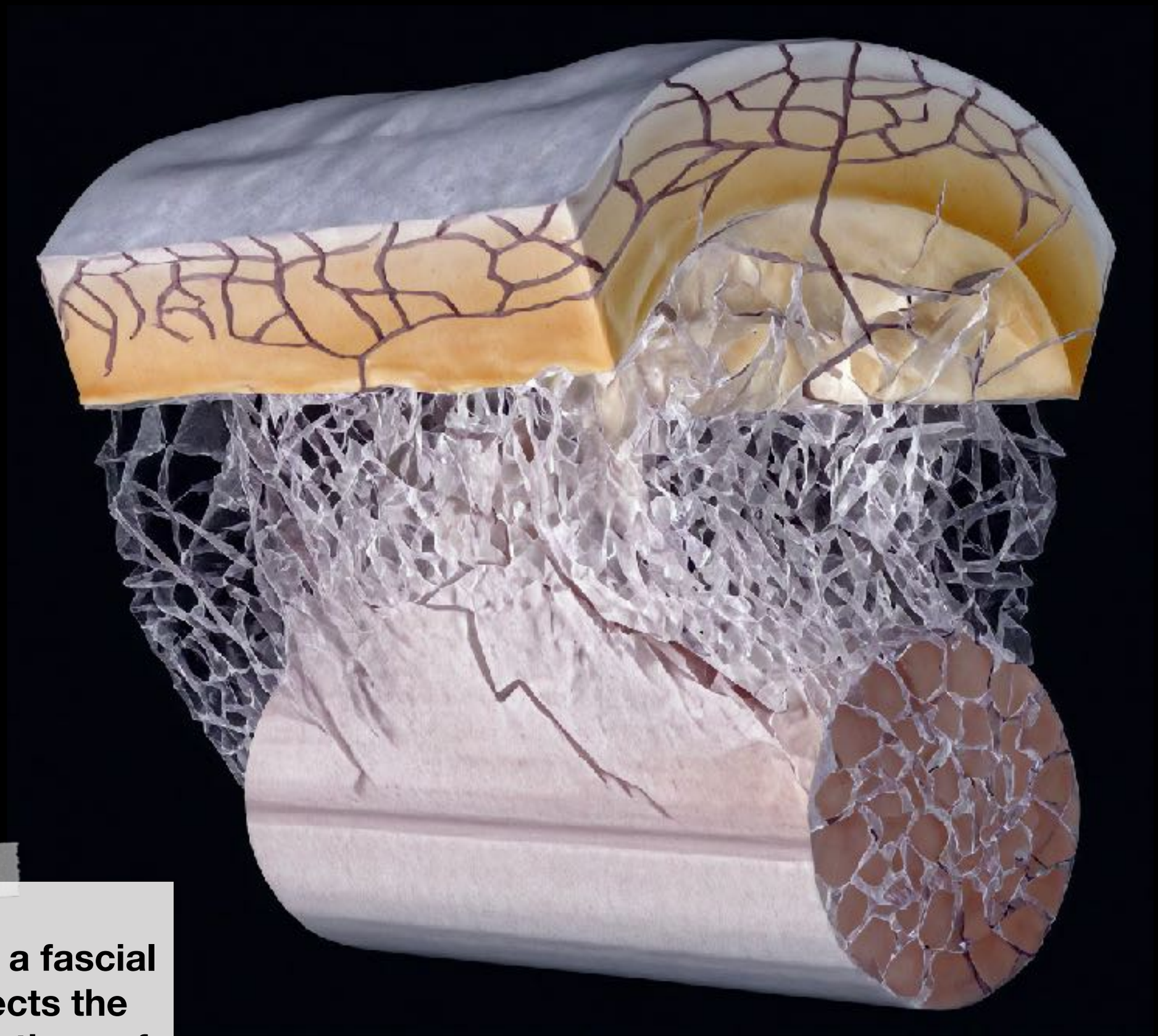

And is built around a fascial matrix that connects the inner and outer portions of the bones.

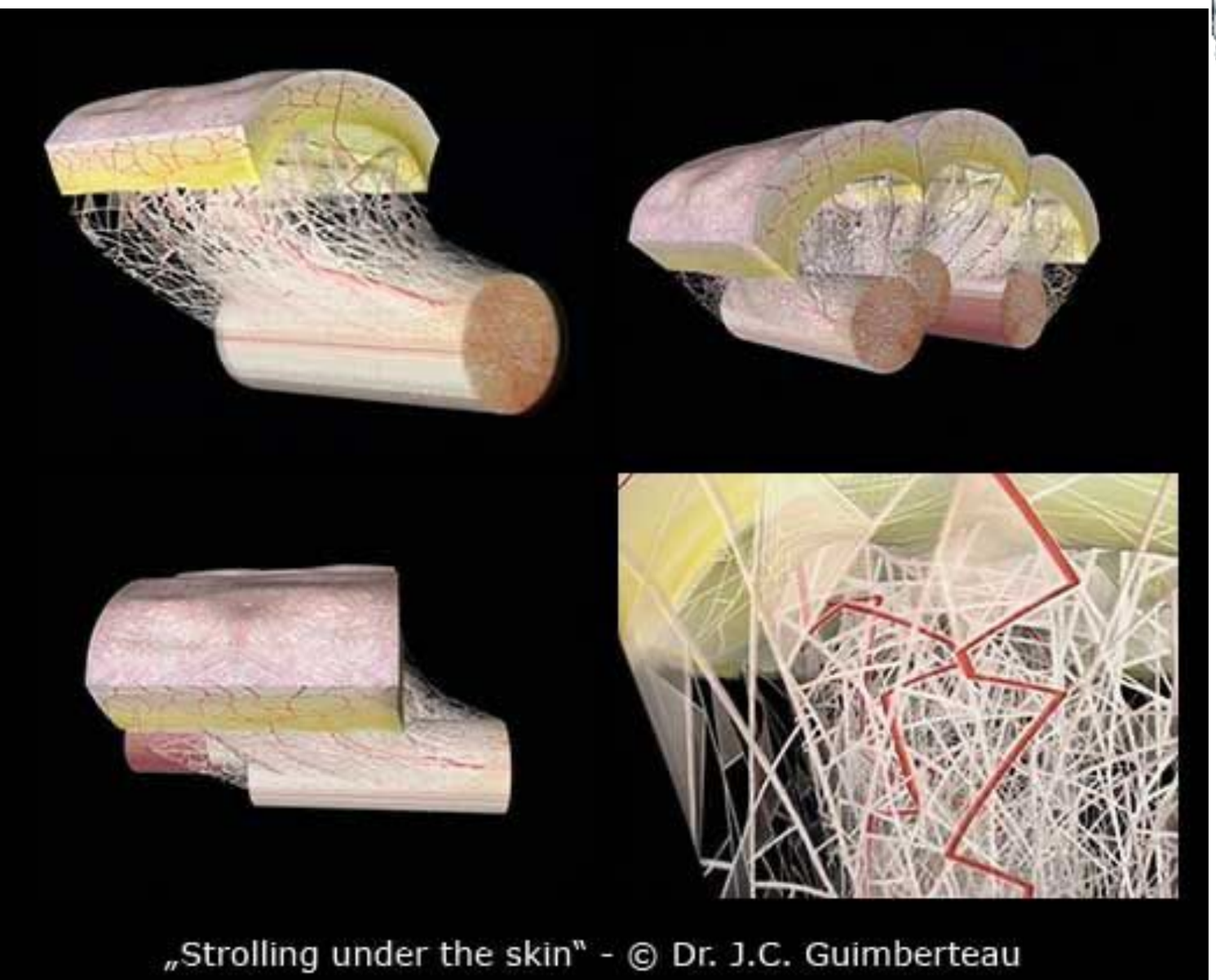

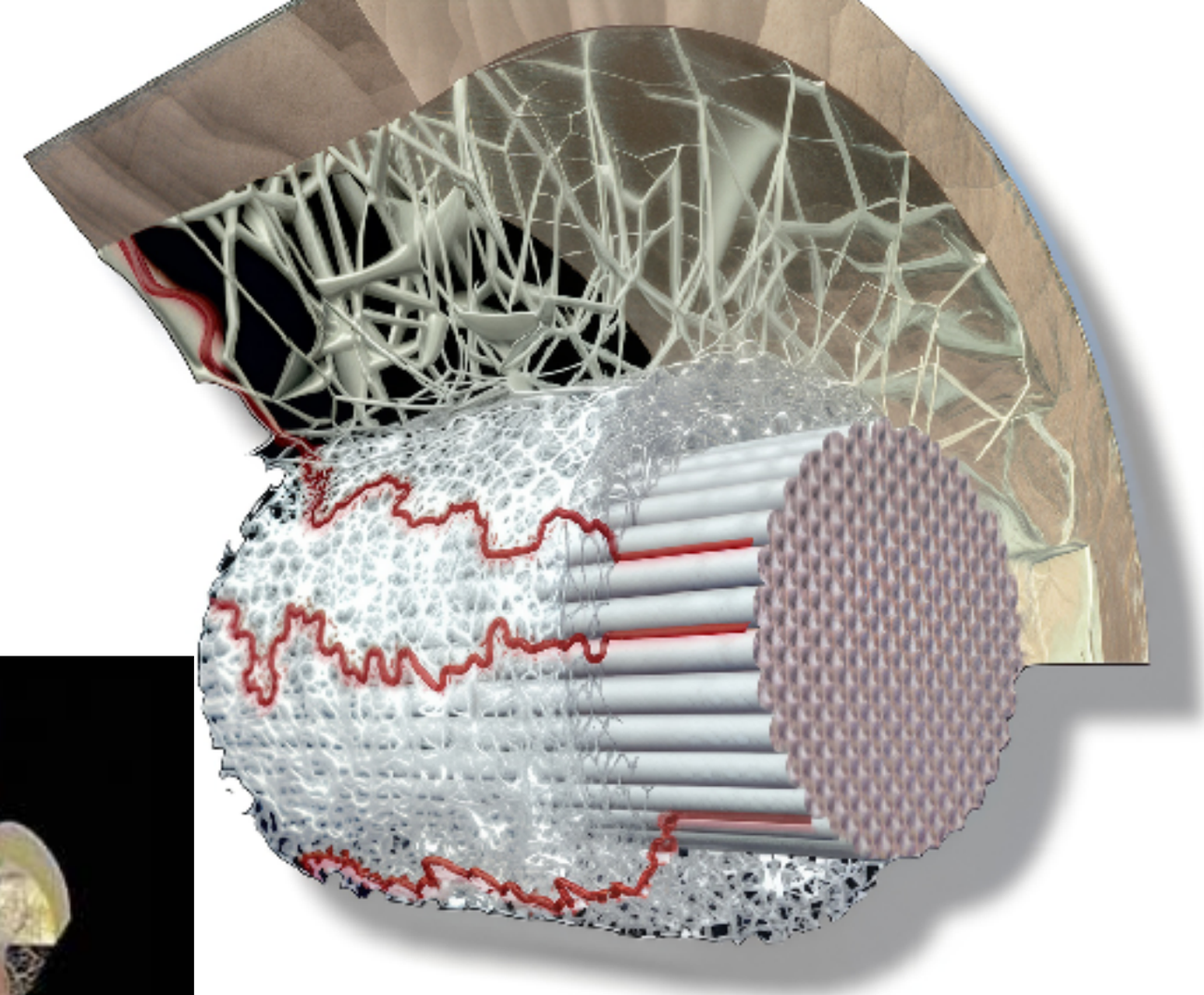

The matrix creates the trabecula and their locations within the bone…

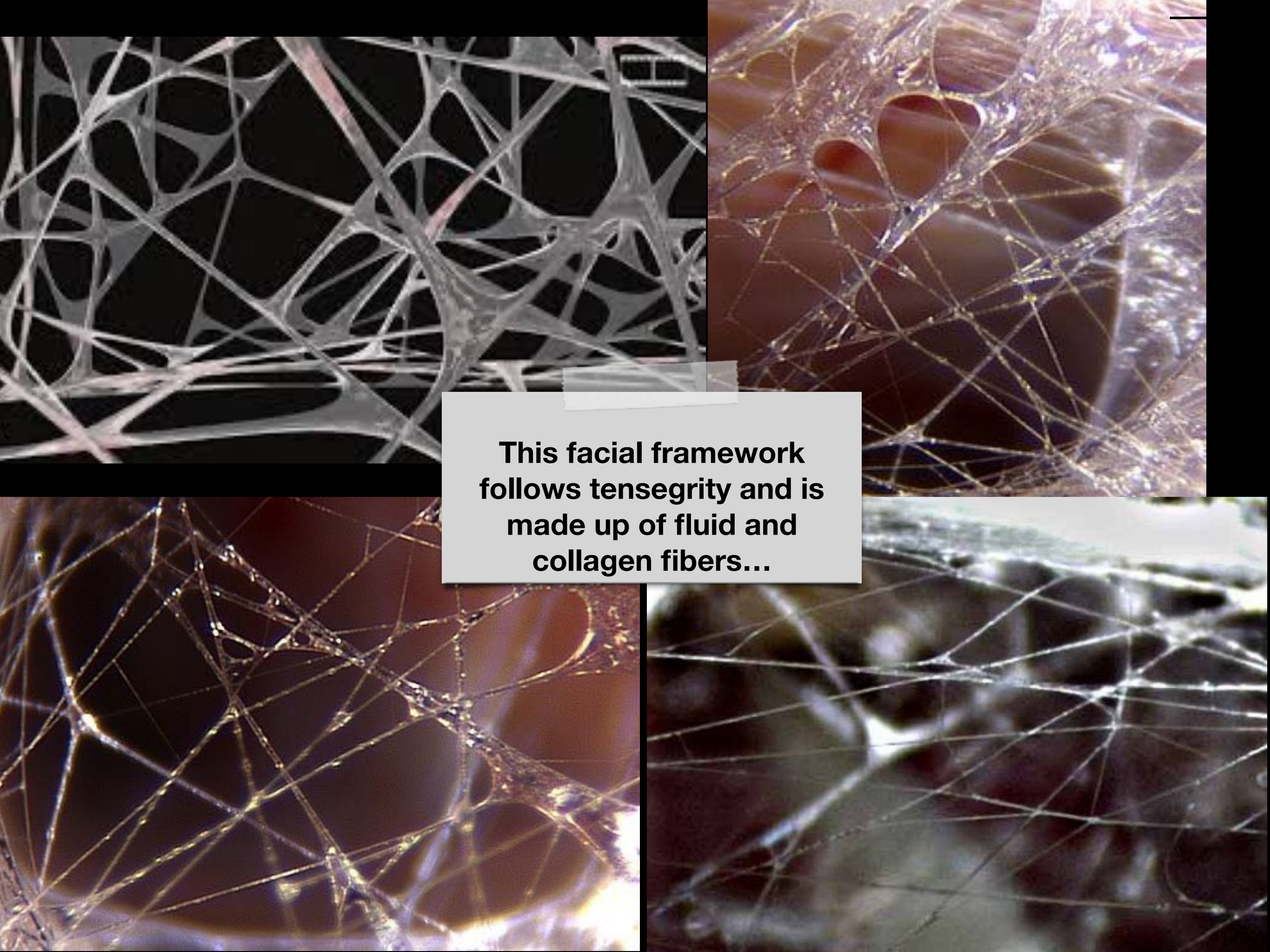

This facial framework follows tensegrity and is made up of fluid and collagen fibers…

In some places these fibers specialized and are considered ligaments.

In other places they carry fluids

In the tooth, they being to create a framework for the feedback of the motion of the tooth and the things it contacts.

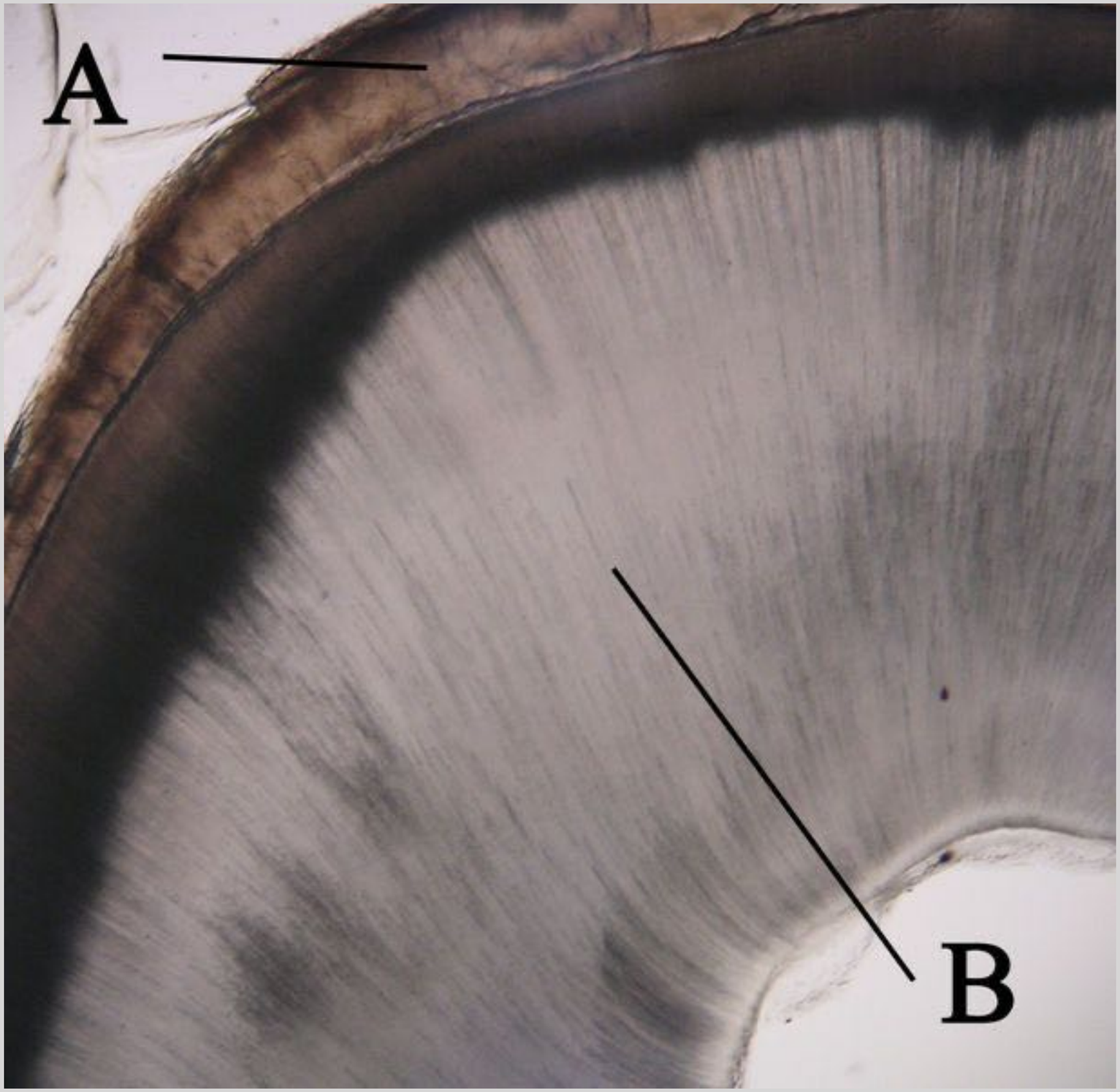

This fascial framework in the tooth is fairly unique… there are multiple fibers by which movement(s) of the tooth can be relayed into the nervous system.

To reiterate here, as you grow, your bony framework is laid down. Once you are gown, the framework is relatively fixed.

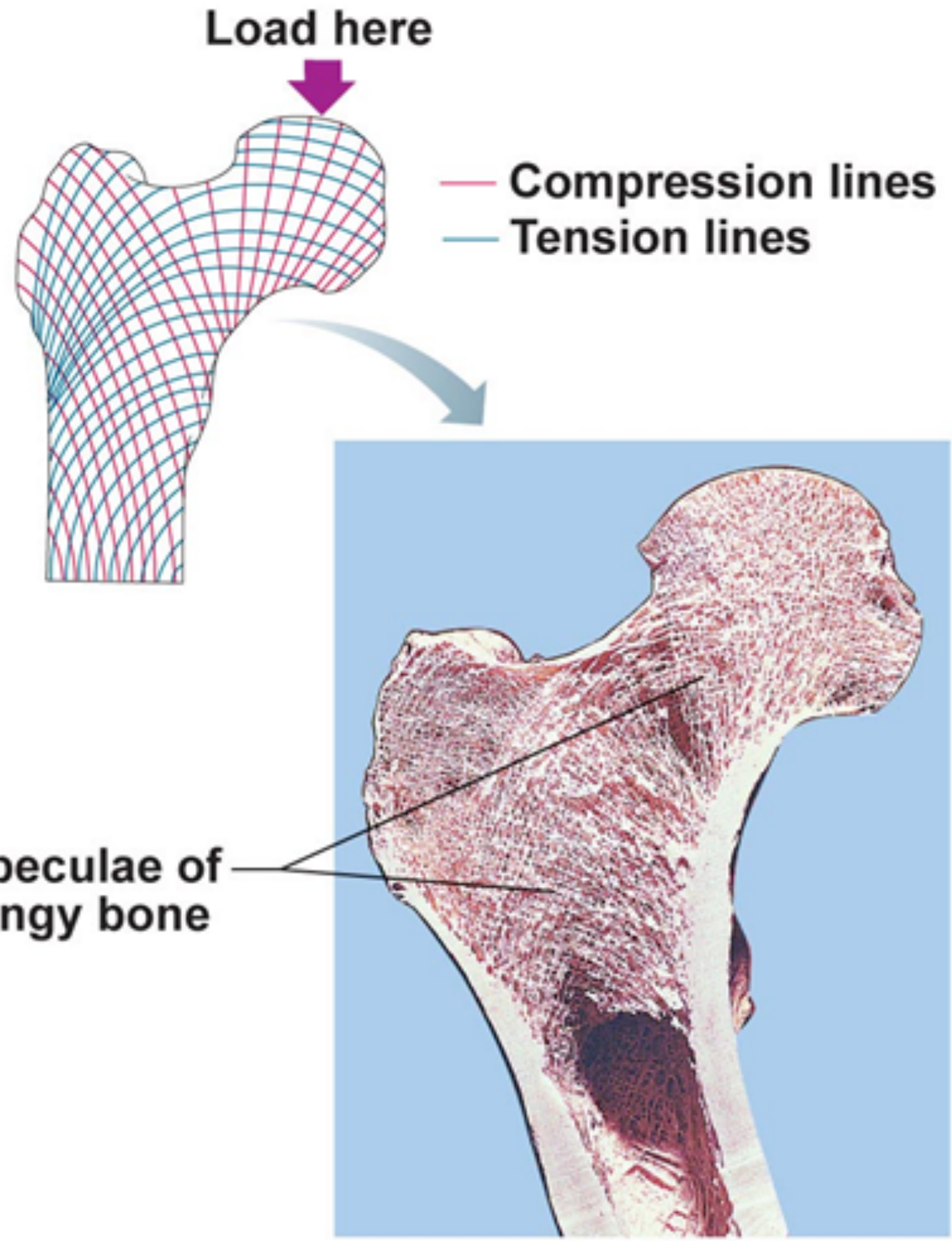

This is why it is easier to work with patients who are not fully grown.

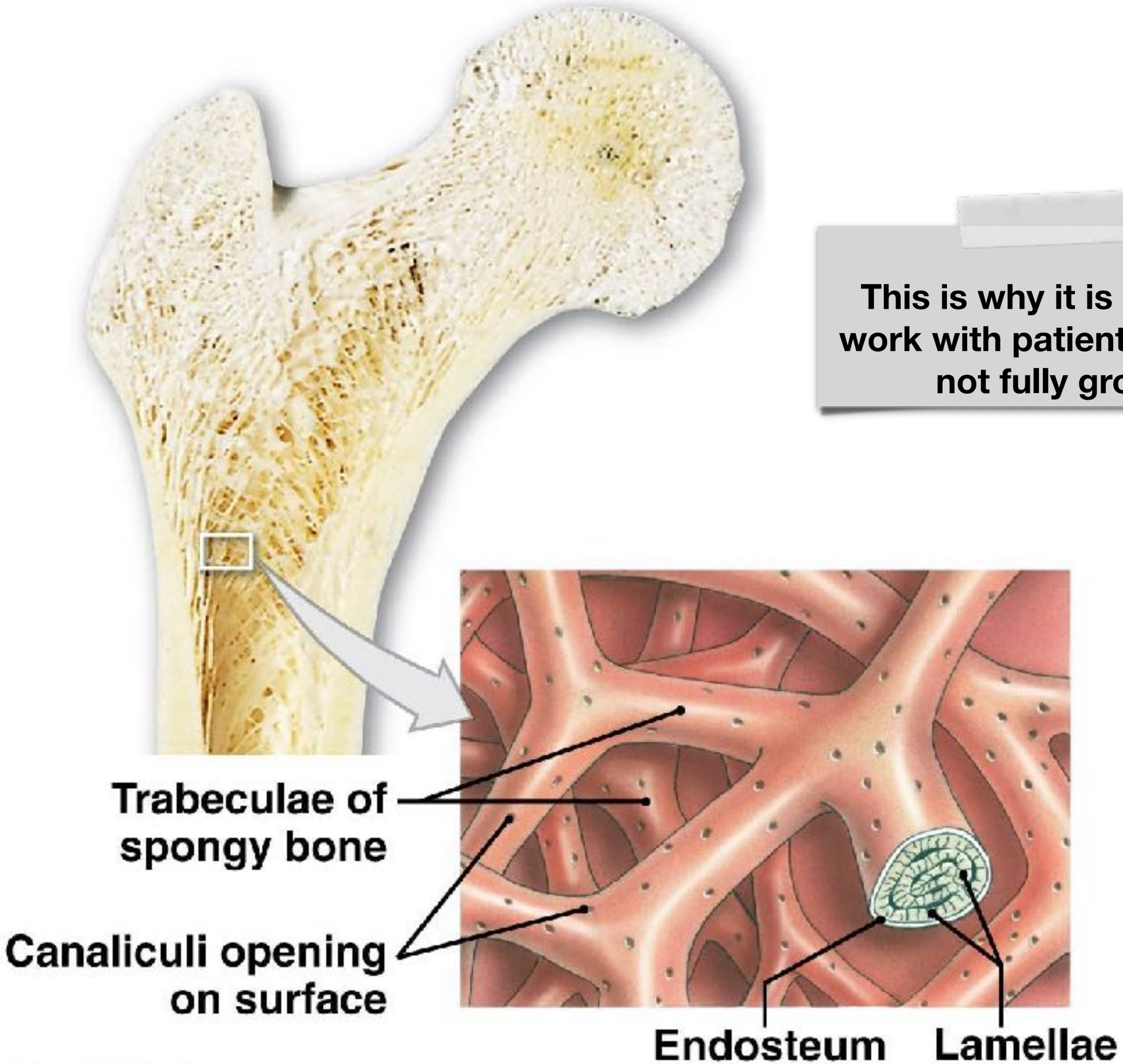

© 2015 Pearson Education, Inc.

Spongy Bone Structure and Stress

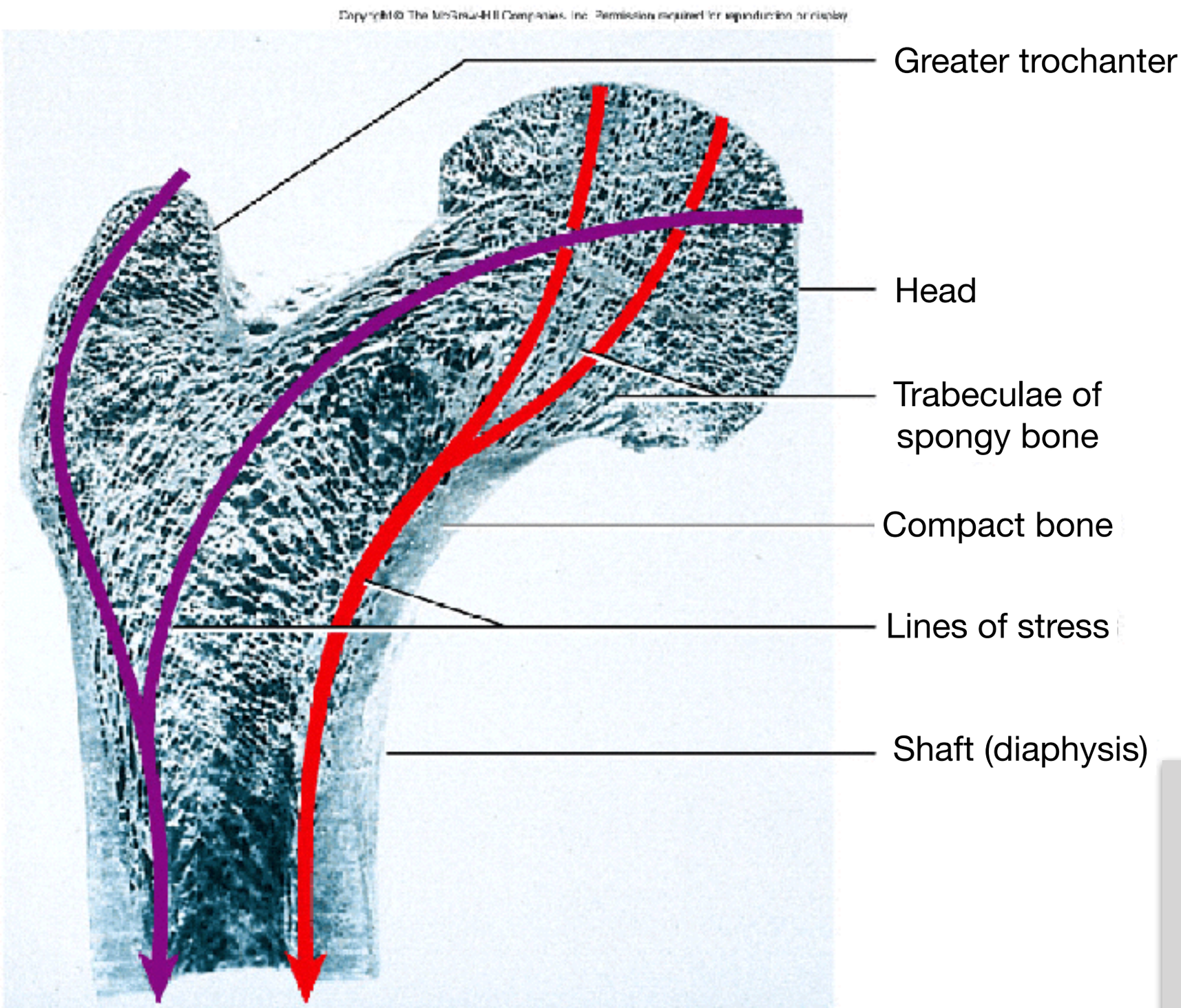

This is the same framework as in the mandible and maxilla. How does moving the teeth impact or change the bony structure?

**Remember:
Babies bounce,
Children bend,
and Adults break.**

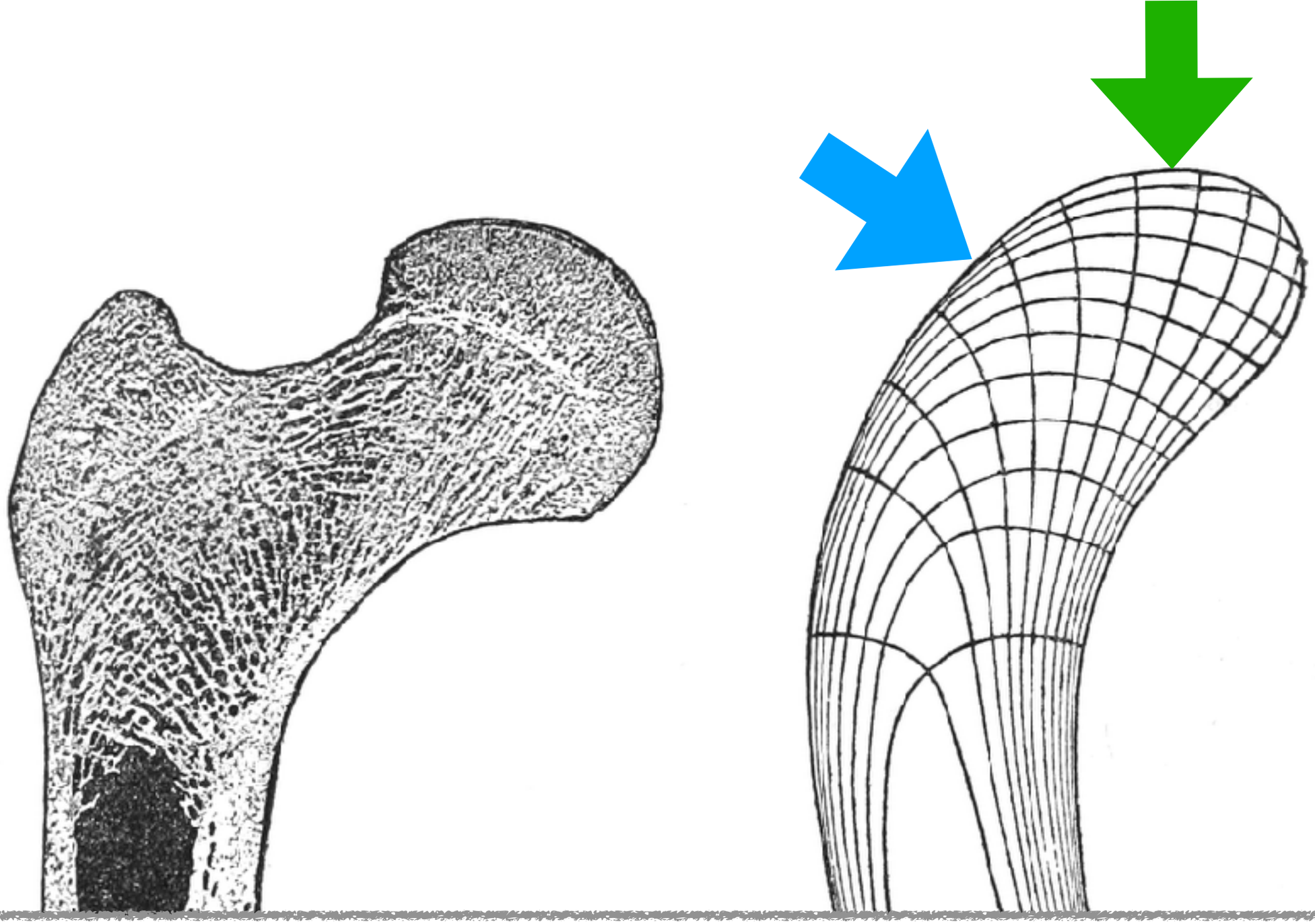

What happens in the mouth or body when you move the loading force from here to here? As a baby? Child? Adult?

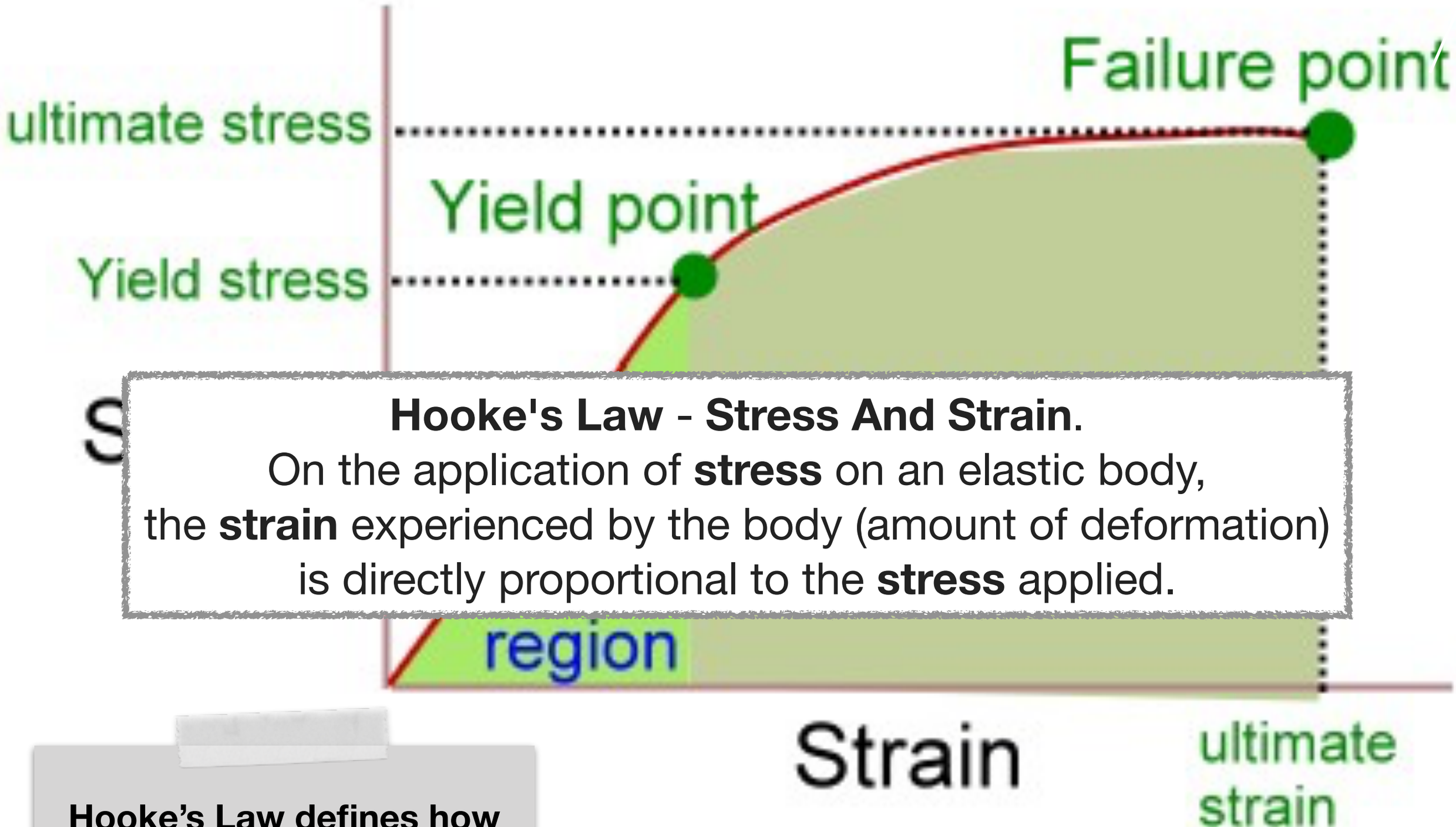

Hooke's Law - Stress And Strain.
On the application of **stress** on an elastic body,
the **strain** experienced by the body (amount of deformation)
is directly proportional to the **stress** applied.

Hooke's Law defines how quickly you can move the body. If you go too fast or too far, the body fights your efforts.

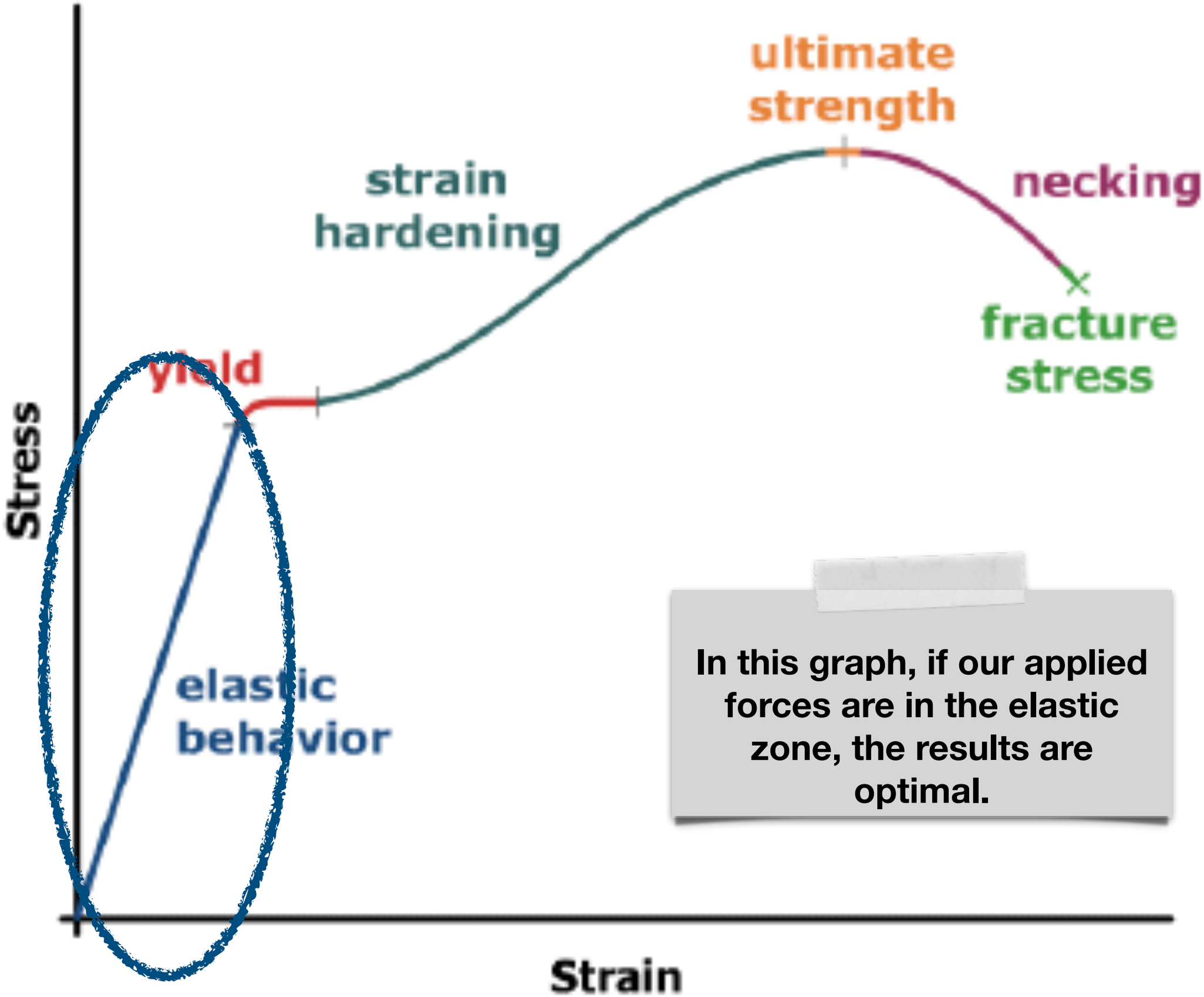

In this graph, if our applied forces are in the elastic zone, the results are optimal.

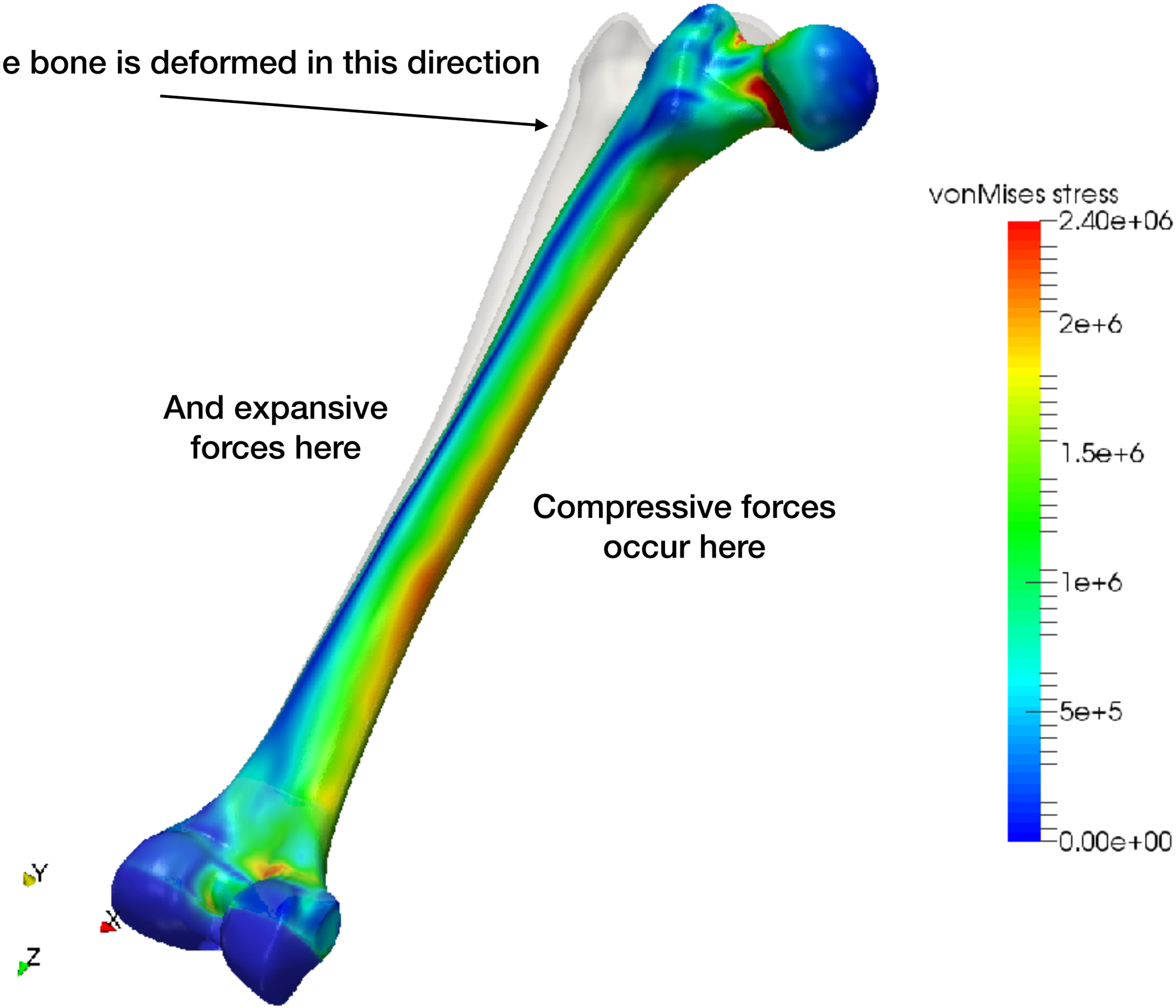
As the bone is deformed in this direction
And expansive forces here
Compressive forces occur here
vonMises stress
2.40e+06
2e+6
1.5e+6
1e+6
5e+5
0.00e+00
Y
X
Z

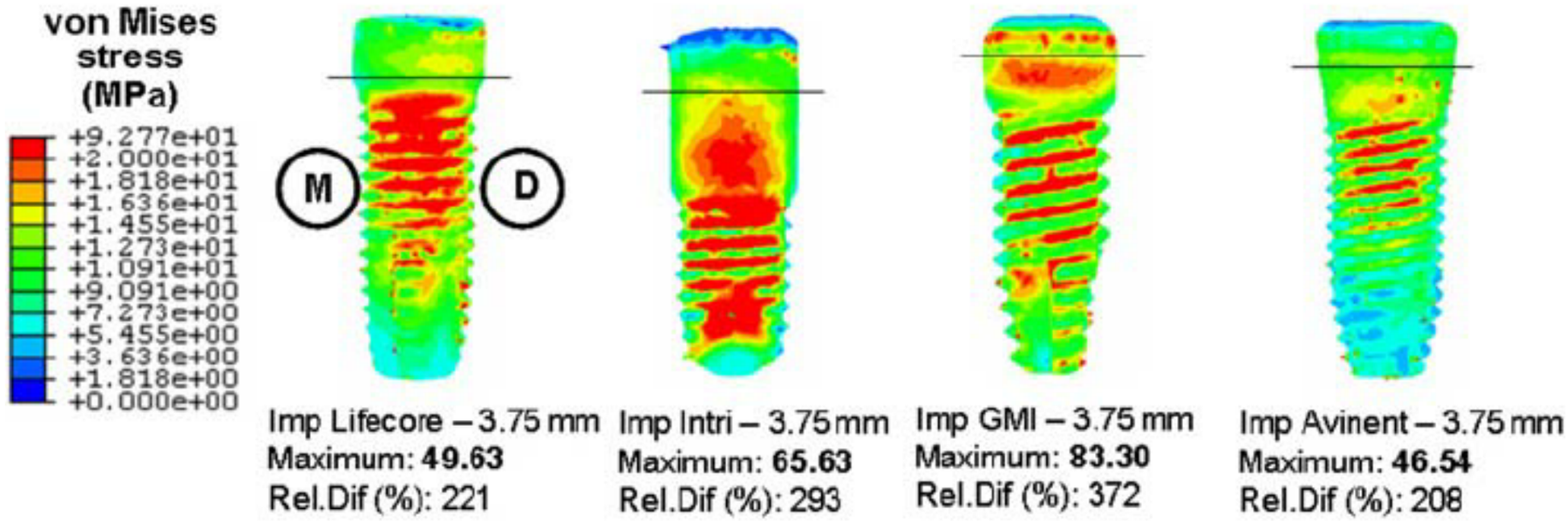

If we go outside the elastic zone, we start to get stress forces like the upper left.

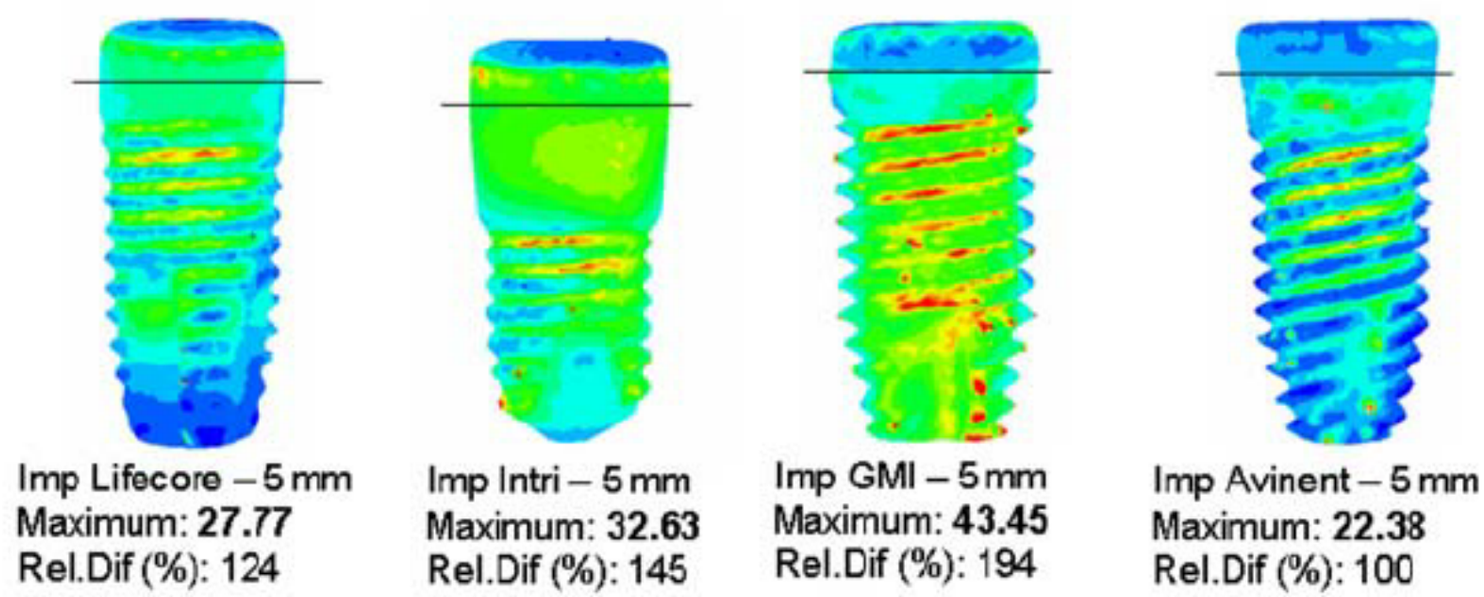

Stress forces in dental implants

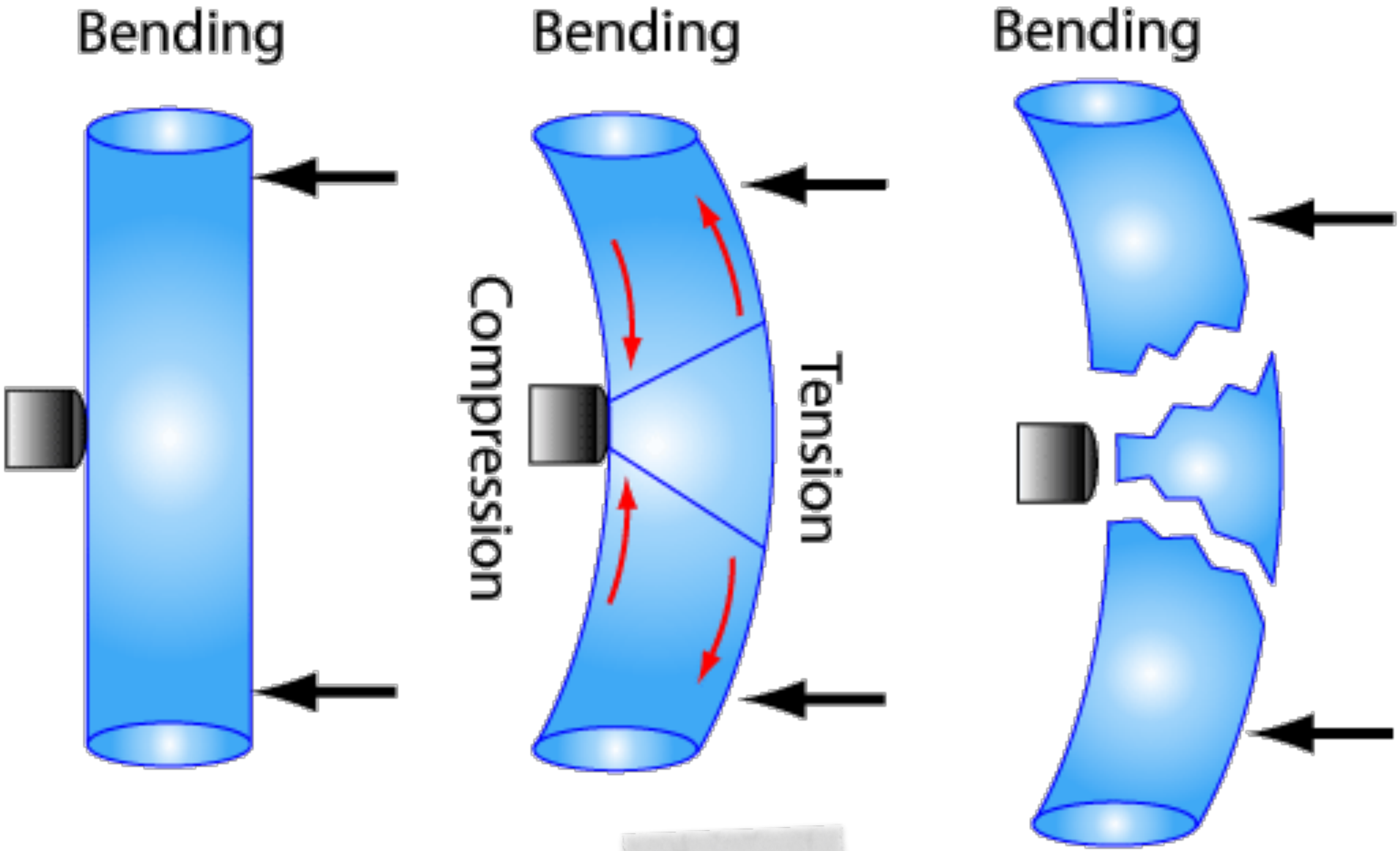

And it we far exceed Hooke's Law, breakage can occur.

Bone bending:
Medical-dental model reconciliation

Shear compression strain
→ Bone apposition (+)

Shear tensional strain
→ Bone resorption (–)

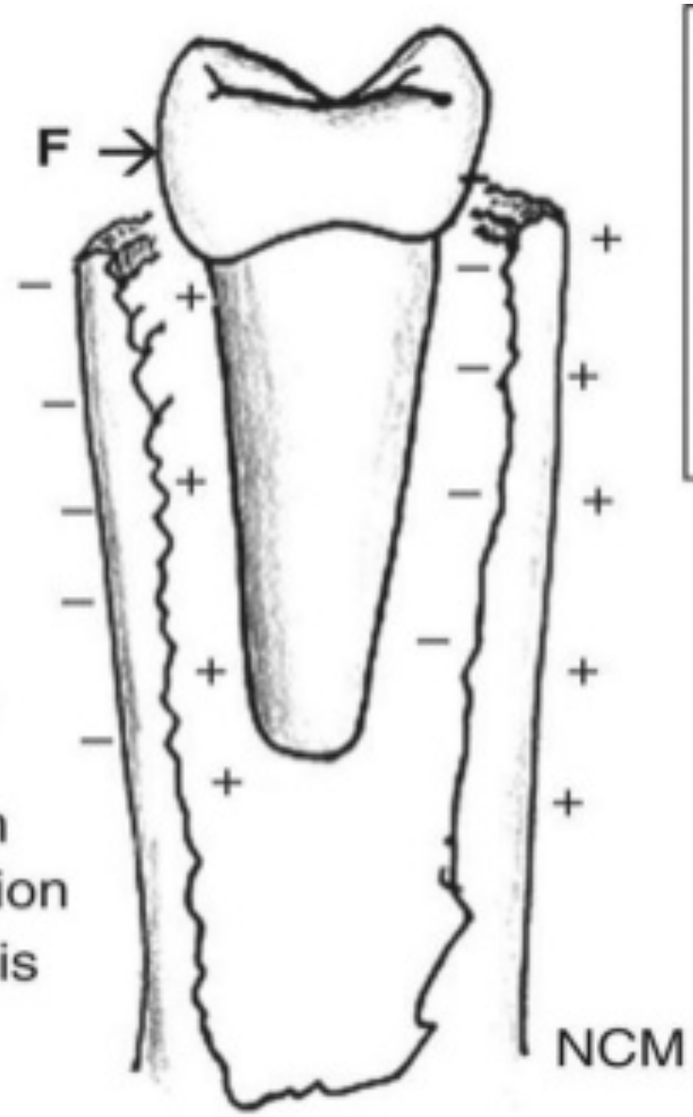

"Tension" side:

Convex periosteum
→ Shear tension
→ osteoclasia

Concave endosteum
→ Shear compression
→ osteogenesis

"Pressure" side:

Concave periosteum
→ Shear compression
→ osteogenesis

Convex endosteum
→ Shear tension
→ osteoclasia

In dentistry, Hooke's Law (and the ability to palpate its effect) can guide our treatment plan.

Alveolar Bone Bends

↓

Deformation of Crystalline Structure

↓

Electrical Signal

↓

Changes in Bone Metabolism

↓

Cellular Differentiation

↓

Tooth Movement

Optimum Forces for Orthodontics Tooth Movement

optimum forces for orthodontics tooth movement, as in the table below:

Types of Movement	Force (gm)
Tipping	35-60
Bodily movement (**Translation**)	70-120
Root up righting (**Torque**)	50-100
Rotation	35-60
Extrusion	35-60
Intrusion	10-20

These forces are not big forces, but should be directed precisely.

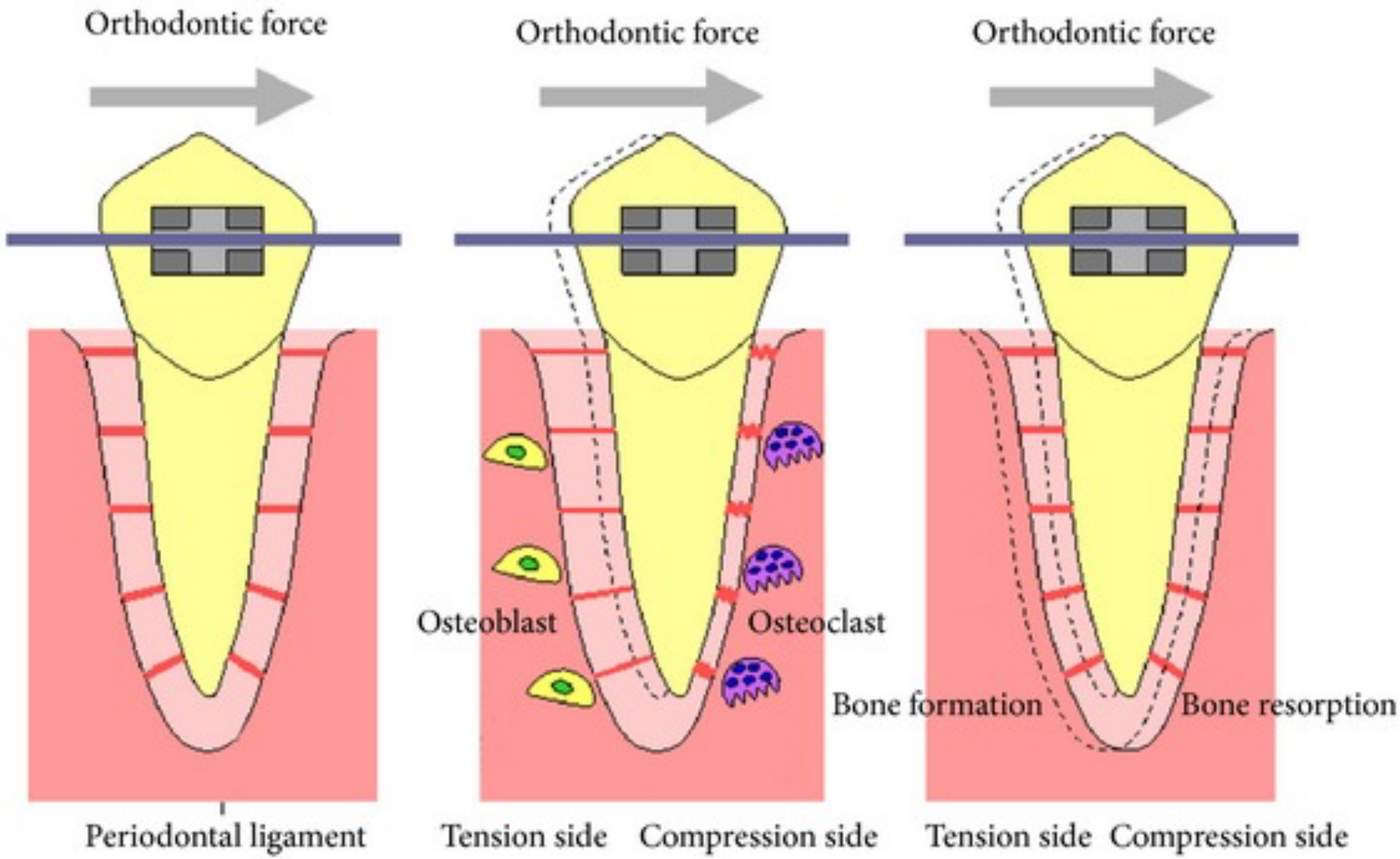
Orthodontic force
Orthodontic force
Orthodontic force
Osteoblast
Osteoclast
Bone formation
Bone resorption
Periodontal ligament
Tension side
Compression side
Tension side
Compression side

Magnitude Of Force

Time	Light Force	Heavy Force
<1s	Fluid stays in, bones bend, piezoelectric current	
1-2 s	Fluid expressed, tooth moves in socket	
3-5 s	Blood vessels distorted, no pain	Blood vessels occluded, pain from crushing pressure
Minutes	Blood flow and oxygen levels altered, elevated PGE, elevated RANKL	Blood flow cut off
Hours	Increased cAMP, cell differentiation	Sterile necrosis, hyalinized PDL (no cells)
2 days	Frontal reabsorption = osteoclasts and osteoblasts	
3-5 days		Undermining resorption begins
7-14 days		Undermining resorption ends, tooth moves

If too much force is used:

Blood Vessel Compression
↓
Local Ischemia
↓
Anaerobic Respiration
↓
Lactic Acid Build-up

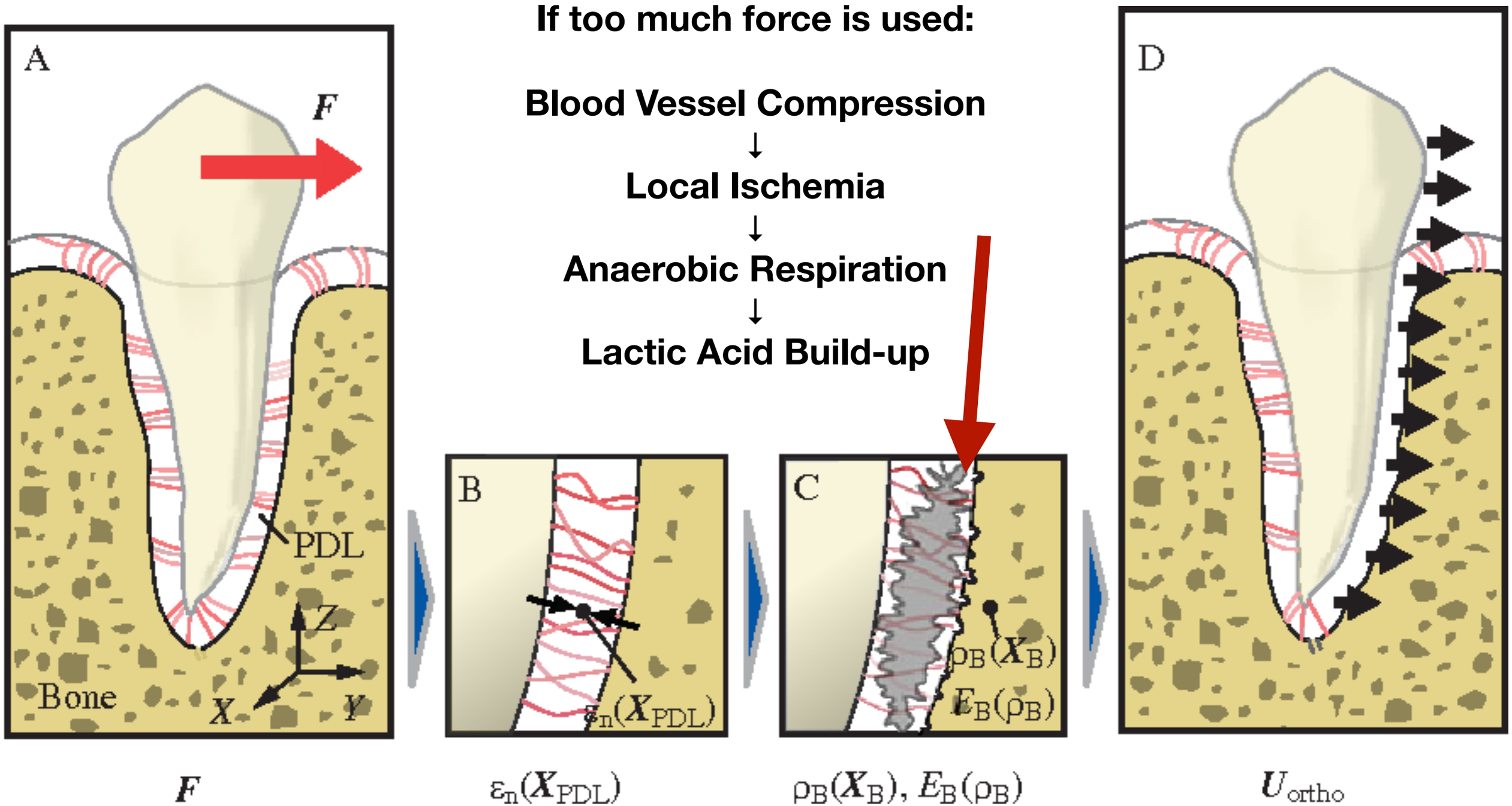

Factors that can effect tooth movement

Effects of Systemic Factors on Induced Tooth Movement

Substance	Effects on Bone Metabolism	Effects on Tooth Movement
Estrogen	↓ Bone Resorption	↓ Tooth Movement
Androgen	↓ Bone Resorption	Unproven
Relaxin	↑ Bone Resorption	↑ Tooth Movement
Thyroid Hormones	↑ Rate of Bone Remodeling ↑ Bone Resorption	↑ Tooth Movement ↓ Root Resorption
Parathyroid Hormone	↑ Bone Resorption	↑ Tooth Movement
Vitamin D	↑ Rate of Bone Remodeling ↑ Bone Resorption	↑ Tooth Movement

Nonsteroidal anti-inflammatory drugs	Effects on bone metabolism	Effects on tooth movement
Aspirin	Reduced bone resorption	Reduced tooth movement
Diclofenac	Reduced bone resorption	Reduced tooth movement
Indomethacin	Reduced bone resorption	Reduced tooth movement
Ibuprofen	Reduced bone resorption	Reduced tooth movement
Flurbiprofen	Reduced bone resorption	Reduced tooth movement
Naproxen	Reduced bone resorption	Reduced tooth movement
Celecoxib	No effect on bone resorption	No influence on tooth movement
Acetaminophen	No effect on bone resorption	No influence on tooth movement

HORMONES
Estrogens and androgen

- It controls bone remodeling during reproductive life

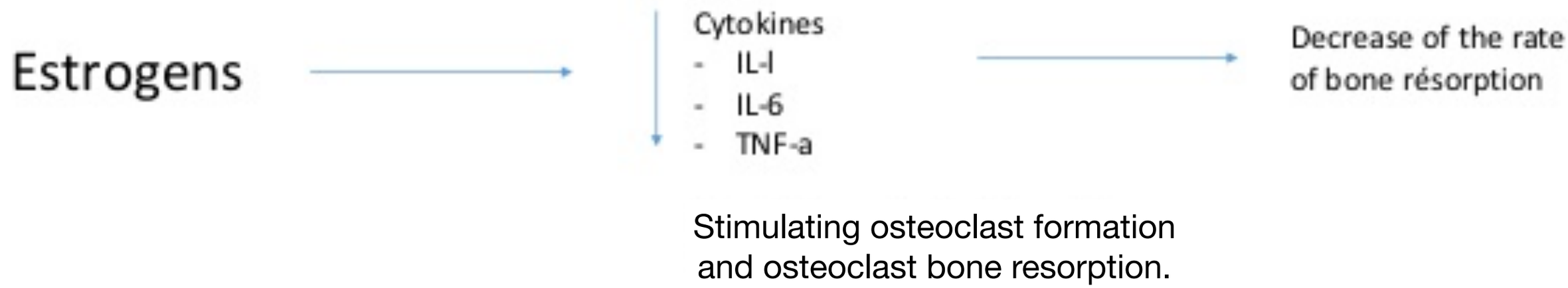

They also inhibit osteoblasts responsiveness to parathyroid hormone (PTH).

Oral Contraceptives can influence the rate of tooth movement.

Androgens may affect the length and results of orthodontic treatment.

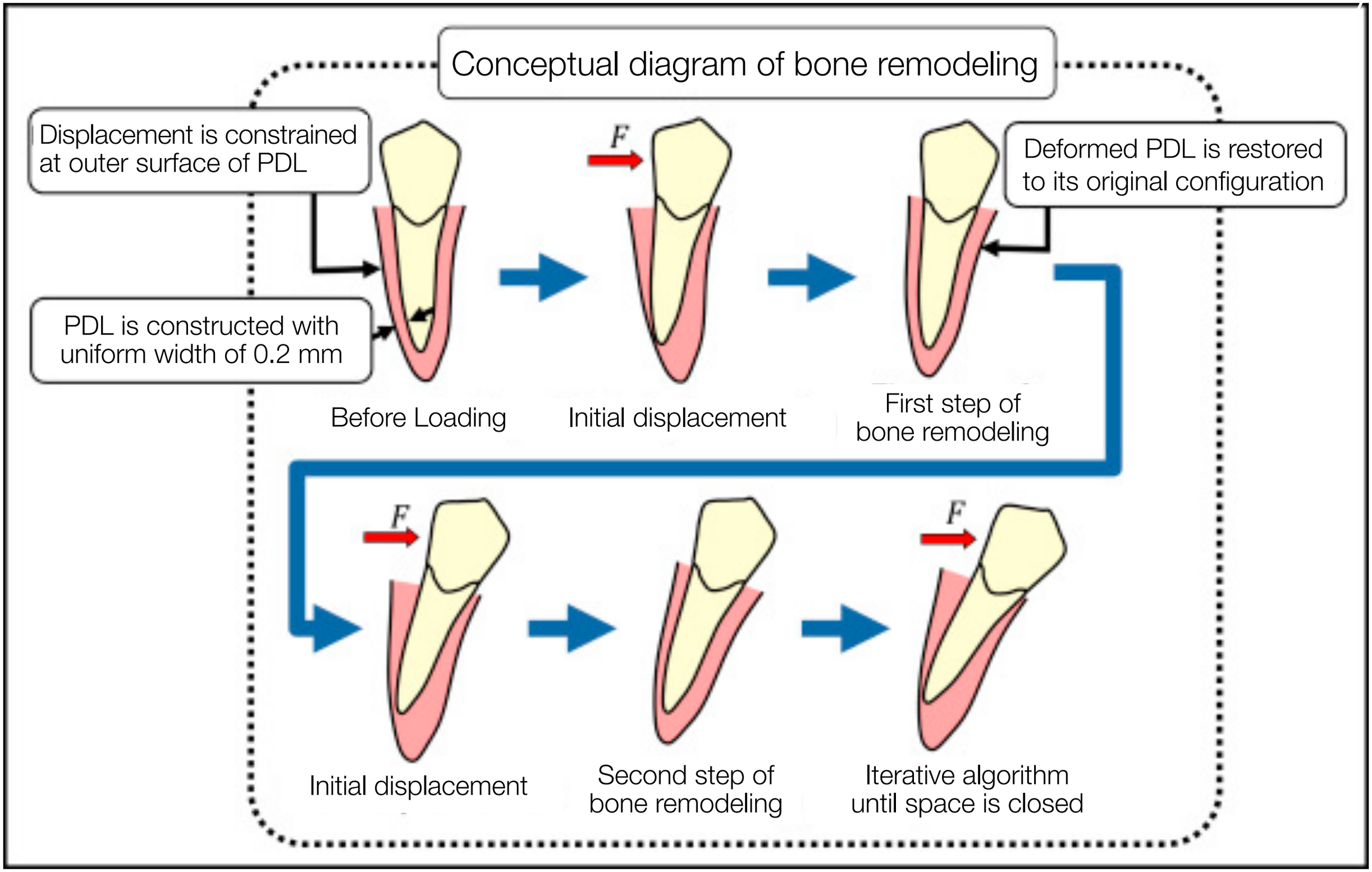
Conceptual diagram of bone remodeling
Displacement is constrained at outer surface of PDL
PDL is constructed with uniform width of 0.2 mm
F
Deformed PDL is restored to its original configuration
Before Loading
Initial displacement
First step of bone remodeling
F
F
Initial displacement
Second step of bone remodeling
Iterative algorithm until space is closed

Principle Fiber Groups

- Interradicular Group
- Apical Group
- Oblique Group
- Horizontal Group
- Alveolar Crest Group

We are coming back around. The mandible has a similar bone structure to the femur we talked about before.

So the forces placed upon the mandible (and maxilla) during growth determine its shape.

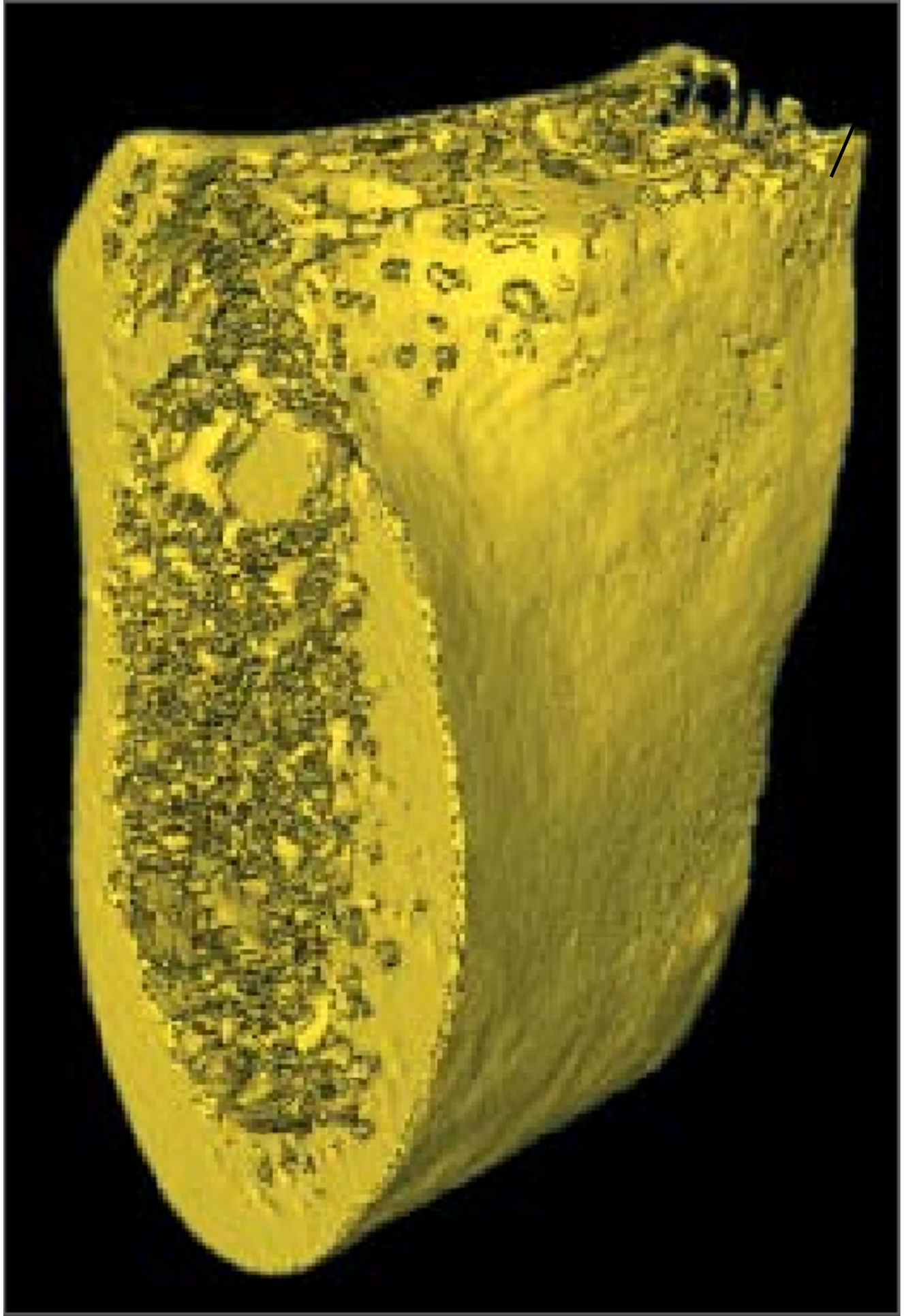

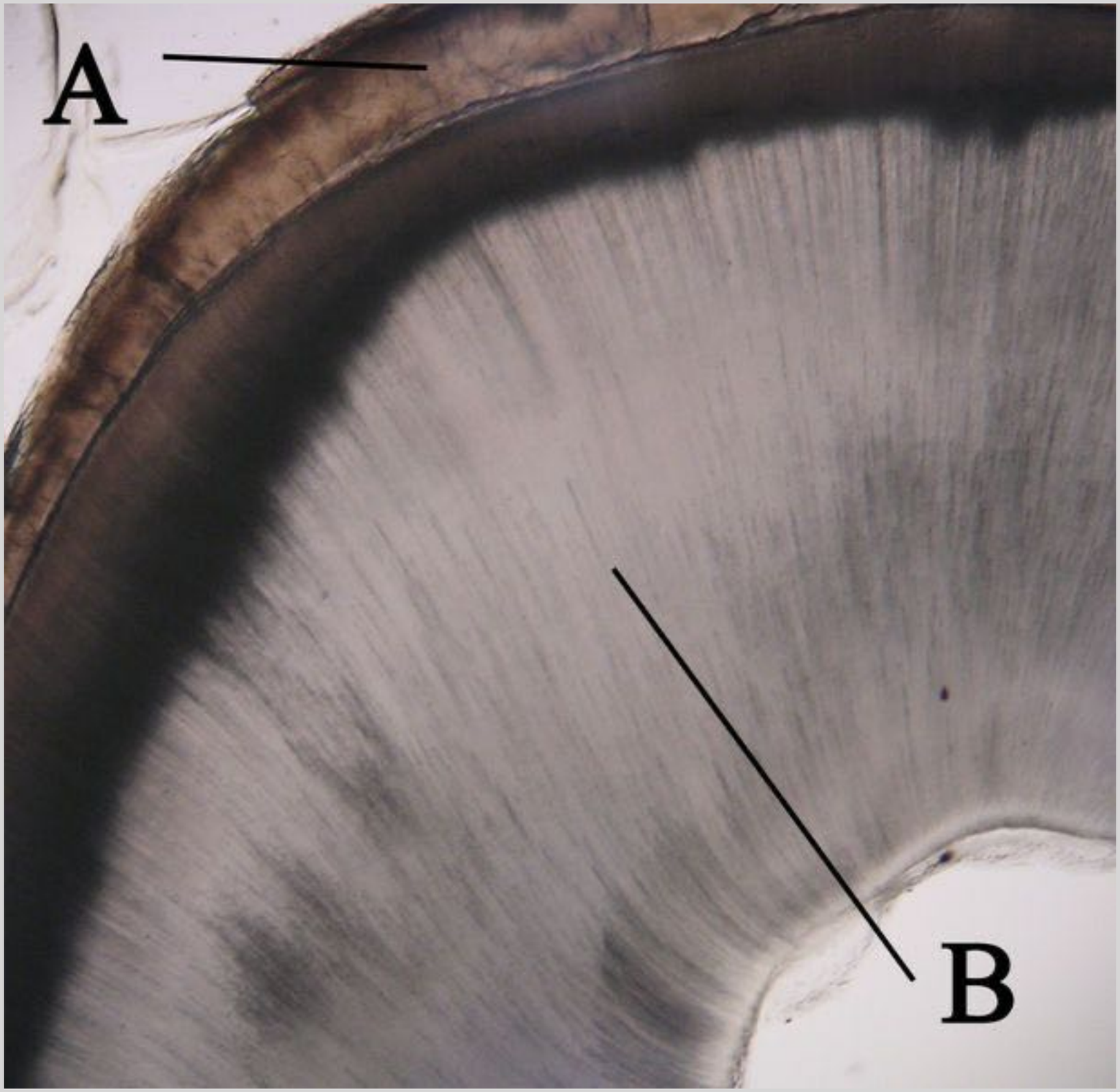

Look at this tooth again and think about how much information it can feed back into the nervous system because of its unique structure…

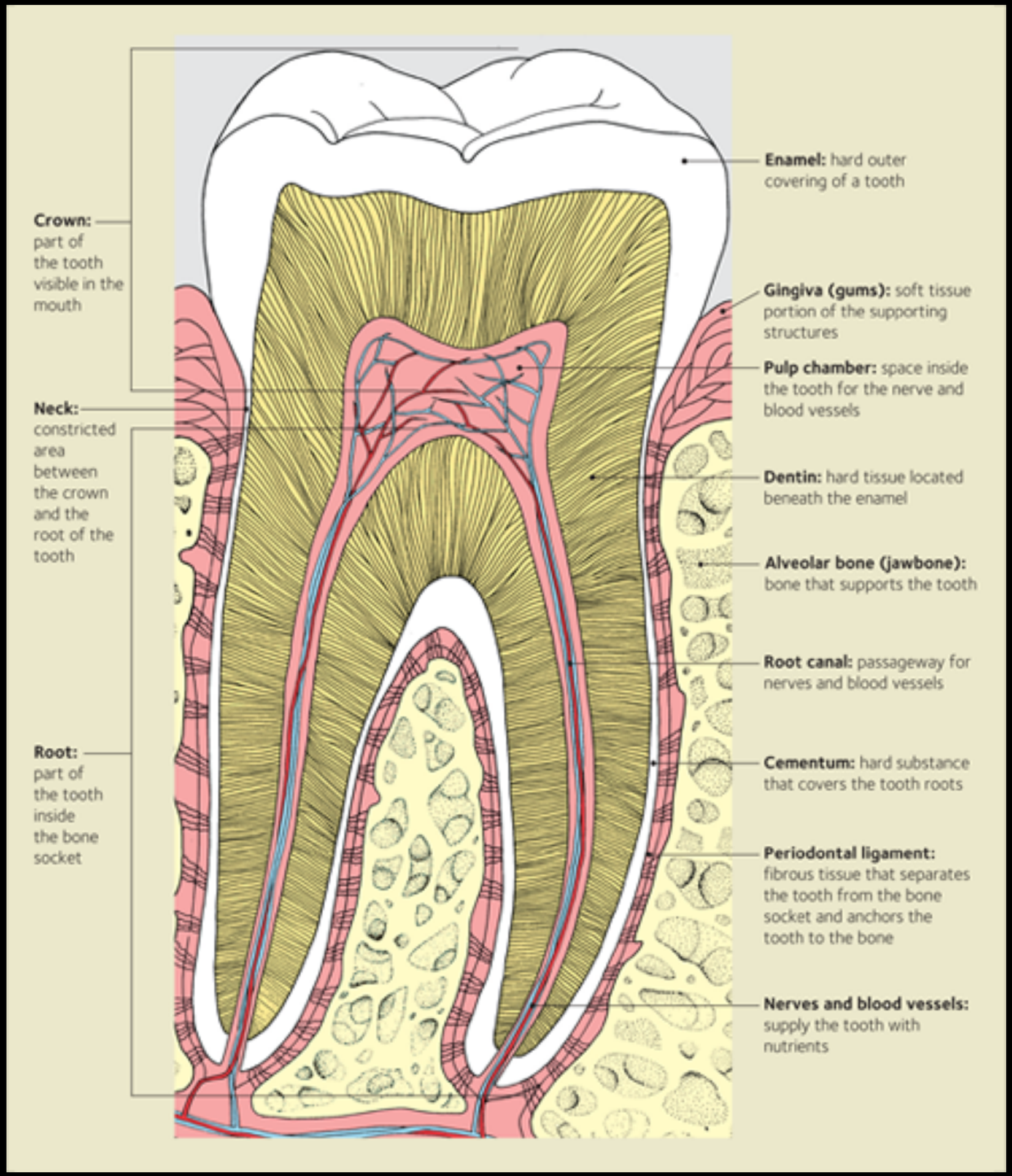
Crown: part of the tooth visible in the mouth
Neck: constricted area between the crown and the root of the tooth
Root: part of the tooth inside the bone socket
Enamel: hard outer covering of a tooth
Gingiva (gums): soft tissue portion of the supporting structures
Pulp chamber: space inside the tooth for the nerve and blood vessels
Dentin: hard tissue located beneath the enamel
Alveolar bone (jawbone): bone that supports the tooth
Root canal: passageway for nerves and blood vessels
Cementum: hard substance that covers the tooth roots
Periodontal ligament: fibrous tissue that separates the tooth from the bone socket and anchors the tooth to the bone
Nerves and blood vessels: supply the tooth with nutrients

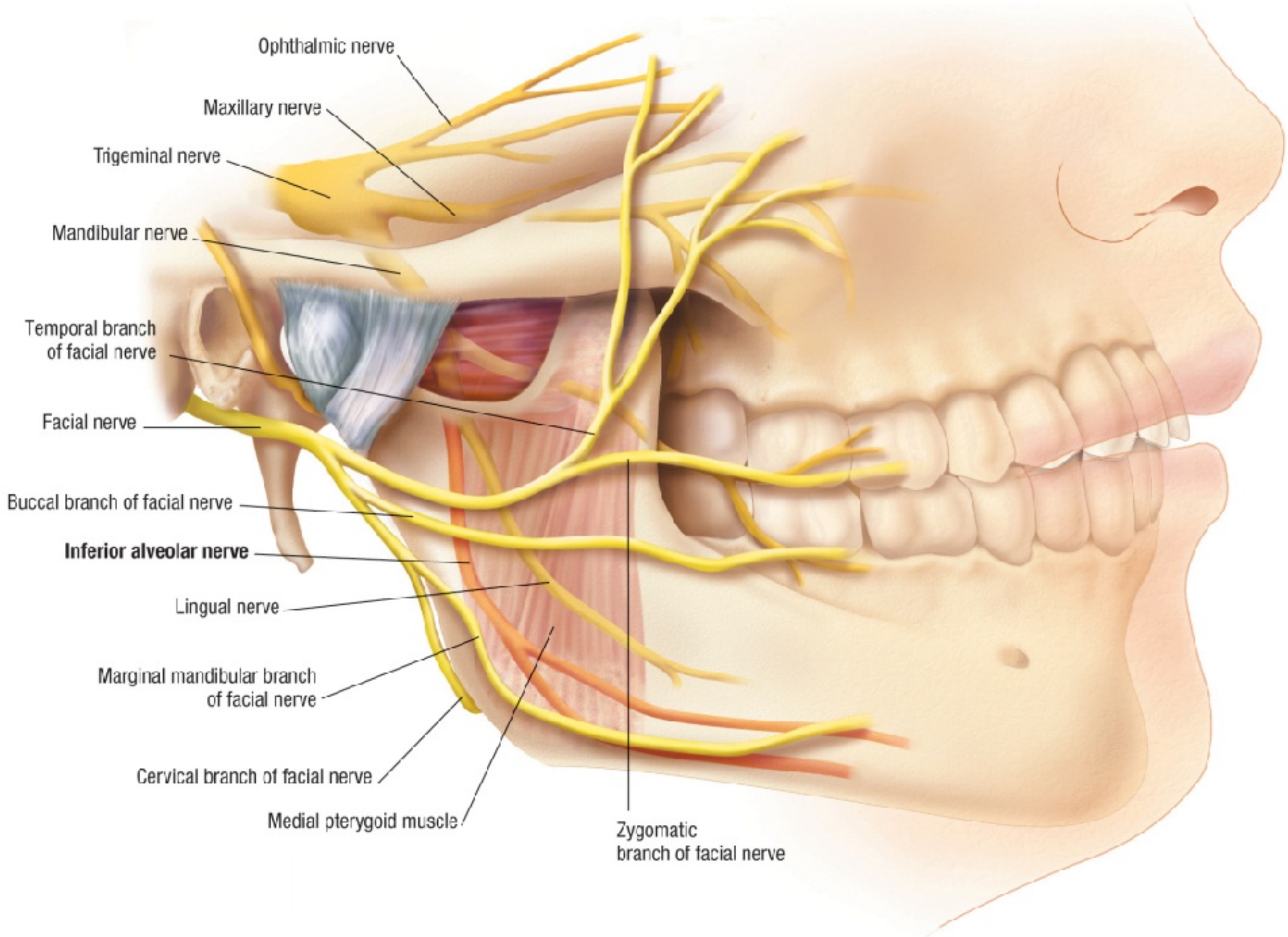
Ophthalmic nerve
Maxillary nerve
Trigeminal nerve
Mandibular nerve
Temporal branch of facial nerve
Facial nerve
Buccal branch of facial nerve
Inferior alveolar nerve
Lingual nerve
Marginal mandibular branch of facial nerve
Cervical branch of facial nerve
Medial pterygoid muscle
Zygomatic branch of facial nerve

Recap

- Hooke's Law dictates how tissues respond to forces placed upon them.
- Forces that elicit elastic behavior from the tissue cause growth and the body does not fight the forces.
- Forces that exceed the elastic portion of Hooke's curve cause "strain hardening" - we can read that as strain in the tissues and hardening in how it feels to palpation. This tells us that we have done something too far (even if it was with good intention).

Recap

- That means if we move too far and/or too fast we can cause tissue trauma and the body will respond via Hooke's law by tightening the tissue.
- This can be too much compressive force (think traditional orthodontia) or too much expansive force (think tongue tie release).
- WAY too much force causes fracture stress.

Hooke’s Law

- If we are working with the body, we need to have the end goal in sight and have a plan to reach that goal.

- In order to keep Hooke’s Law from being inadvertently exceeded, we need to TEST the patient’s body repeatedly to make sure we are not making mistakes.

If you exceed Hooke’s Law if takes effort to return to balance.

418210

GARFIELD

BEWARE OF THE DOG
WHO SOMEHOW MANAGED TO...
GET DENTISTRY TOOLS
NEXT!
JIM DAVIS 7-20
www.facebook.com/garfield
Distributed by Universal Uclick
© 2012 PAWS, INC. All Rights Reserved.

Tooth Dysfunction

for Appliance/ALF Adjusting

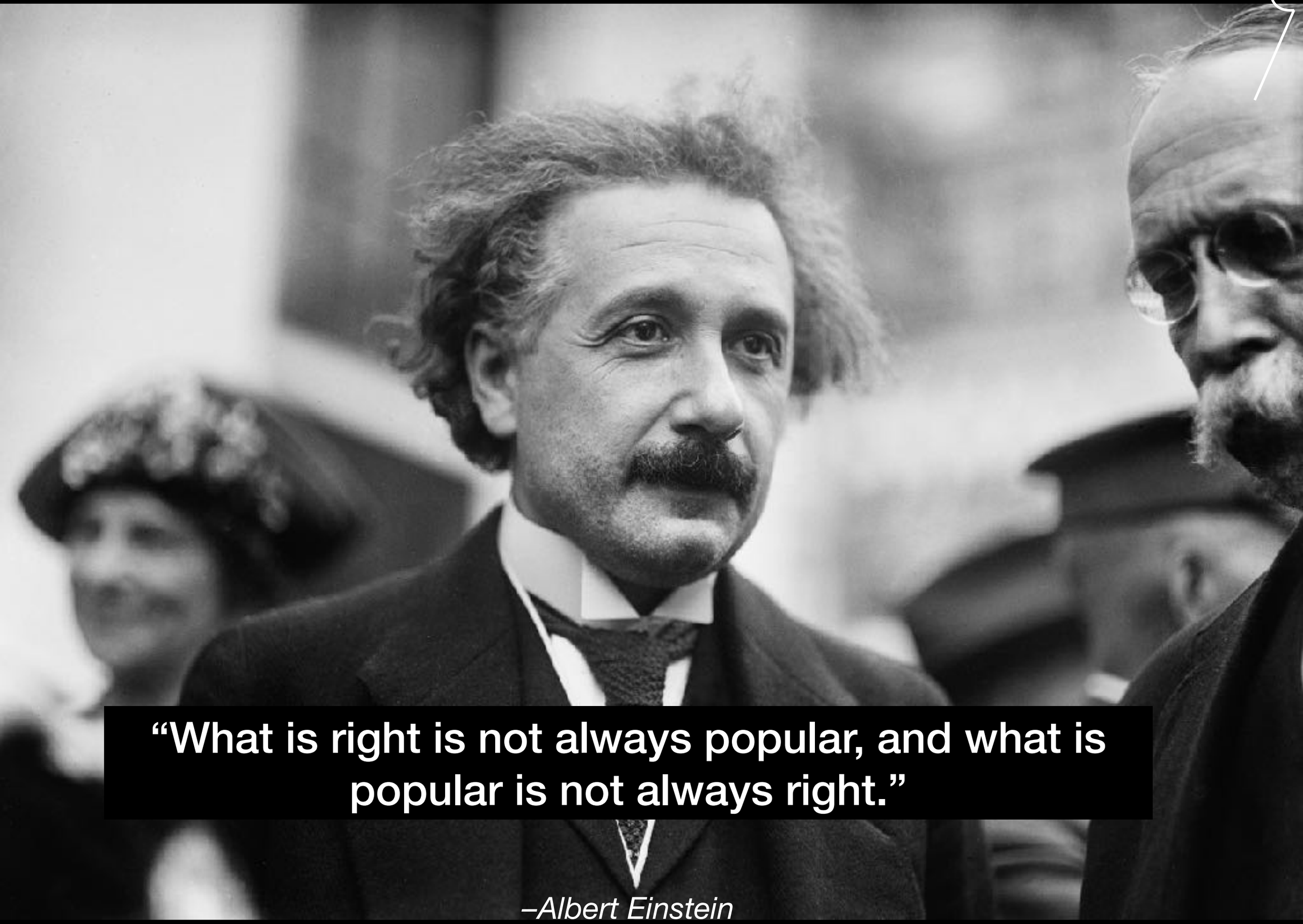

“What is right is not always popular, and what is popular is not always right.”

–Albert Einstein

If a tooth won’t move…

- Because the appliance is pushing against it and the tooth is resisting
- Because there is tooth pain
- Because there is altered function
- Because the body it pushing back at you or fighting you in one location
- Because the tooth is out of optimal position

Consider that the issue may be with a single tooth or its supporting structure.

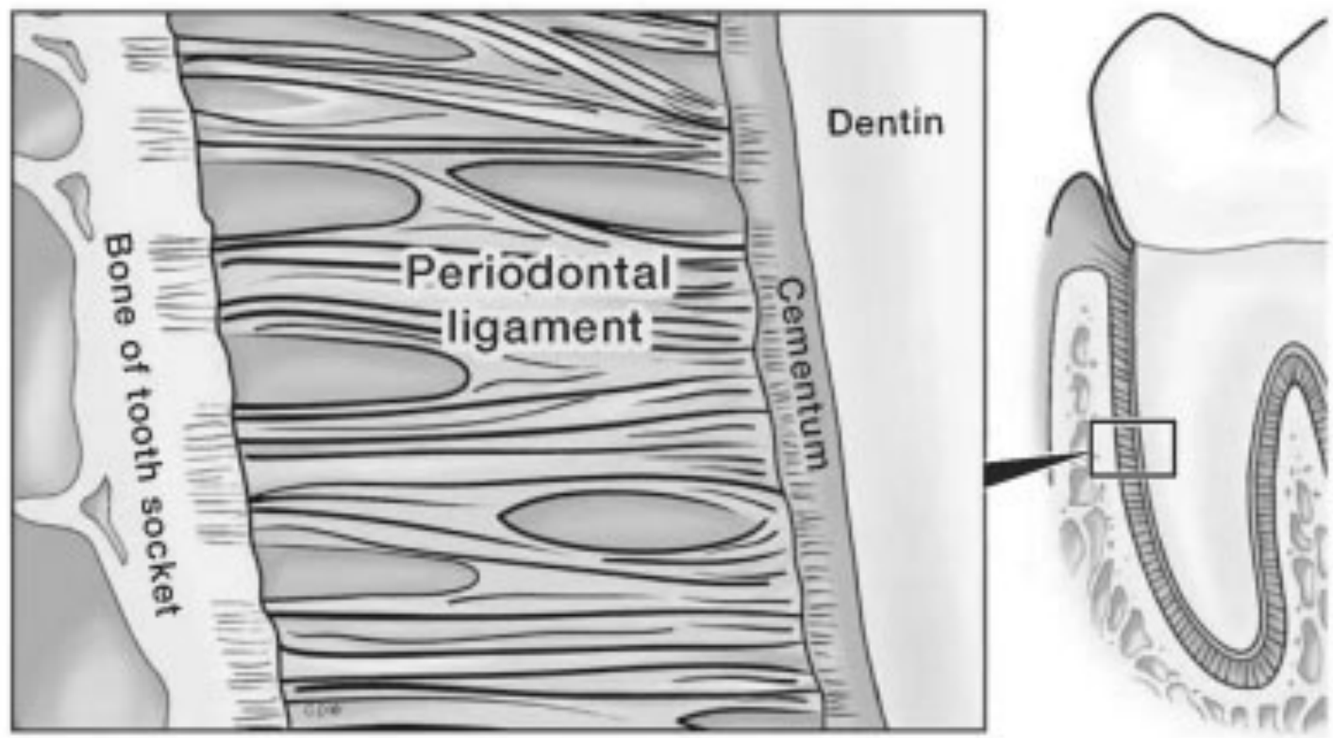

Figure 1.13. **Periodontal Ligament.**

- On the bone side, the ends of the periodontal ligament fibers are anchored in the alveolar bone of the tooth socket.
- On tooth side, the ends of the periodontal ligament fibers are anchored in the cementum of the root.

Periodontal Ligament

It supports the tooth in its surrounding bone

The fibers have different names depending on where they are located

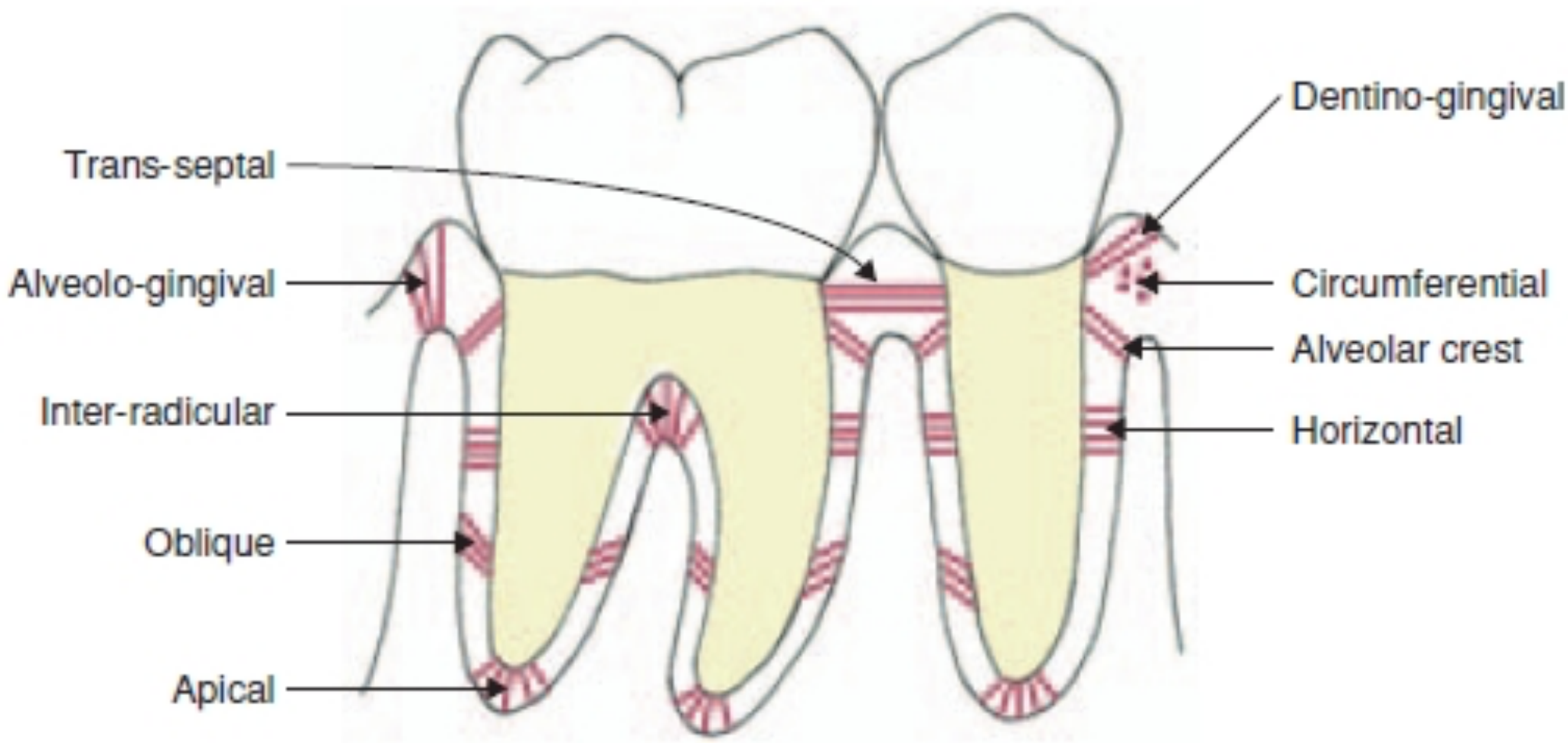

And different directions they anchor or can influence

Course of the gingival fiber bundles (see also Fig. 21)

1 Dentogingival
- Coronal
- Horizontal
- Apical

2 Alveologingival
3 Interpapillary
4 Transgingival
5 Circular, semicircular
6 Dentoperiosteal
7 Transseptal
8 Periosteogingival
9 Intercircular
10 Intergingival

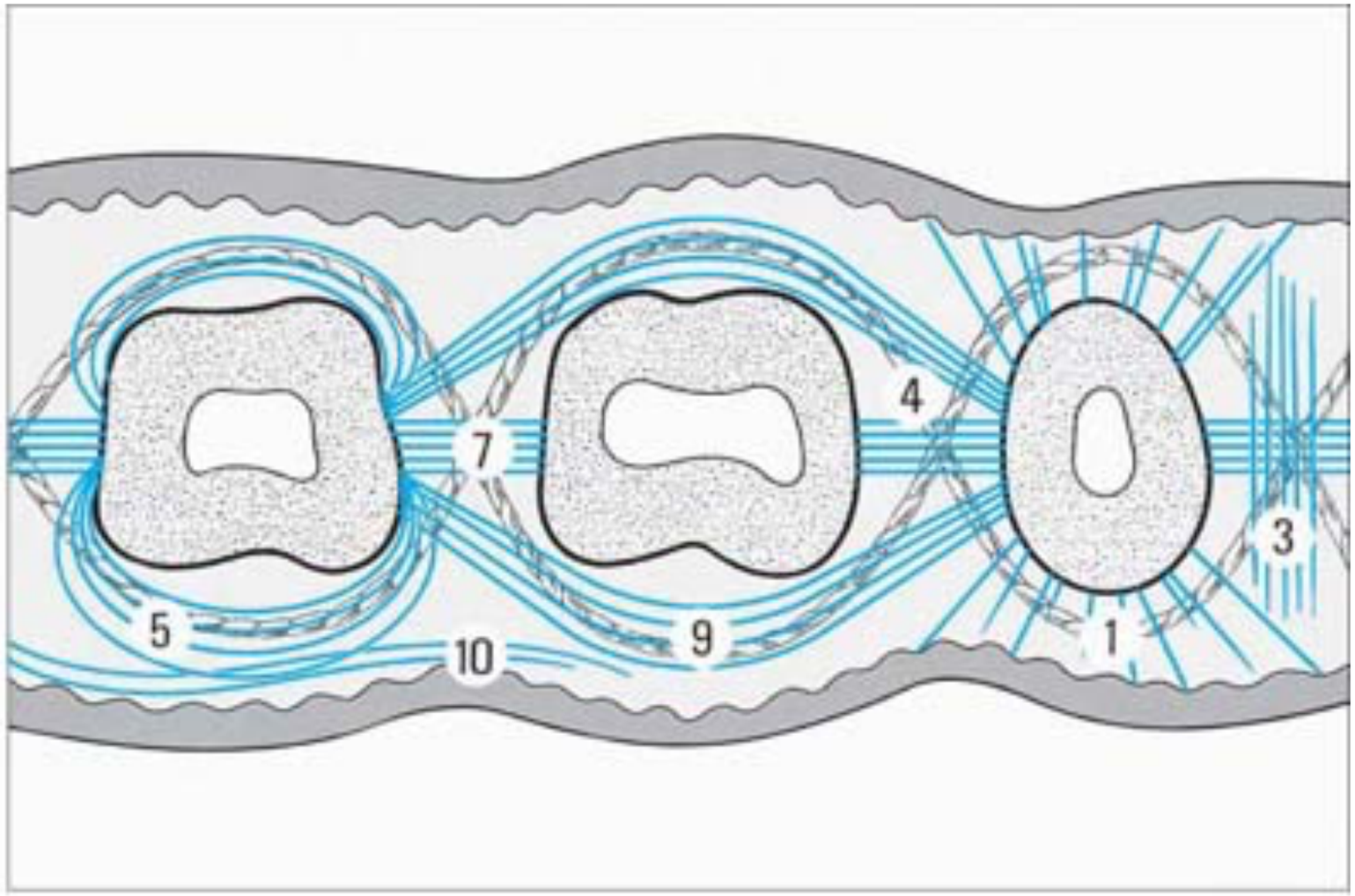

Ligament Trauma

- Osteopathically, when a ligament gets traumatized, it shortens (tightens). This can lead to pain and altered motion.
- Dentally, this can alter the normal motion of a tooth, cause pain or frustration…
- Treatment is to release or unwind the tension in the ligament.

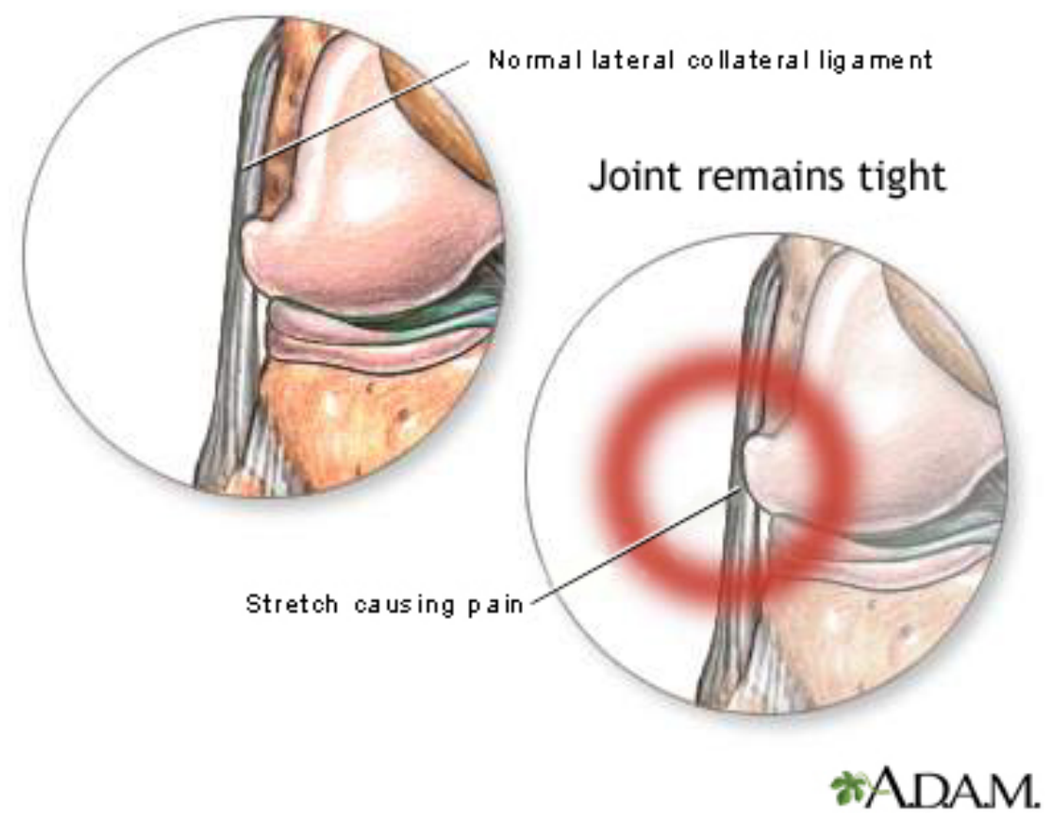

Ligament Dysfunction

- Fortunately, each dysfunction has specific anatomy that is involved and shows up slightly differently to palpation.

- That makes testing straightforward.

Normal Palpation

- When the teeth move freely, palpation of an individual tooth, a group of teeth, the alveolar ridge or the supporting bone around a tooth should feel should feel pliable and without giving a sensation of being pulled in any direction.

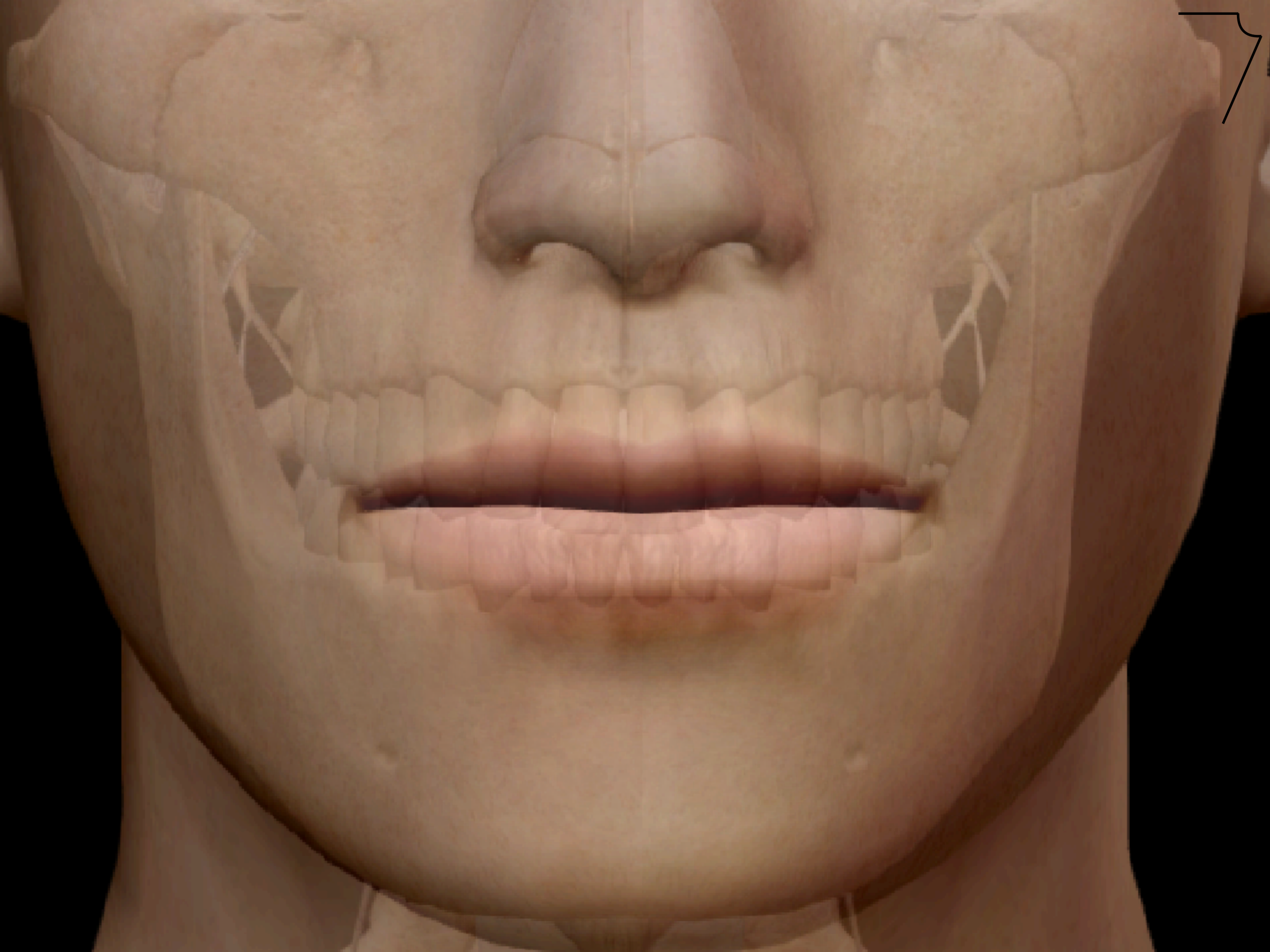

Periodontal Ligament

- If this ligament is tight, the tooth won’t move freely in its socket.
- One or more of the following motions is restricted: anterior/posterior, mesial/buccal, clockwise/ counterclockwise rotation when testing the tooth in its socket.
- The palpatory tension shows up at the gingival border

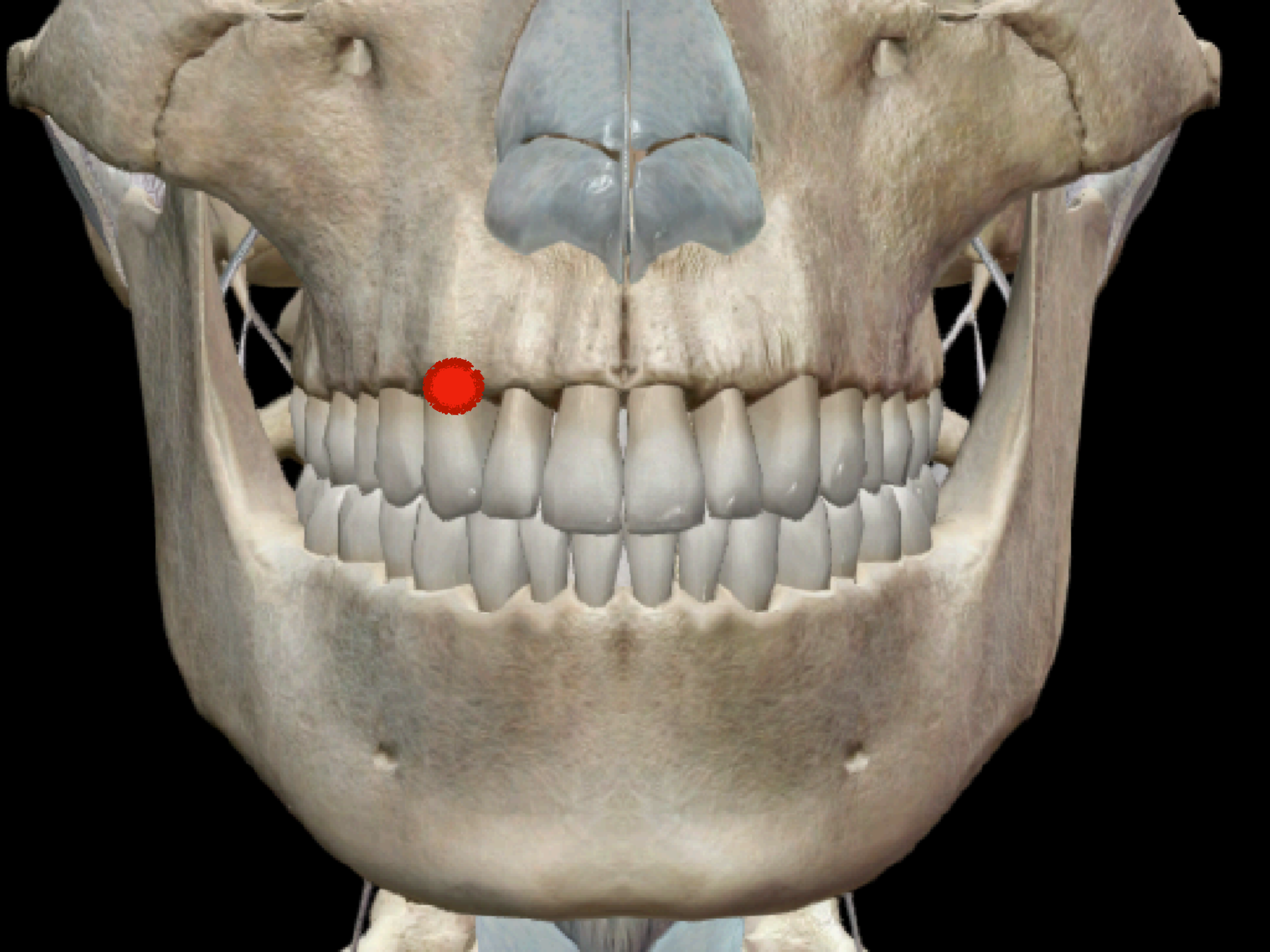

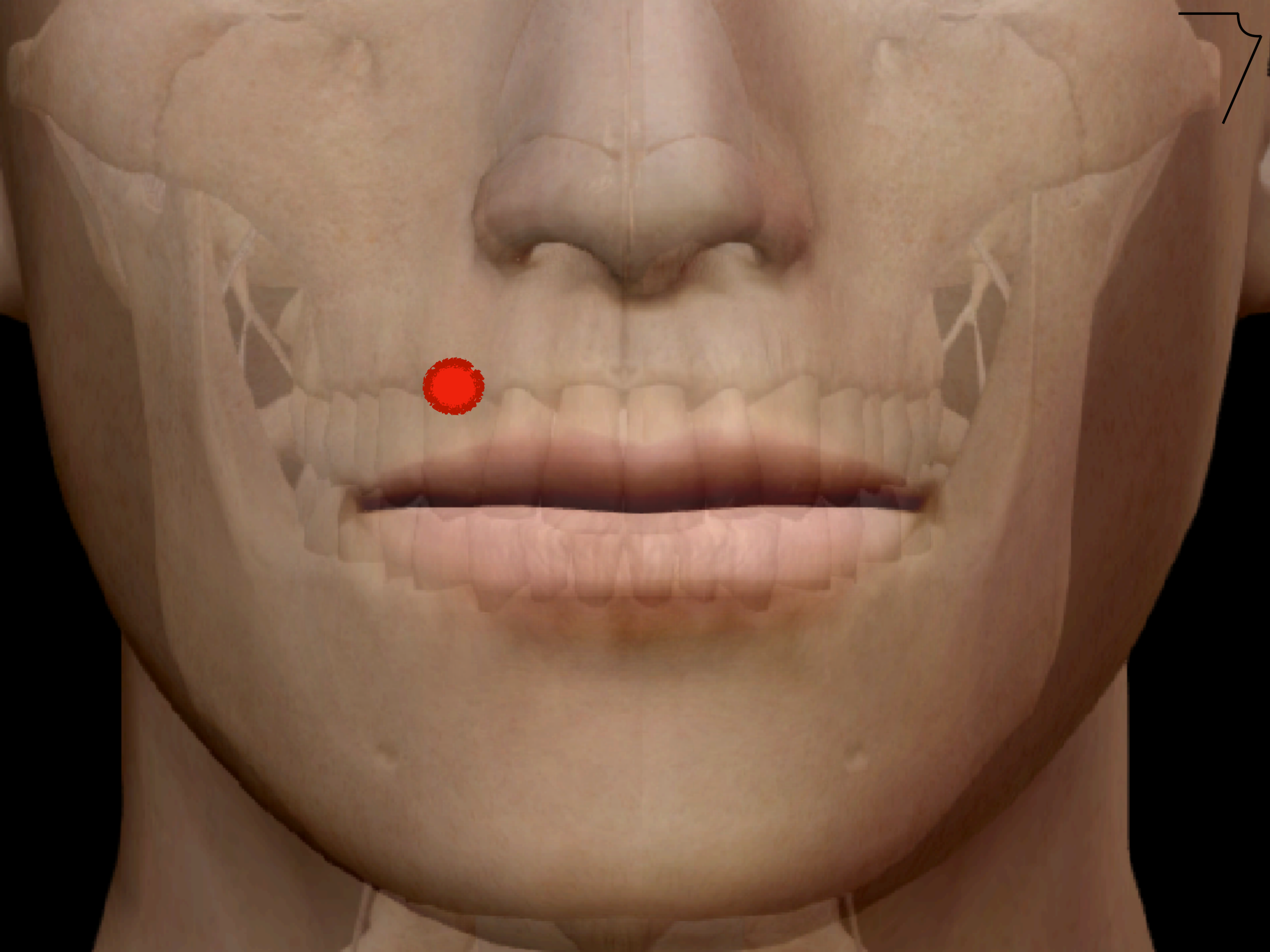

Other Ligaments

- If ligaments other than the periodontal ligament are tight, the tooth won’t move freely in its relationship to its neighbor.
- One or more of the following motions is restricted: anterior/posterior, mesial/buccal, clockwise/ counterclockwise rotation, approximation/distraction when testing one tooth in relation to its neighbor.
- The palpatory tension shows up at the gingival border of multiple teeth

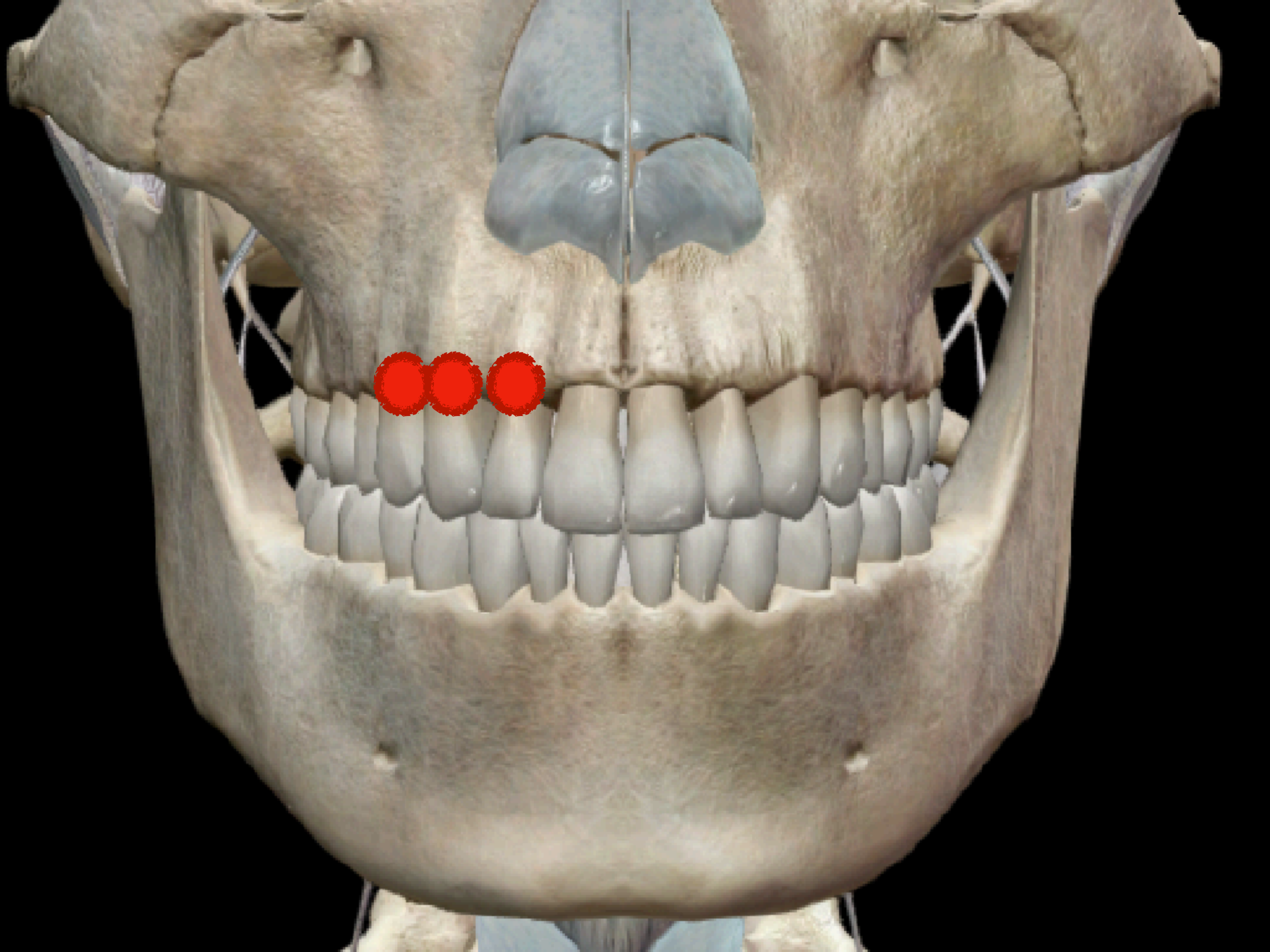

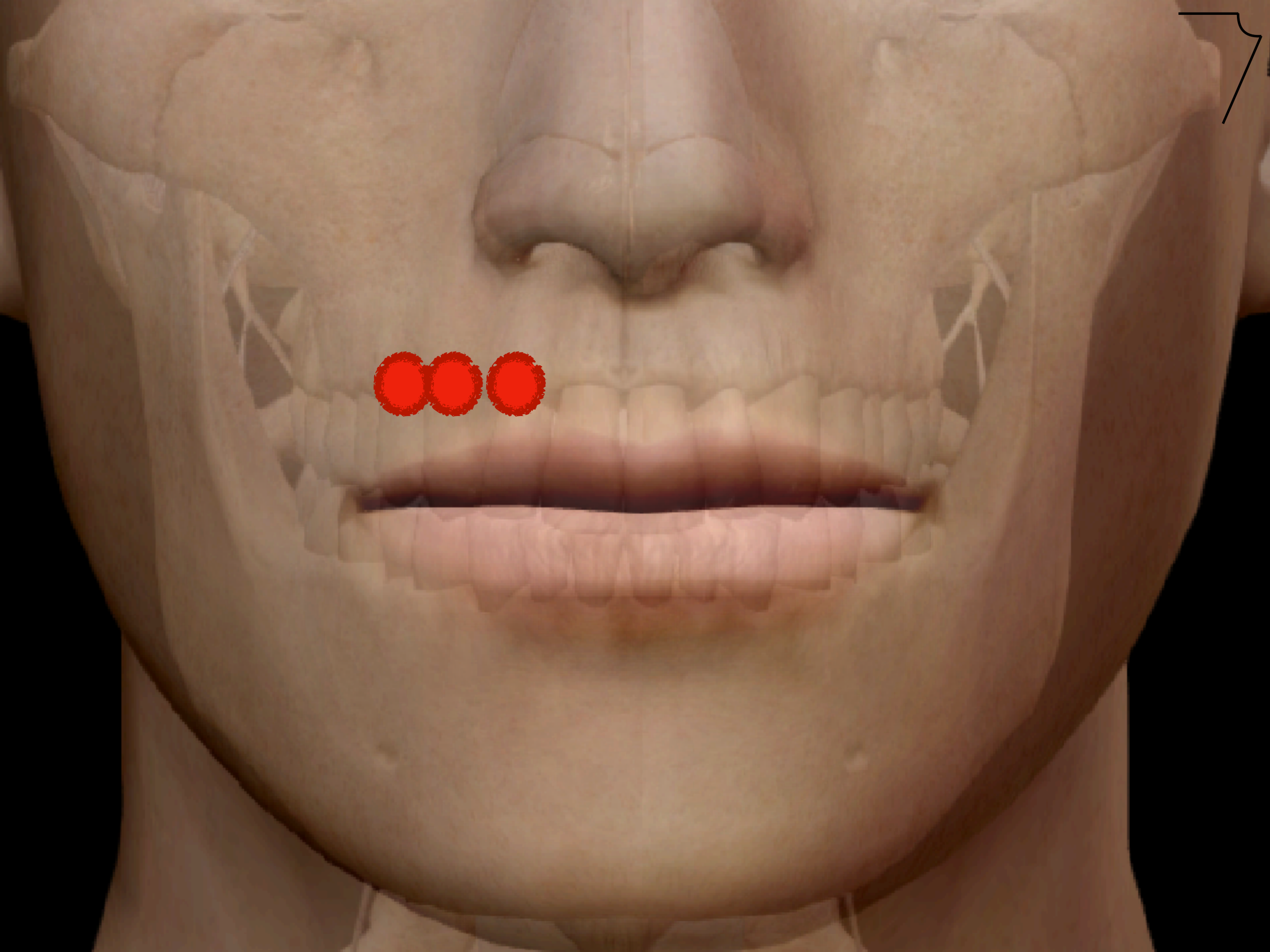

Embryologic Strain in the Supporting Bone

- If the alveolar ridge is involved, multiple teeth will be affected and their movement will be altered.
- One or more of the following motions is restricted: anterior/posterior, mesial/buccal, clockwise/ counterclockwise rotation, approximation/distraction when testing a group of teeth.
- The palpatory tension shows up at the ABOVE the gingival border of multiple teeth

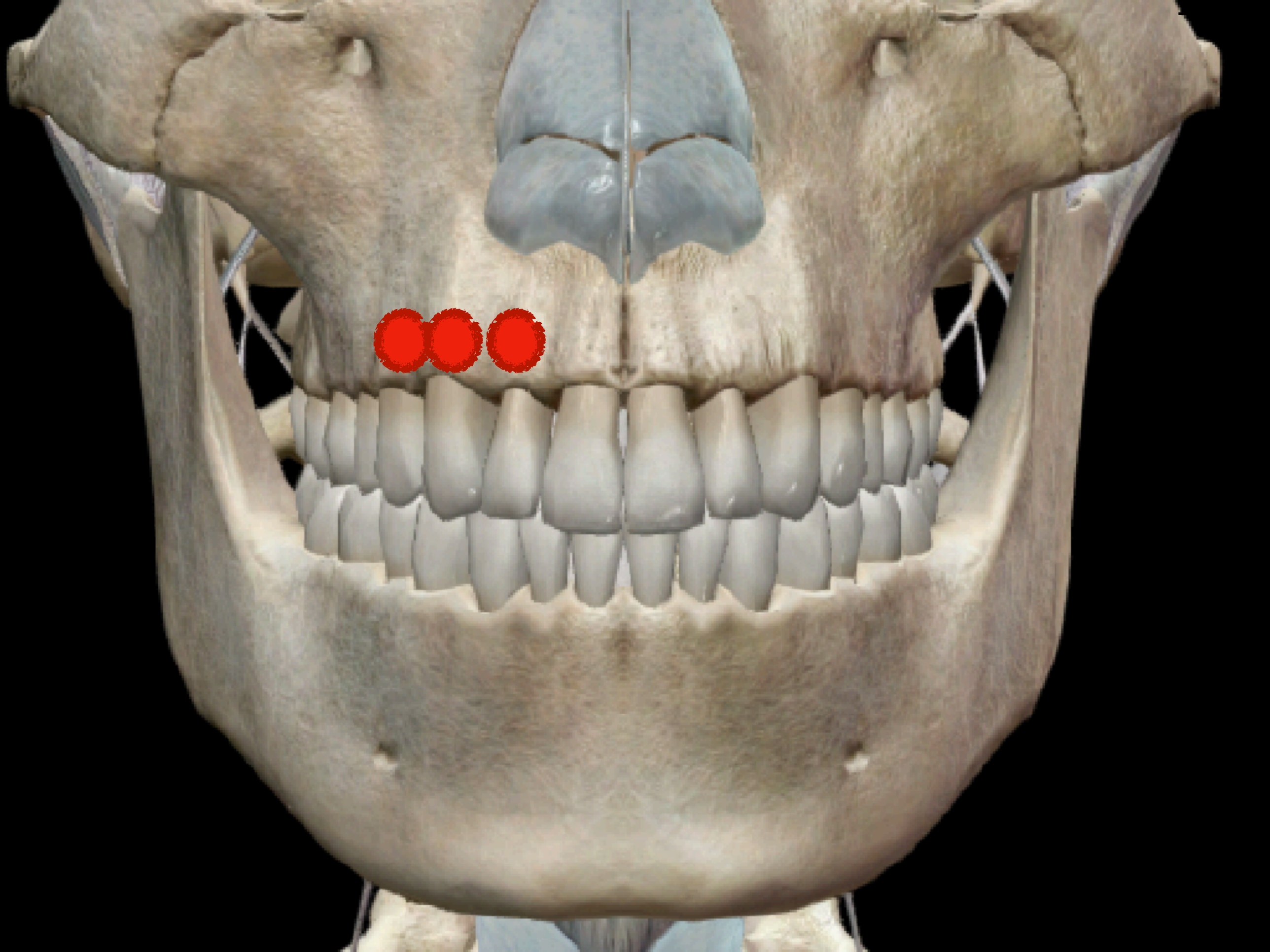

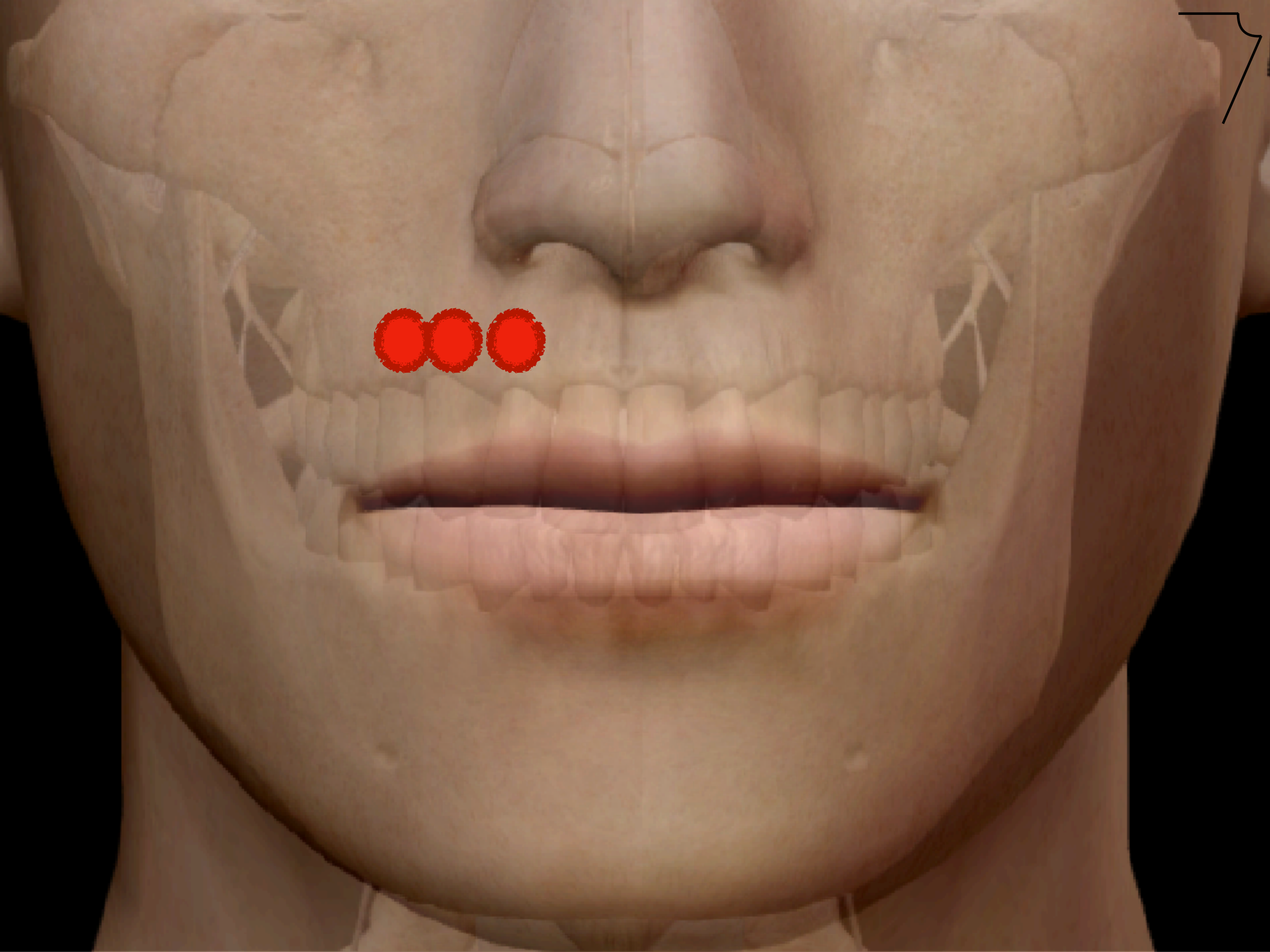

Embryologic Strain in the Tooth

- If an embryologic portion of the tooth is involved:
- One or more of the following motions is restricted in one or more cusps of the tooth: anterior/posterior, mesial/buccal, clockwise/counterclockwise rotation, approximation/distraction when testing a within the tooth.
- The palpatory tension shows up at the in one or more cusps of the tooth.

Intraosseous Strain in the Supporting Bone

- If the bone itself has received trauma, it will feel hard in that location when compared with the surrounding area.
- Connective tissue gets pulled into the area of trauma - this can affect a large area.
- The palpatory tension shows up in a focal area of the supporting bone

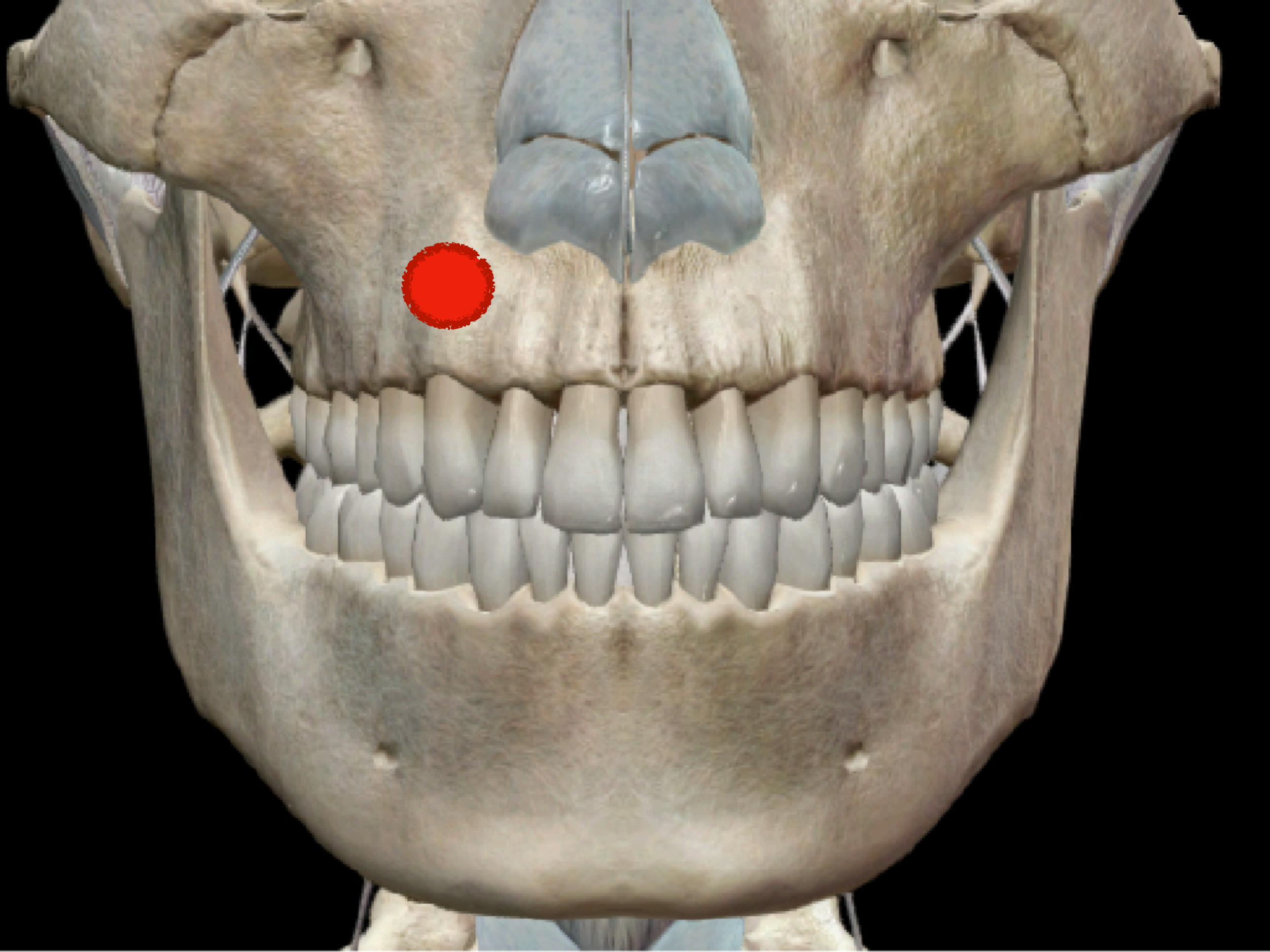

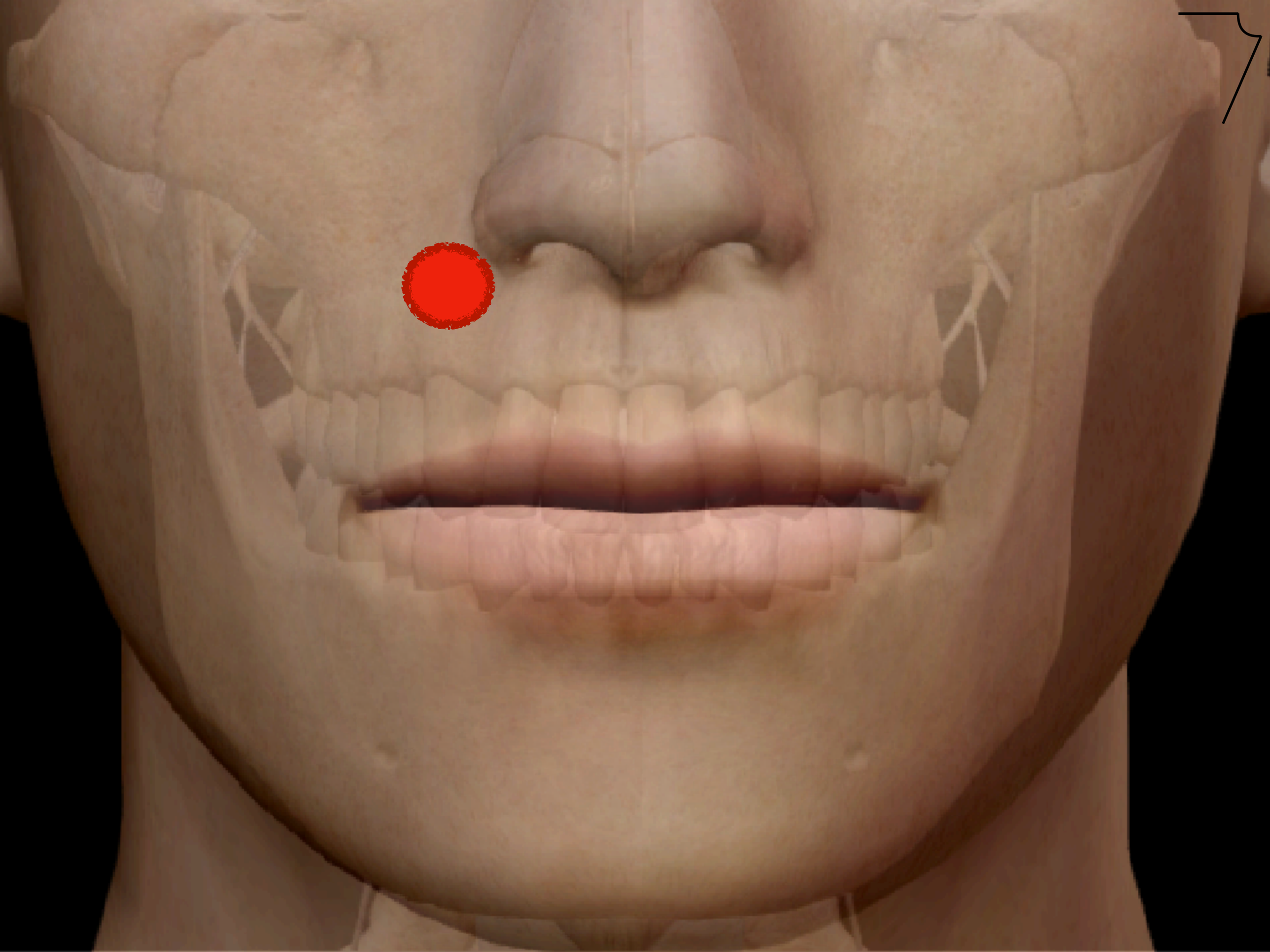

Intraosseous Strain within the Tooth

- If the tooth itself has received trauma, it will feel hard over the entire tooth.
- The palpatory tension shows up as the entire tooth feeling hard. Within that tension there is a focal area which is harder (which is what gets treated).

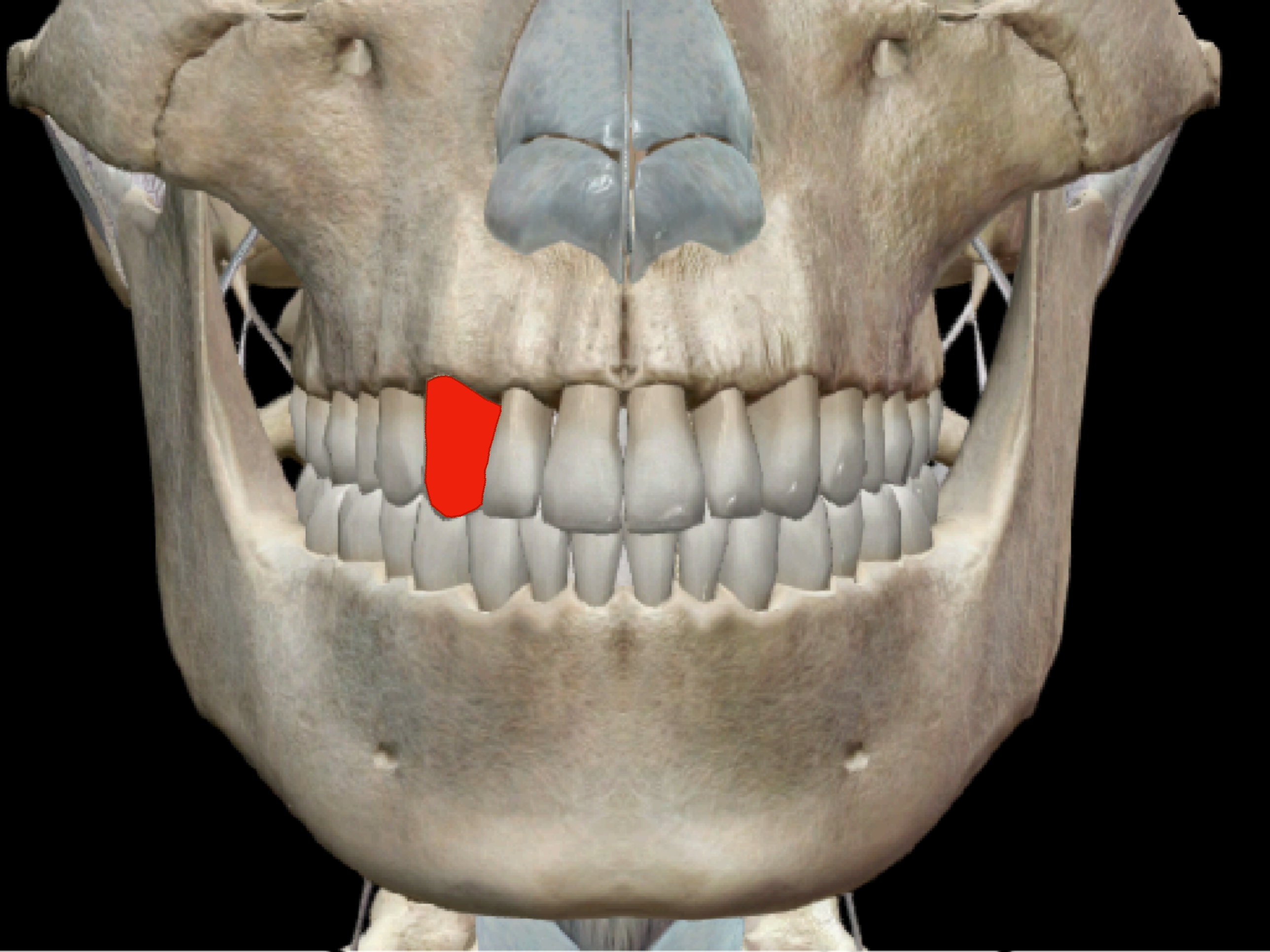

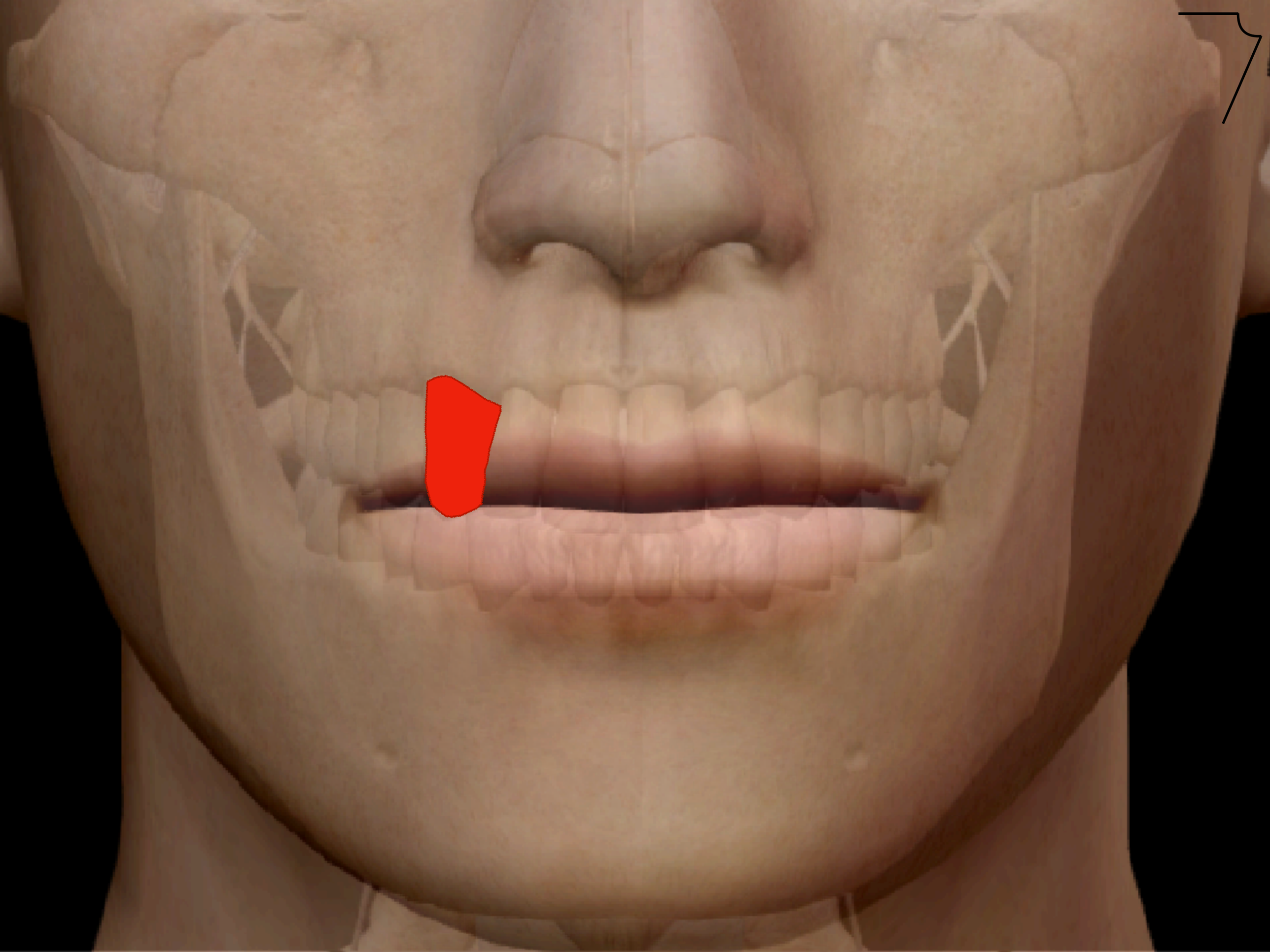

Cavitation

- An infection below the gum line is known as a cavitation
- It can be found using palpation

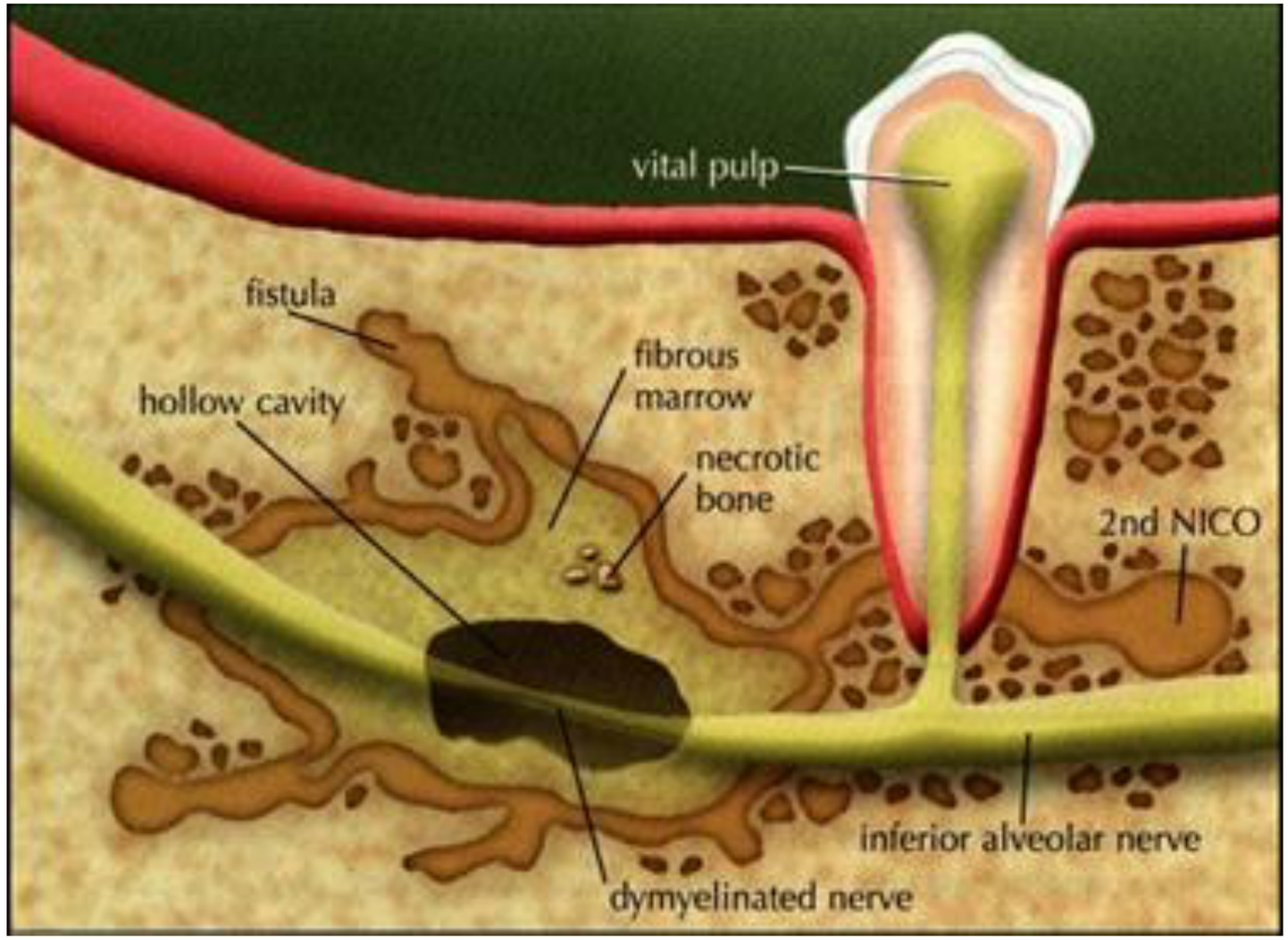

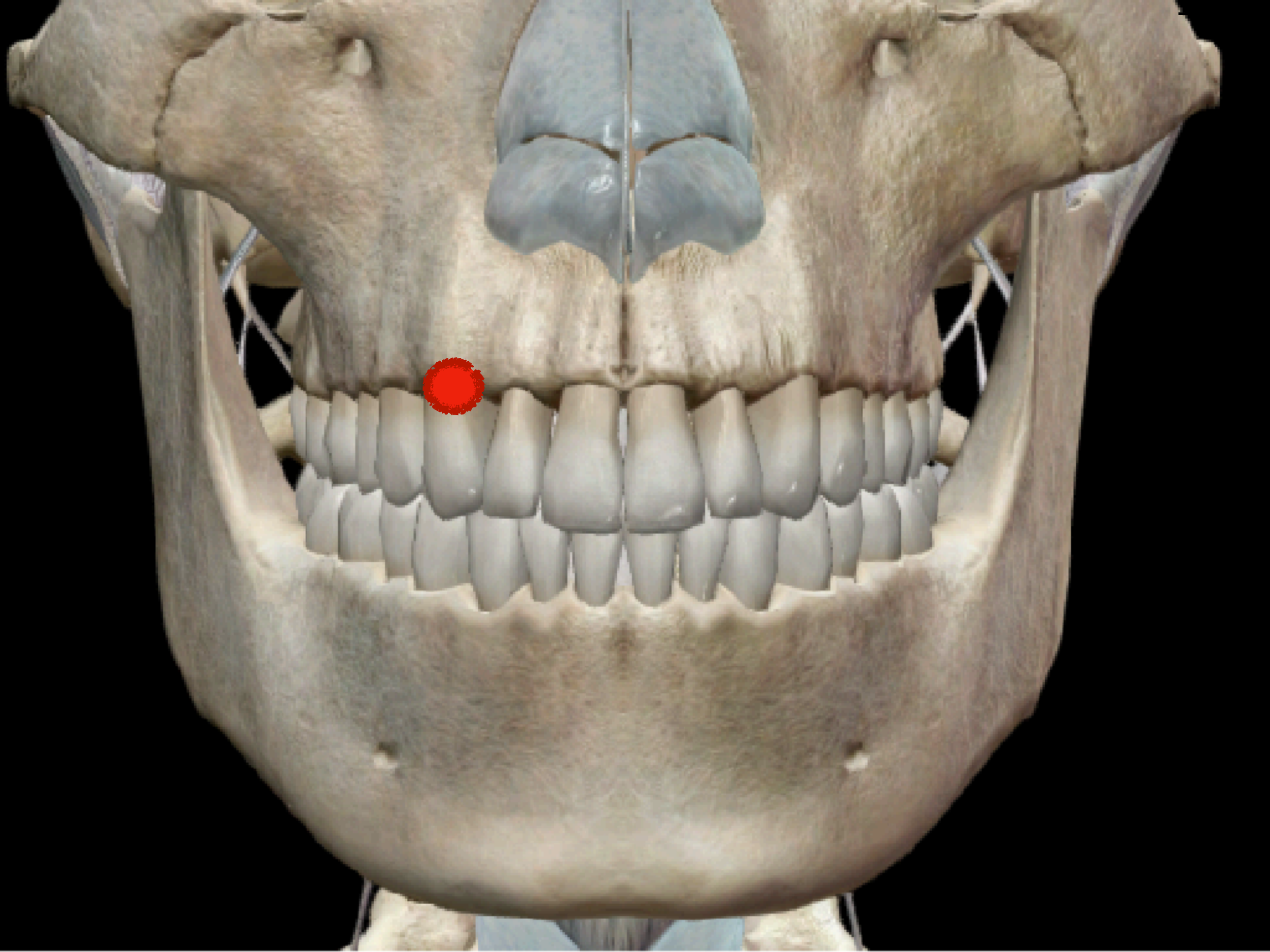

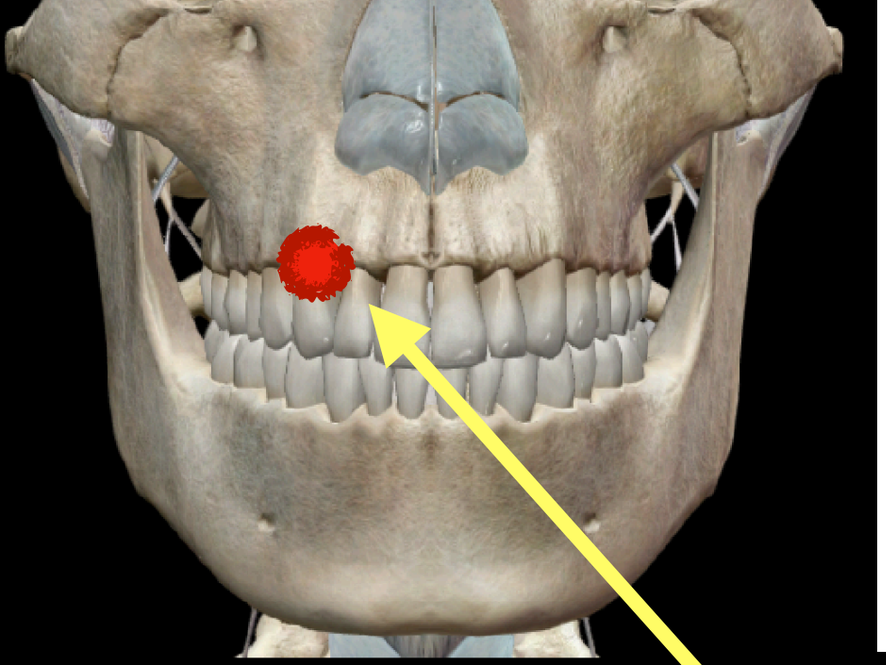

And is found by placing
one hand over the heart,
while the other tests the teeth

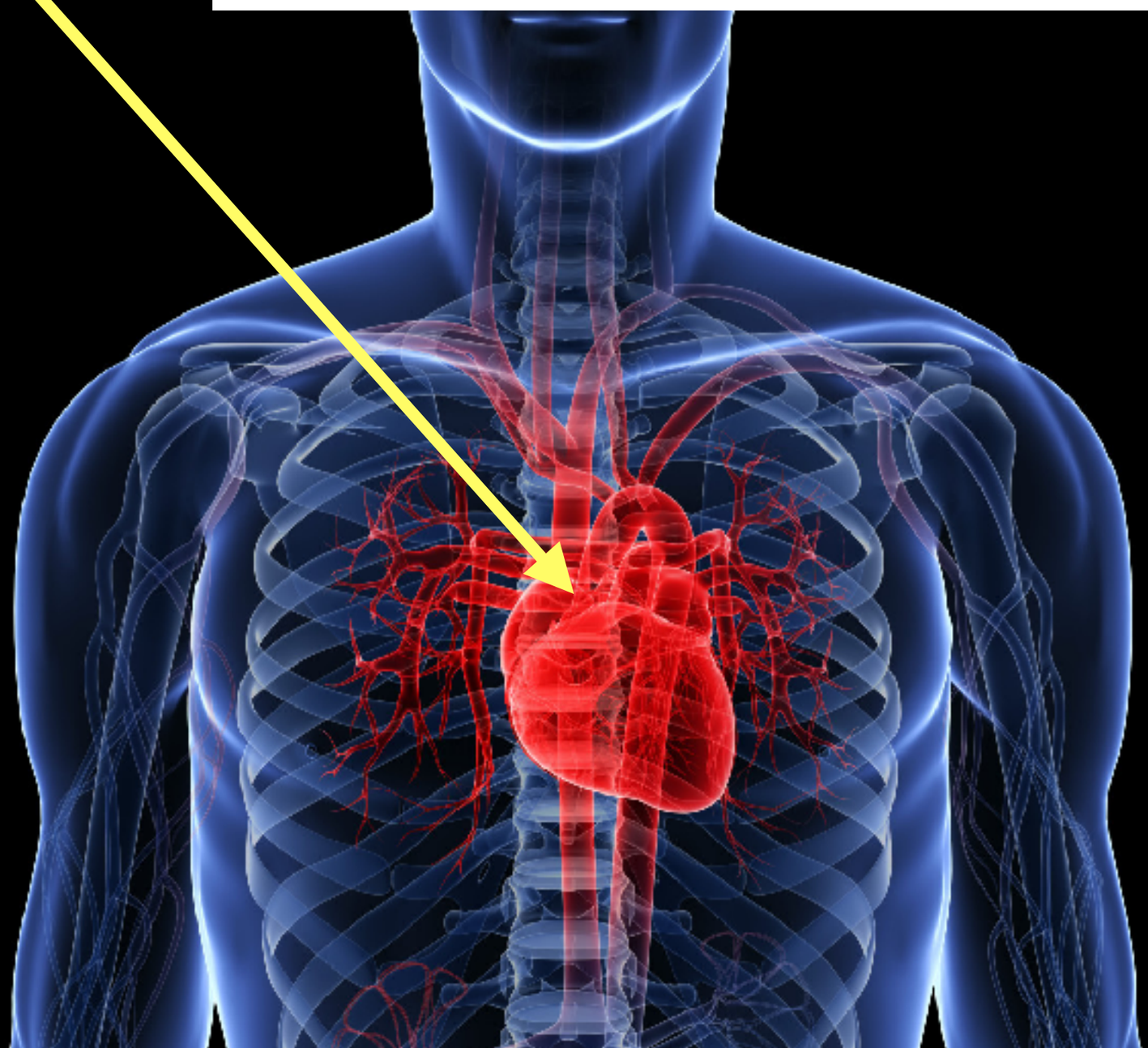

Cavitations

- A positive test for a suspected cavitation results in a fluttering feeling over the heart when the suspect tooth (or teeth) are palpated.
- These areas should be evaluated with further tests to confirm the presence of an infected area.

Cavitations

- Things that may lead you to think of (or really need to evaluate for) cavitations:
  - Bruxing/Parasites
  - Teeth that will not move in an appliance (constantly breaking appliances, grinding through them, etc.)
  - ANY KIND OF DISEASE THAT YOU CANNOT <u>SIMPLY</u> EXPLAIN (heart disease, kidney disease, etc).

Lab

Tooth Dysfunction Lab

- To begin, just pick a tooth. Place a finger on its biting surface and gently try moving it: anterior/posterior, mesial/buccal, clockwise/counterclockwise rotation.

- If any of those motions are restricted, you may treat the tooth.

- Treatment involves taking the tooth to its position of ease and waiting for release (stack the motions it CAN do and wait for release).

Tooth Dysfunction Lab

- Visual assessment of teeth looking for strain patterns
- Putting pressure on each tooth to get strain patterns
- Dental wedges (wedges with rubber bands connecting)?
- Pressure on upper and lower lip
- Shims on teeth - relate to appliance adjustments

Basic Appliance/ALF Adjusting



“Education is not the learning of facts, it’s rather the training of the mind to think.”

–Albert Einstein

Osteopathic Strains Caused by Dental Occlusion

- These strains are caused when (and only when) the occlusal surfaces of the teeth come into contact.
- They are not present when the teeth are separate.
- Osteopathically, these are dental in origin and a result of occlusal strains.

Dental Occlusal Strains

- They are usually caused by a tooth which has rotated in its socket, causing premature contact (and thus, the body tries to get out of the way of the tooth).
- They can also be caused by trauma (auto accidents, tooth extraction), dental work (crowns, caps or veneers), orthodontia, or appliances.

Dental Strains

- These strains ONLY occur when the occlusal surfaces meet, or when an appliance is placed in the mouth. (Dental Occlusal Somatic Dysfunction)
- Each affected tooth will initiate a cranial strain pattern when occlusion occurs.
- They are simple to identify and correct if you know what teeth cause what strain patterns...

Dental Strains

- They may or may not elucidate pain from the patient.
- They are most likely related to nerve irritation caused by the tooth contact (V2 or V3).

Basic Dental Evaluation

An Osteopathic Approach

Basic Dental Evaluation

- First we would like to determine if your patient is a good candidate for an appliance/orthodontia WITHOUT first getting an osteopathic treatment.

Basic Dental Evaluation

- The thought process is:
  - If your patient moves well in their head and body, they may not need osteopathic evaluation/ treatment first.
  - If they are not moving well, then both you (because they will need less dental work) and the patient (because everything you do will be easier), would benefit from an osteopathic evaluation and treatment.

Basic Dental Evaluation

- If the patient moves well in all, or most of these tests, then they may be able to receive dental work without a treatment first. (the idea being that their cranium and mouth are moving fairly well).

- If the patient does not move well in most, or all of these tests, then refer them to your osteopath (or treat them yourself).

The Dental Link to Cranial Strain Patterns

Flexion/Extension

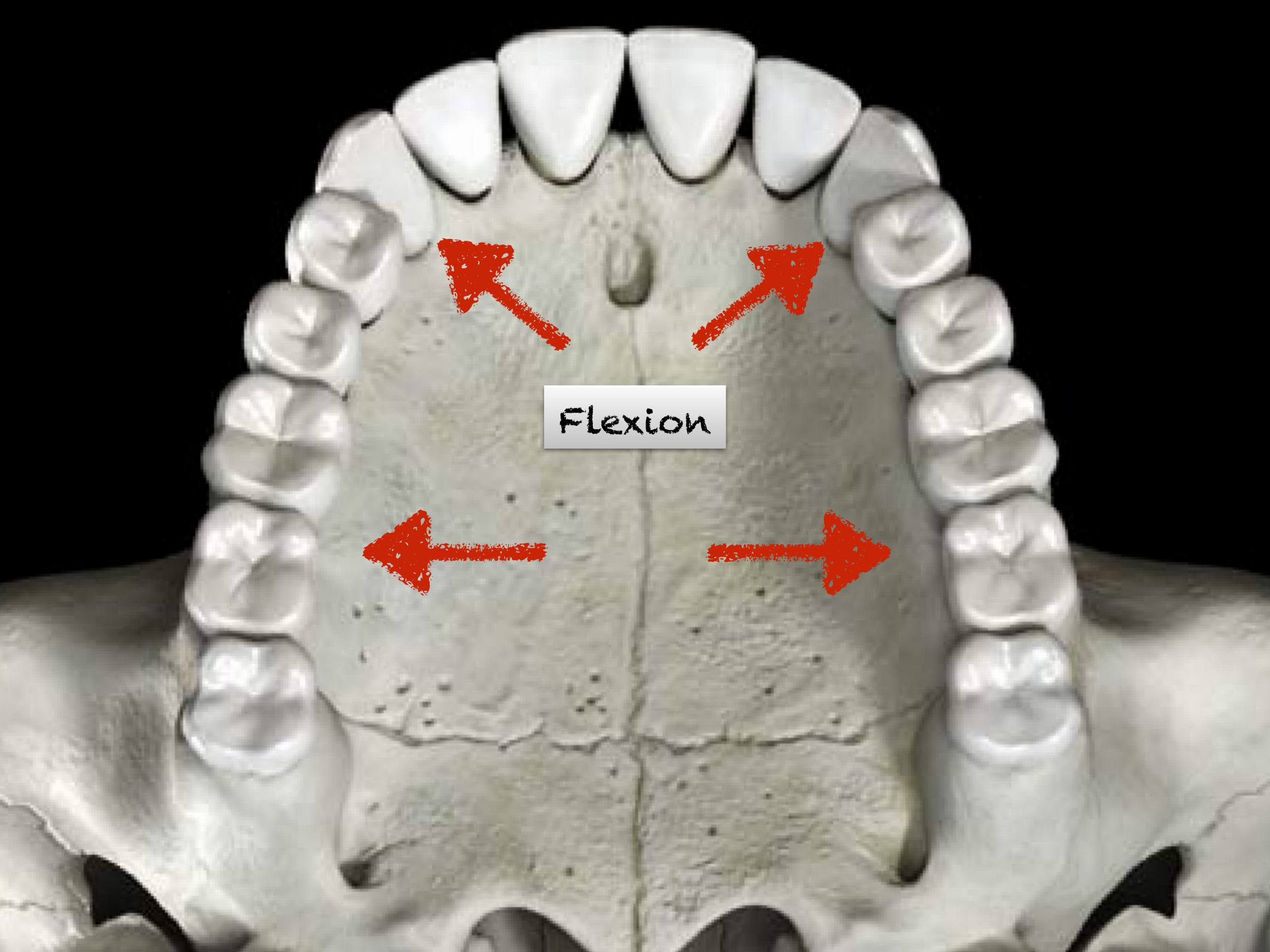
Flexion

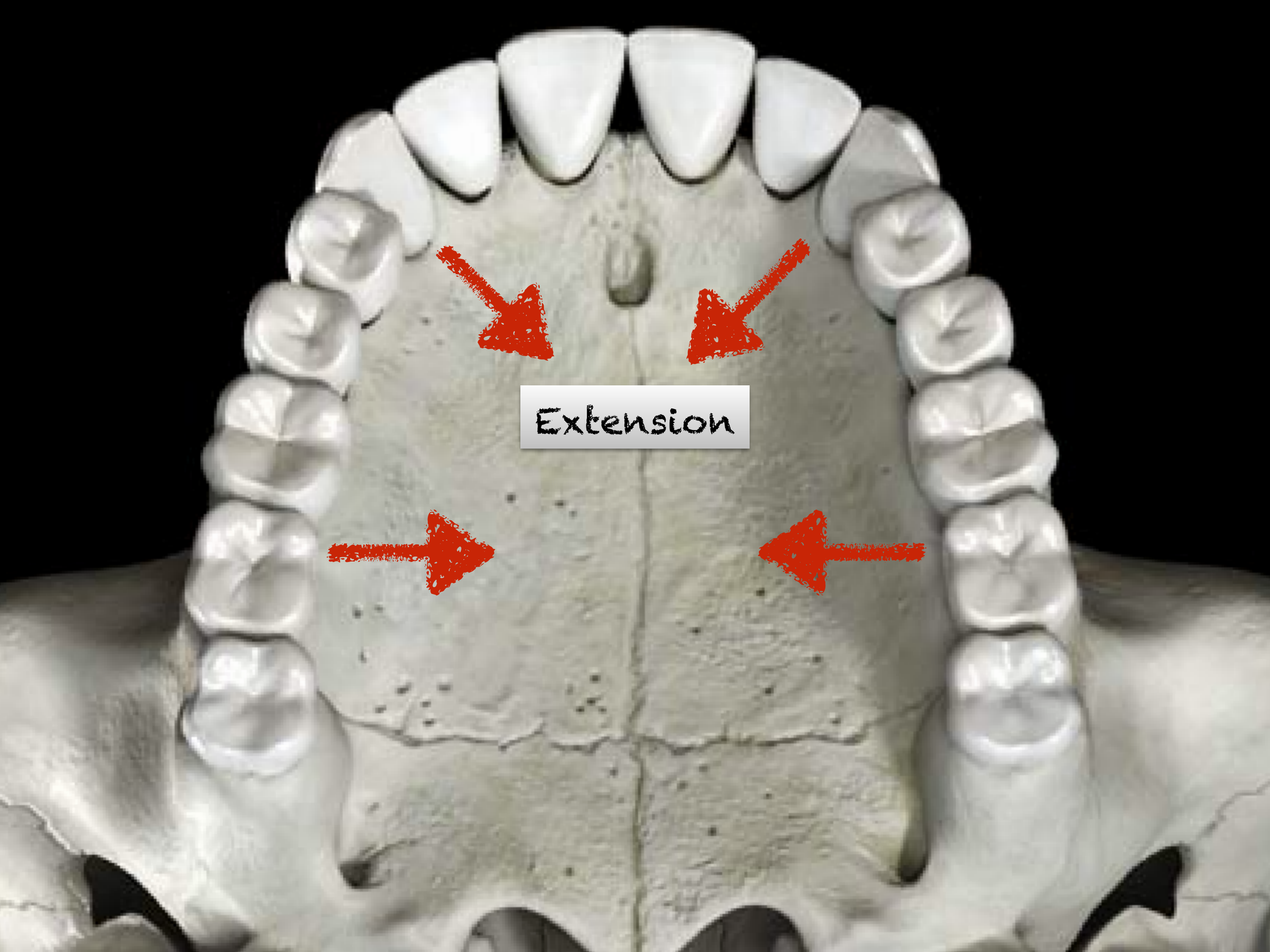
Extension

Torsions

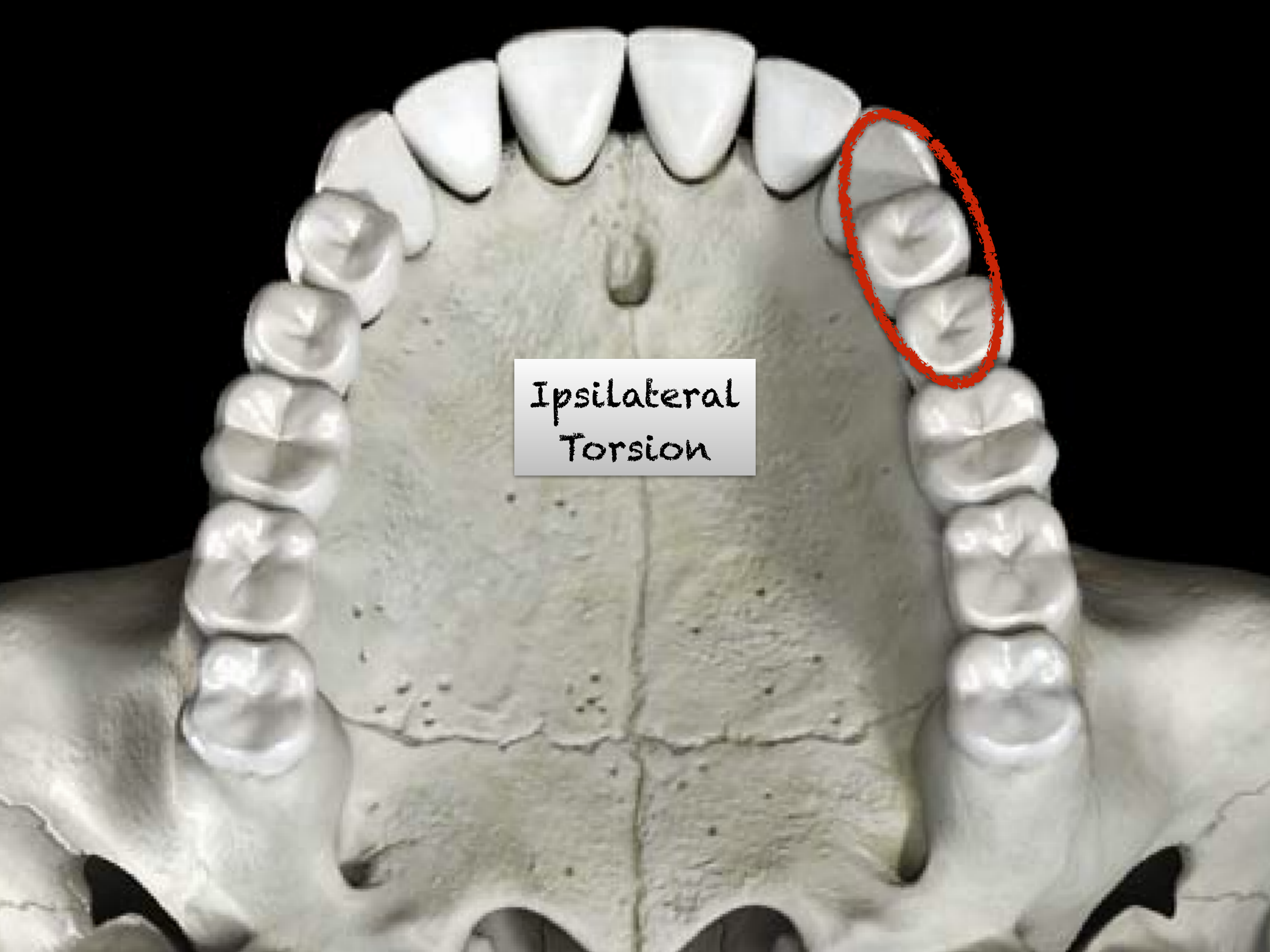
Ipsilateral
Torsion

Sidebending/Rotation

Ipsilateral
Side Bending/Rotation

Vertical Strains

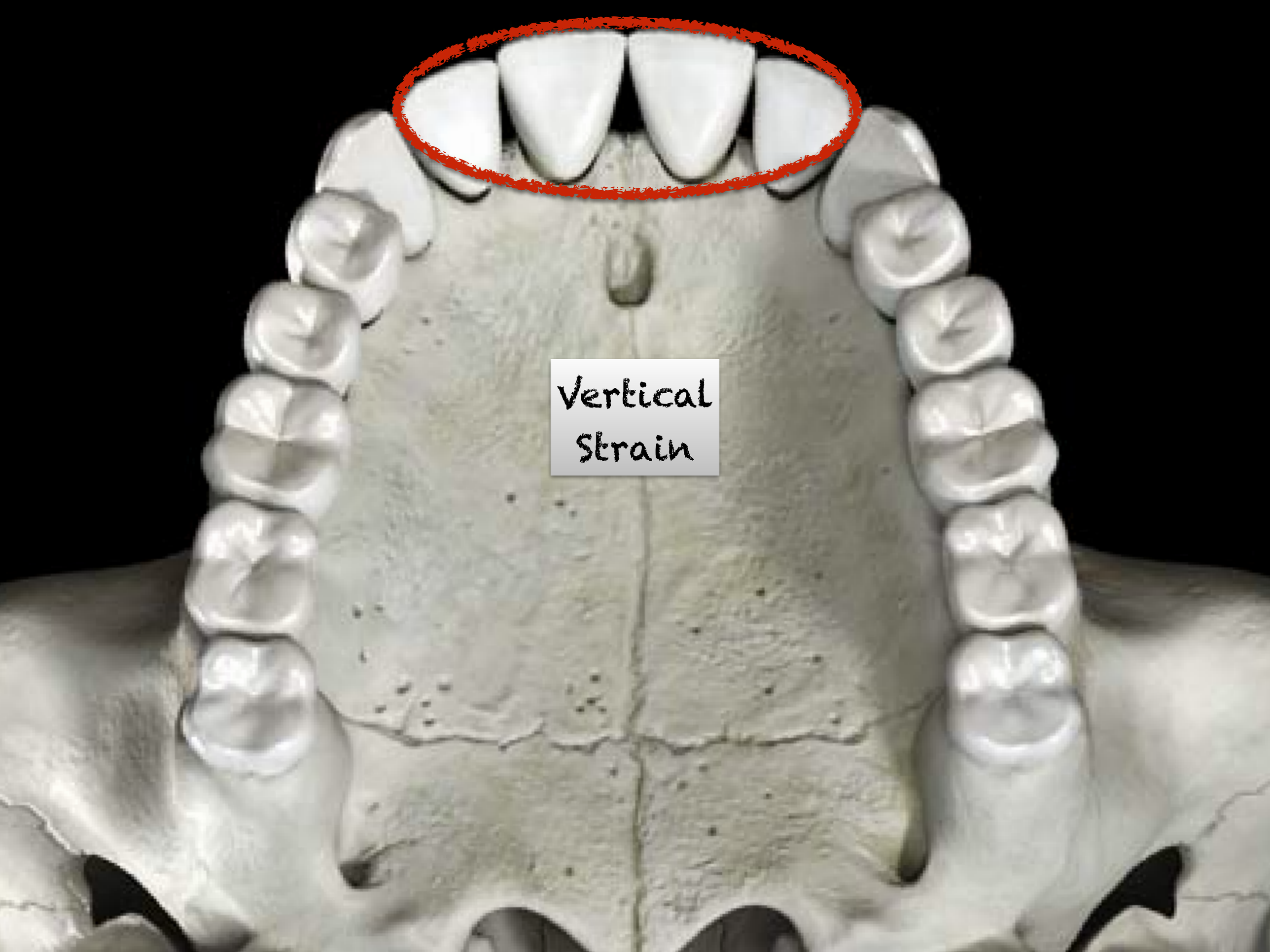
Vertical
Strain

Vertical
Strain

Lateral Strains

Contralateral
Lateral
Strain

SBS Compression

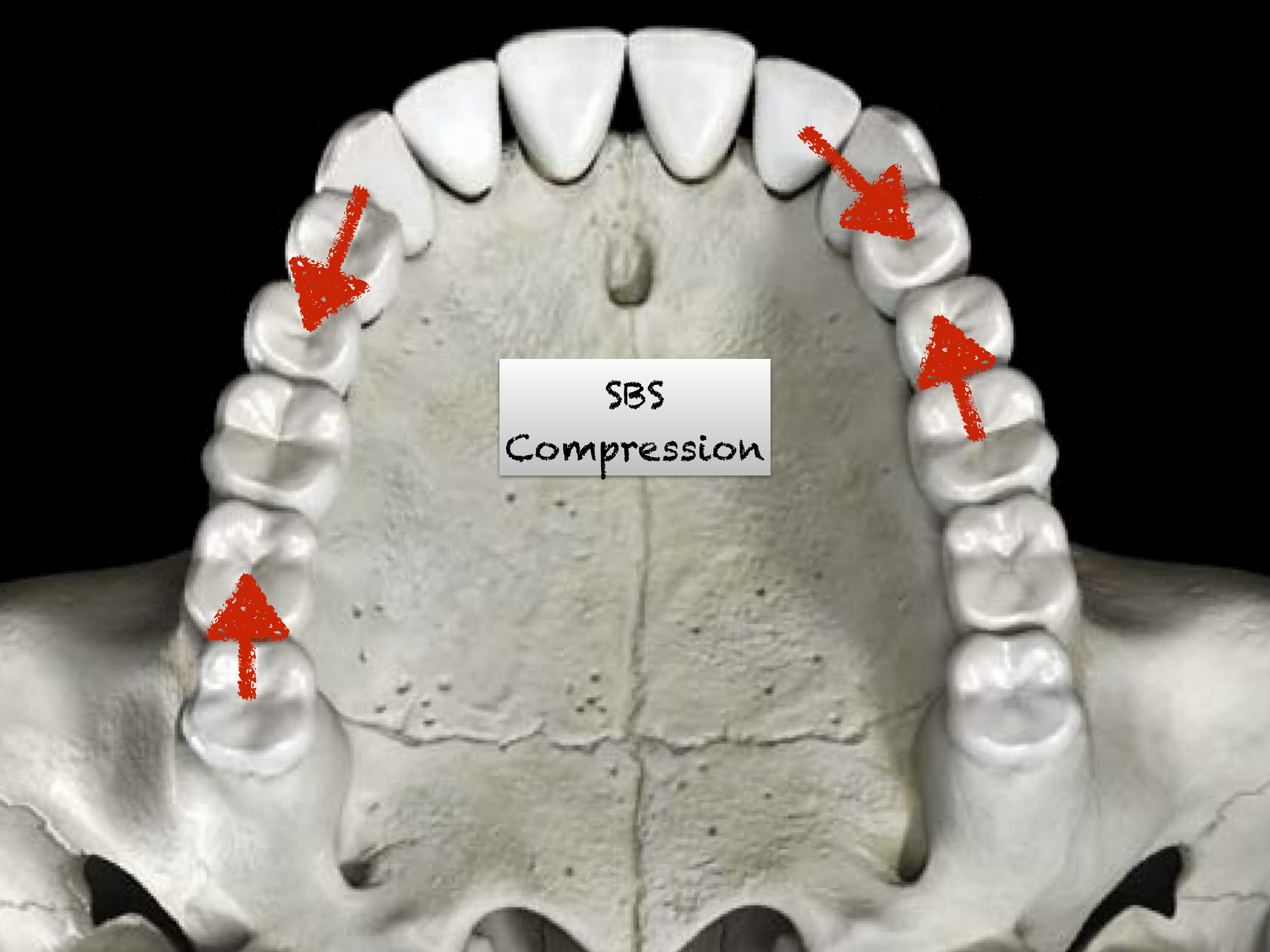
SBS
Compression

Lab

Dental Occlusion Strains Lab

- For those of you who know cranial, palpate the patients head with teeth apart and identify the strain patterns present.

- Then have the patient occlude the teeth and identify any changes. These patterns show which areas to look at to find the teeth causing the issue.

Appliance/ALF Testing

Testing the Appliance/ALF patient to see if the appliance needs an adjustment



“It is the supreme art of the teacher to awaken joy in creative expression and knowledge.

–Albert Einstein

ALF Adjustment Testing

- By having the patient use their fingers to place gentle pressure in the directions indicated, the operator can monitor the head/body and ascertain its reaction to the suggested motion.

- If the body relaxes (better CRI) when the motion is introduced, that suggests that that change in the appliance would be well tolerated.

- If the body tightens (less CRI) when the motion is introduced, that suggests that that change in the appliance would be advised.

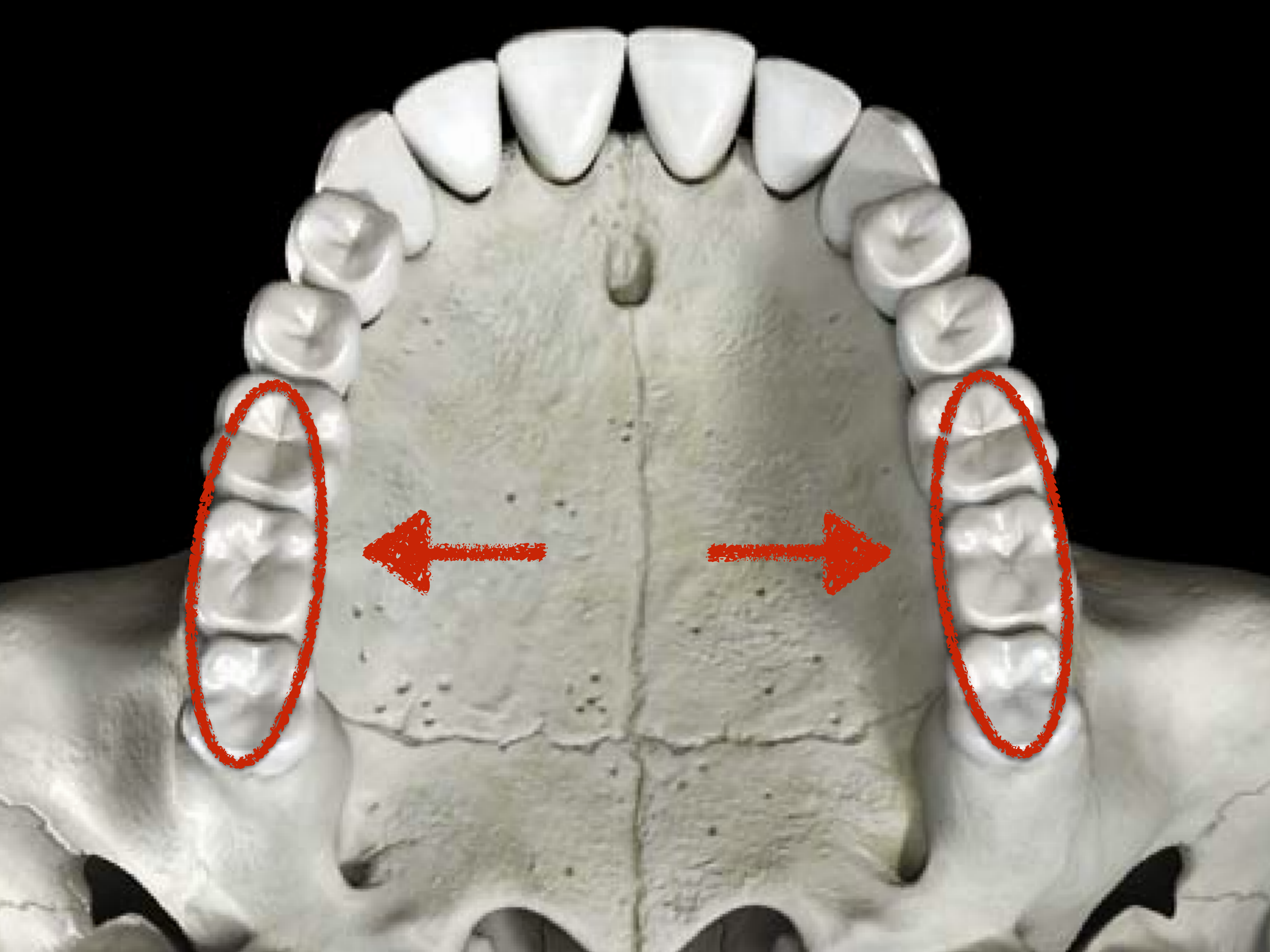

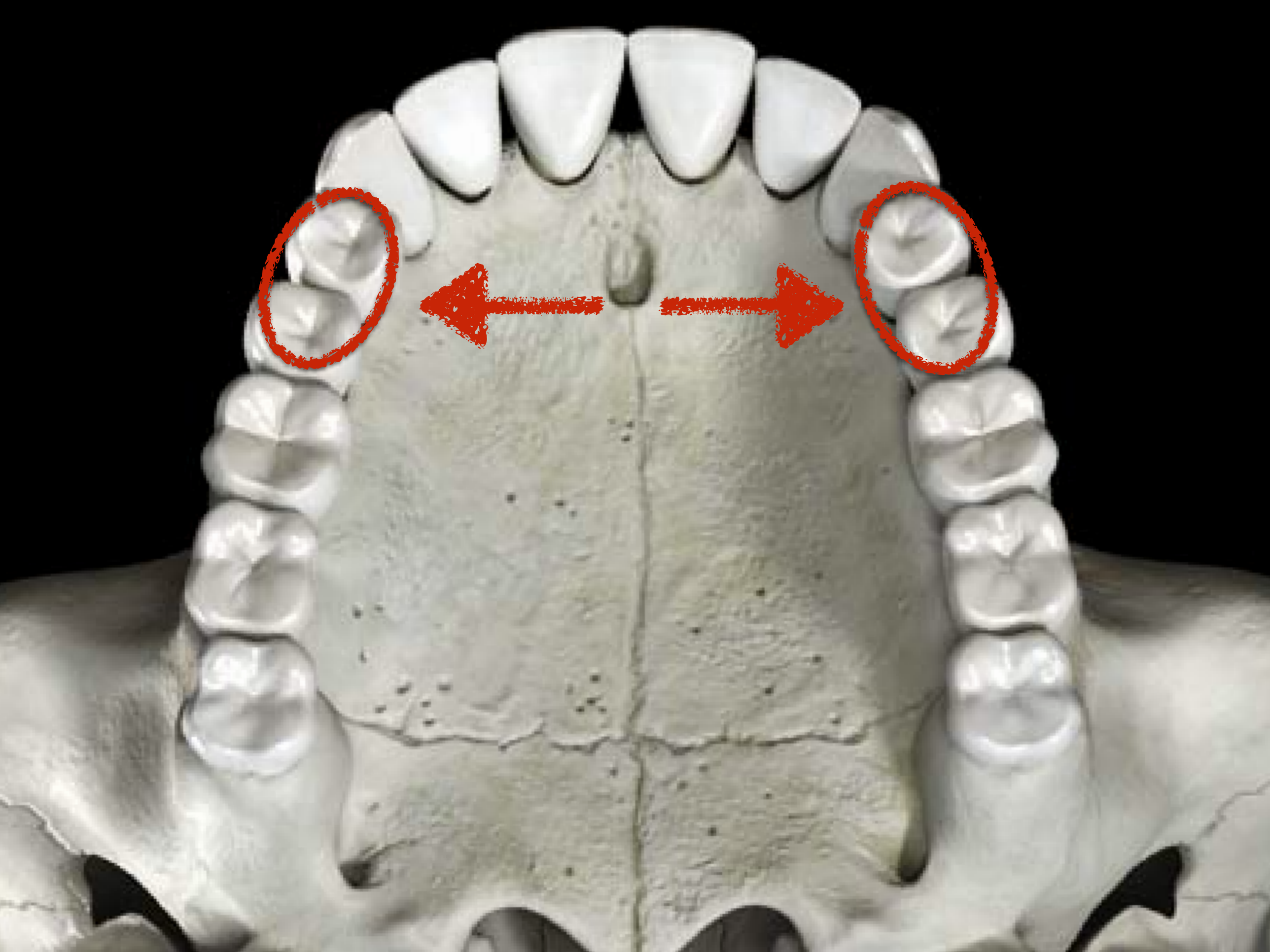

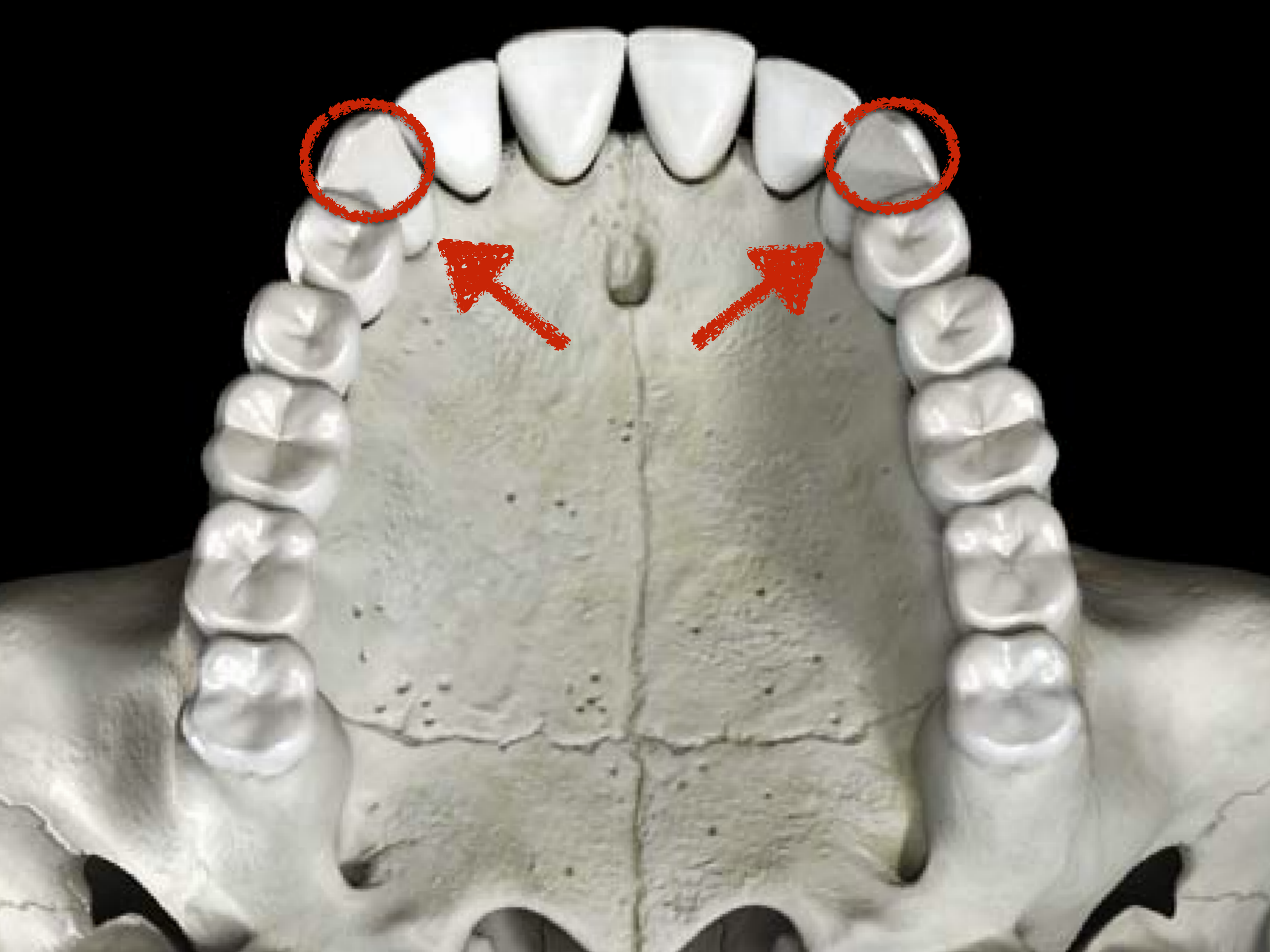

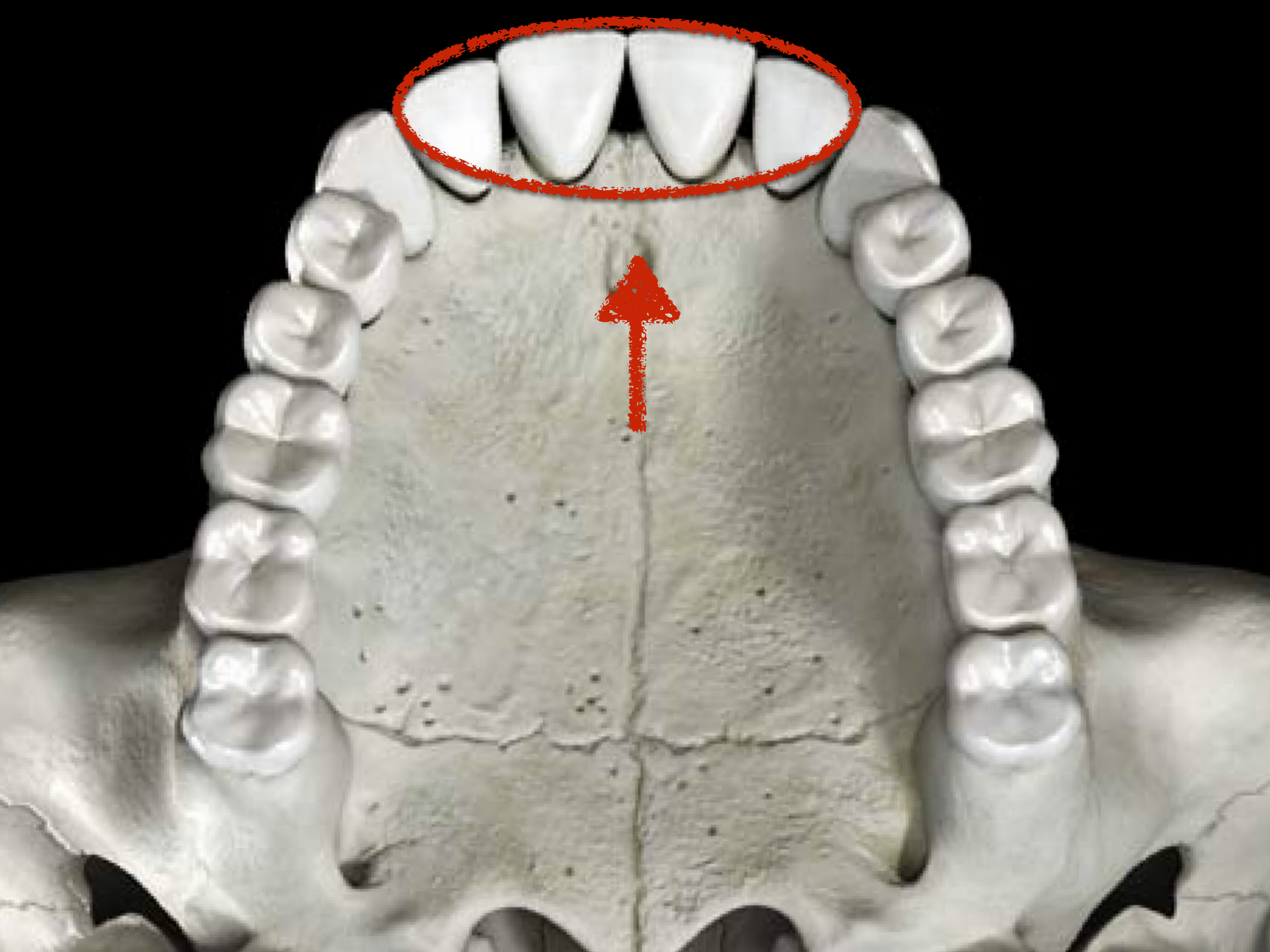

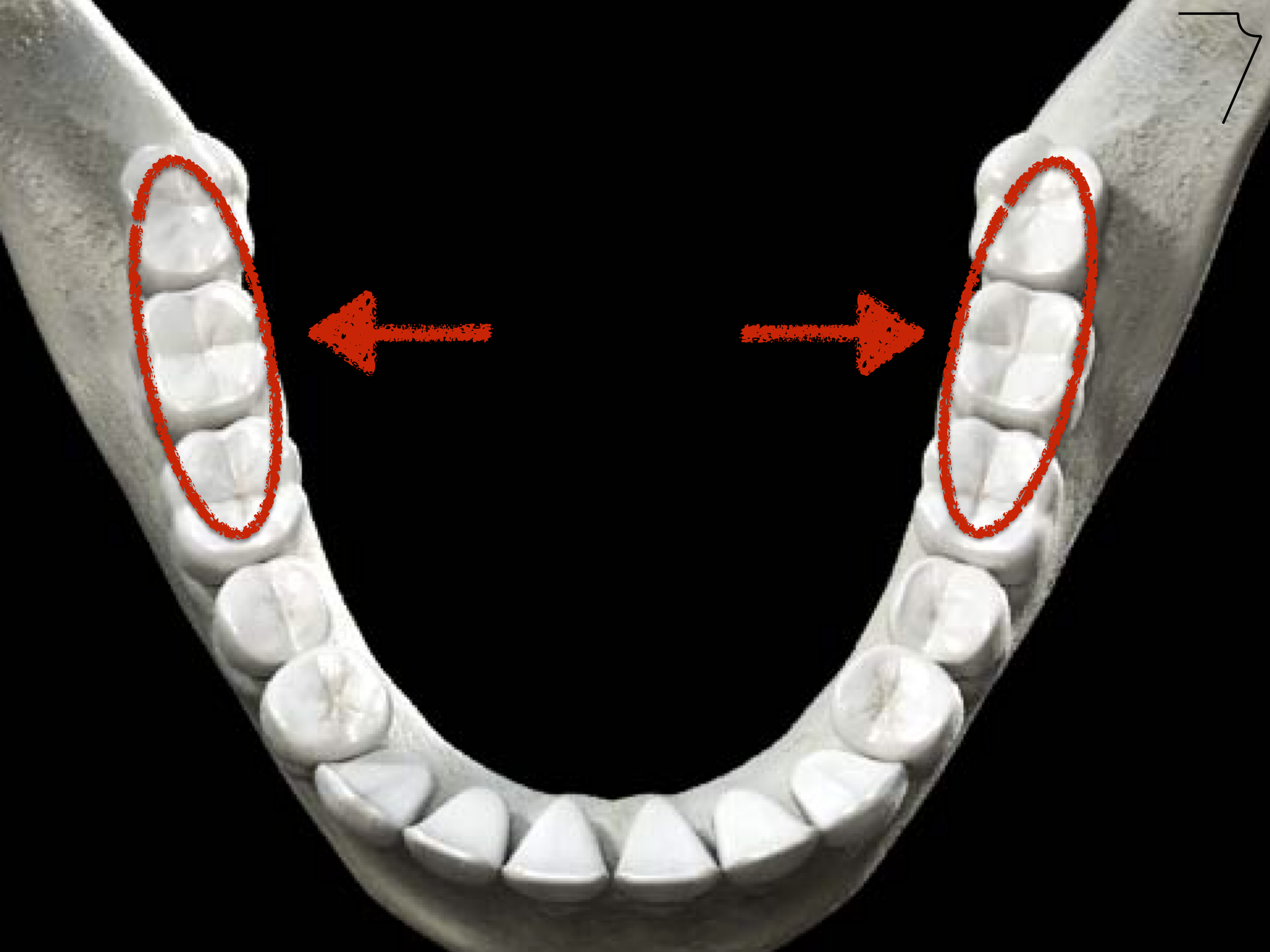

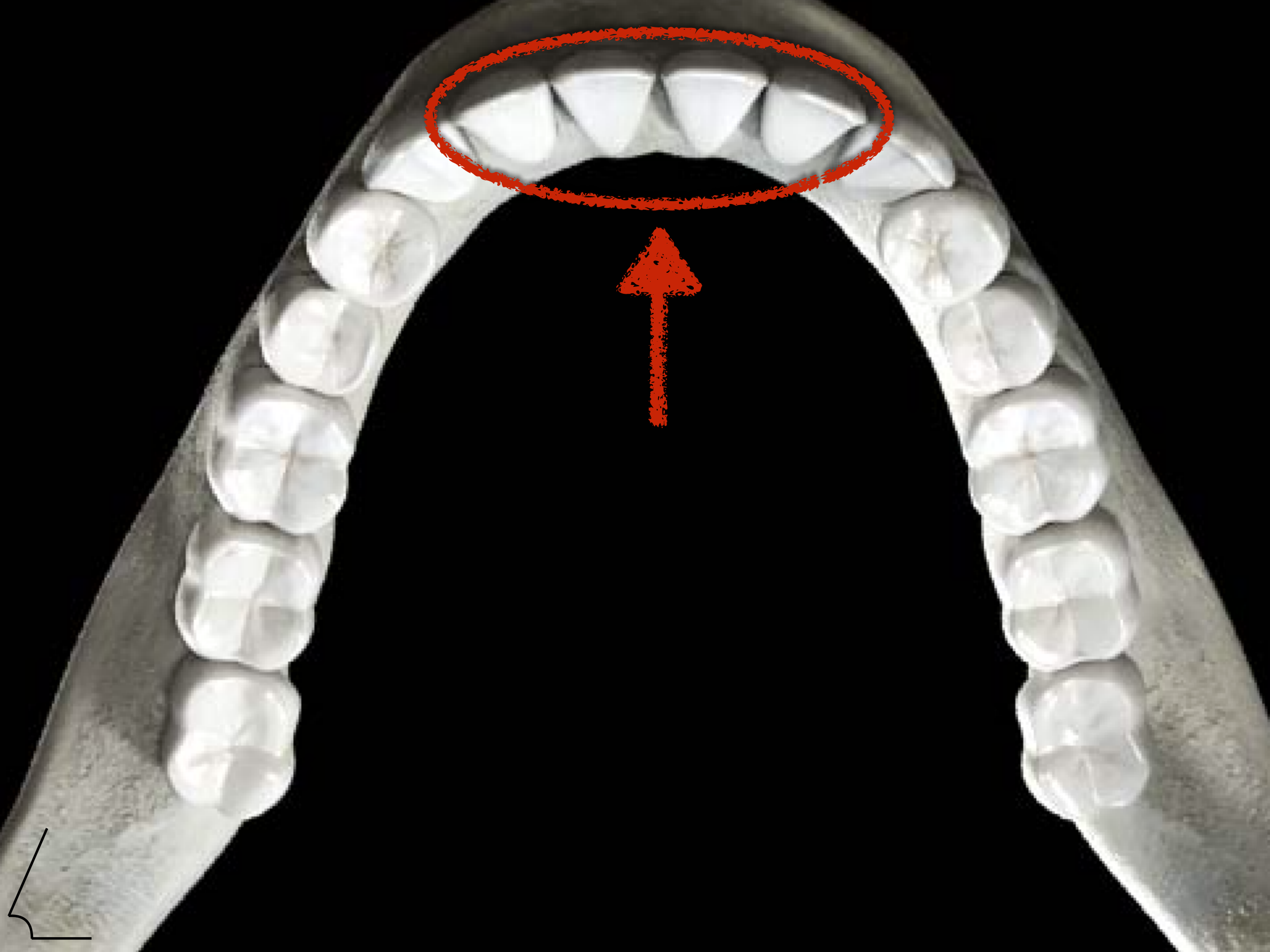

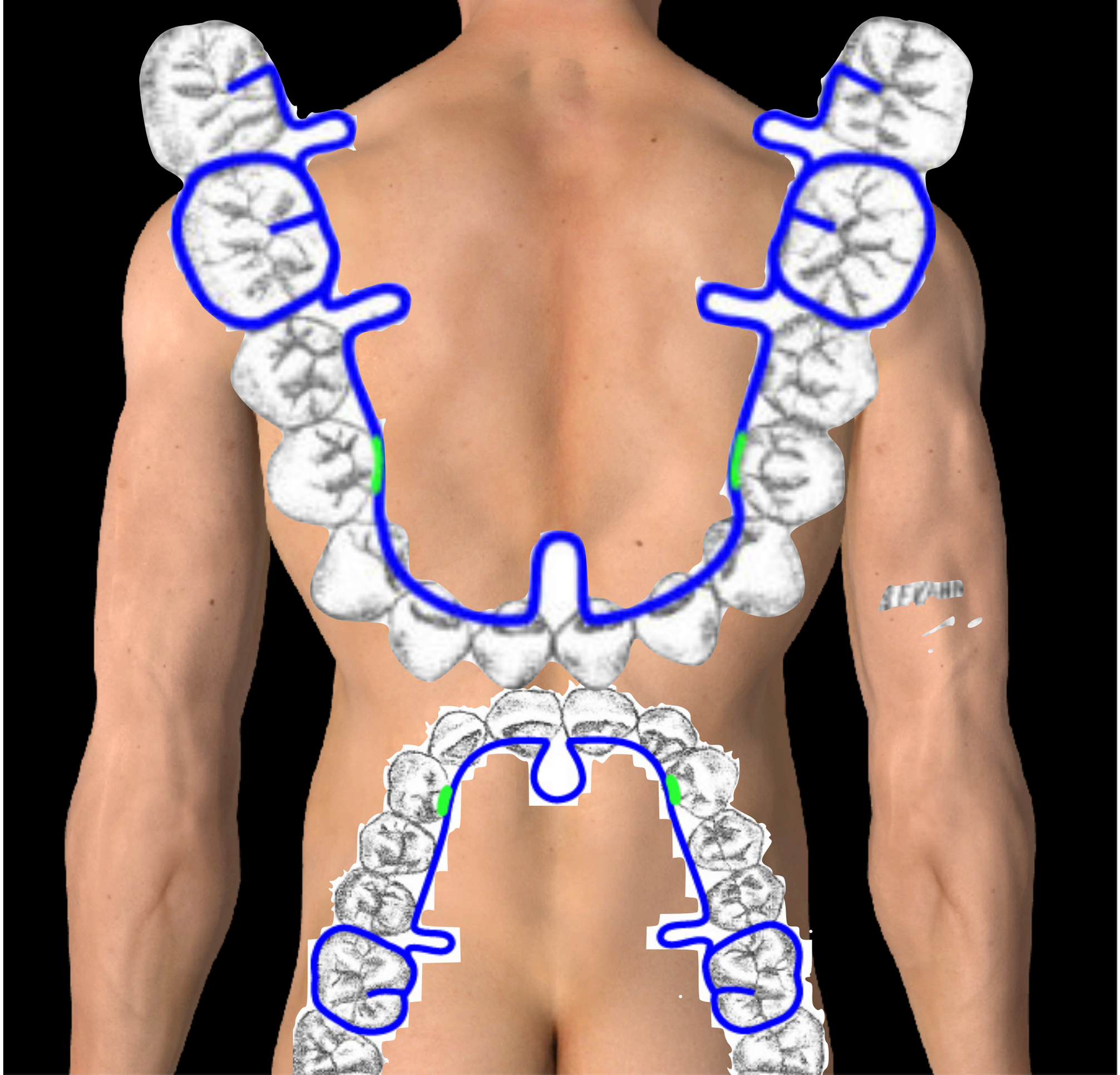

Lab

Basic Tooth Testing Lab

- Testing for bilateral changes is fairly straightforward - have the patient put gentle traction on the teeth (you can test both lingual and buccal movements).

- Testing for ipsilateral patterns is only slightly more complicated - you must make sure that the patient's midline is not effected by the testing (remember these movements are gentle - only a few grams of force). In this way you can test to see if one side only needs movement, or if one side needs more movement than the other to bring balance.

Mouth Connections to the Body

(these are physical, not energetic, links)

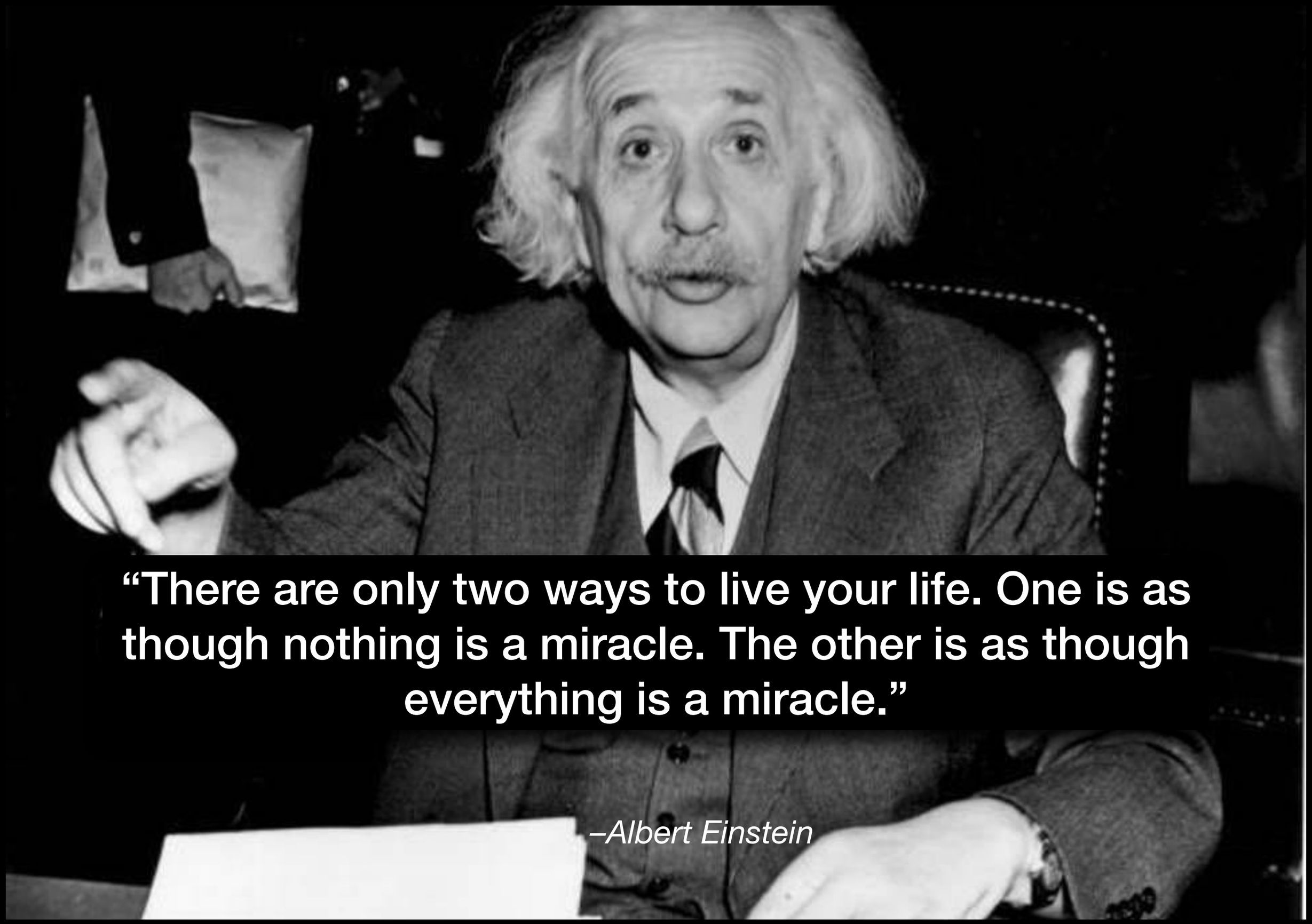
“There are only two ways to live your life. One is as though nothing is a miracle. The other is as though everything is a miracle.”
–Albert Einstein

“If you hold a cat by the tail you learn things you cannot learn any other way.”

–Mark Twain

Mouth Connections to the Body

- These were discovered and tested over a two year period on every patient that had the indicating sign of a dental dysfunction.

- To date, the connections connect with the places taught 100% of the time.

- But to be safe, we are talking connection, not necessarily causation.

This is an overview of the entire map

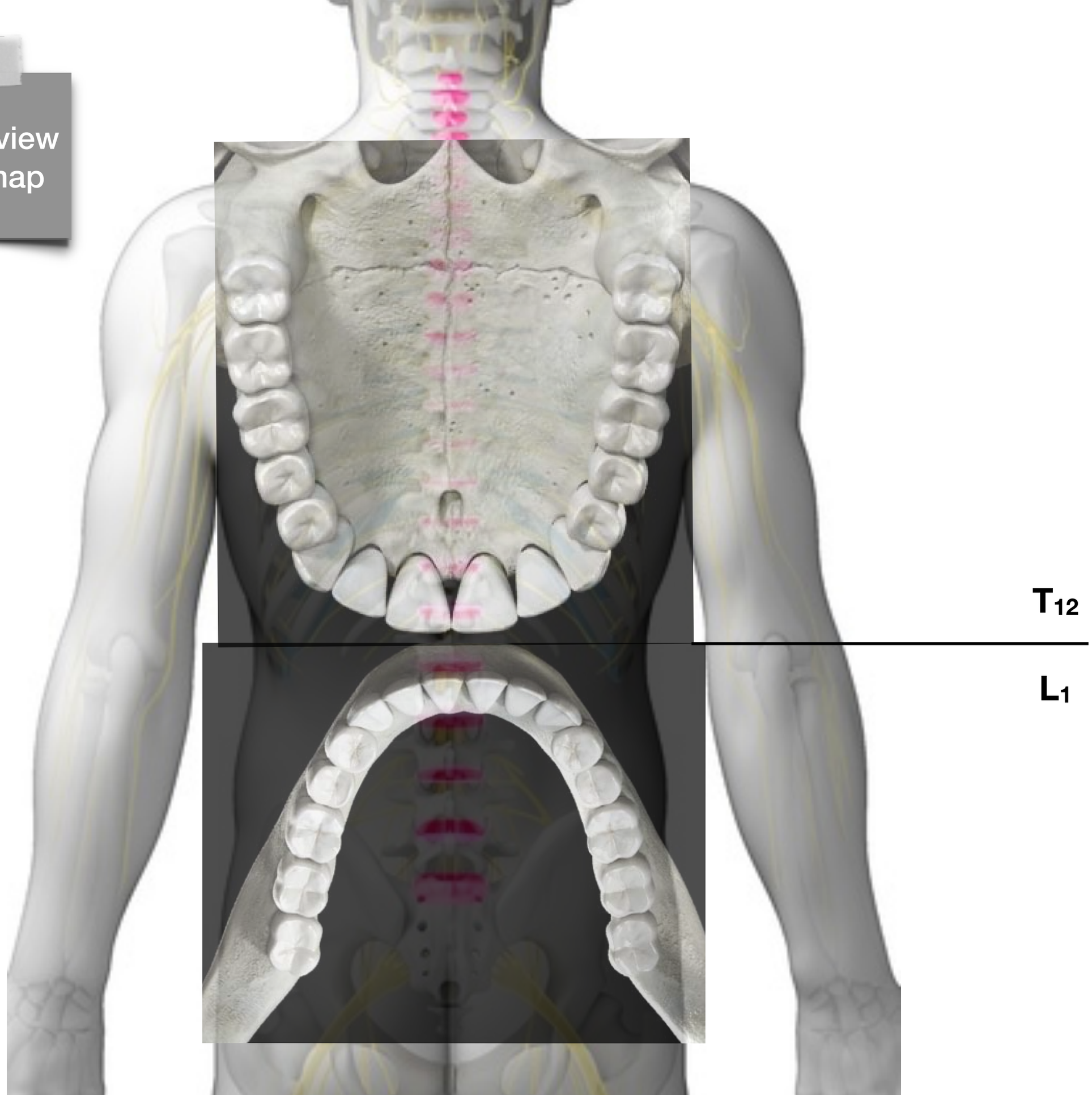

The Dental Body Connection

- First, for this overlay to apply, the patient must have tension (abnormal tension) in the lower third of the sternocleidomastoid (SCM) muscle.

- If this tension is present, first, it tells you that they have a dental restriction/dysfunction.

- Second, by using the overlay, you can learn where the dysfunction is in the mouth and get feedback from the body on whether you accomplished the correction.

The Dental Body Connection

- This connection not only allows for a map to connect the mouth/teeth with the rest of the body…
- But it allows you to determine how effective your treatments are and how they impact the whole body…
- This allows…more collaboration between the TEAM…a better idea of who needs to go next (and what they need to focus on)….and tells you when a patient is healthy…

Now we will break up the dental overlay into its component parts.

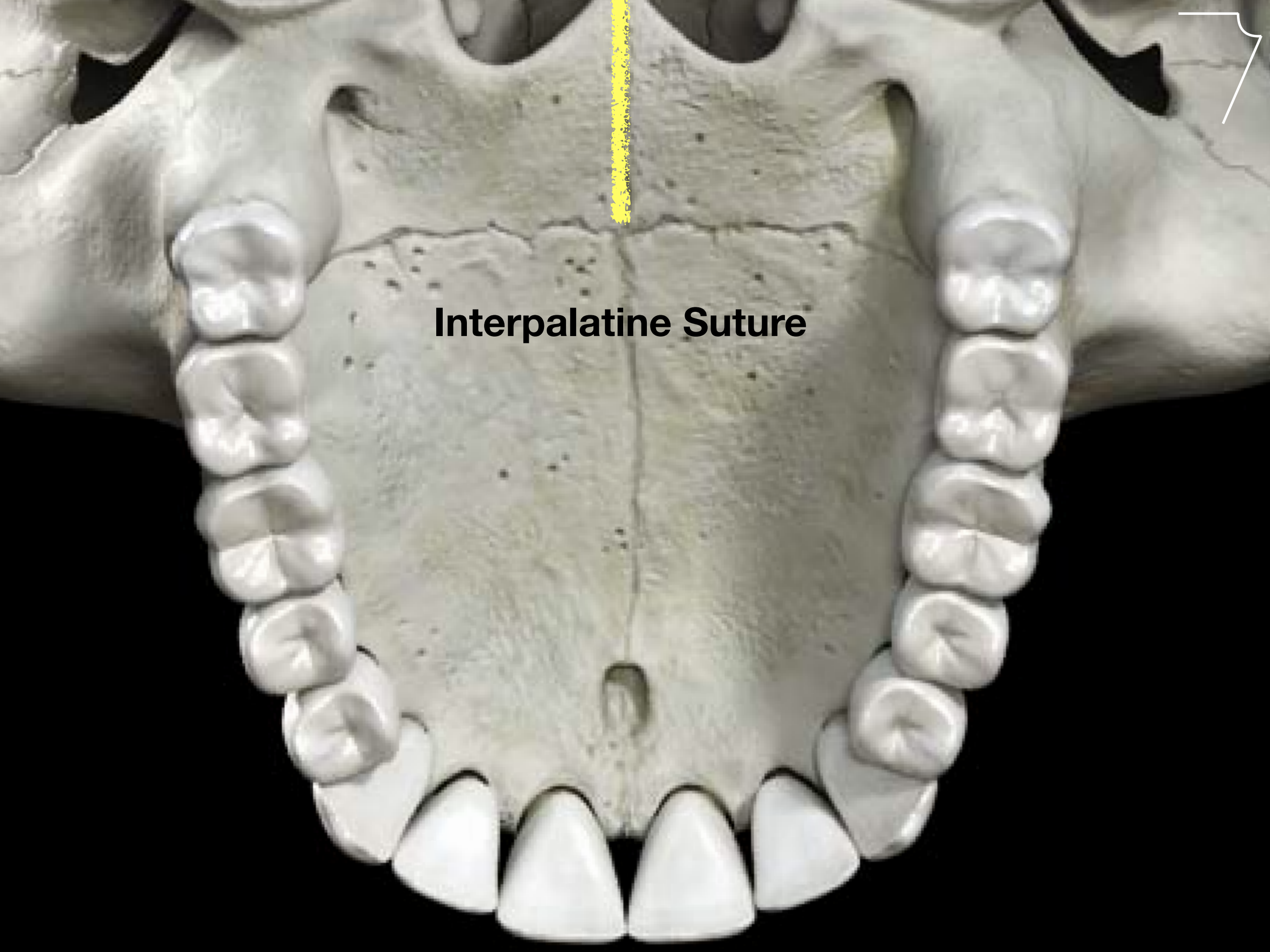
Interpalatine Suture

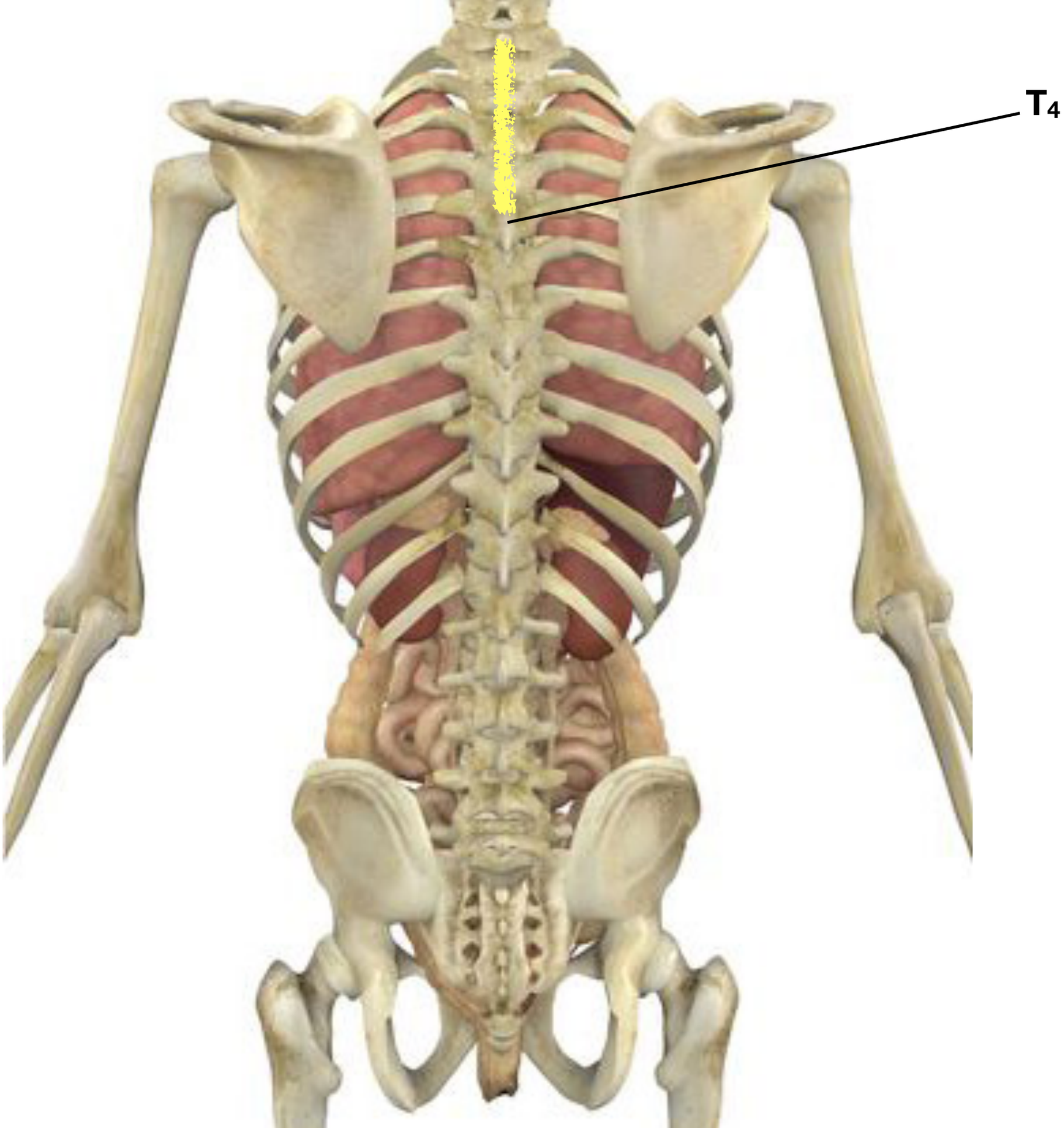
T4

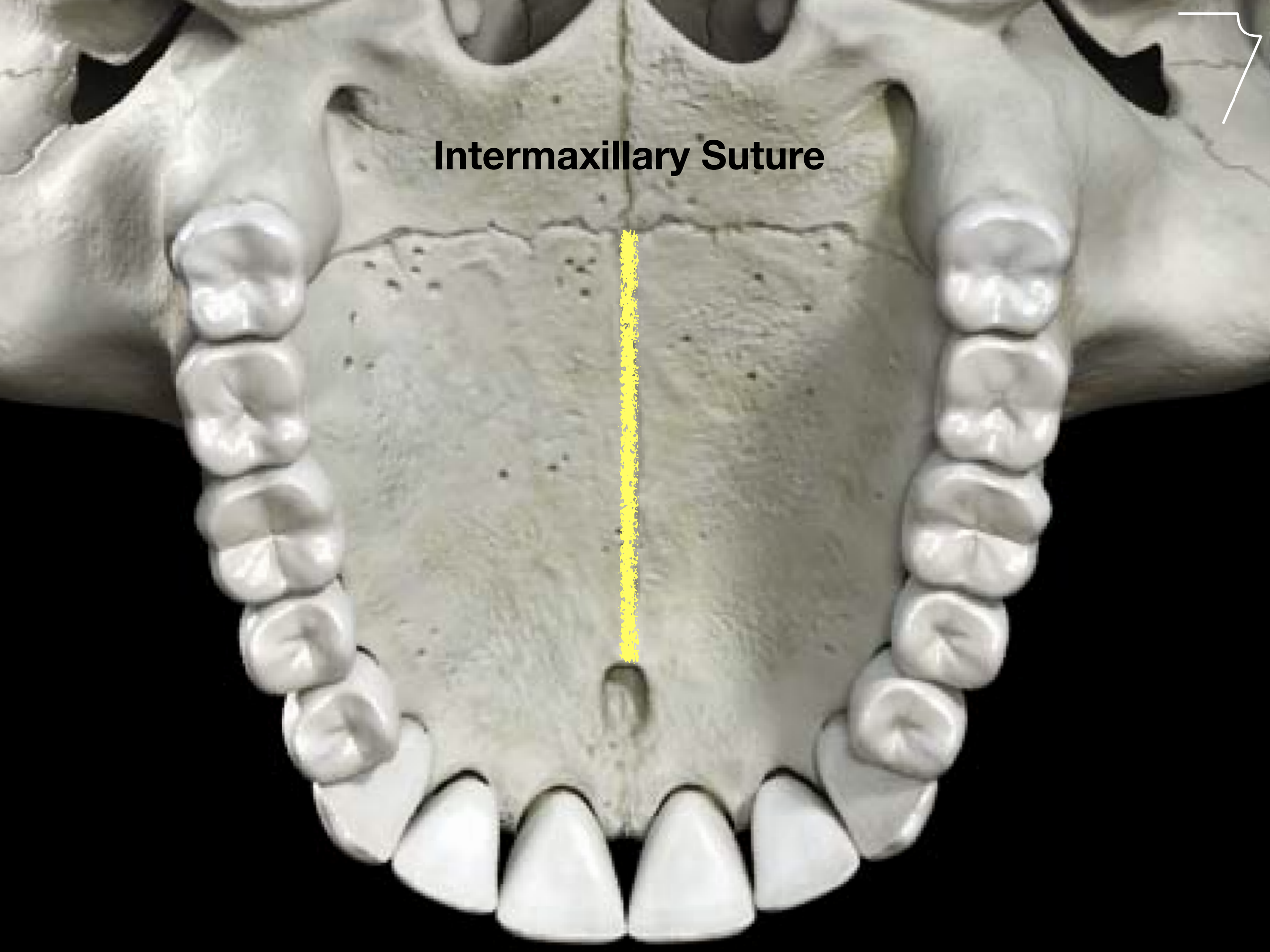
Intermaxillary Suture

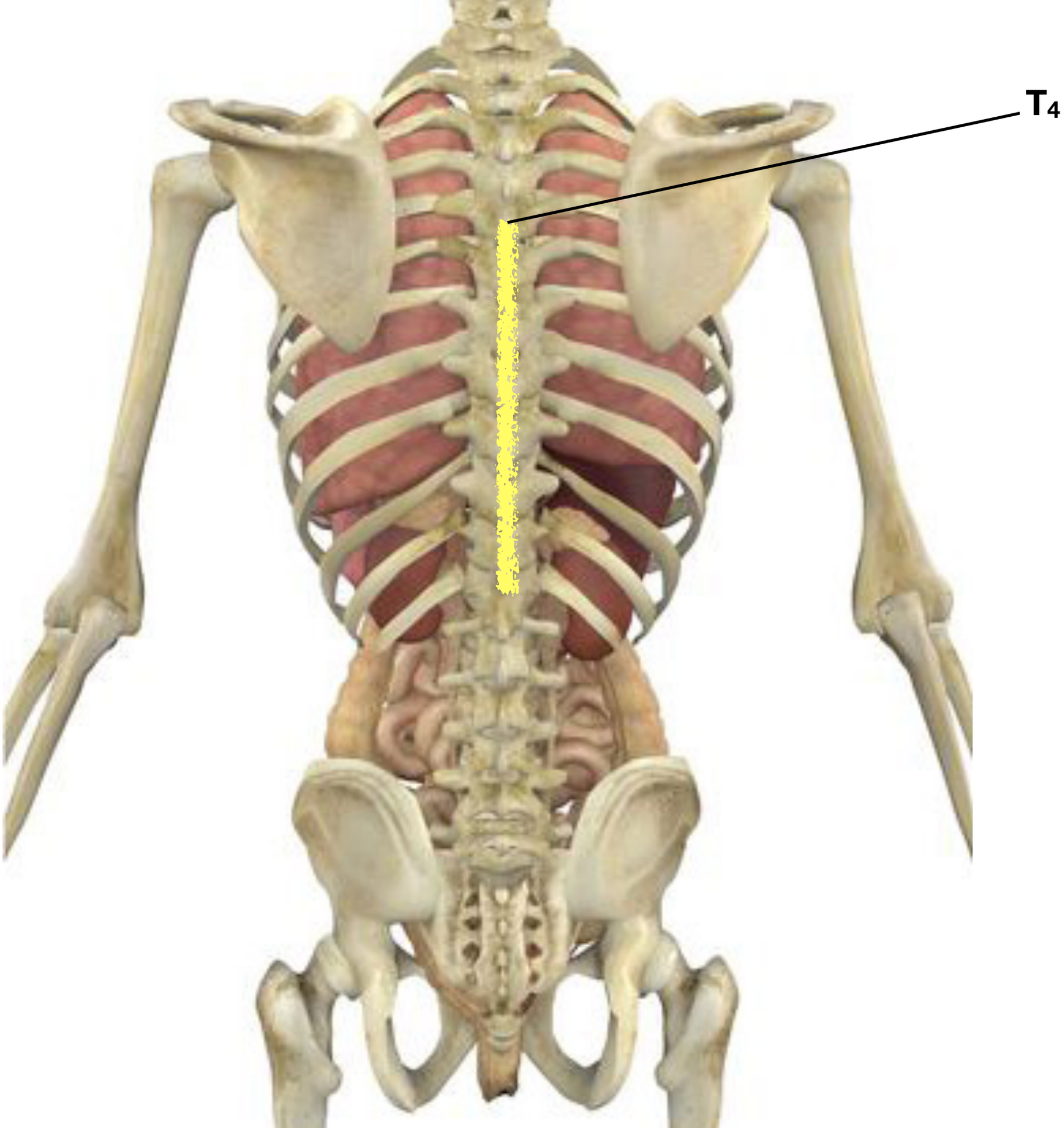
T_4

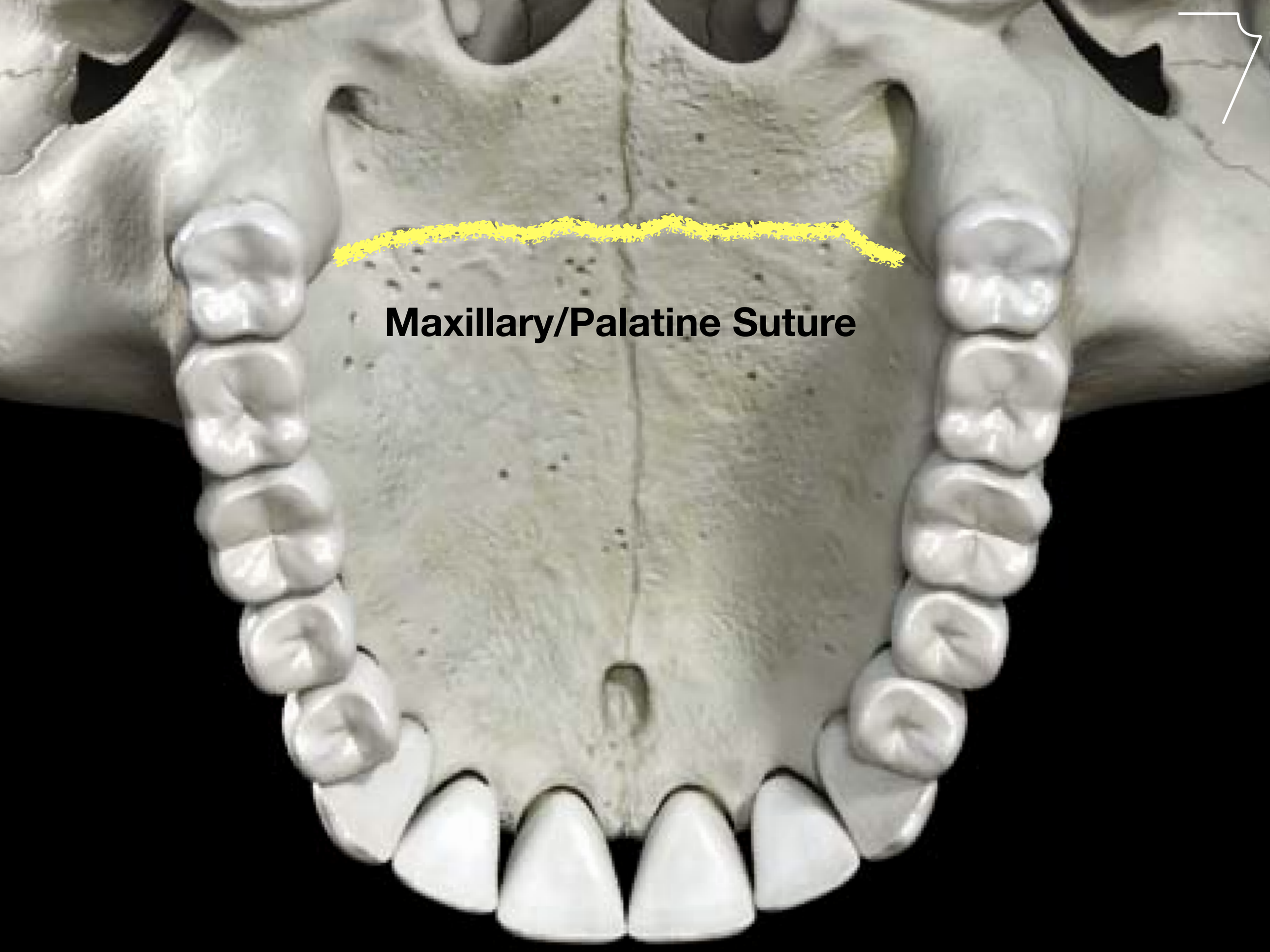
Maxillary/Palatine Suture

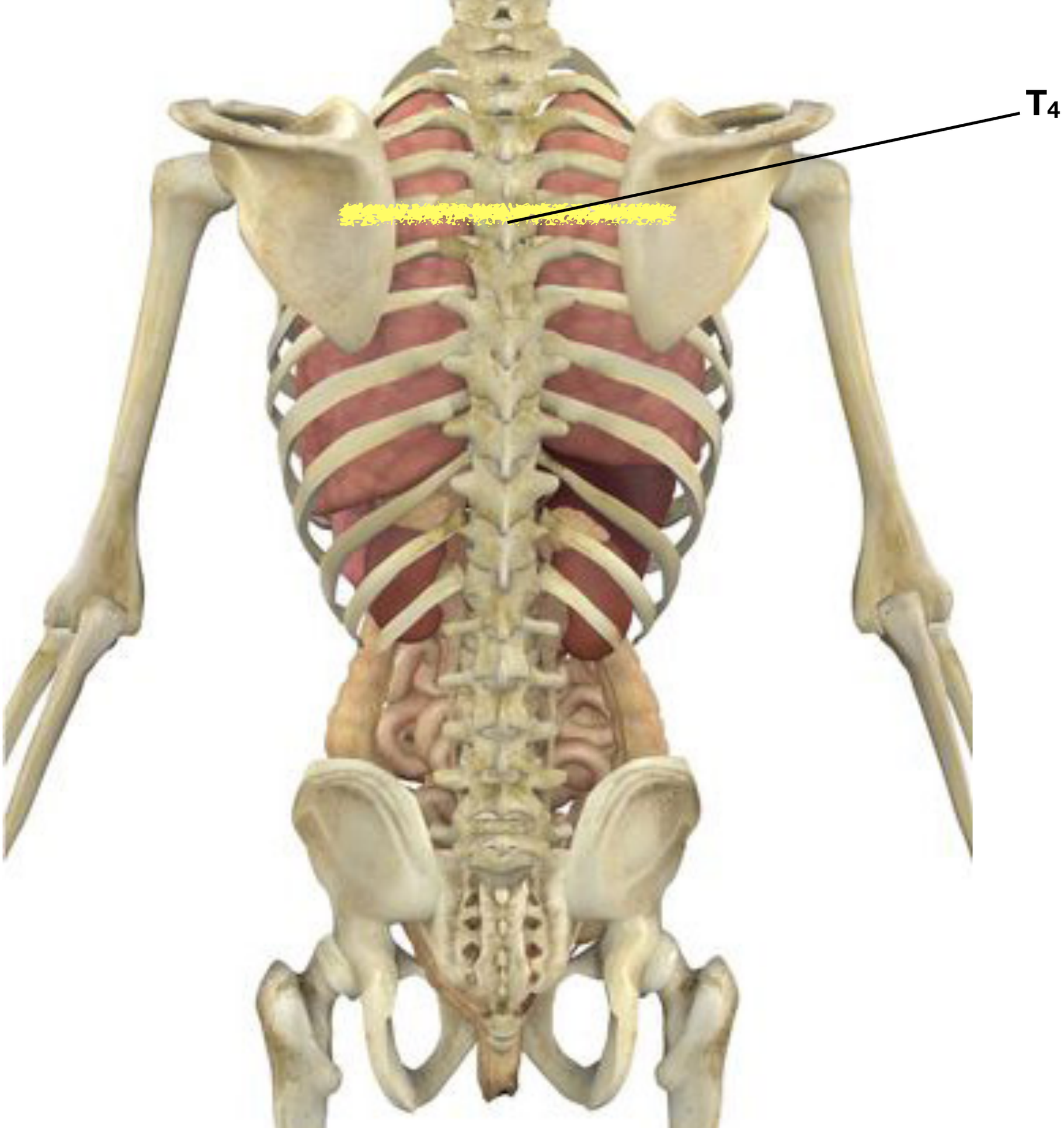
T4

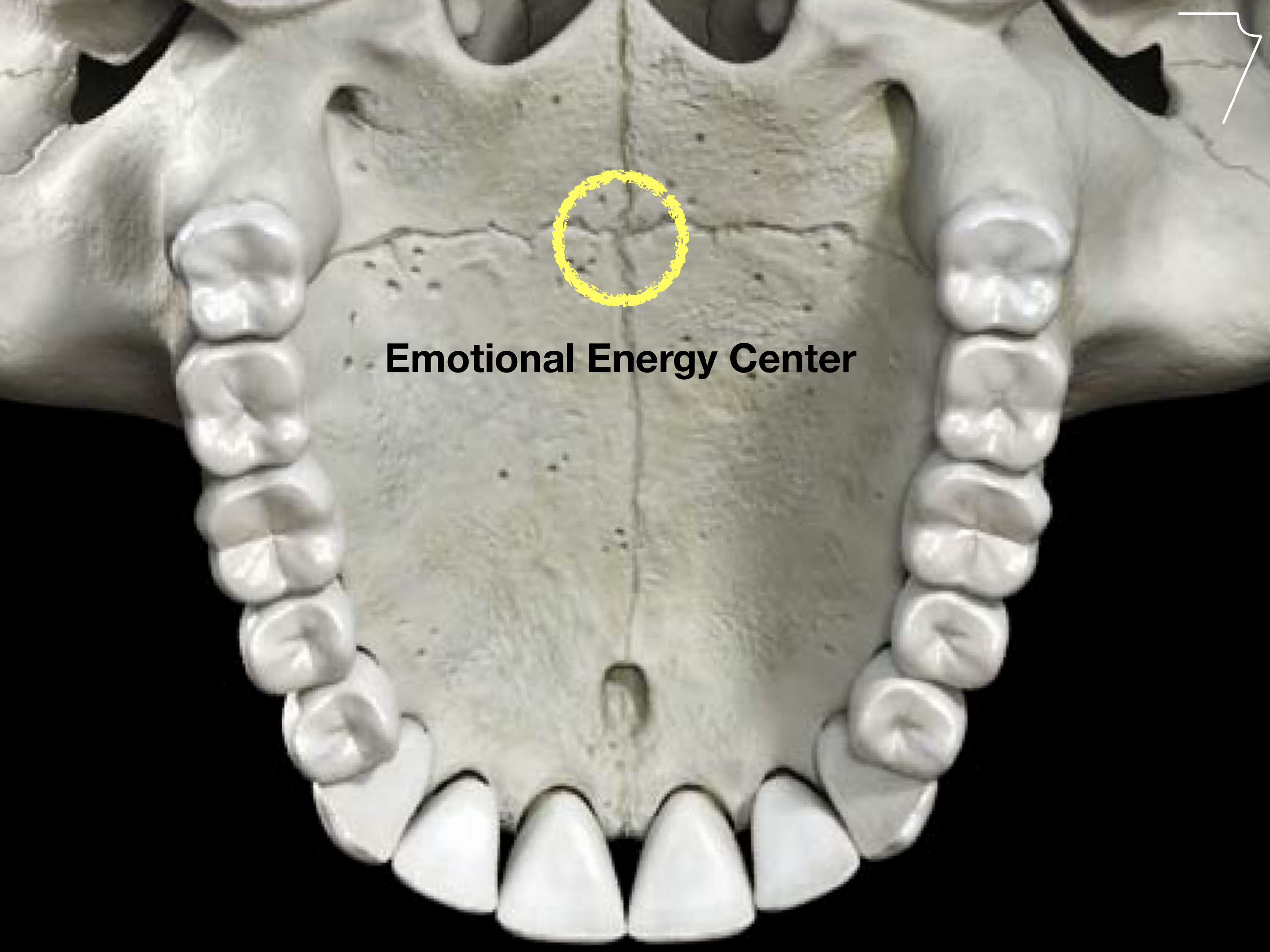
Emotional Energy Center

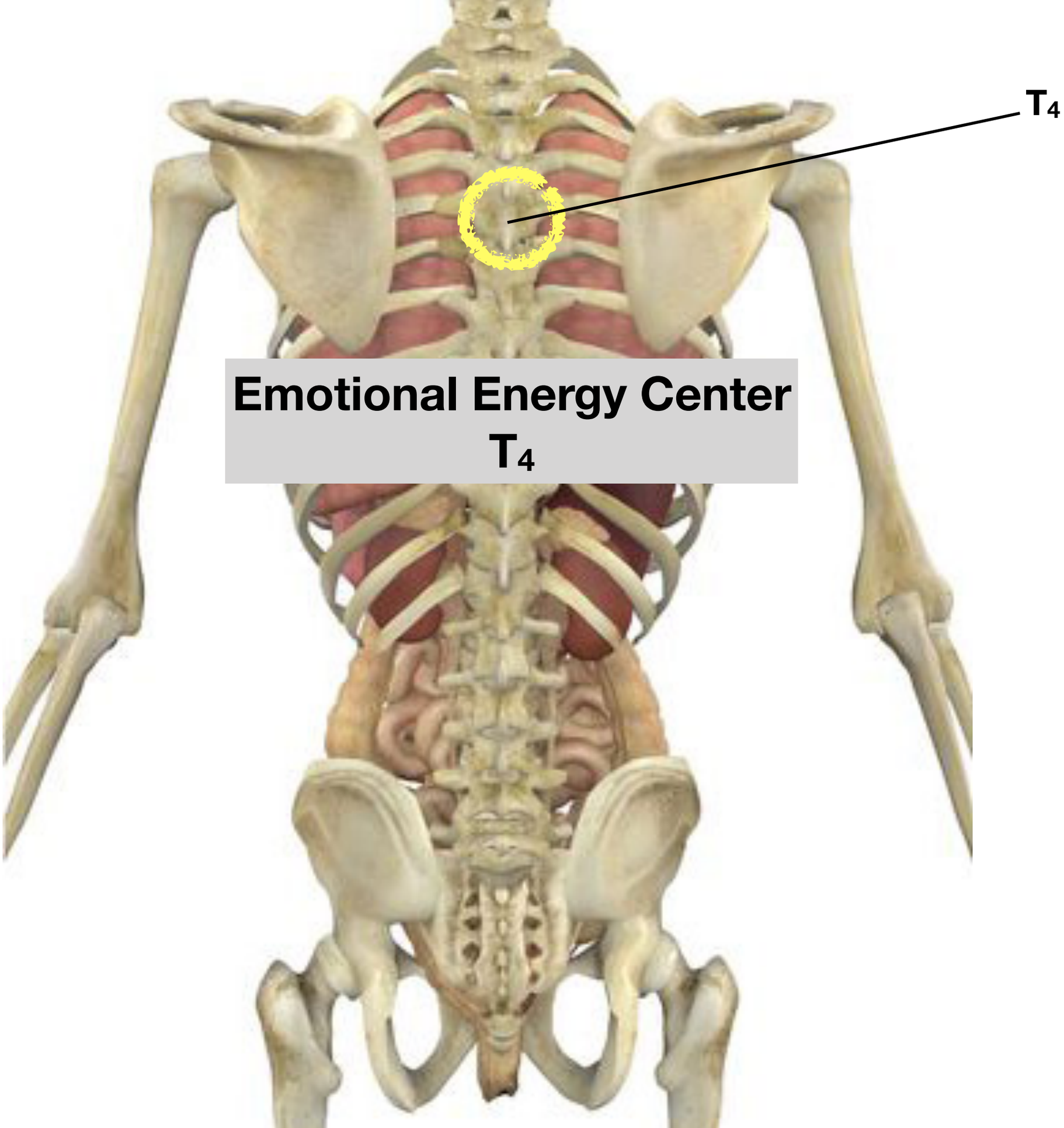
T4
Emotional Energy Center
T4

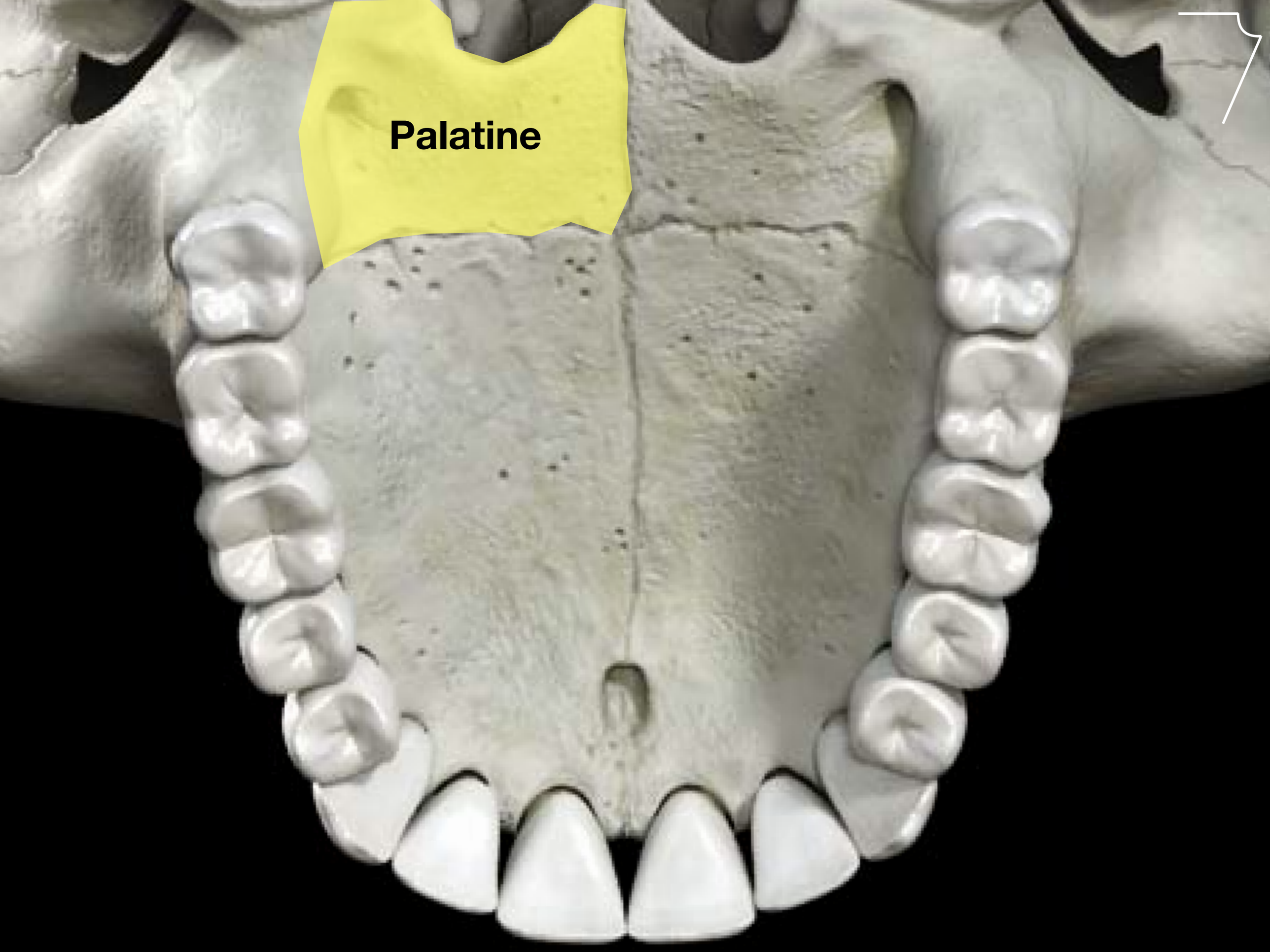
Palatine

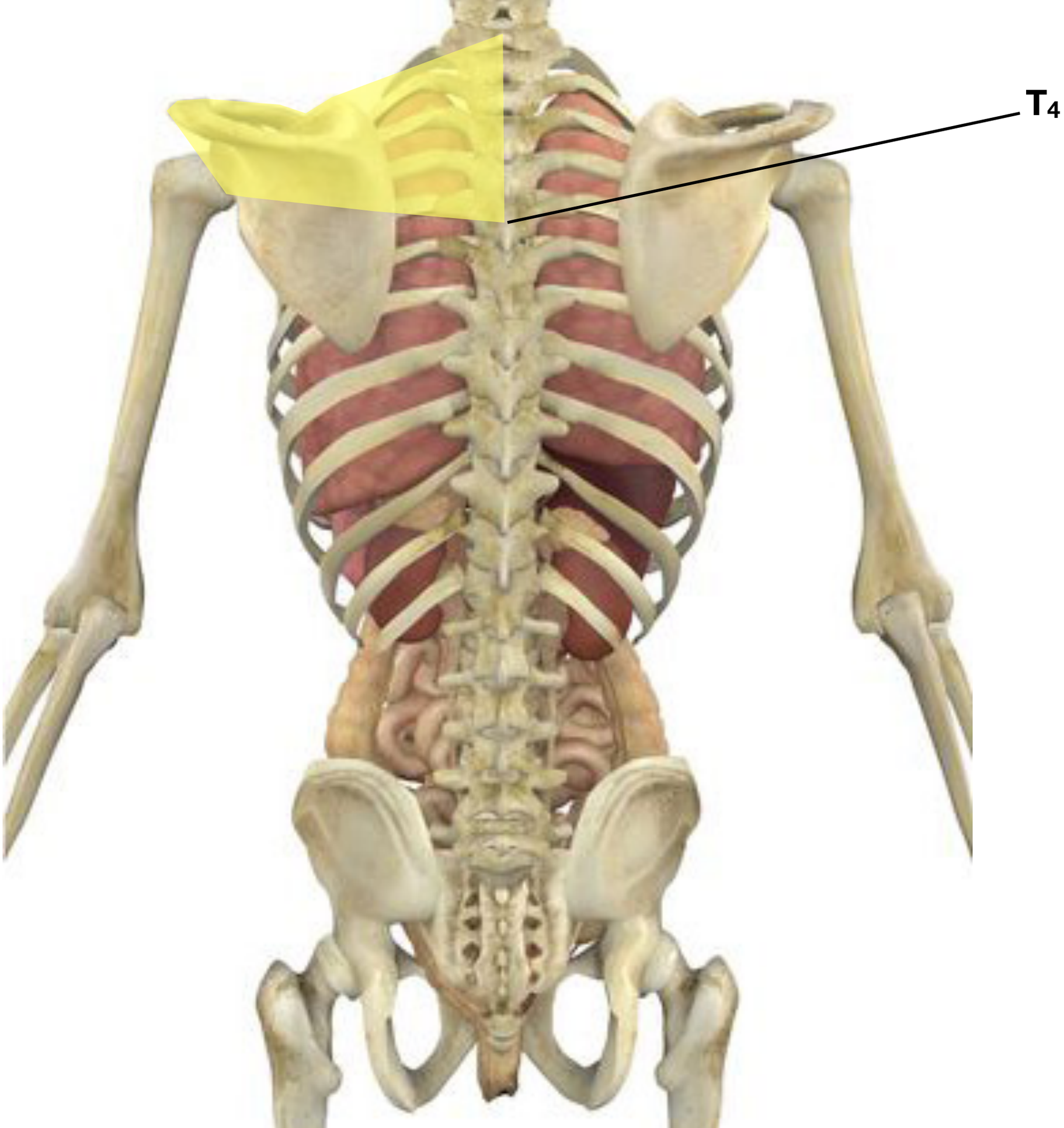
T_4

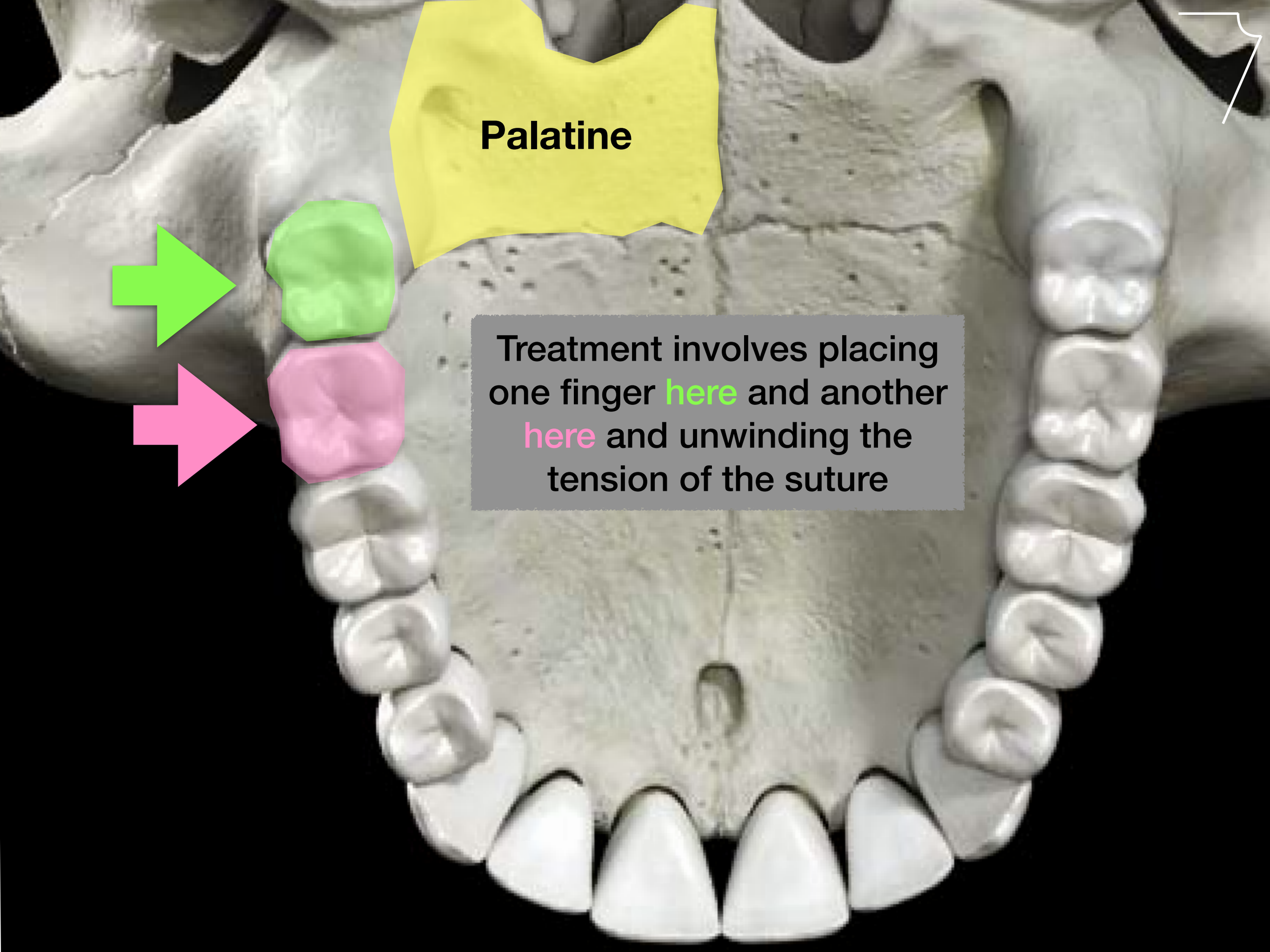
Palatine
Treatment involves placing one finger here and another here and unwinding the tension of the suture

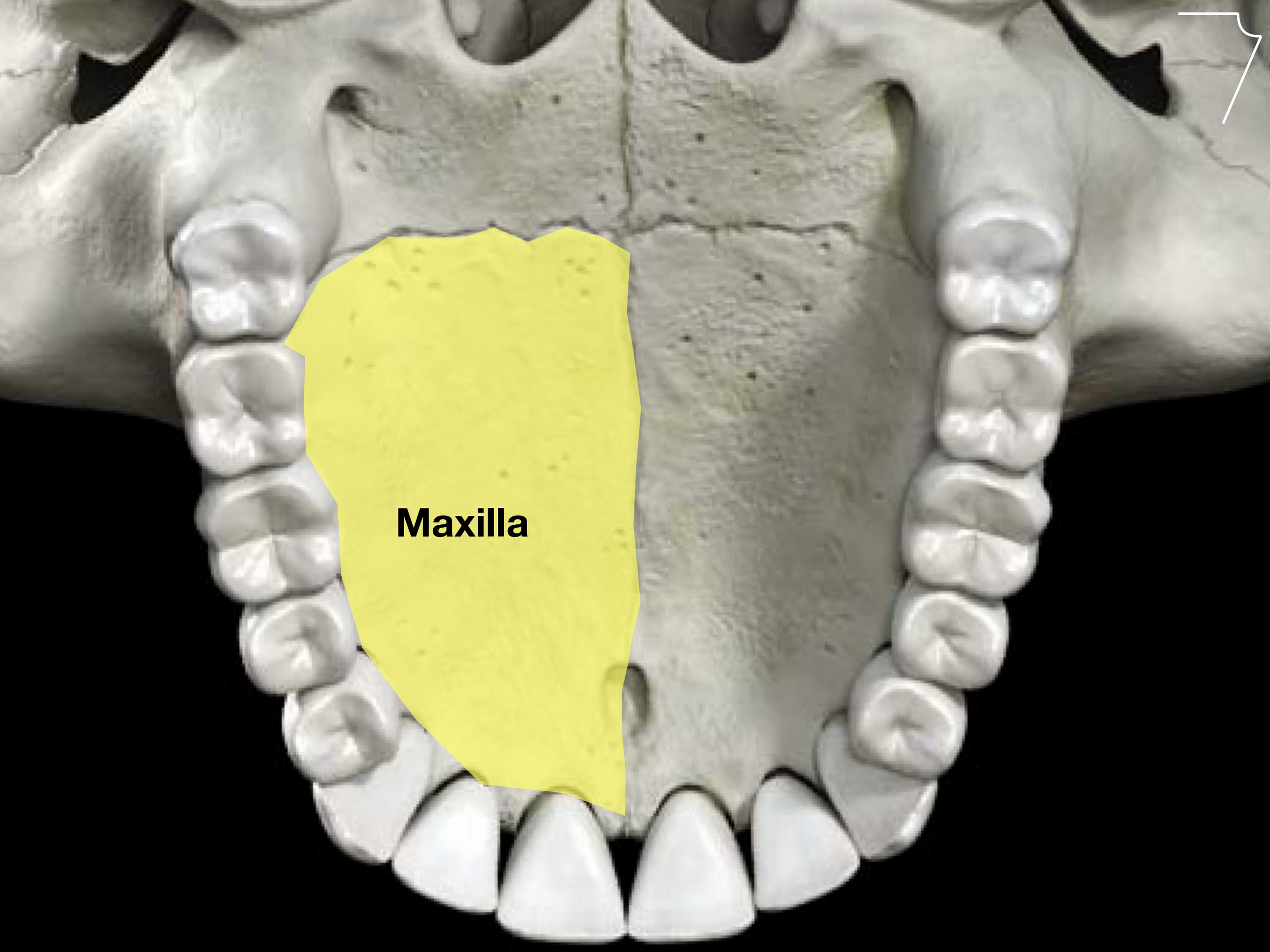
Maxilla

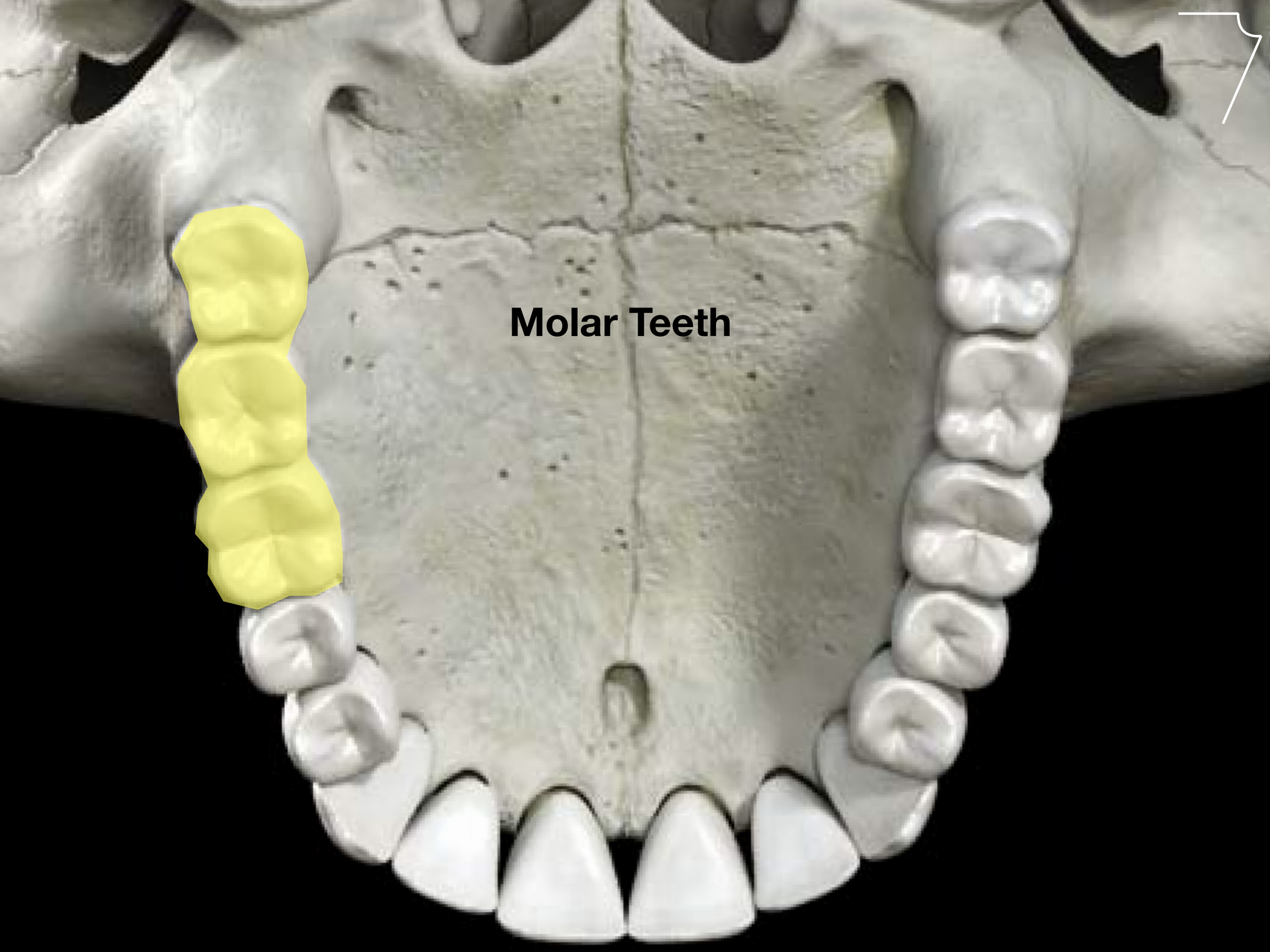
Molar Teeth

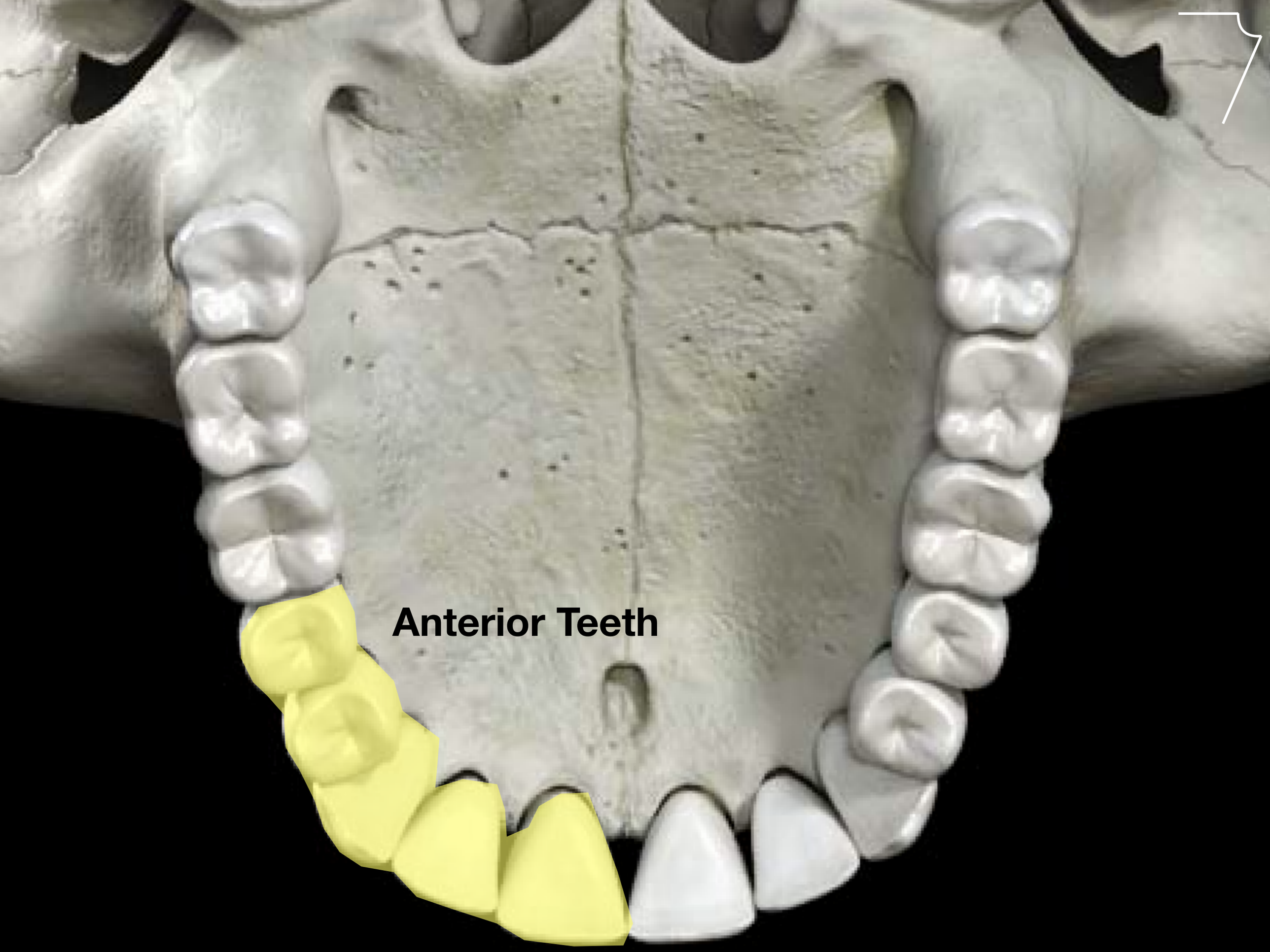
Anterior Teeth

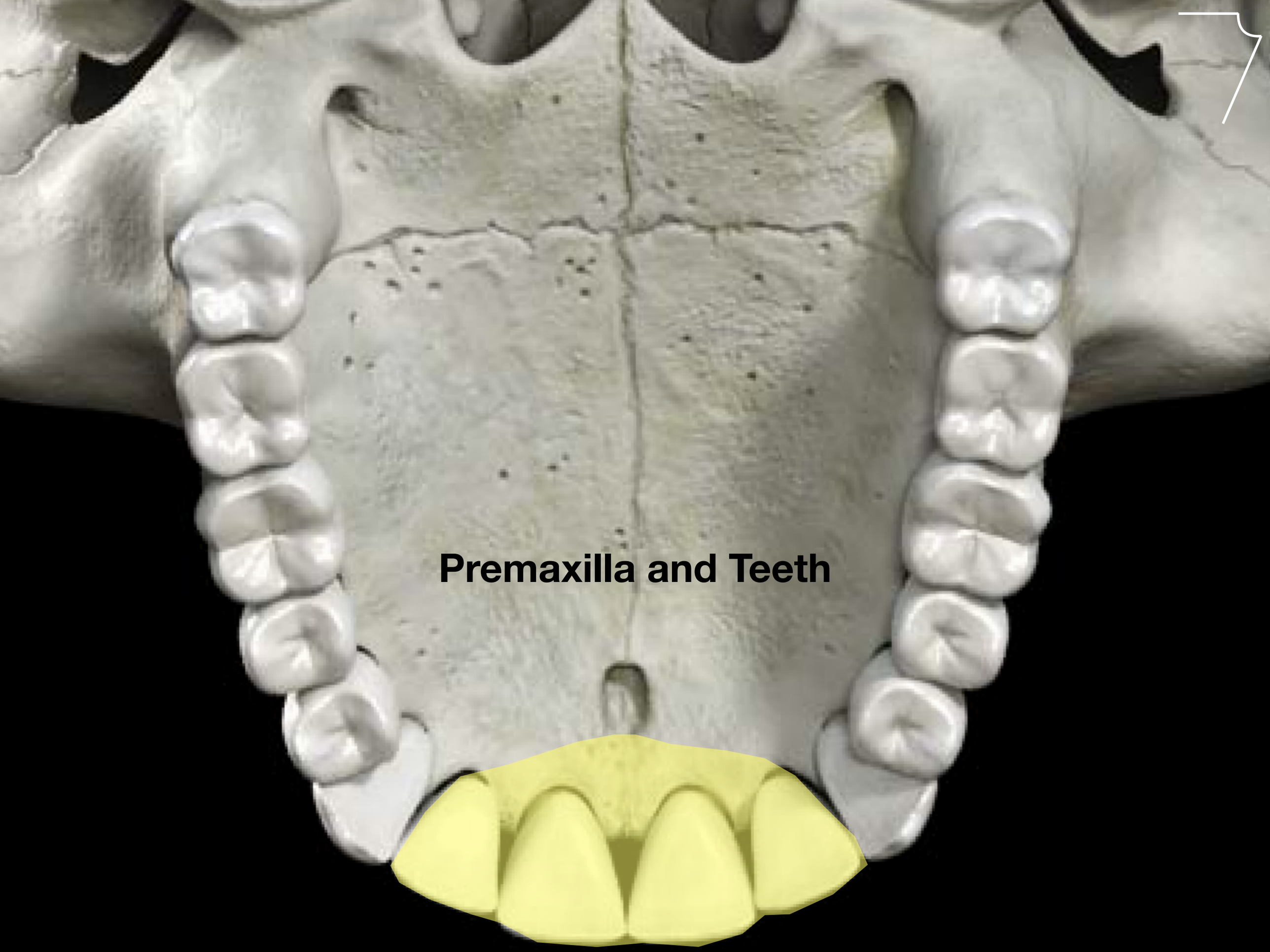
Premaxilla and Teeth

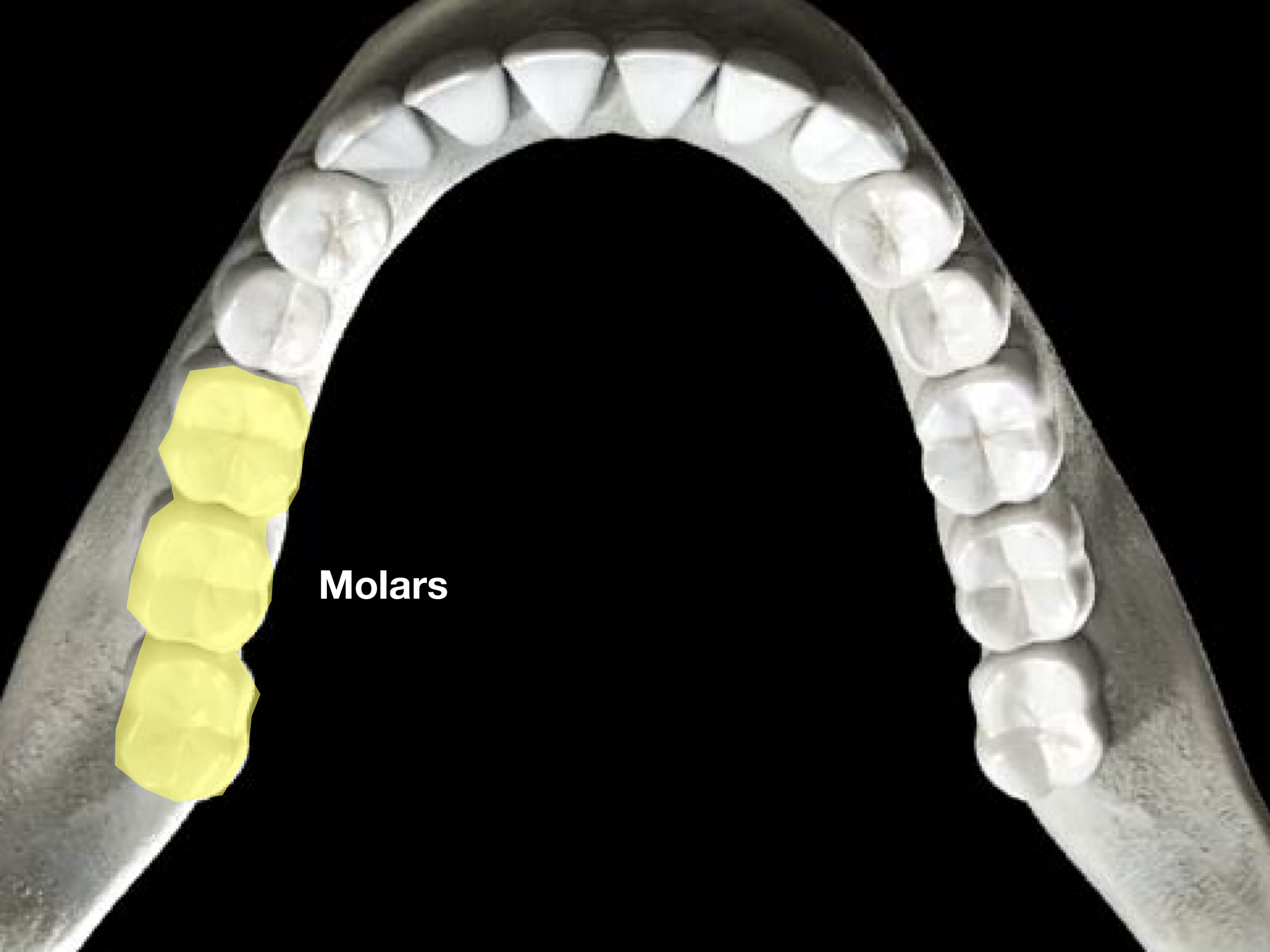
Molars

Anterior Teeth

Symphysis Menti
and Teeth

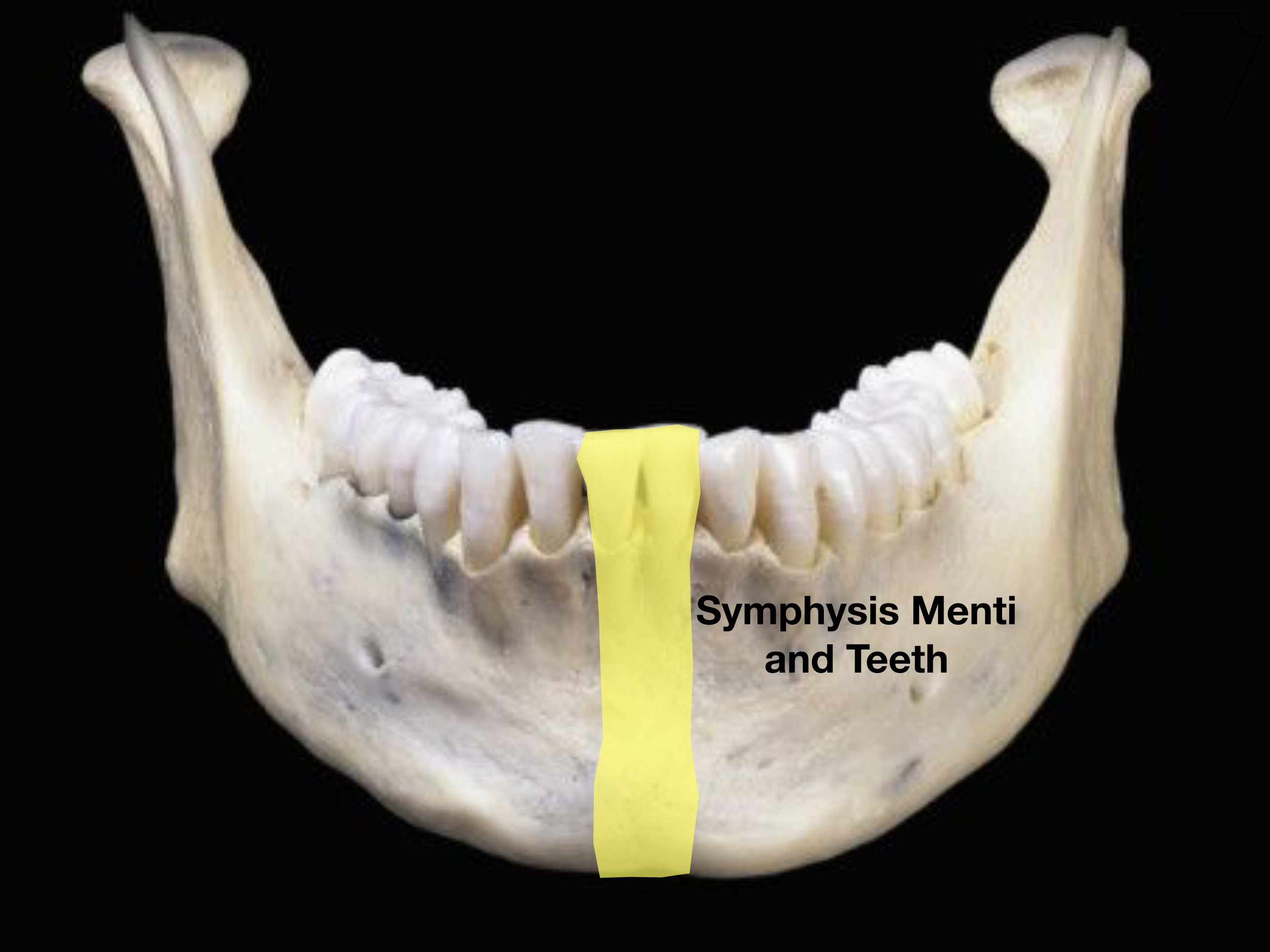
Symphysis Menti
and Teeth

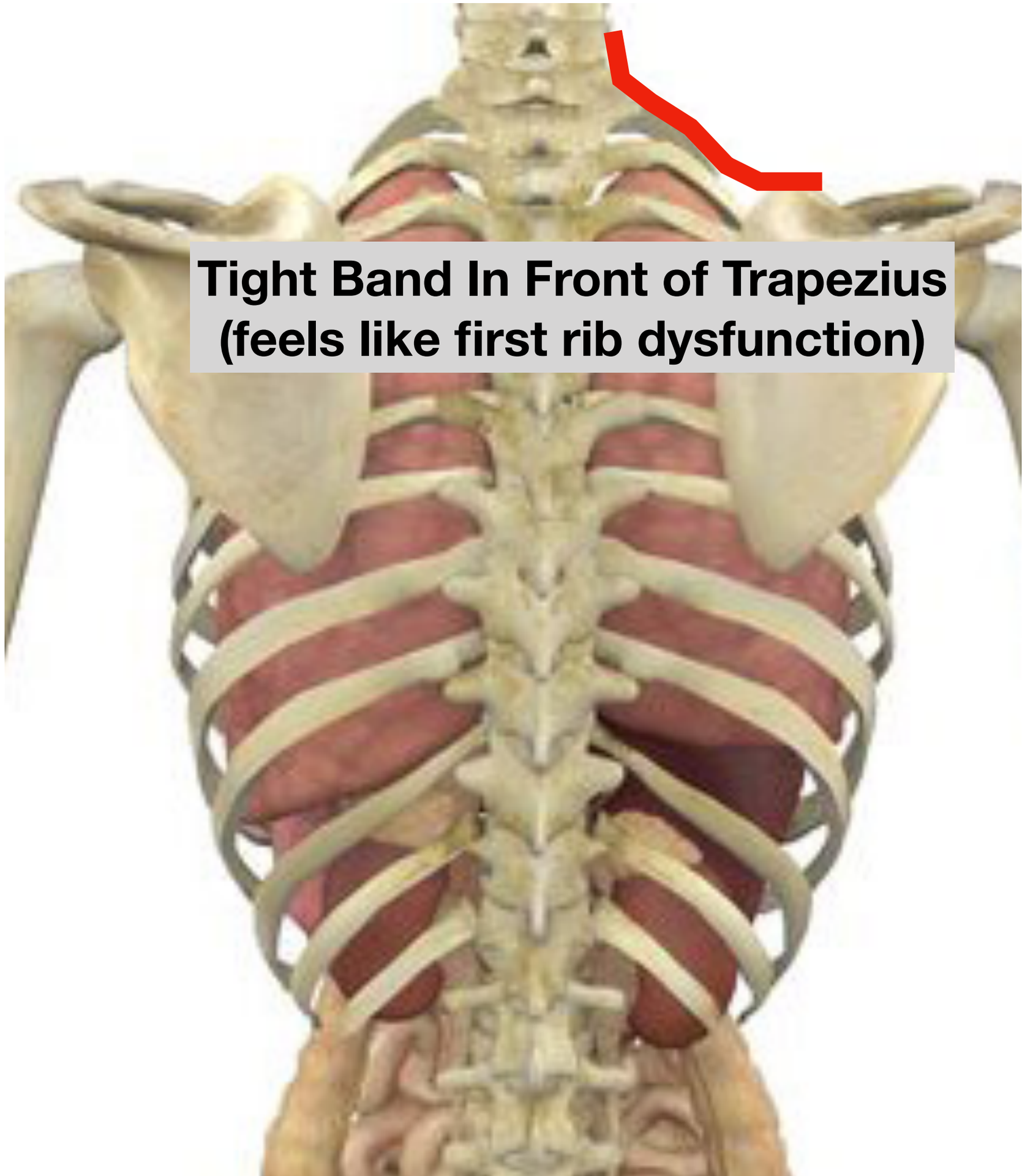
Tight Band In Front of Trapezius
(feels like first rib dysfunction)

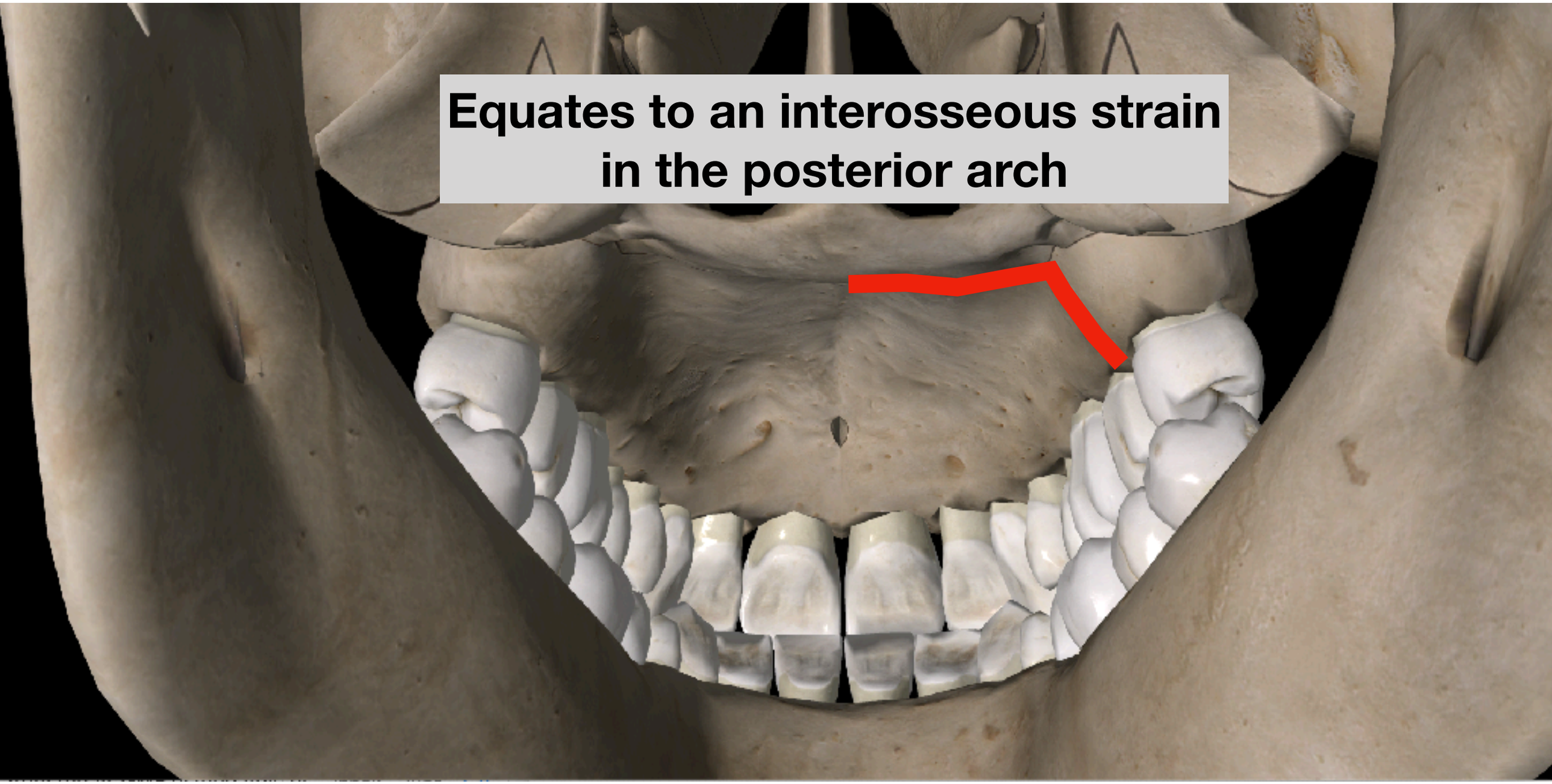
Equates to an interosseous strain
in the posterior arch

Lab

This is an overview of the entire map

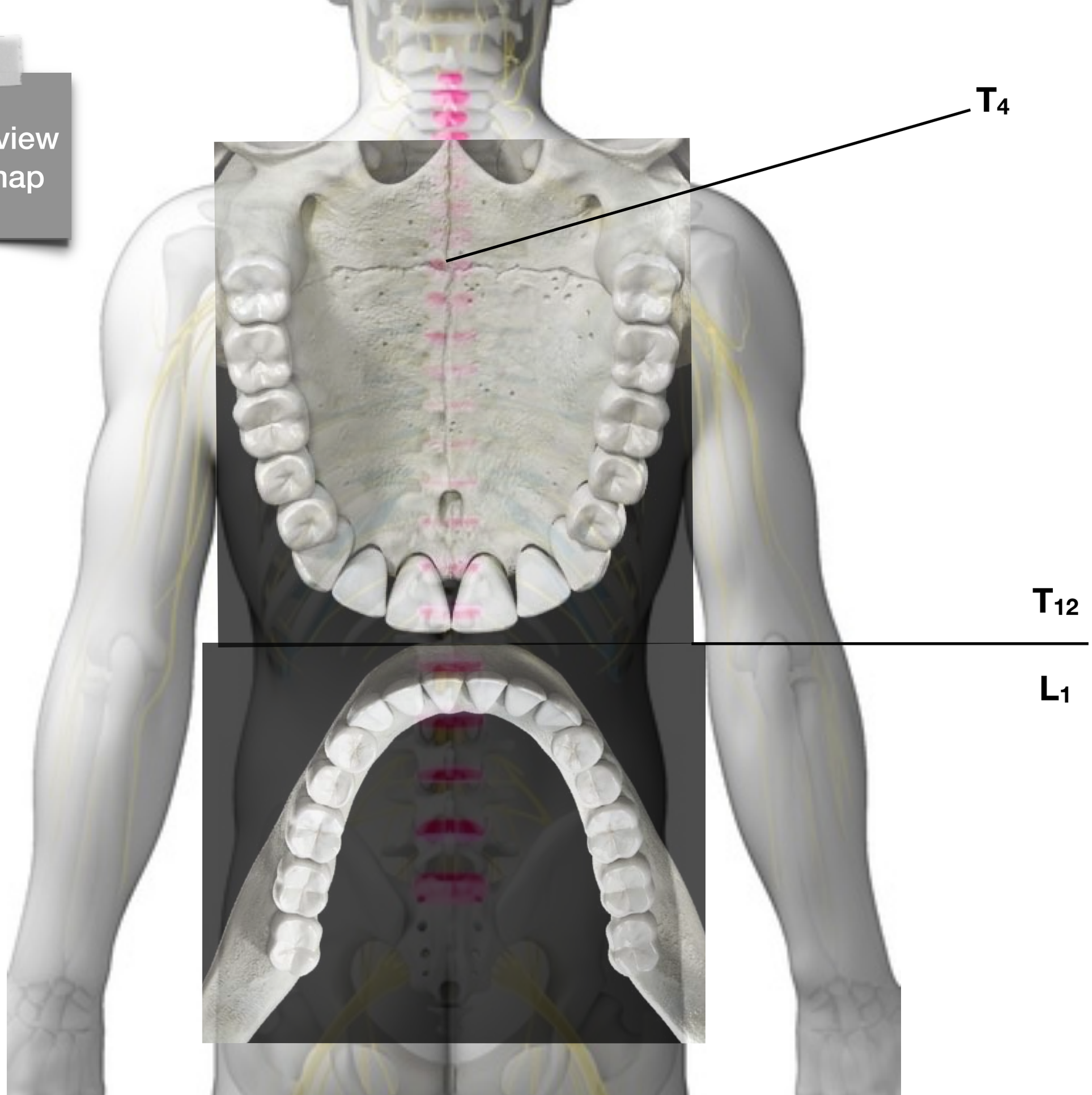

Relating to the Cranial Fossa’s



“I am thankful for all of those who said NO to me.
Its because of them I’m doing it myself.”

–Albert Einstein

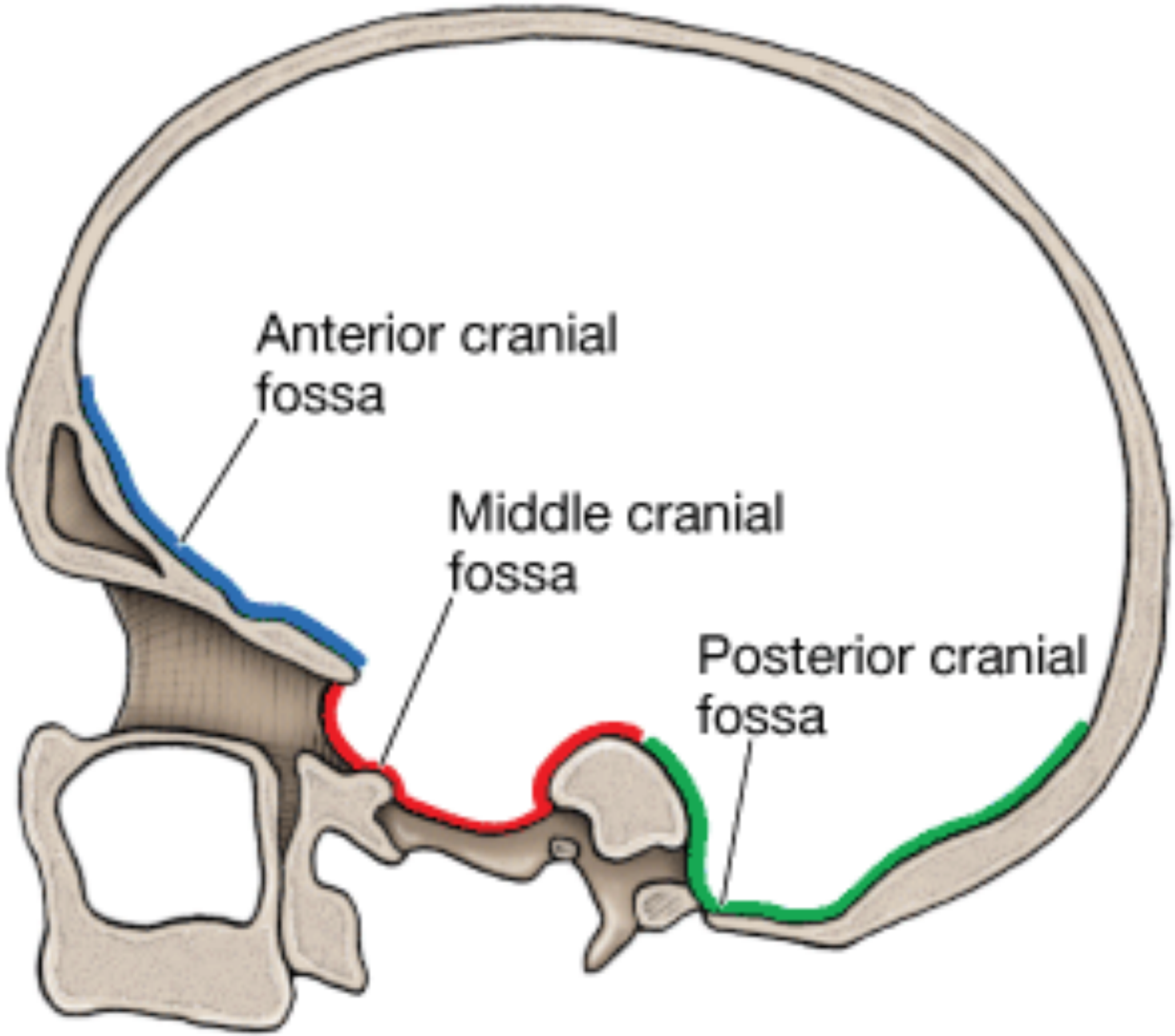
Anterior cranial fossa
Middle cranial fossa
Posterior cranial fossa

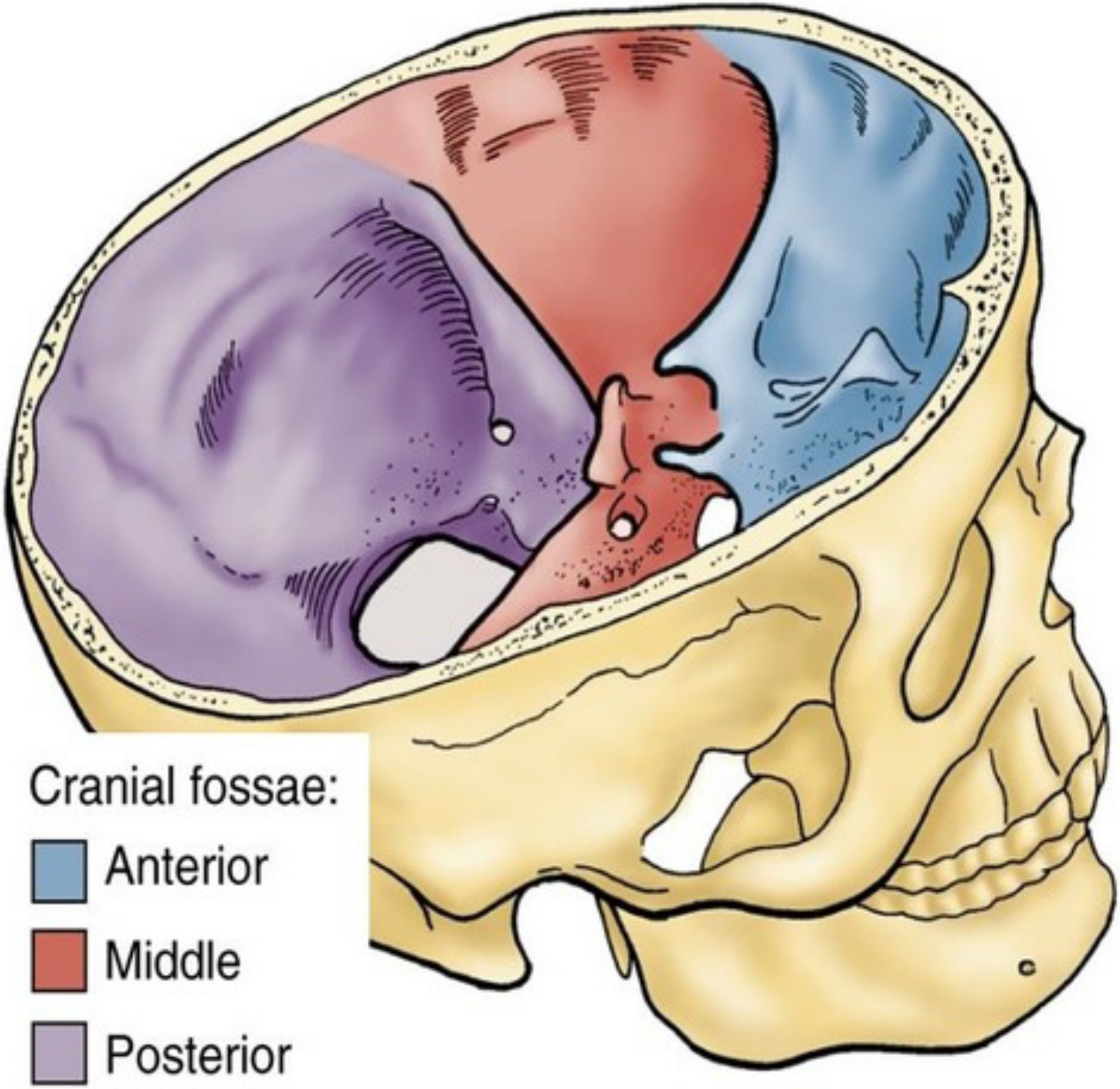
Cranial fossae:
Anterior
Middle
Posterior

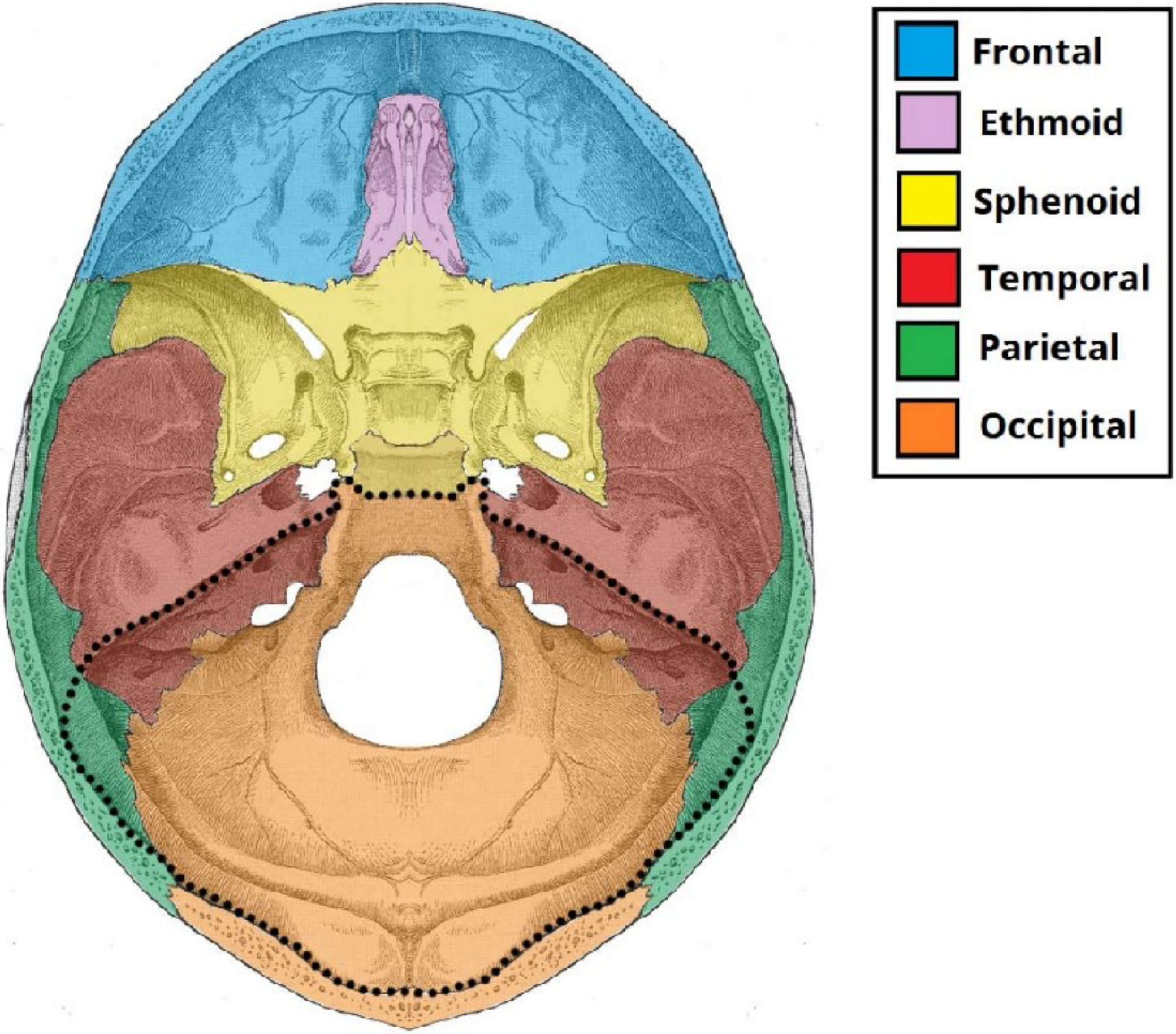
Frontal
Ethmoid
Sphenoid
Temporal
Parietal
Occipital

V1- anterior and middle cranial fossae

V2- anterior and middle cranial fossae

V3- middle cranial fossa

Vagus, Hypoglossal, Upper 3 Cervical Vertebra - posterior cranial fossa

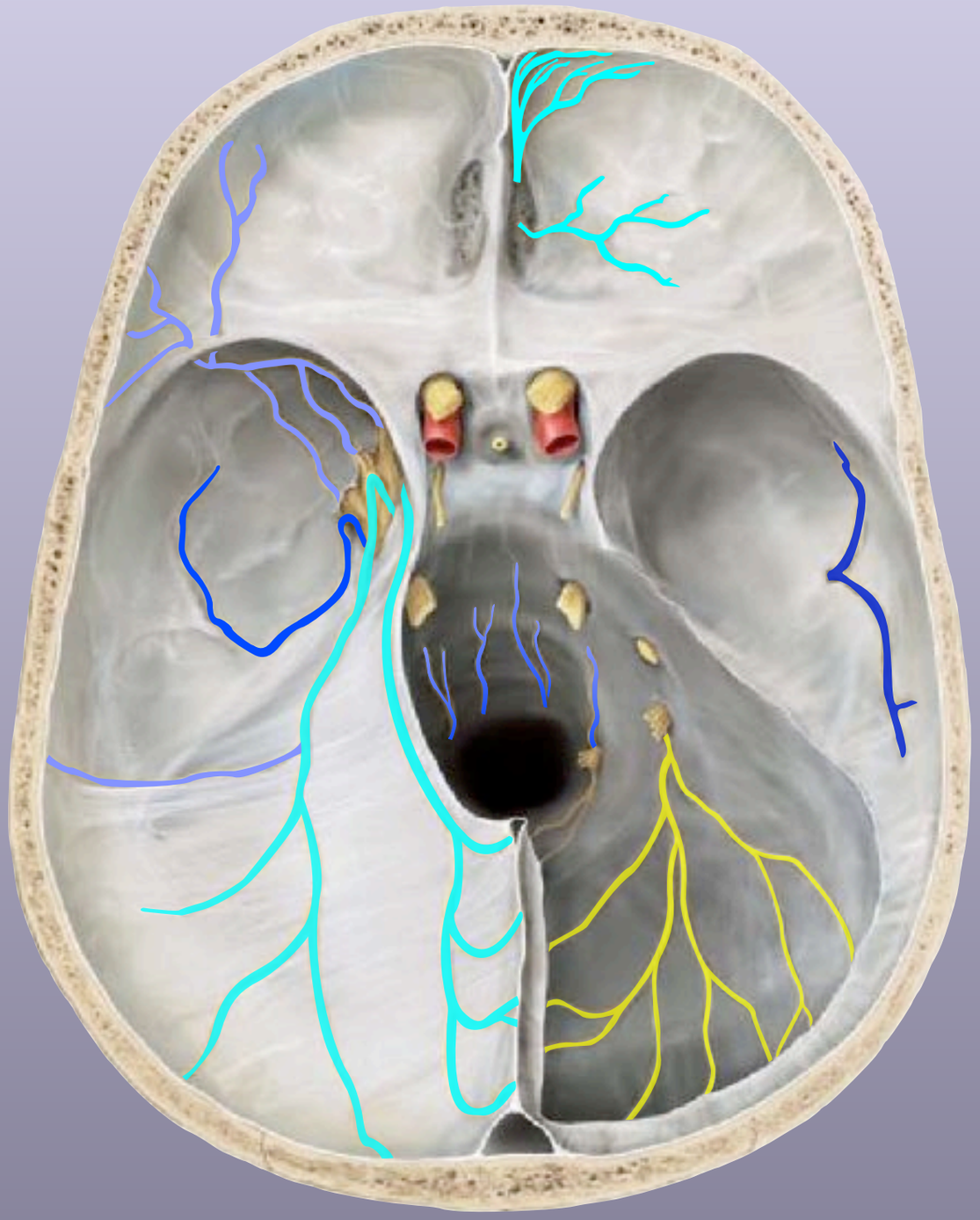

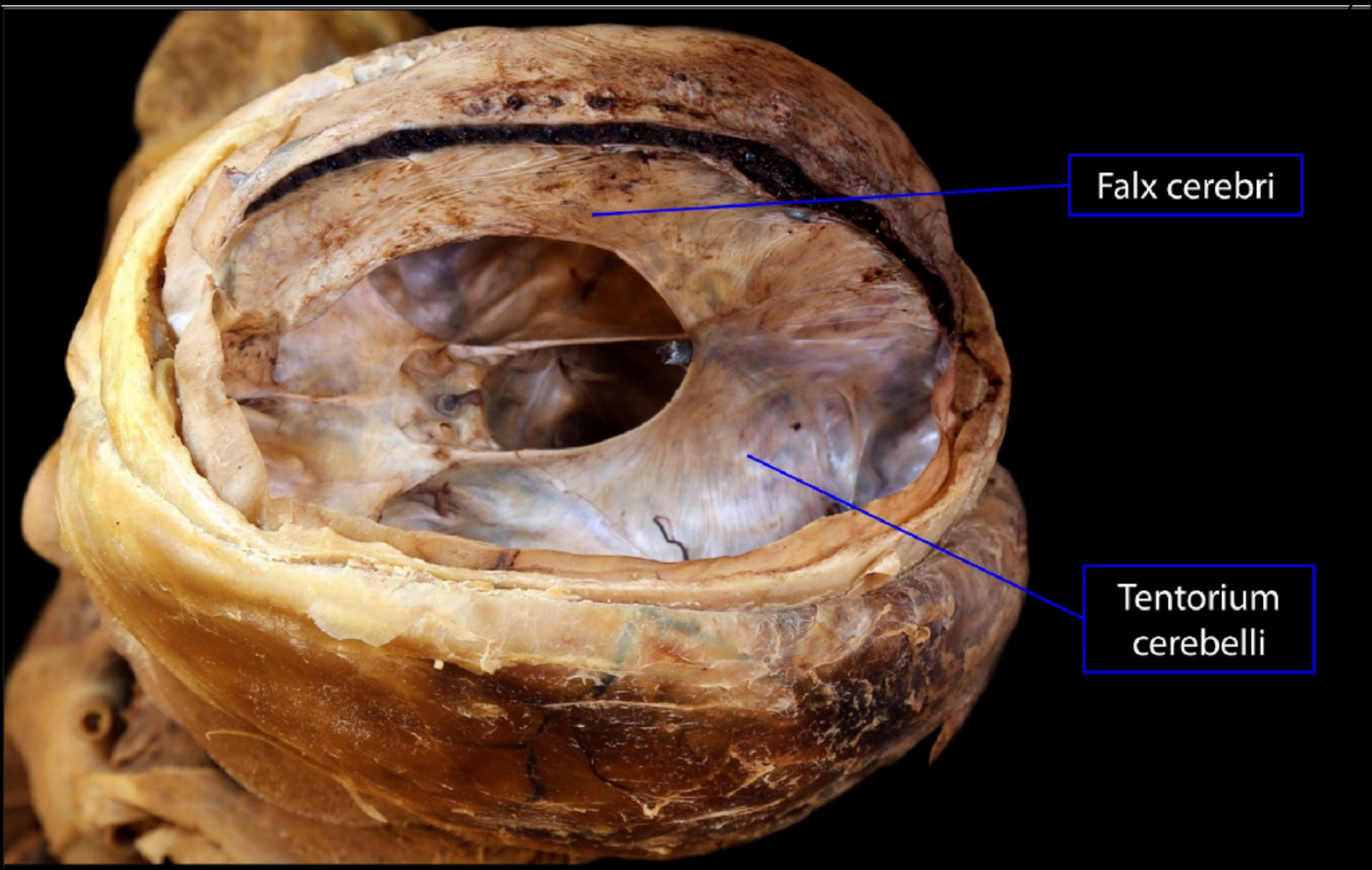
Falx cerebri
Tentorium cerebelli

Dural Partitions

Superior view

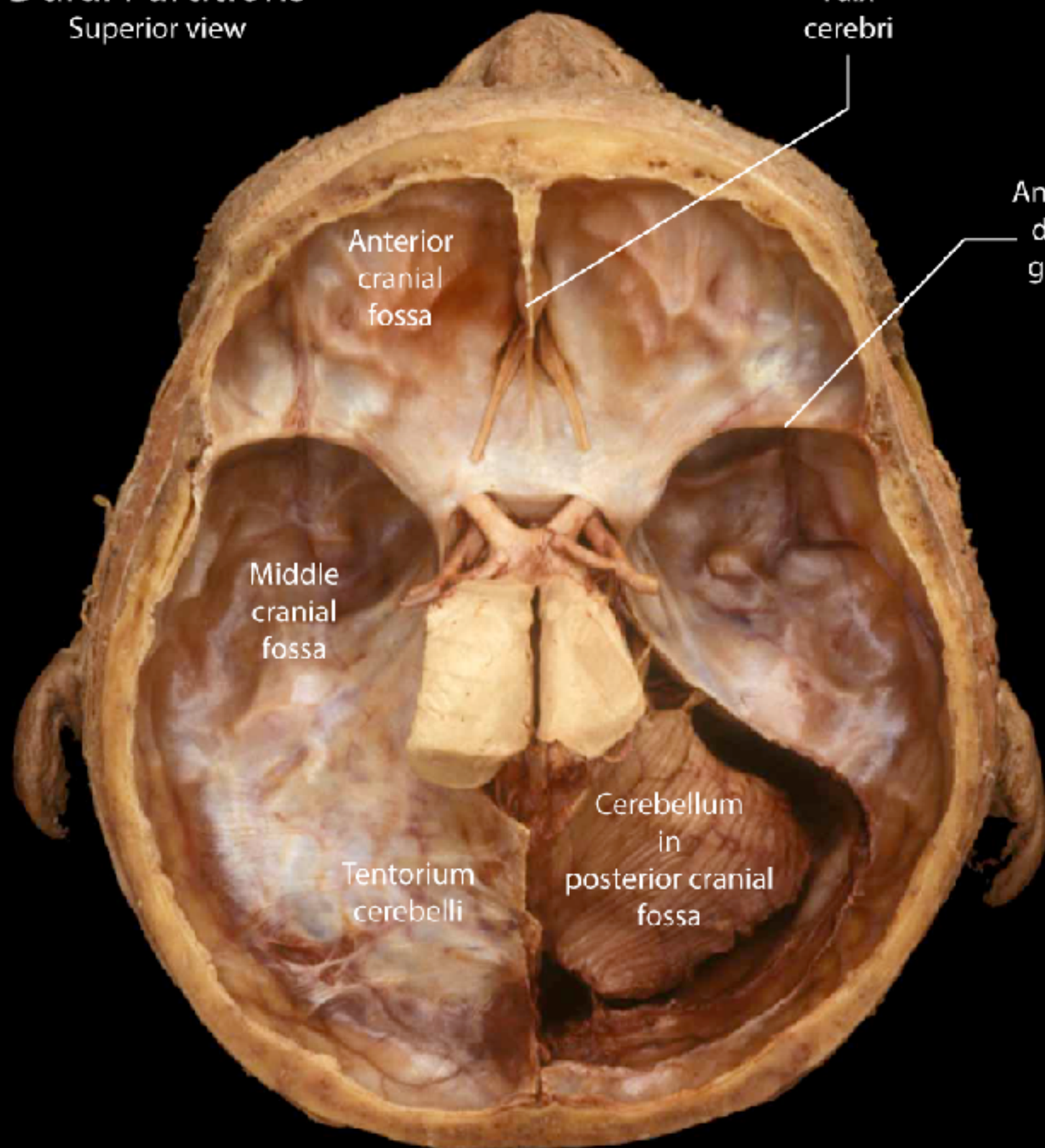

Dural Partitions

Superior view

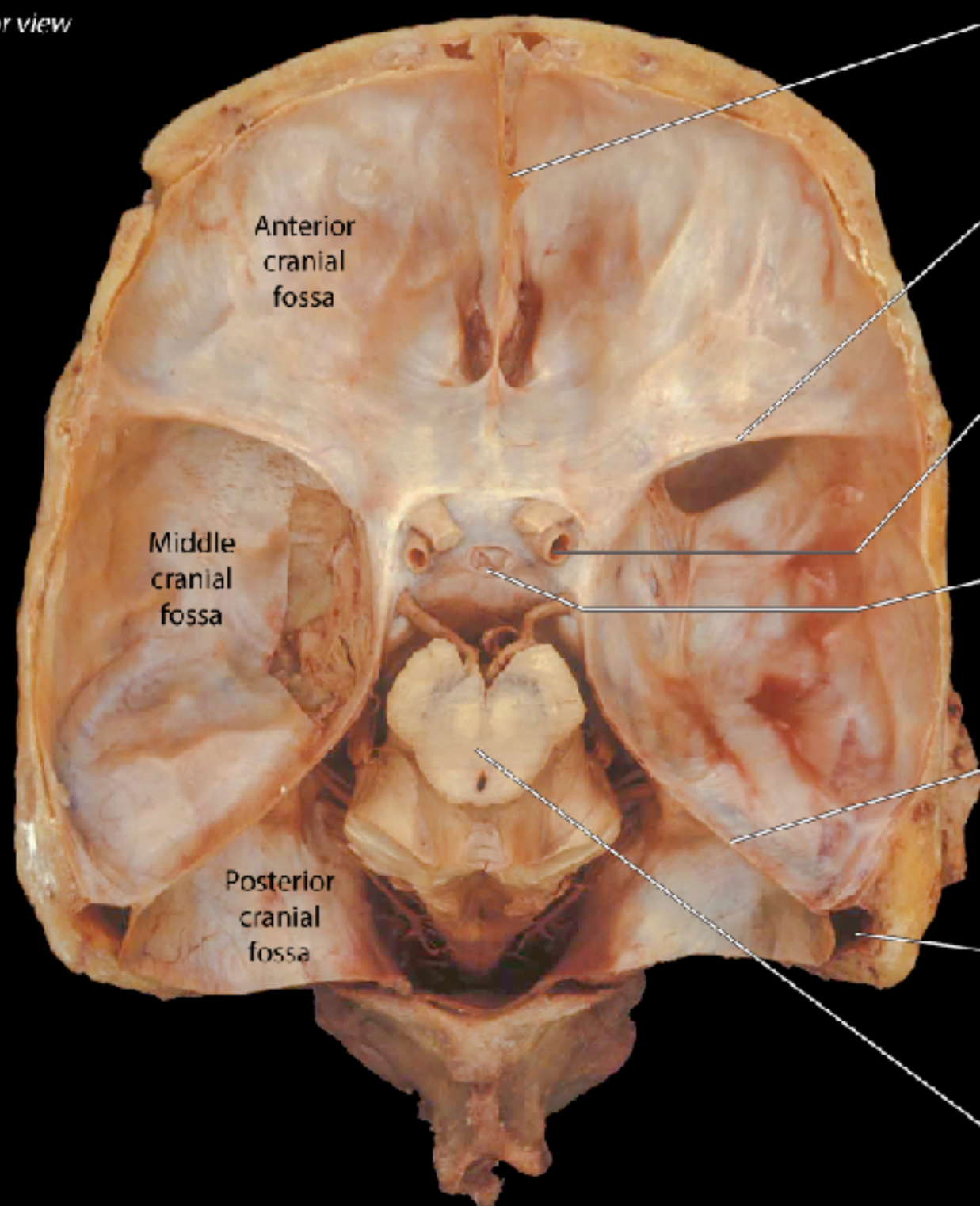

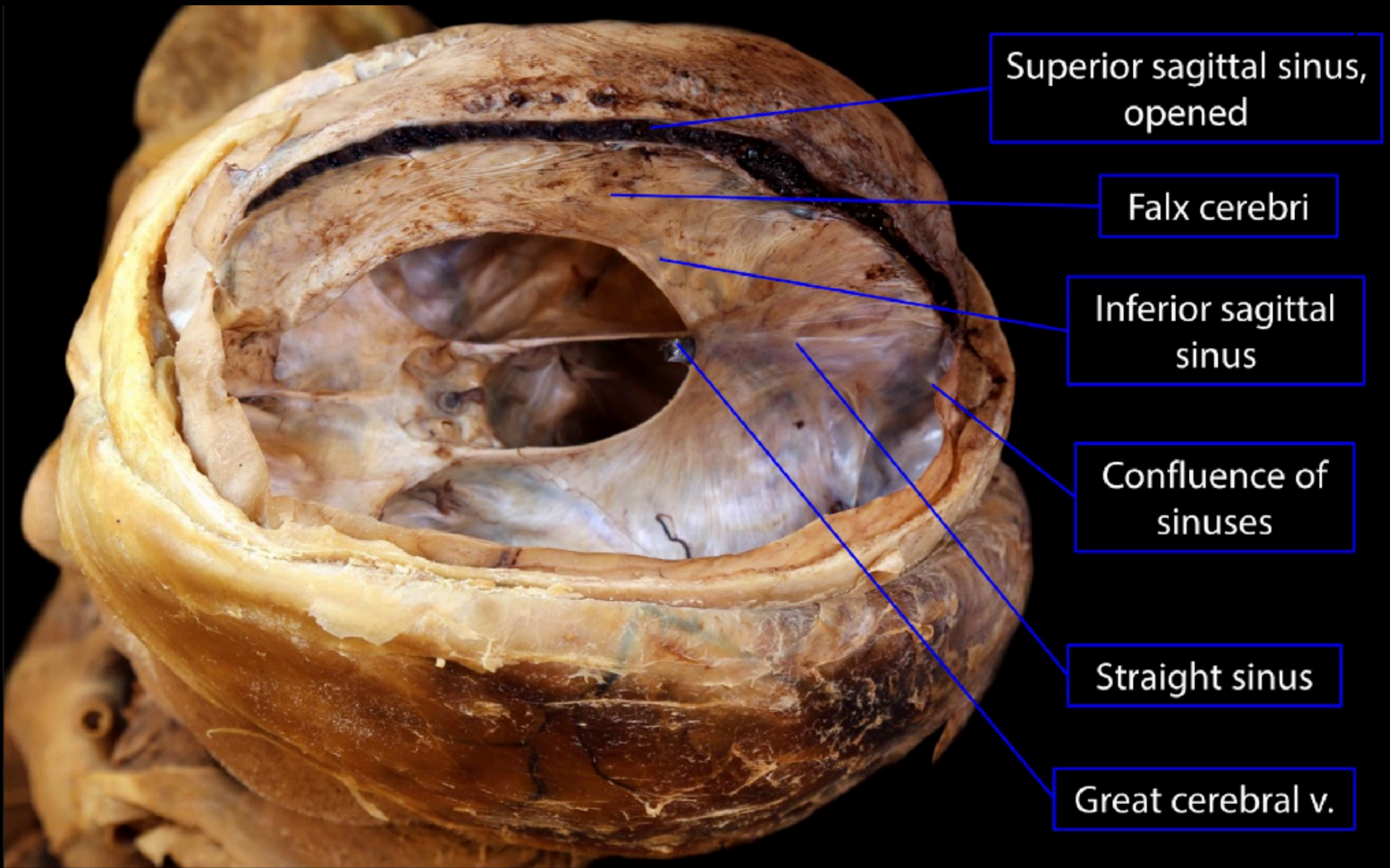
Superior sagittal sinus, opened
Falx cerebri
Inferior sagittal sinus
Confluence of sinuses
Straight sinus
Great cerebral v.

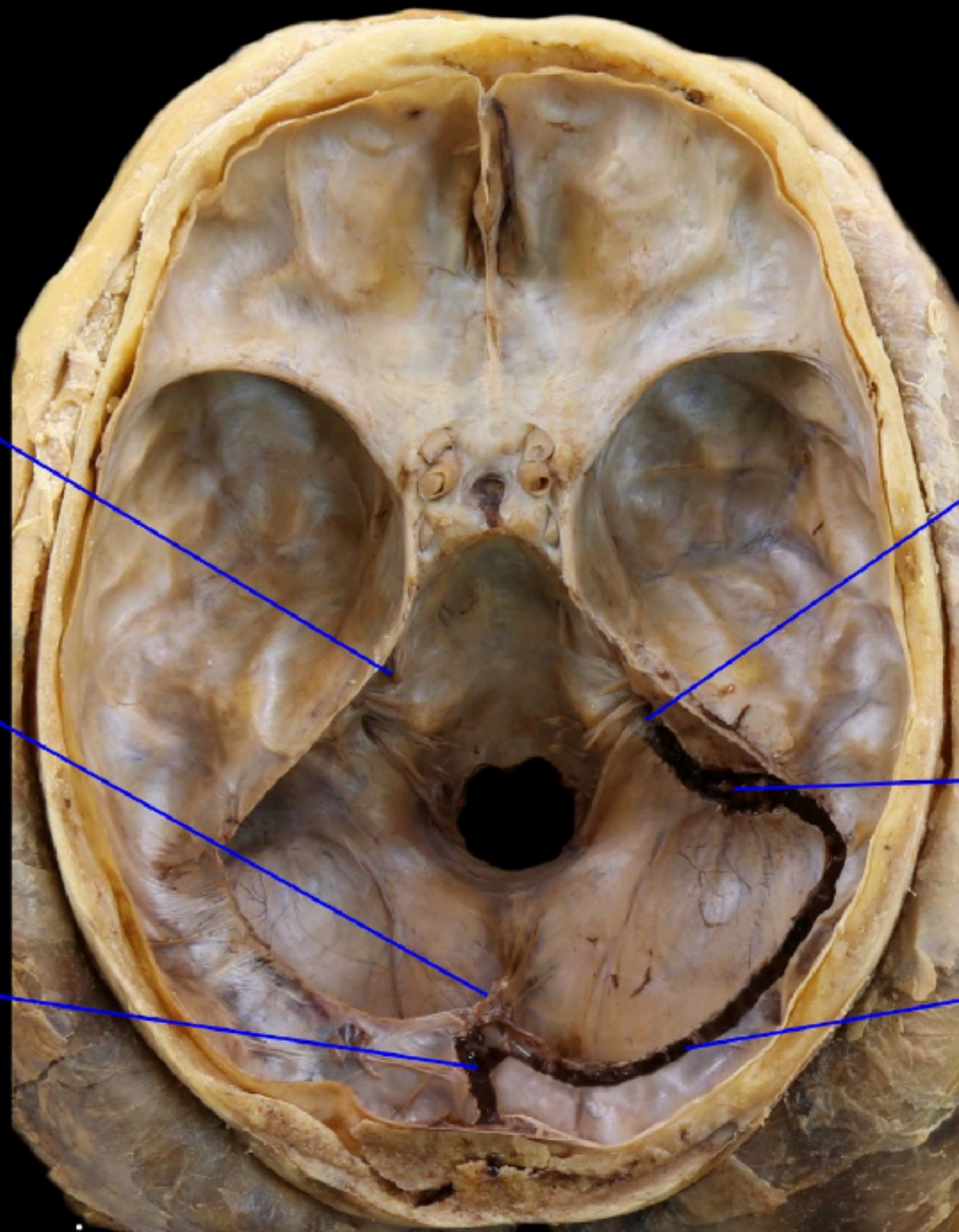

Cranial cavity, superior

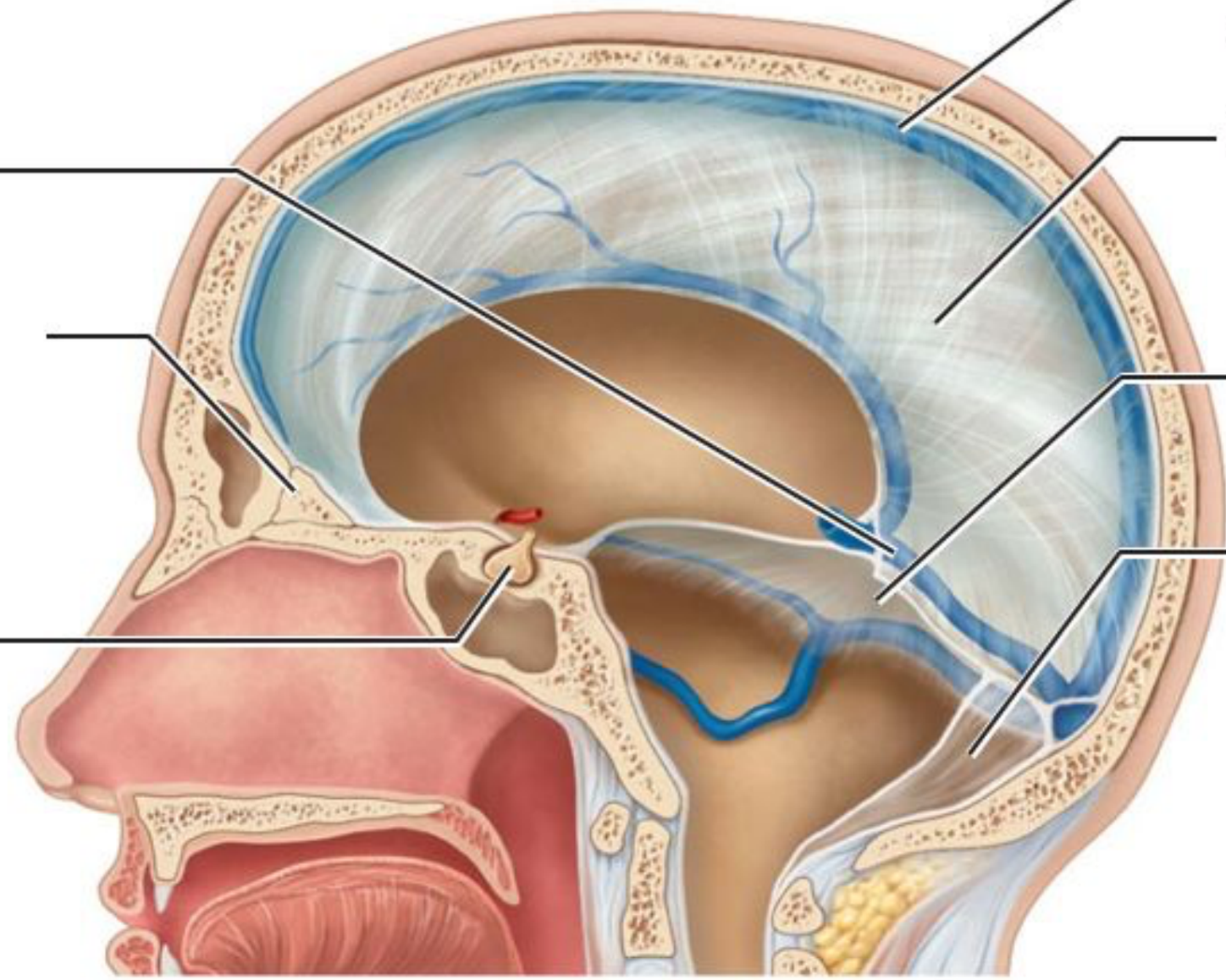
Superior sagittal sinus
Falx cerebri
Straight sinus
Crista galli of the ethmoid bone
Tentorium cerebelli
Falx cerebelli
Pituitary gland

Cranium 02

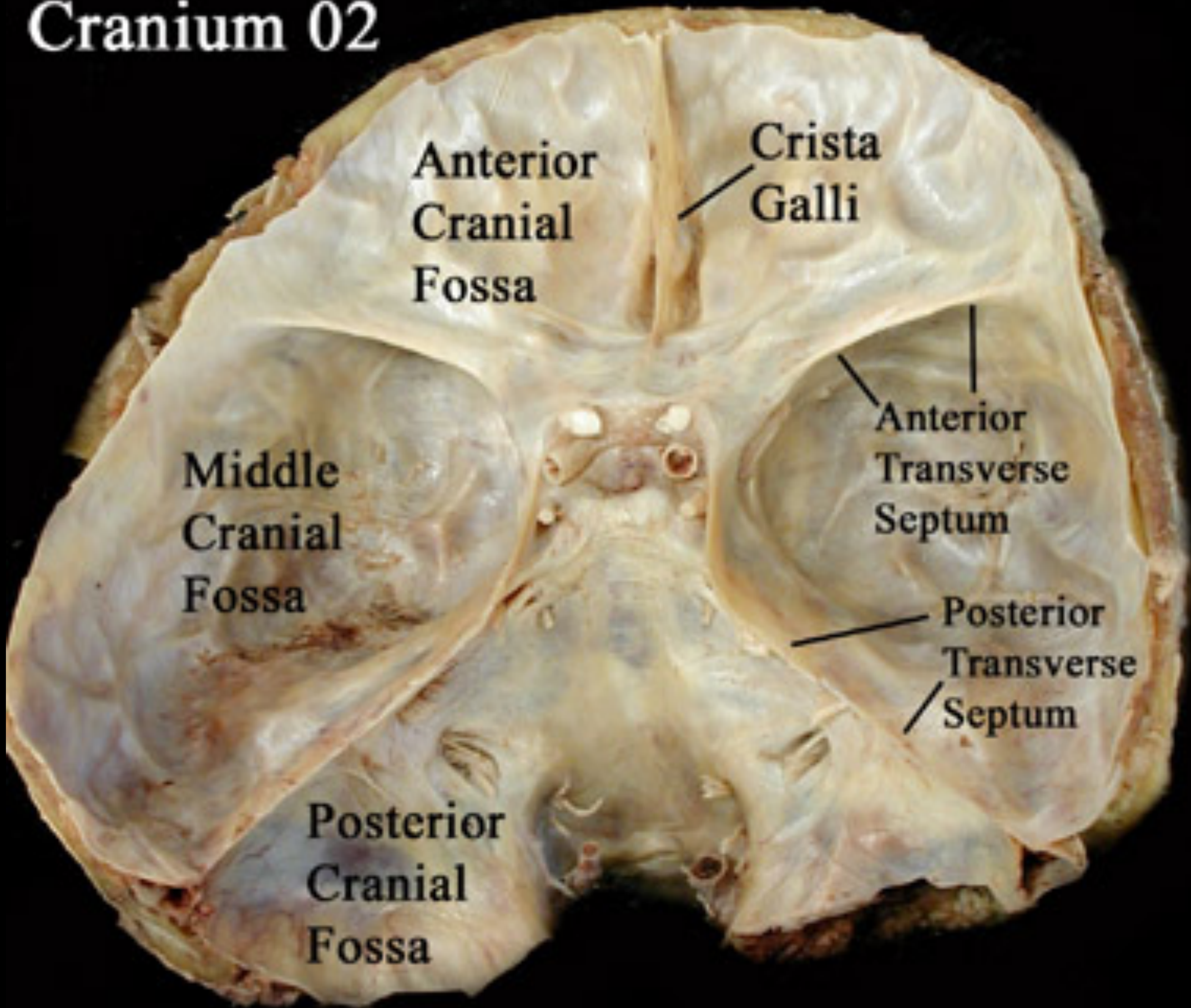
Anterior Cranial Fossa
Crista Galli
Middle Cranial Fossa
Anterior Transverse Septum
Posterior Transverse Septum
Posterior Cranial Fossa

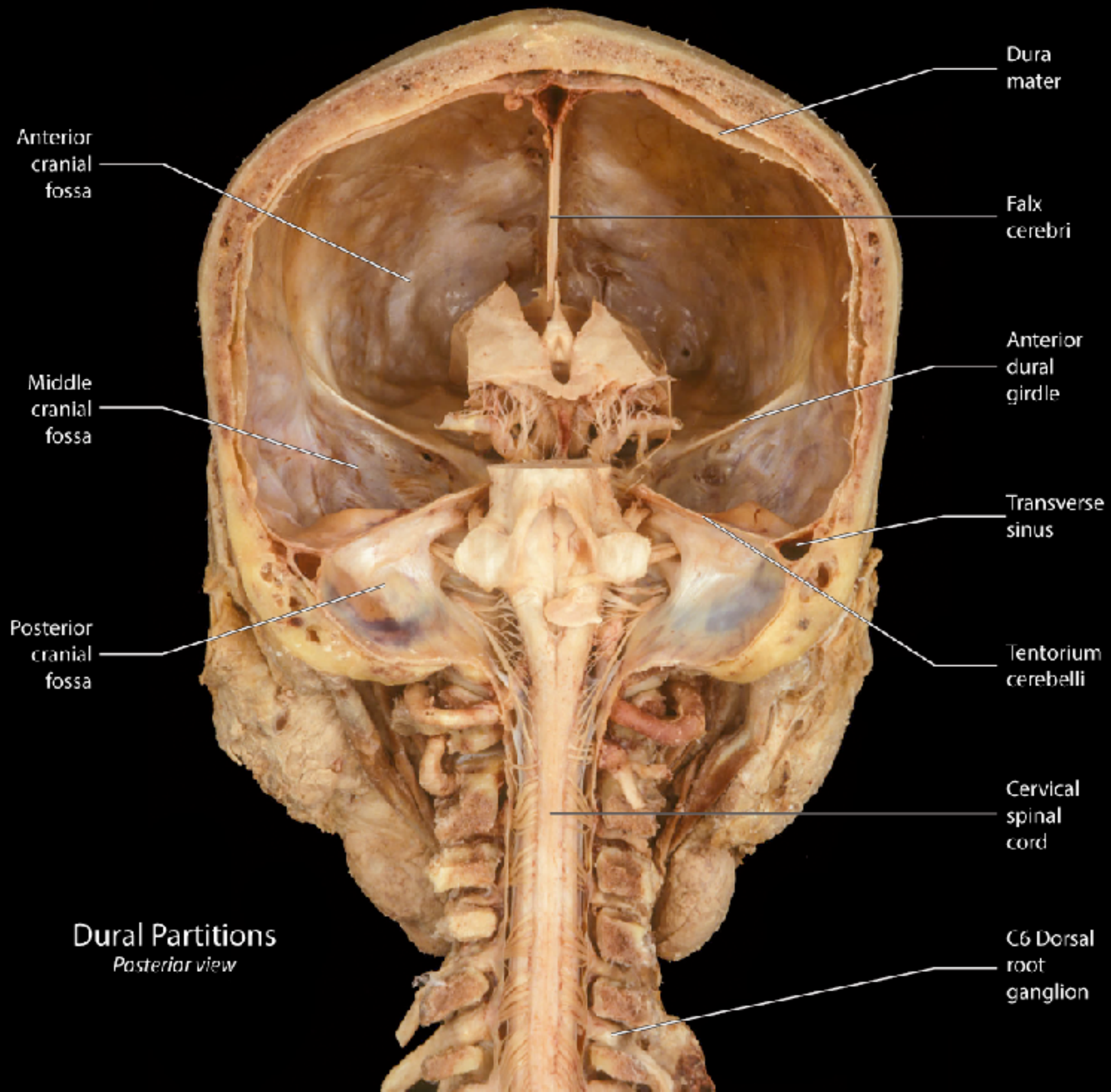

Dural Partitions

Posterior view

Dural Partitions

Superior view

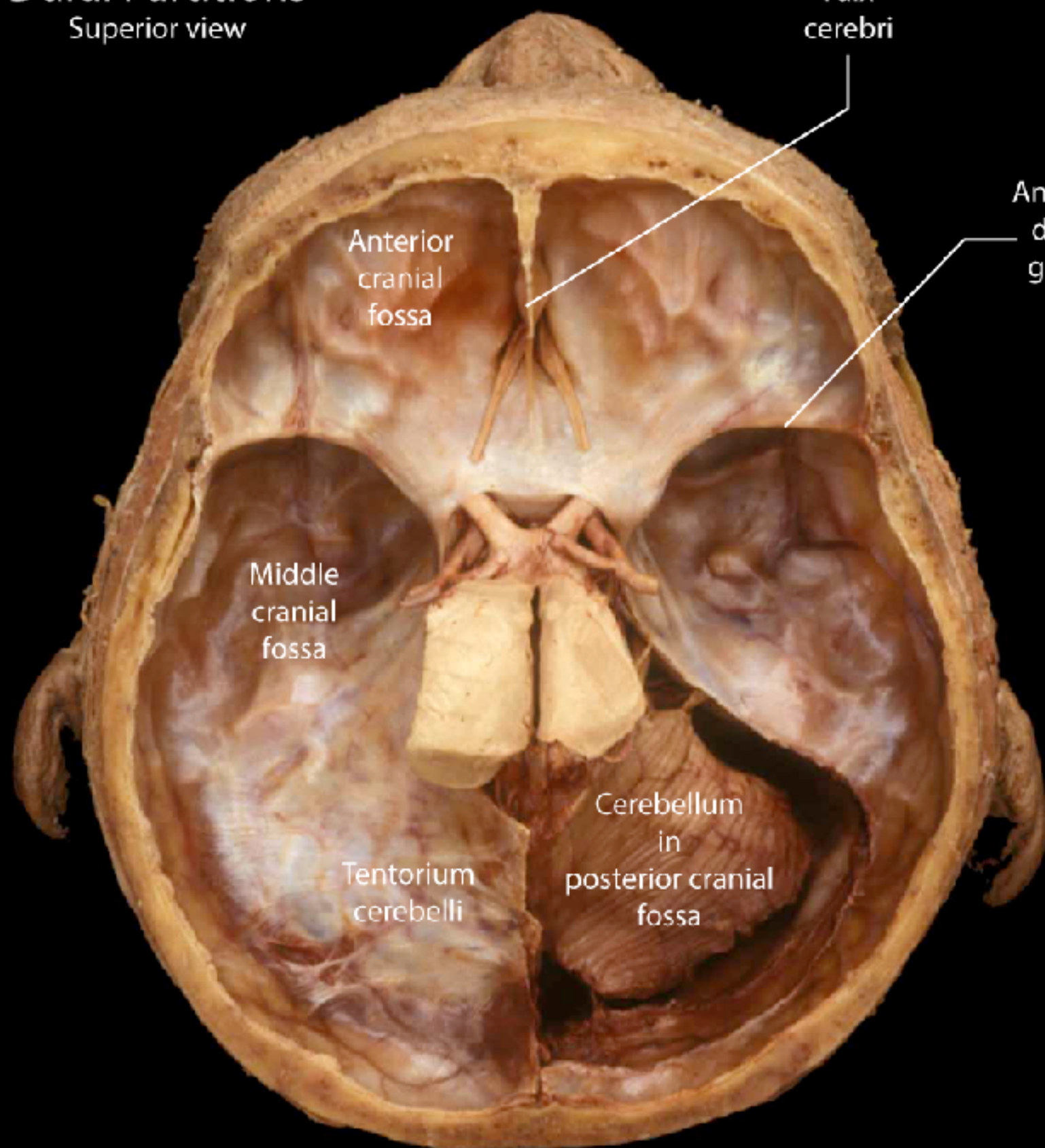

Innervation

- The dura mater in the anterior and the middle **cranial fossae** is sensory **innervated** by the trigeminal nerve.
- The dura in the **posterior fossa** is supplied by the upper three cervical nerves and by branches from the vagus (X) and hypoglossal (XII) **cranial** nerves.

This is where the anterior fossa issues will show up in the body

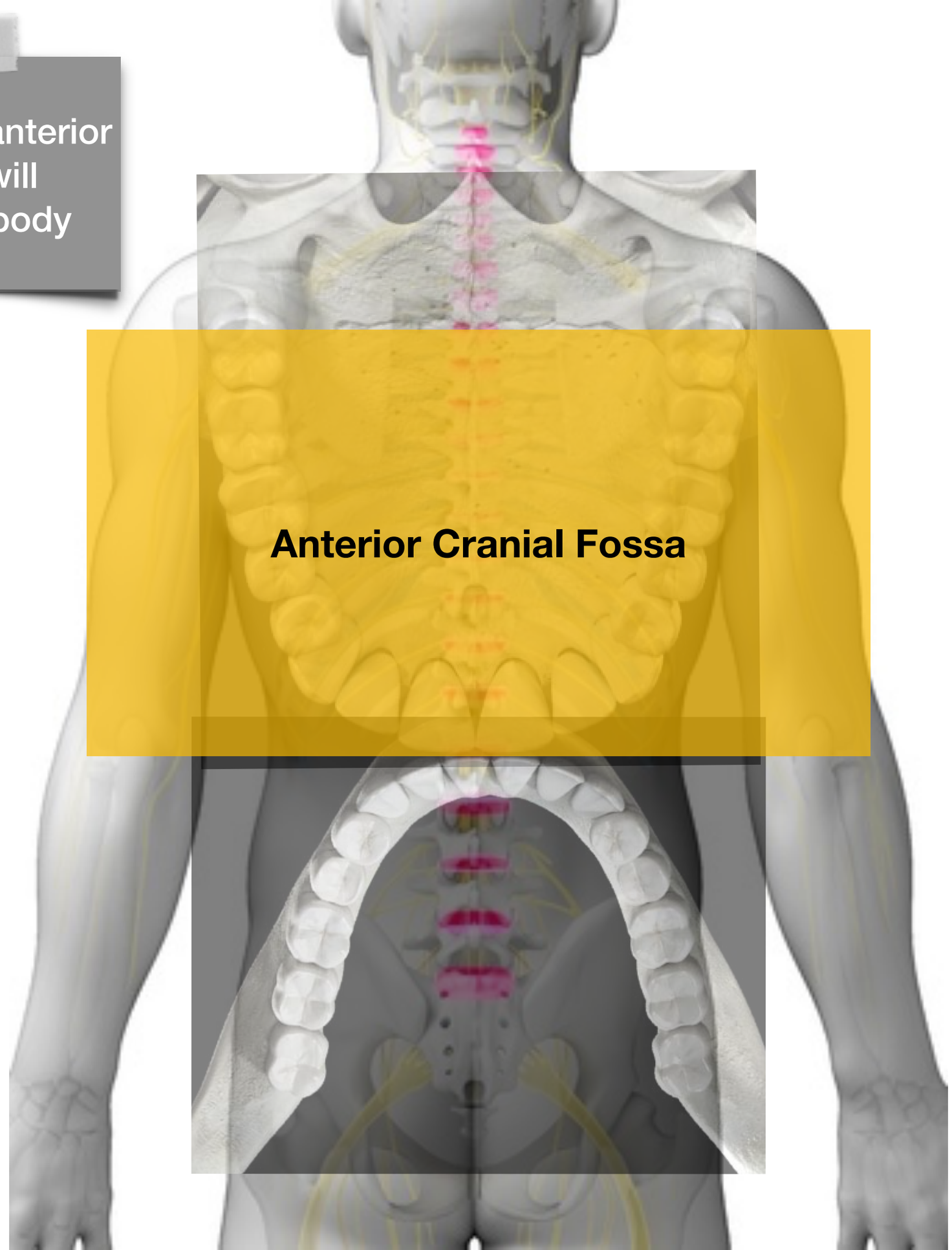

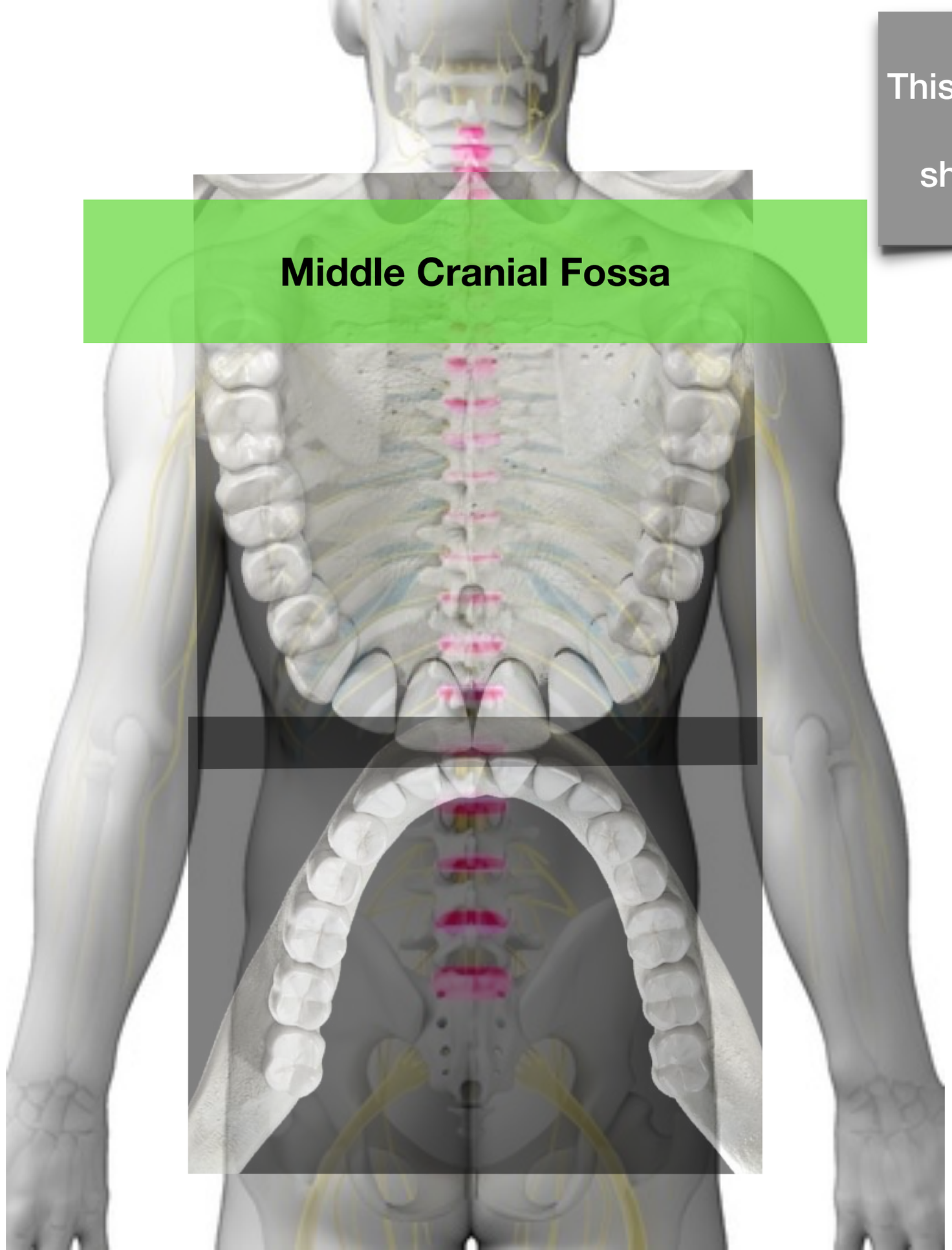

This is where the middle fossa issues will show up in the body

This is where the posterior fossa issues will show up in the body

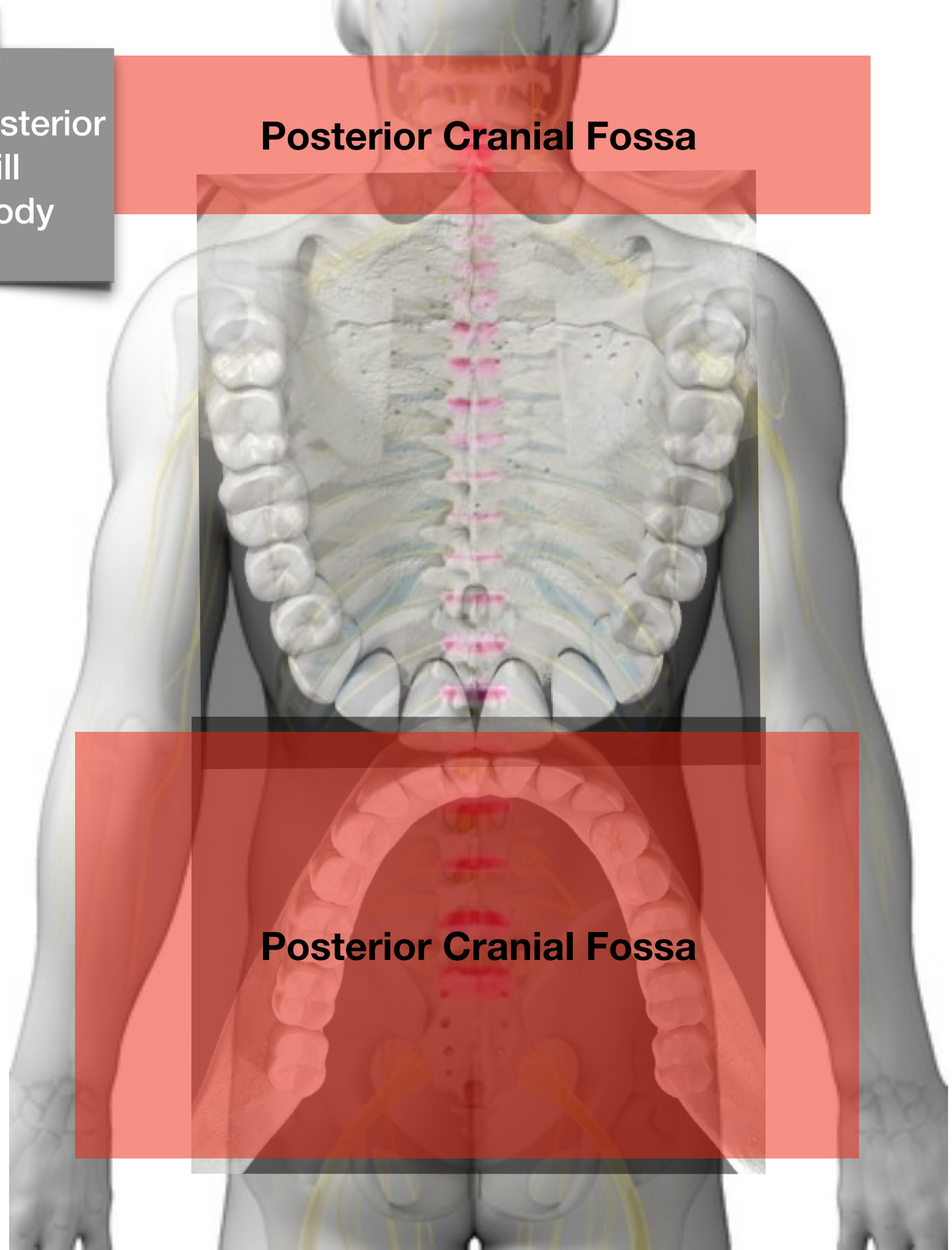

Lab

Lab

- The take home message here is that, if you have a middle cranial fossa restriction/dysfunction, it will show up in the body in the indicated area….in one or more places there.

- And, until treated appropriately, will continue to return the dysfunction in that area…and have effects on the organs…and the vertebra…and the fascia…, etc…

Lab

- That means that a TEAM approach is important, because if YOU can’t correct the issue, the patient continues to suffer…

“Find it, fix it and leave it alone.”

–AT Still

Thoughts on the intermaxillary suture

Cranial Strains

(and how to correct them using the ALF)



“All that is valuable in human society depends upon the opportunity for development accorded the individual.”

–Albert Einstein

ALF Appliance Basic Anatomy

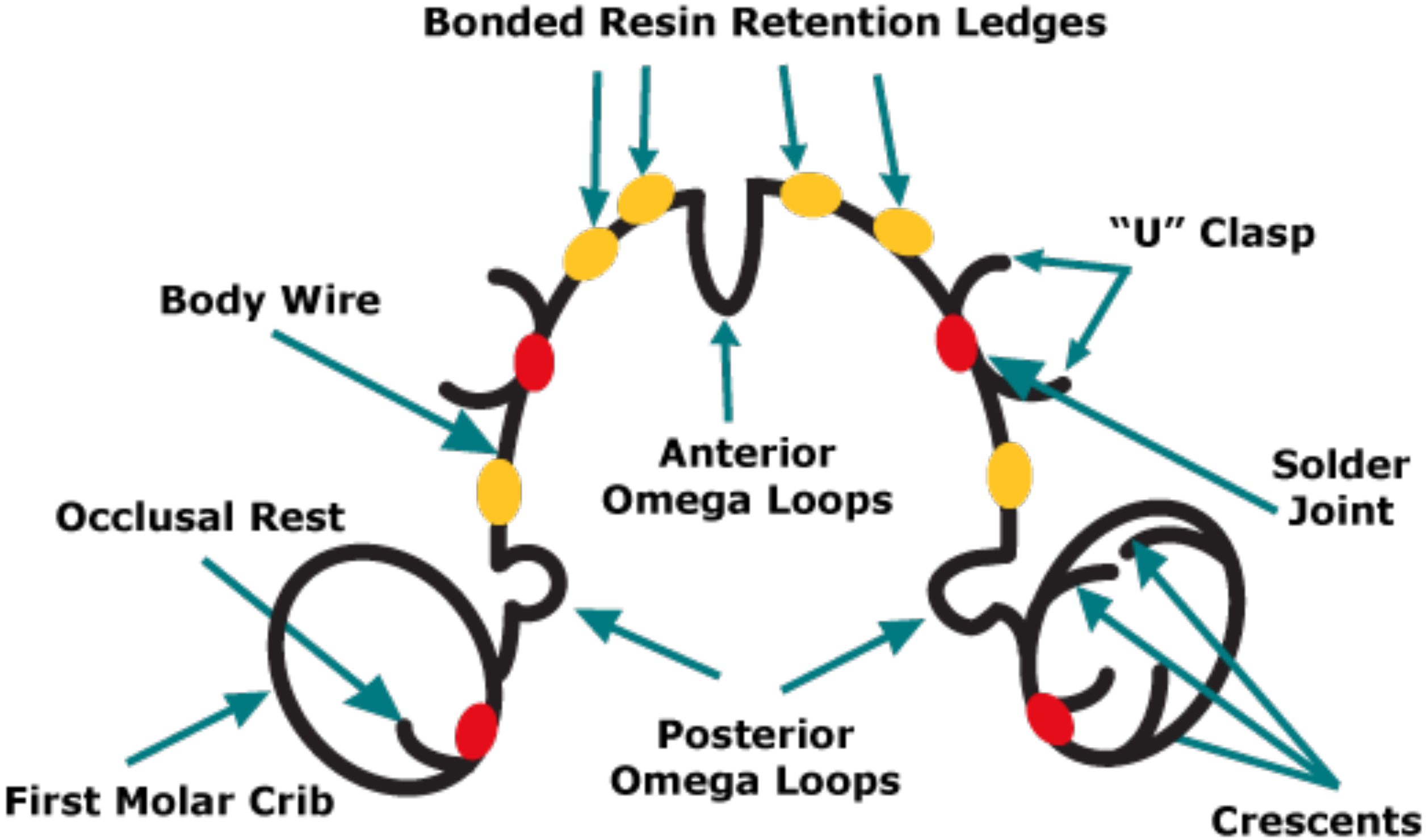

Cranial Strains

- Flexion/Extension
- Torsion
- Sidebending/Rotation
- Vertical Strain
- Lateral Strain
- SBS Compression

Principles

- If you palpate the skull and note one pattern (left side bending, for example), AND then you add the ALF and the pattern changes, that change is due to the ALF.
- The concept is to utilize the ALF to help the body achieve neutral (no dominant pattern) and allow it to grow there.

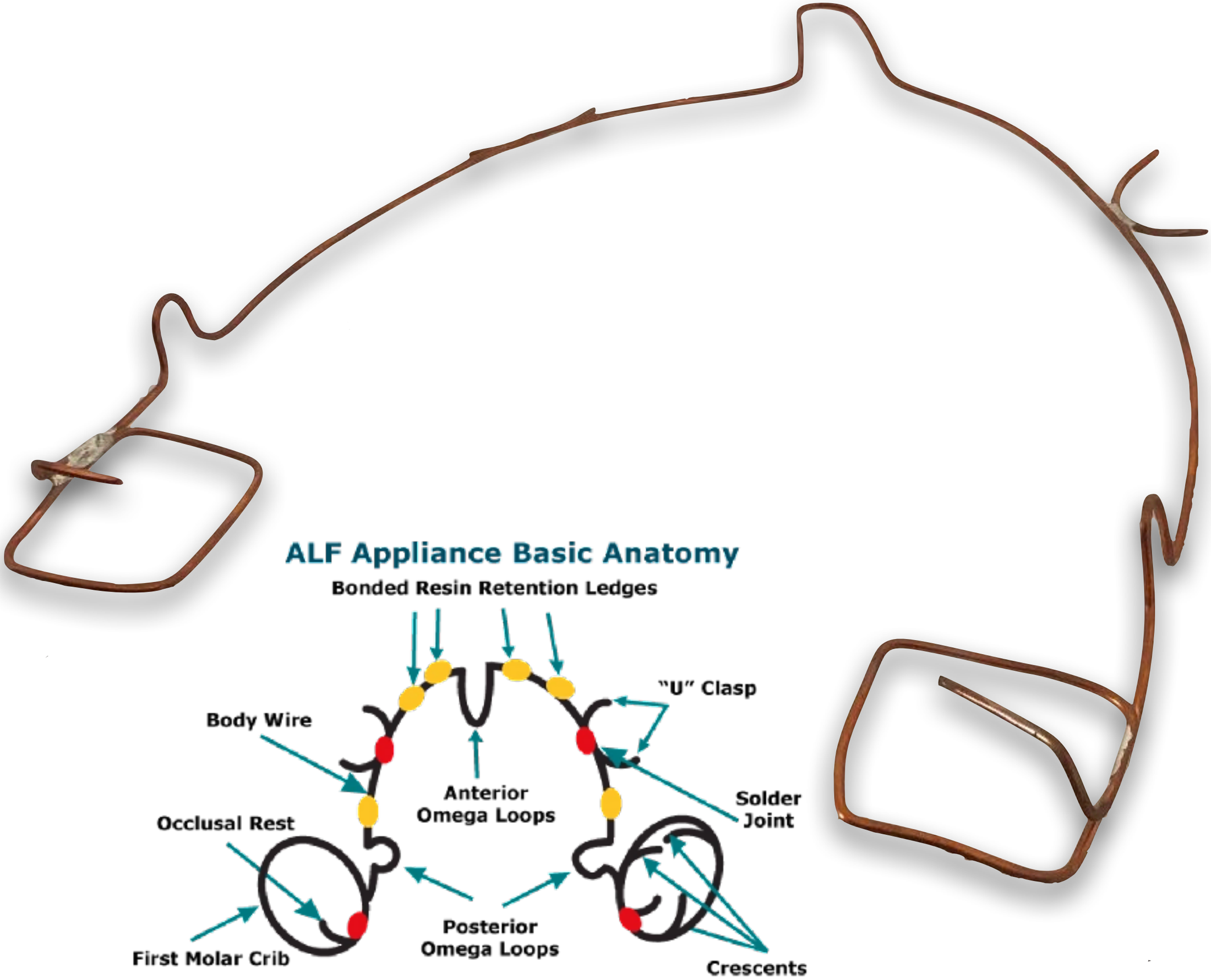
ALF Appliance Basic Anatomy
Bonded Resin Retention Ledges
"U" Clasp
Body Wire
Anterior
Omega Loops
Solder
Joint
Occlusal Rest
Posterior
Omega Loops
First Molar Crib
Crescents

Physiologic Strains

Flexion

- If someone is in (or prefers) extension, to bring them toward neutral or add flexion by expanding the ALF

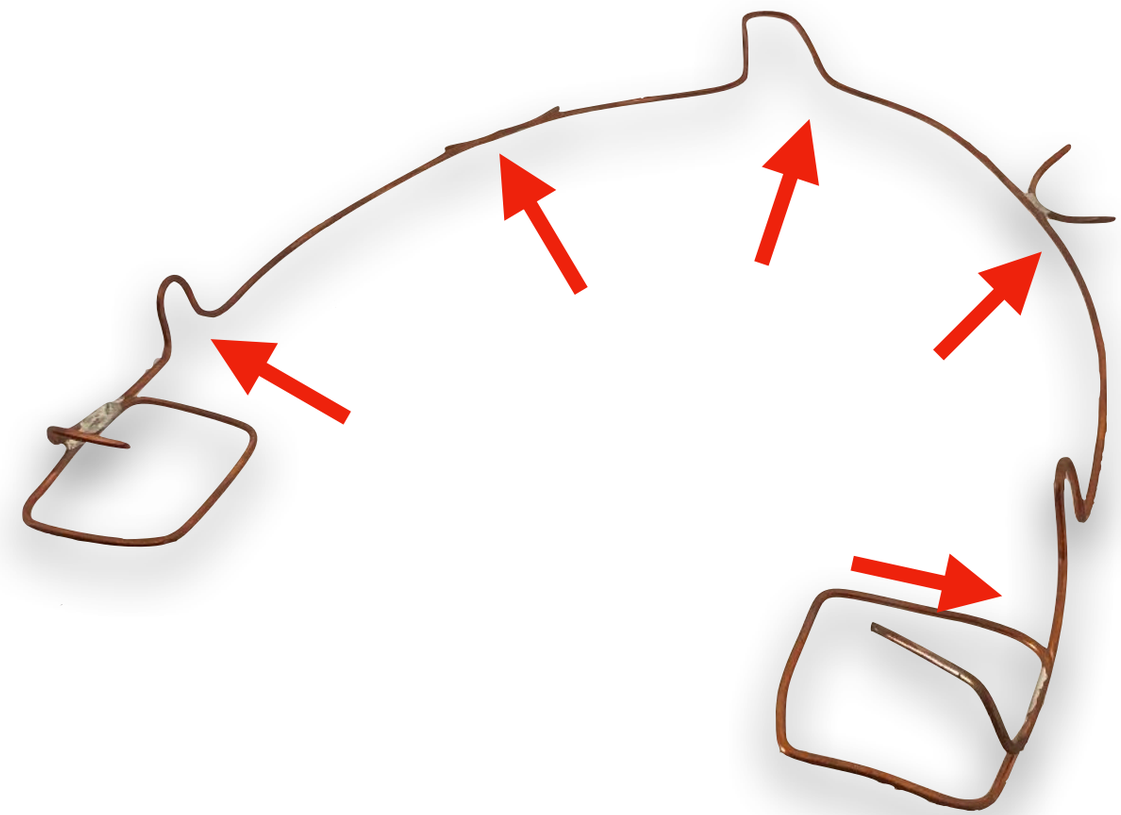

Extension

- If someone is in (or prefers) flexion, to bring them toward neutral or add extension by contracting the ALF

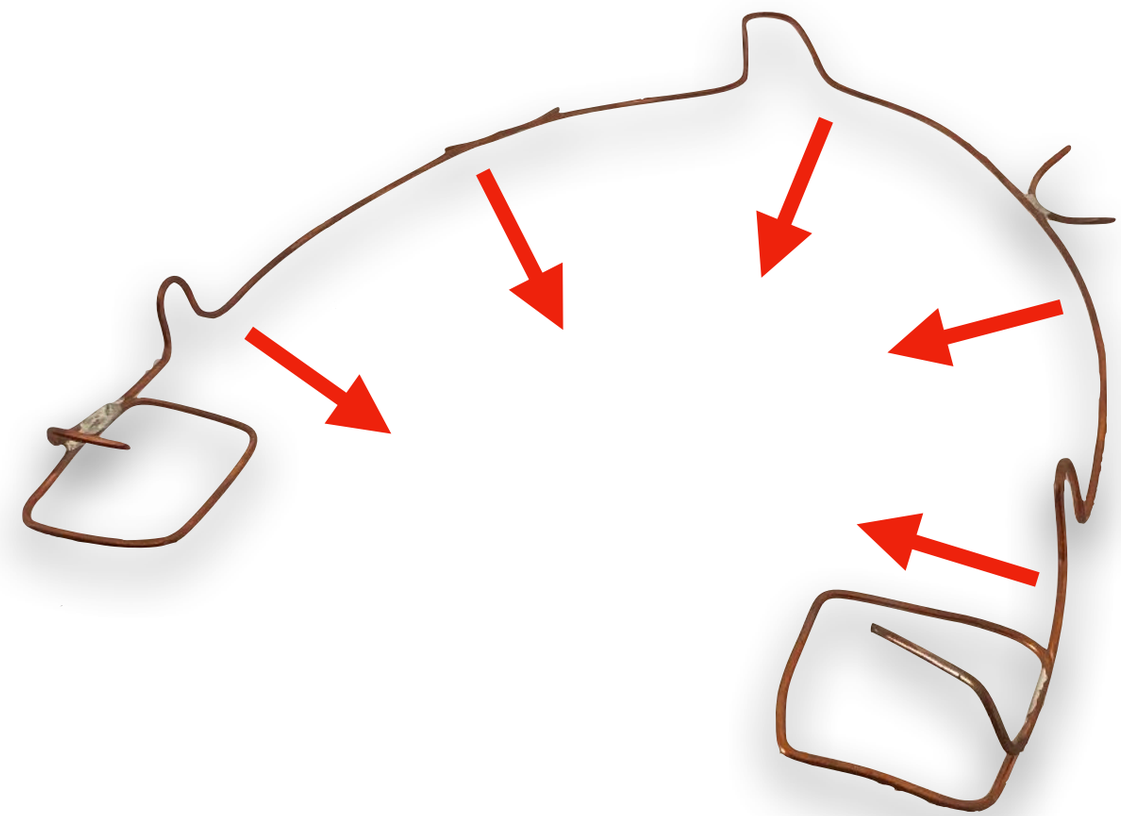

Torsion

- If someone is in (or prefers) a torsion, to bring them toward neutral, remove pressure from the U clasp on the affected side (named side of torsion). This allows the teeth causing the torsion to move down.



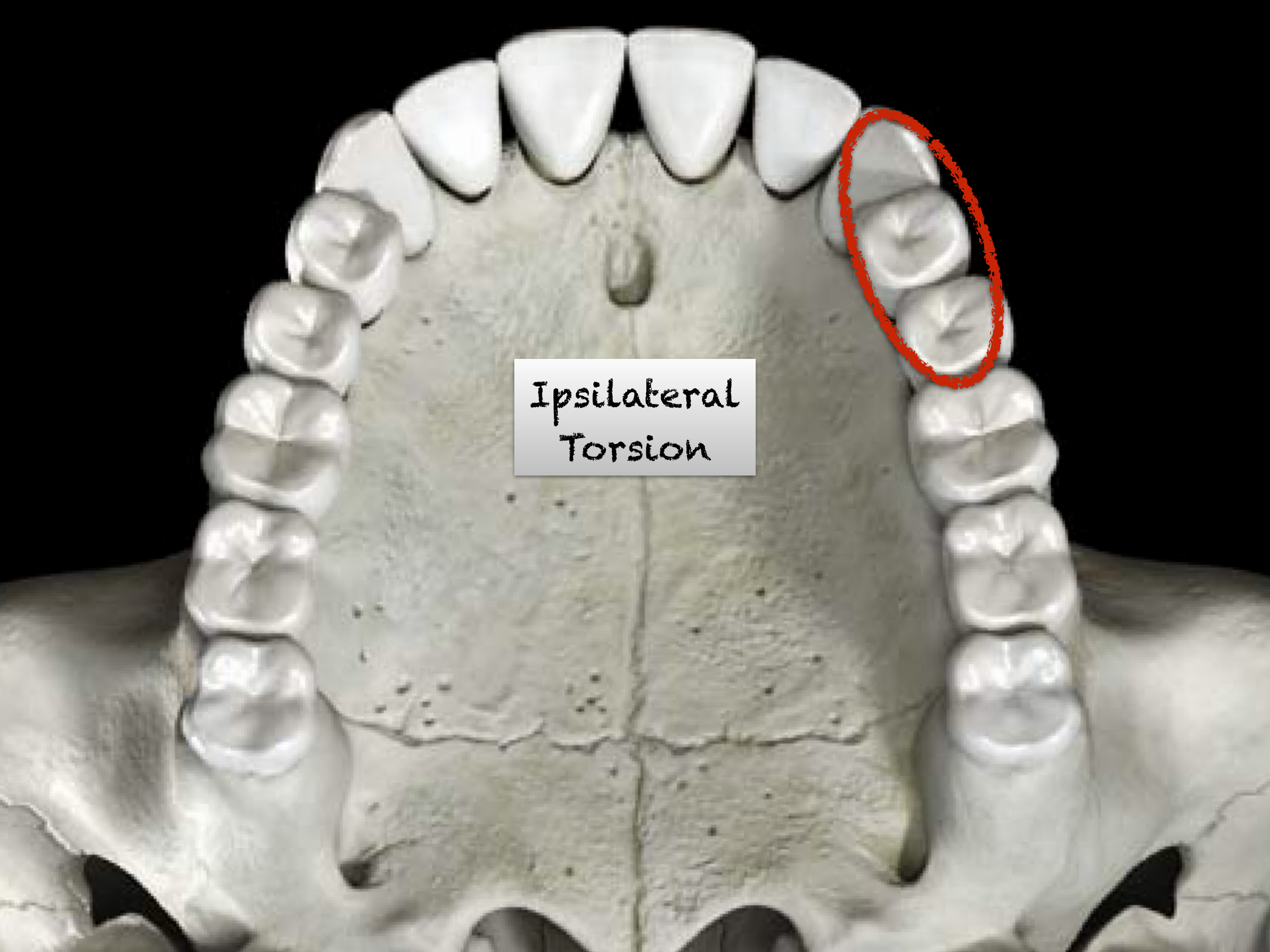
Ipsilateral
Torsion

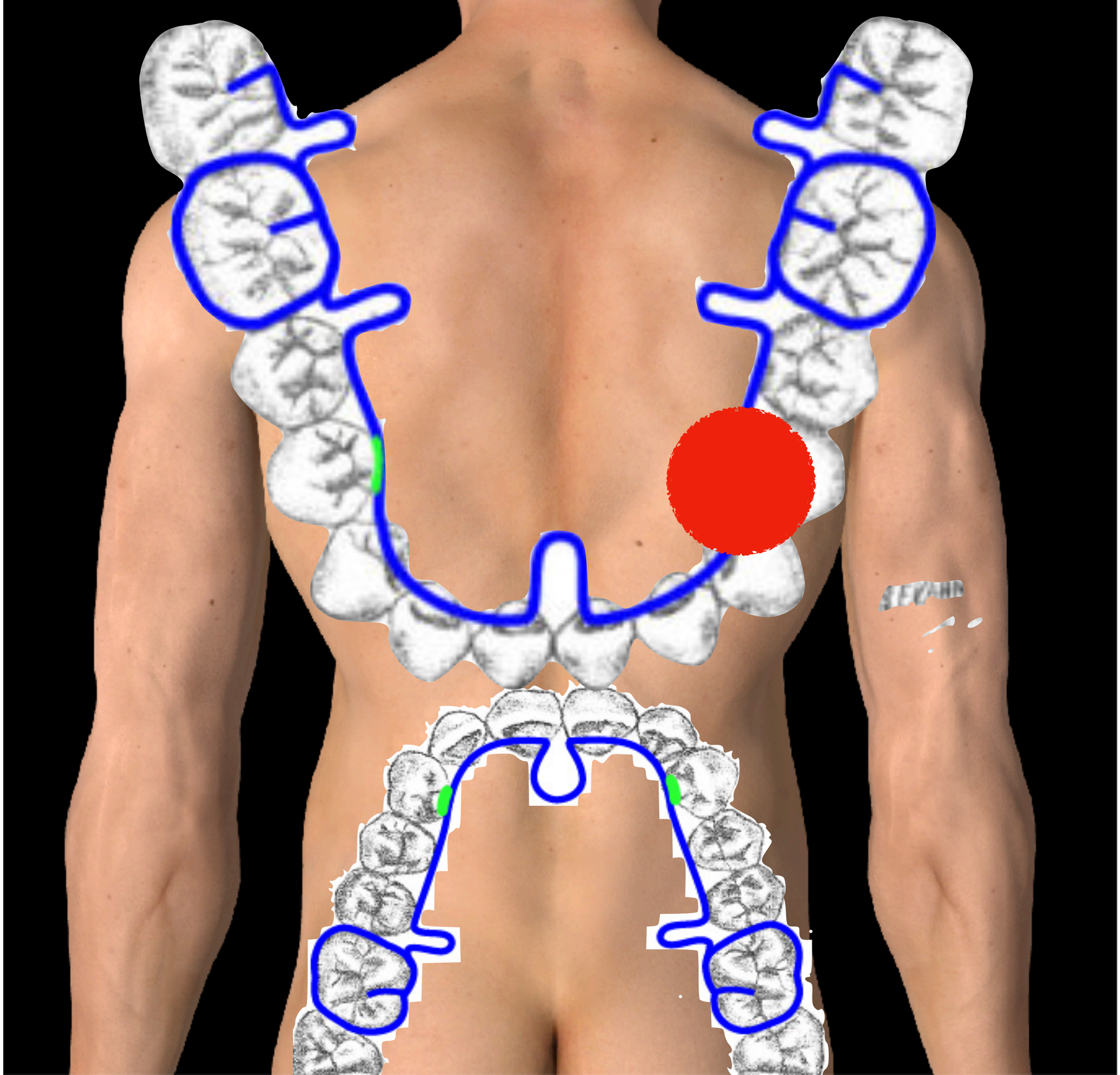

Sidebending / Rotation

- If someone is in (or prefers) a SB/R, to bring them toward neutral, first determine if they are predominantly sidebent, or predominantly rotated….

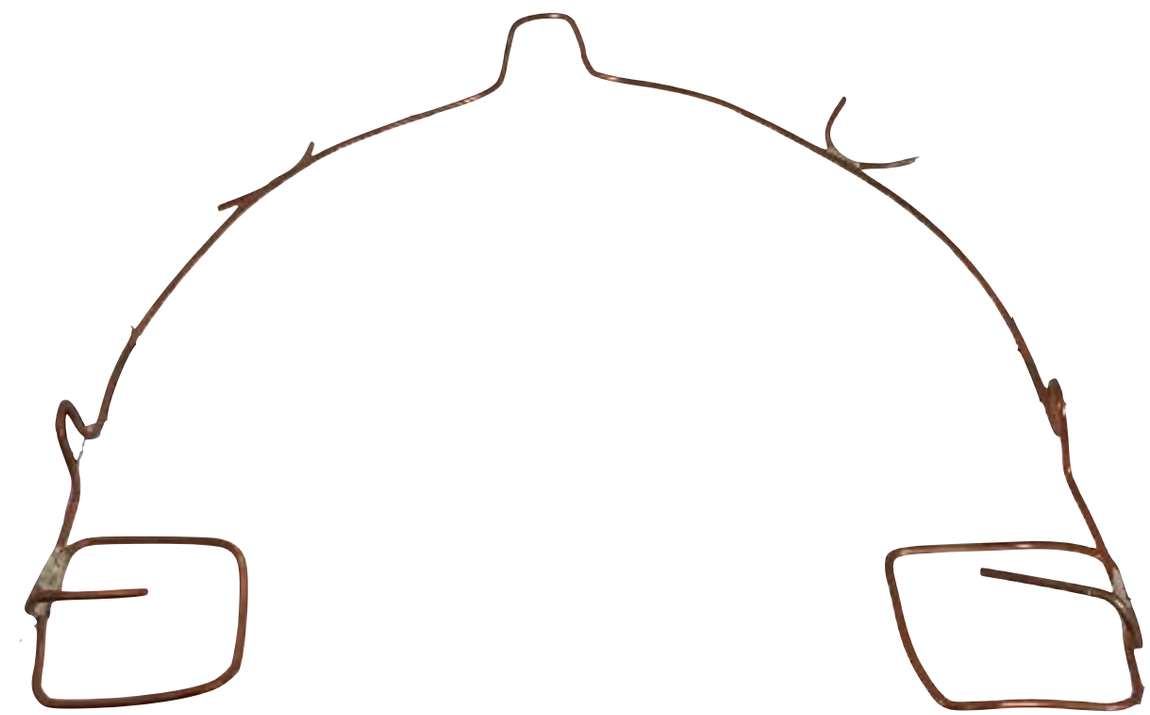

Ipsilateral
Side Bending/Rotation

Sidebending

- If they are predominantly sidebent, the appliance is torqued at the cribs. This example will cause a left sidebending, or correct a right sidebending

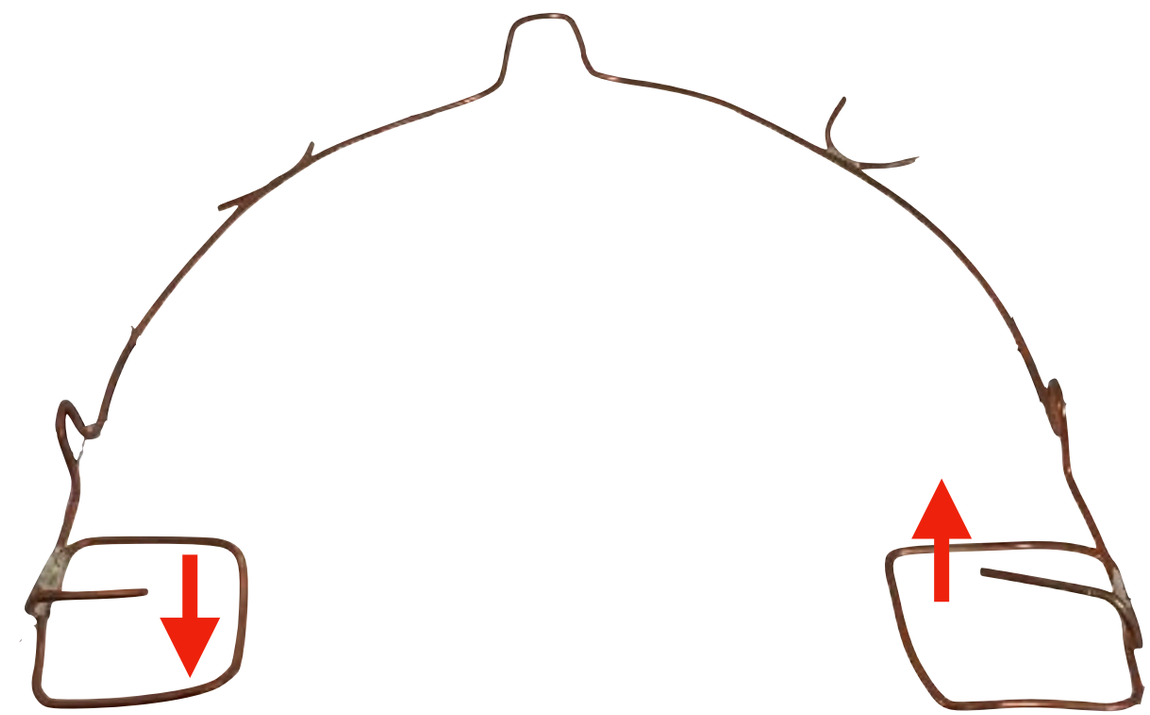

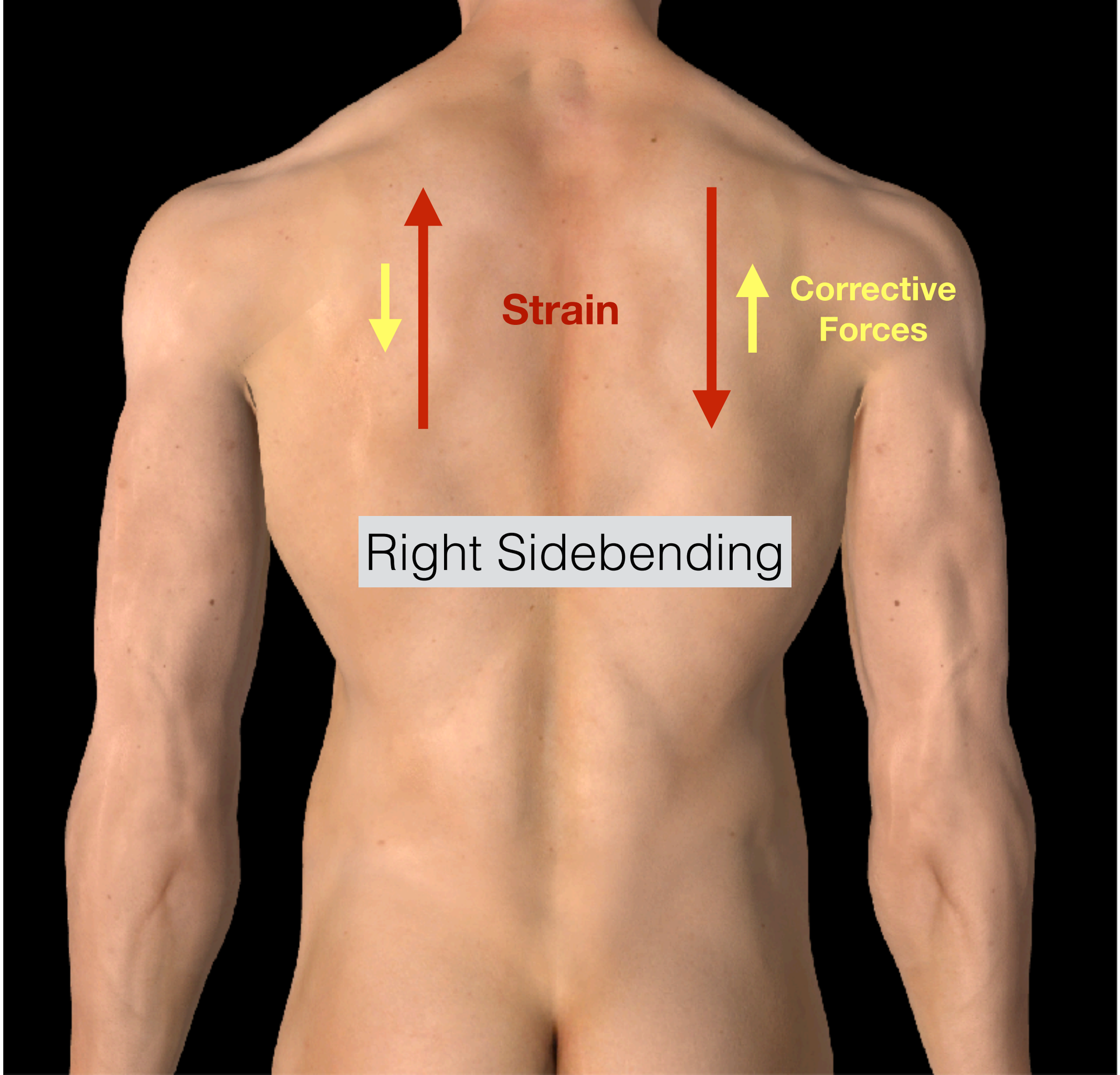
Strain
Corrective Forces
Right Sidebending

Rotation

- If the lesion is predominantly rotated, the posterior omega loops are not balanced left to right. This example would cause a left rotation, or correct a right rotation.

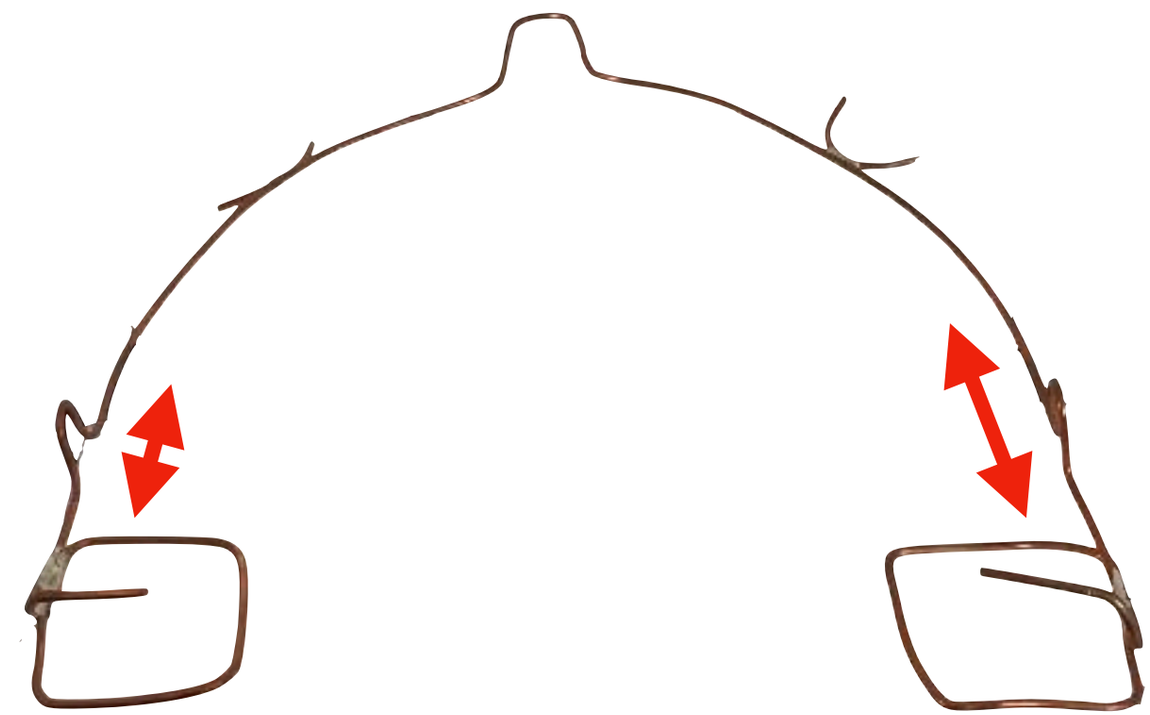

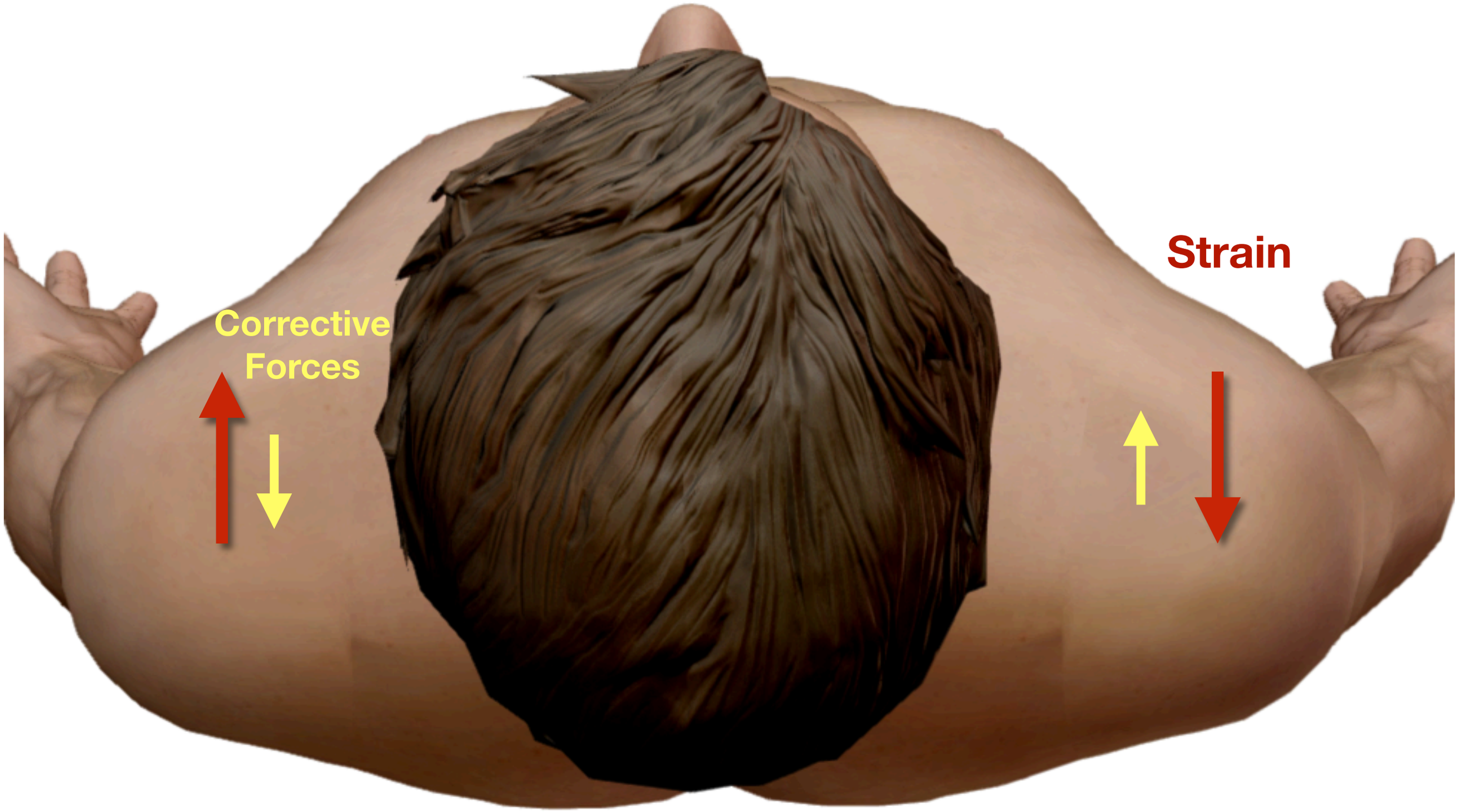
Corrective
Forces
Strain

Non-Physiologic Strains

Vertical Strain

- If someone is in (or prefers) a vertical strain, to bring them toward neutral, adjust the central omega loop toward or away from the palate. The upper ALF seems to affect the sphenoid portion of the strain.



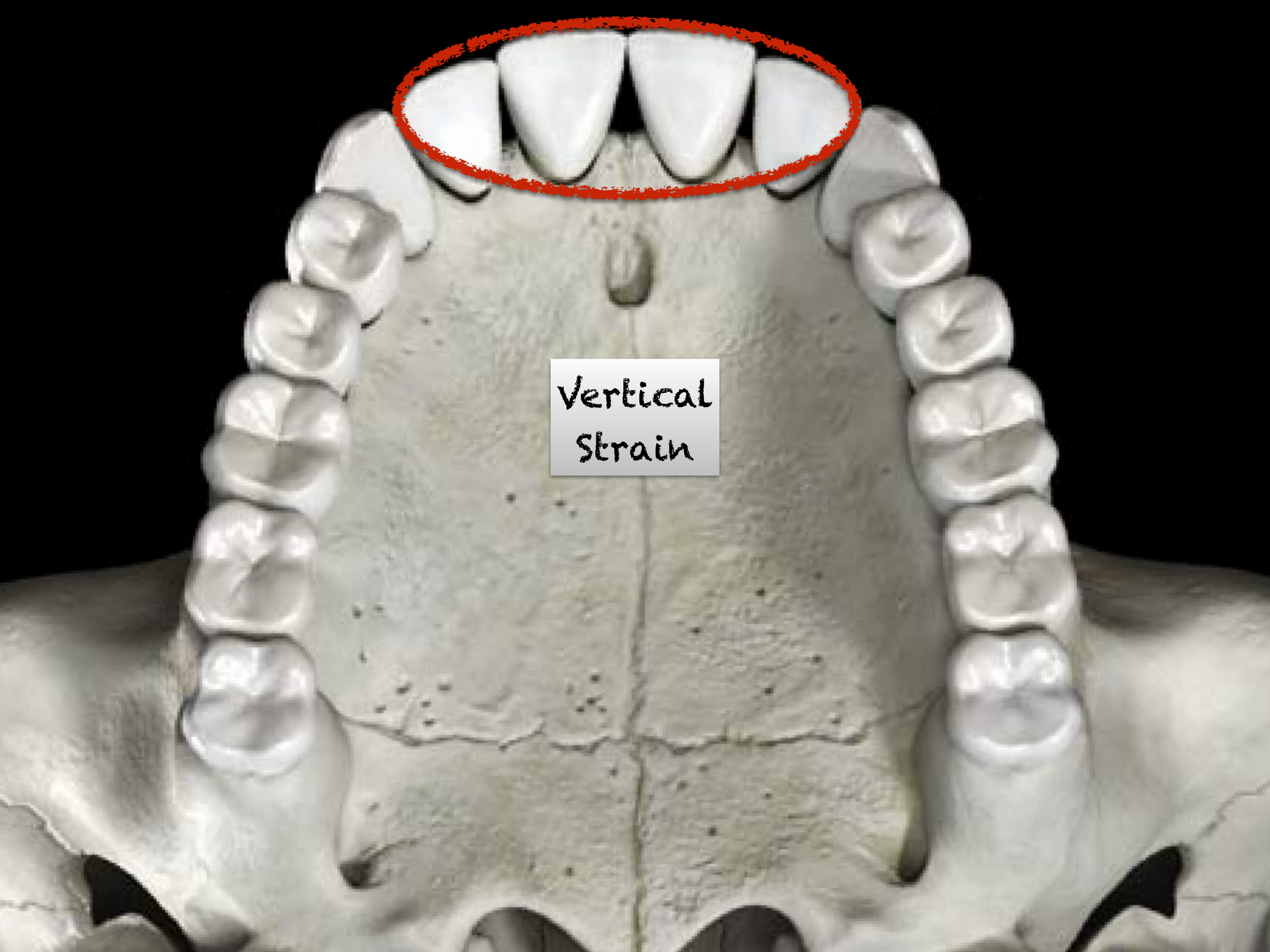
Vertical
Strain

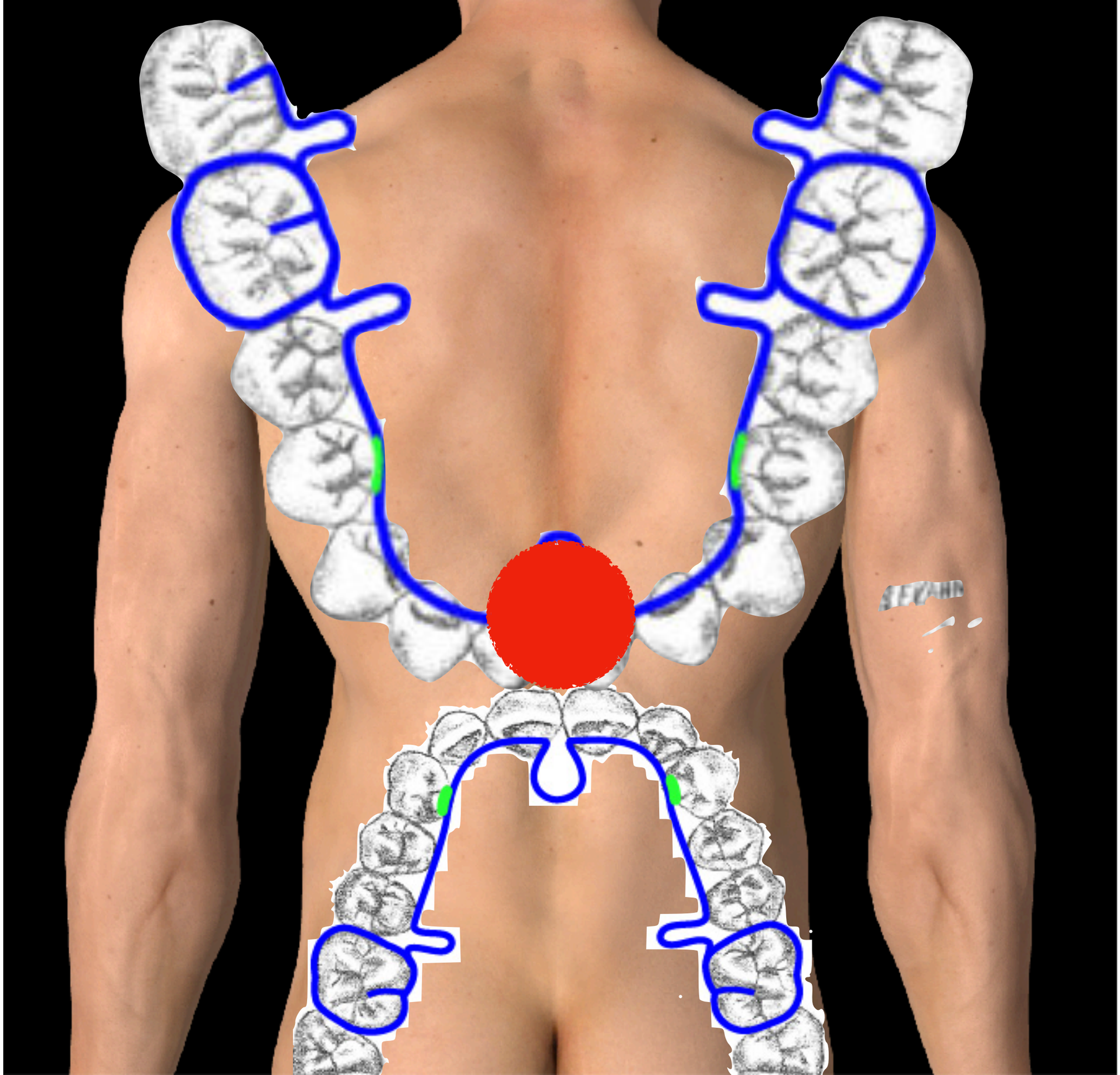

Vertical Strain

- If someone is in (or prefers) a vertical strain, to bring them toward neutral, adjust the central omega loop toward or away from the palpate. The lower ALF seems to affect the occipital portion of the strain.



Vertical
Strain

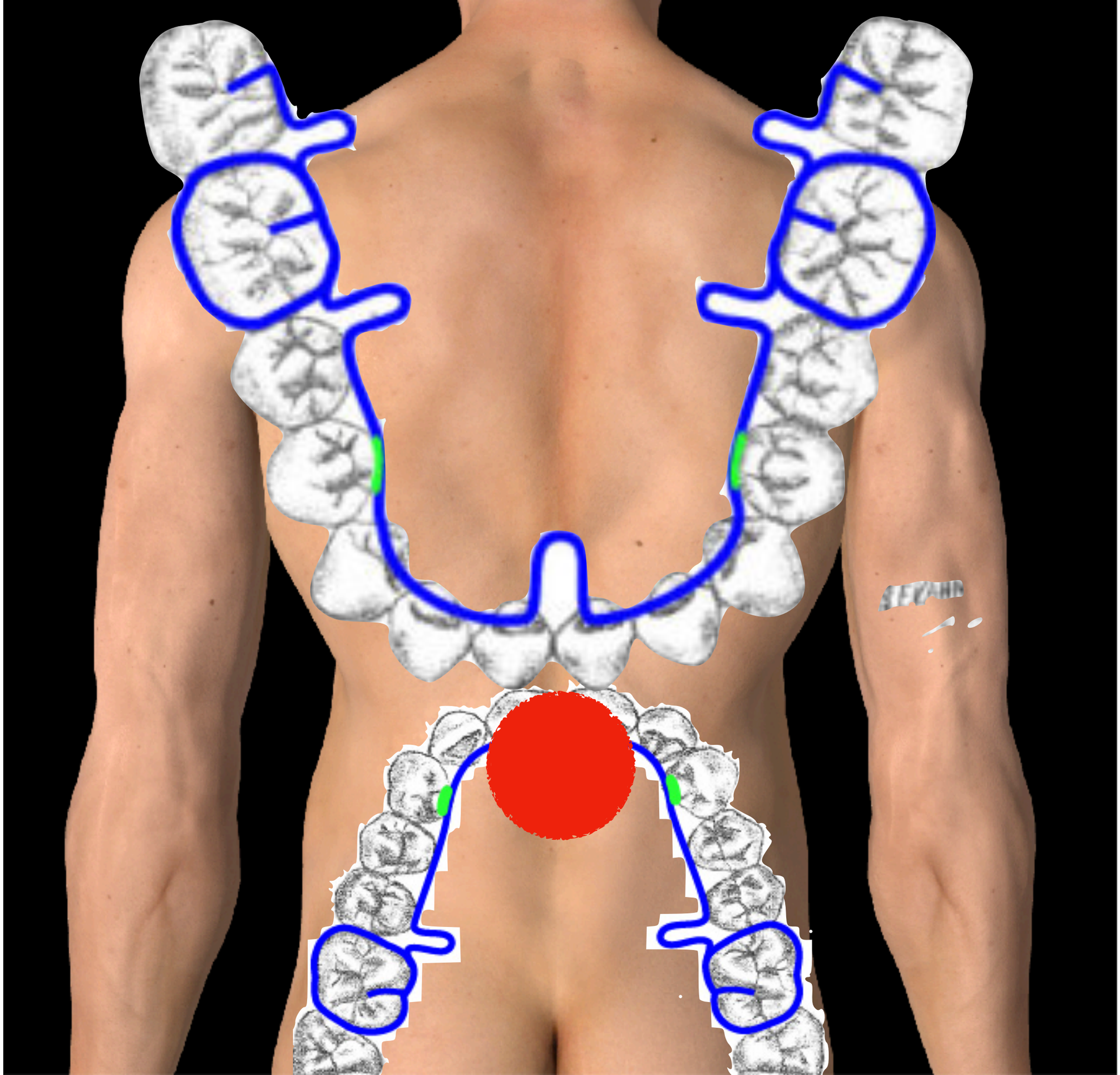

Lateral Strain

- If someone is in (or prefers) a lateral strain, to bring them toward neutral, adjust the crib on the opposite side of the named strain (left crib for a right lateral strain)

Contralateral
Lateral
Strain

Lateral Strain (version 2)

- If someone is in (or prefers) a lateral strain, to bring them toward neutral, adjust the lower lateral omega loops (expanding the left lateral omega loop will move the right occiput posterior)

- NOTE: this also rotates the patients mandible.

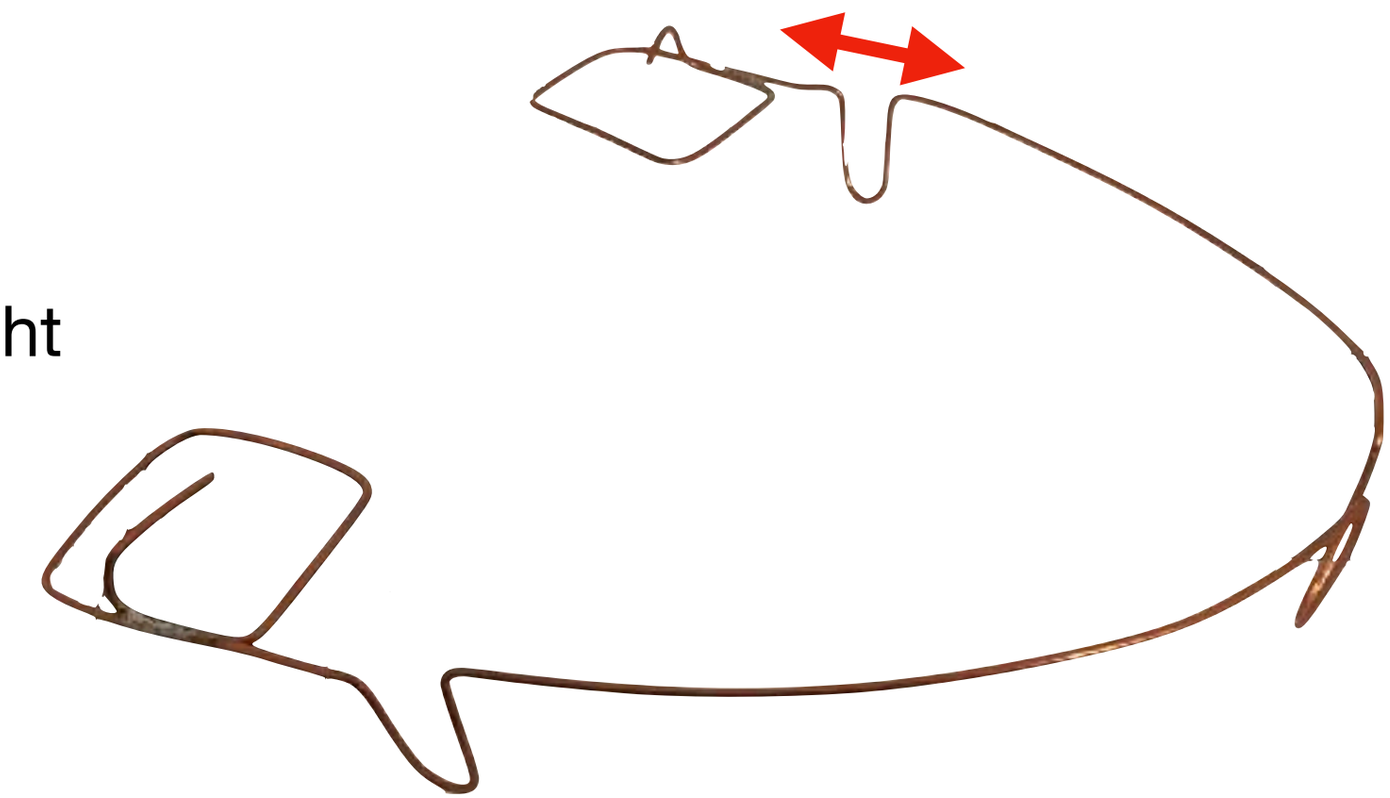

Other Strains

Midline Shift

- By yoking the cribs together and moving them bilaterally in the same direction, you can shift the patient's midline. The upper ALF shifts the midline above T12, the lower ALF shifts the lower half of the body.

- This example would shift the patients upper midline to the left.

- It can be shifted left/right. anterior/posterior.

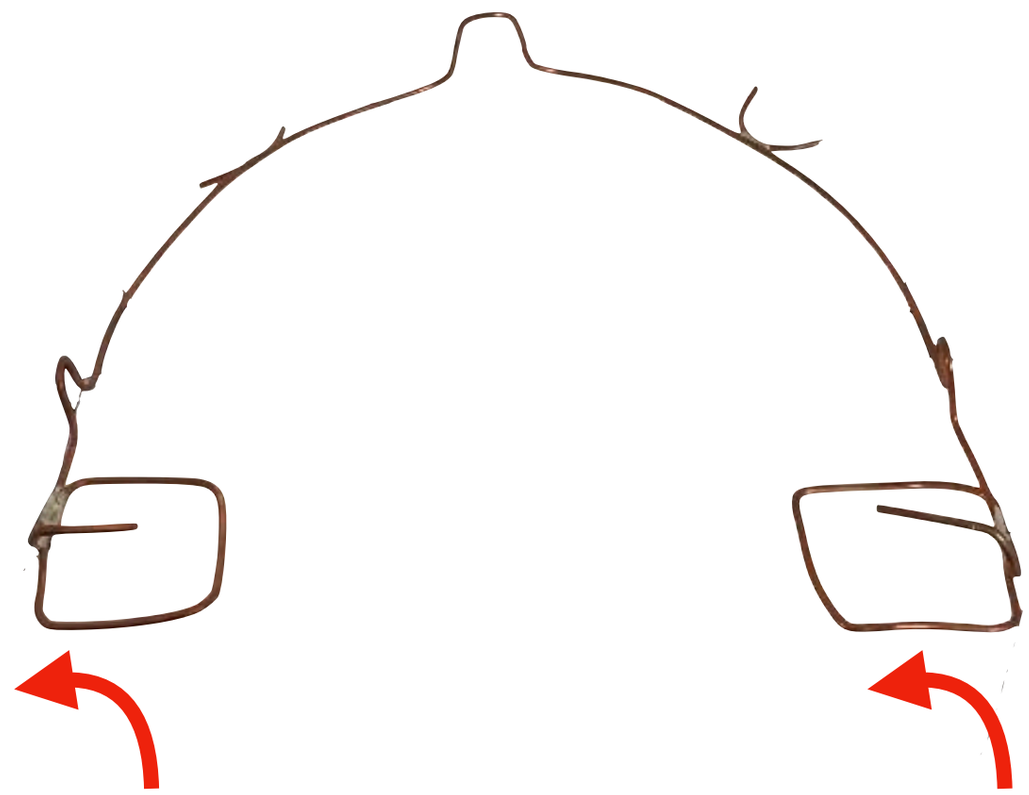

Midline Rotation

- By yoking the cribs together and rotating them bilaterally in the same direction, you can rotate the patient's midline. The upper ALF shifts the midline above T12, the lower ALF shifts the lower half of the body.
- This example would rotate the patients upper midline to the left.
- It can be rotated left/right.
- NOTE: This should only be attempted by advanced practitioners.

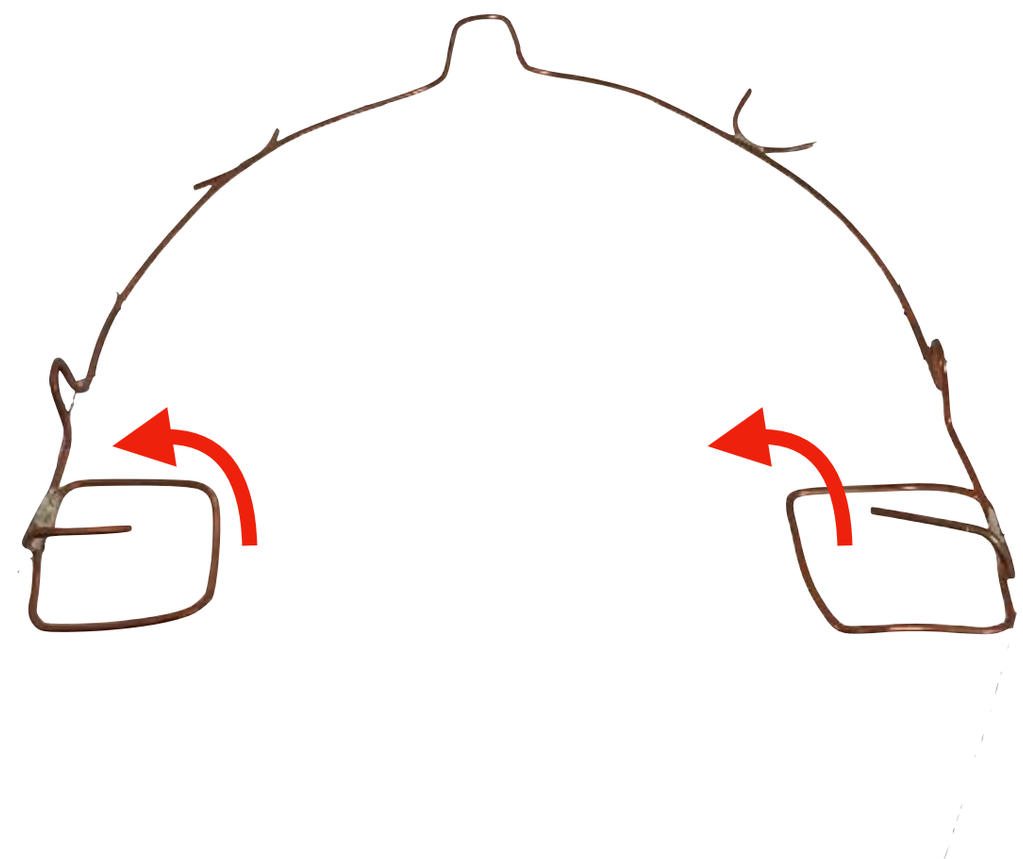

Midline Rotation

- What happens if an uninformed/underinformed practitioner puts the following forces into the teeth (with any appliance)?
- The midline of the maxilla will shift to the left (hopefully).
- But what else?

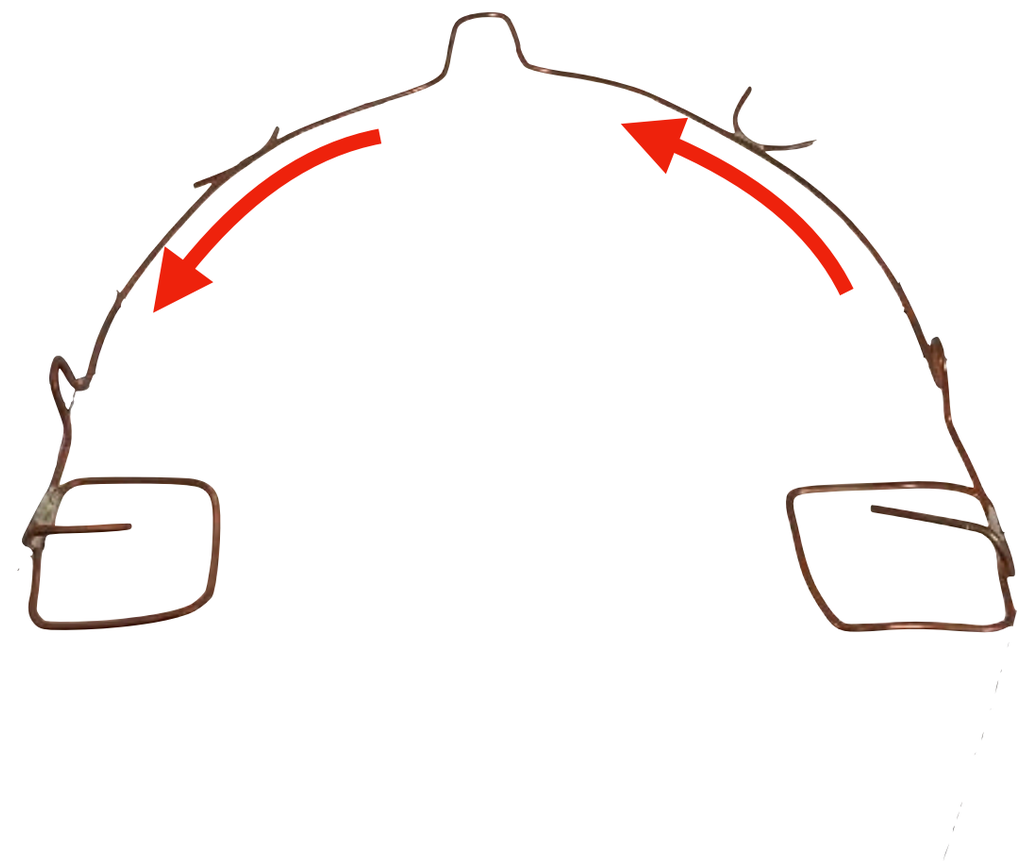

Midline Rotation

- The ligaments on the right side get tractioned and the ones on the left get compressed.

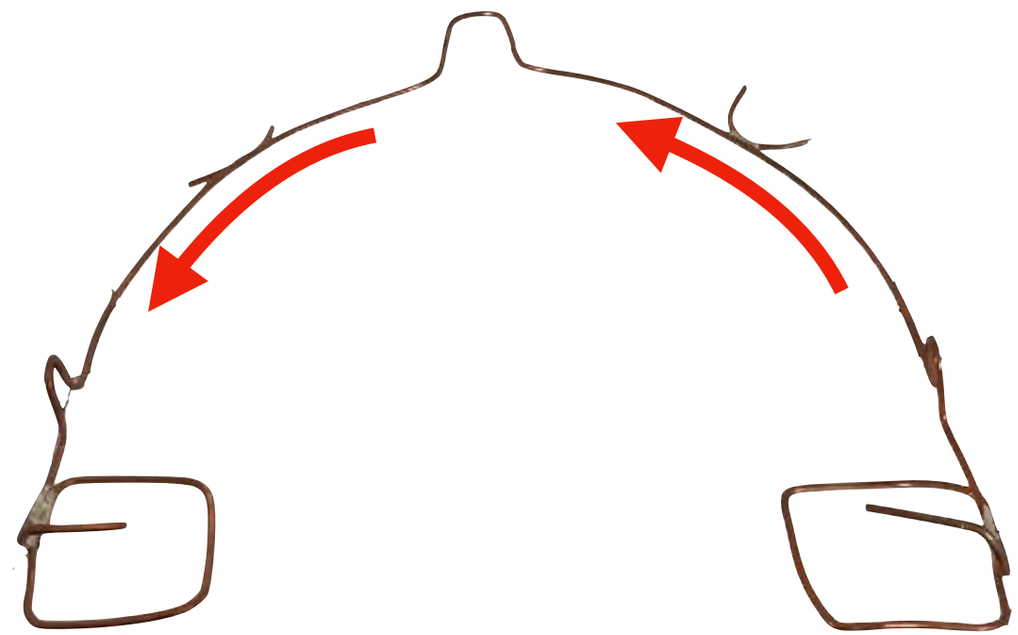

Midline Rotation

- It predisposes your patient to the formation of scoliosis…

- But that also means that the appropriate use of dental forces can help to correct the forces behind scoliosis.

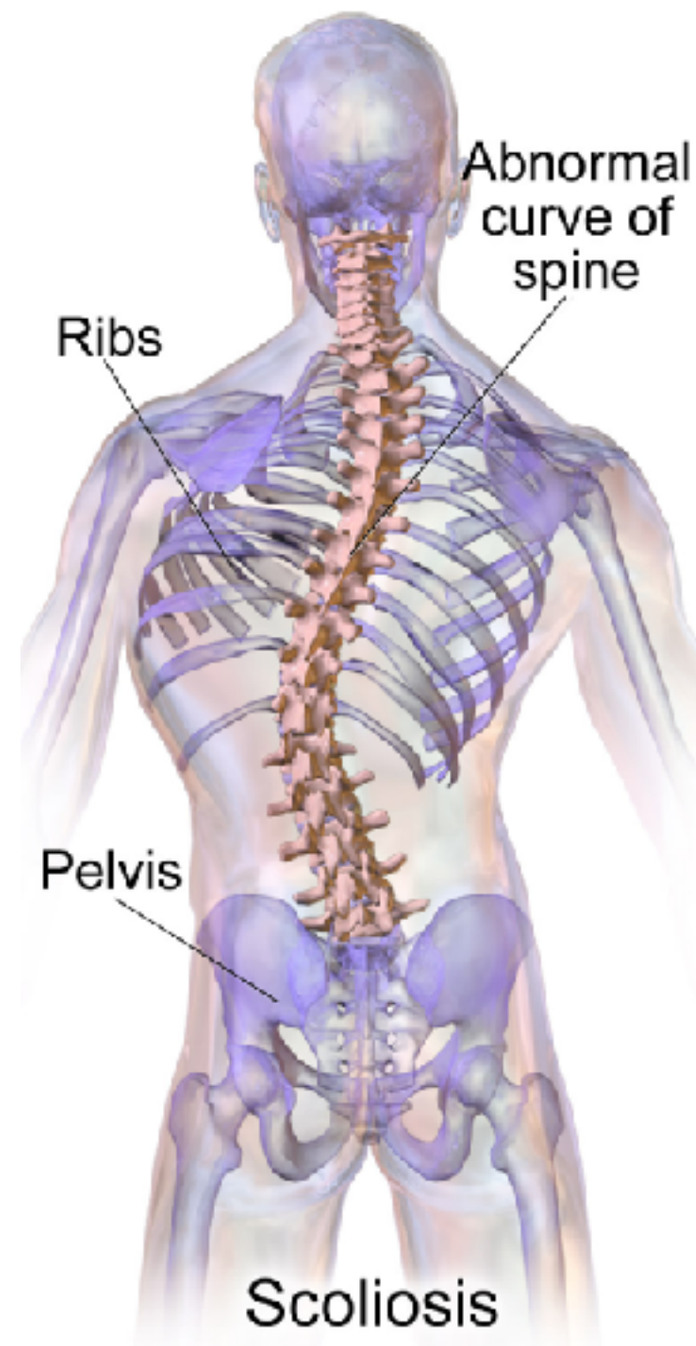

After Making an ALF Adjustment

- *Instantly, every bone of the head changes shape - and the articulations change - and the membranes change - and the fluid changes…*

After Making an ALF Adjustment

- It is important to remember, that, due to tensegrity, the WHOLE body has changed once the adjustment is made.

- The fluid, the fascia, the bones, the joints, the muscles, the blood vessels…

- And the patient needs to be made aware of this and reminded to be patient (to allow the body to integrate the change) and to inform you if there are any abnormal sensations or symptoms.

After Making an ALF Adjustment

- It is important to GO SLOW! You can always do more later.

- Don’t over do it. Once the body gets some freedom, it usually wants MORE! Balance the dentistry with the freedom of movement to obtain balance.

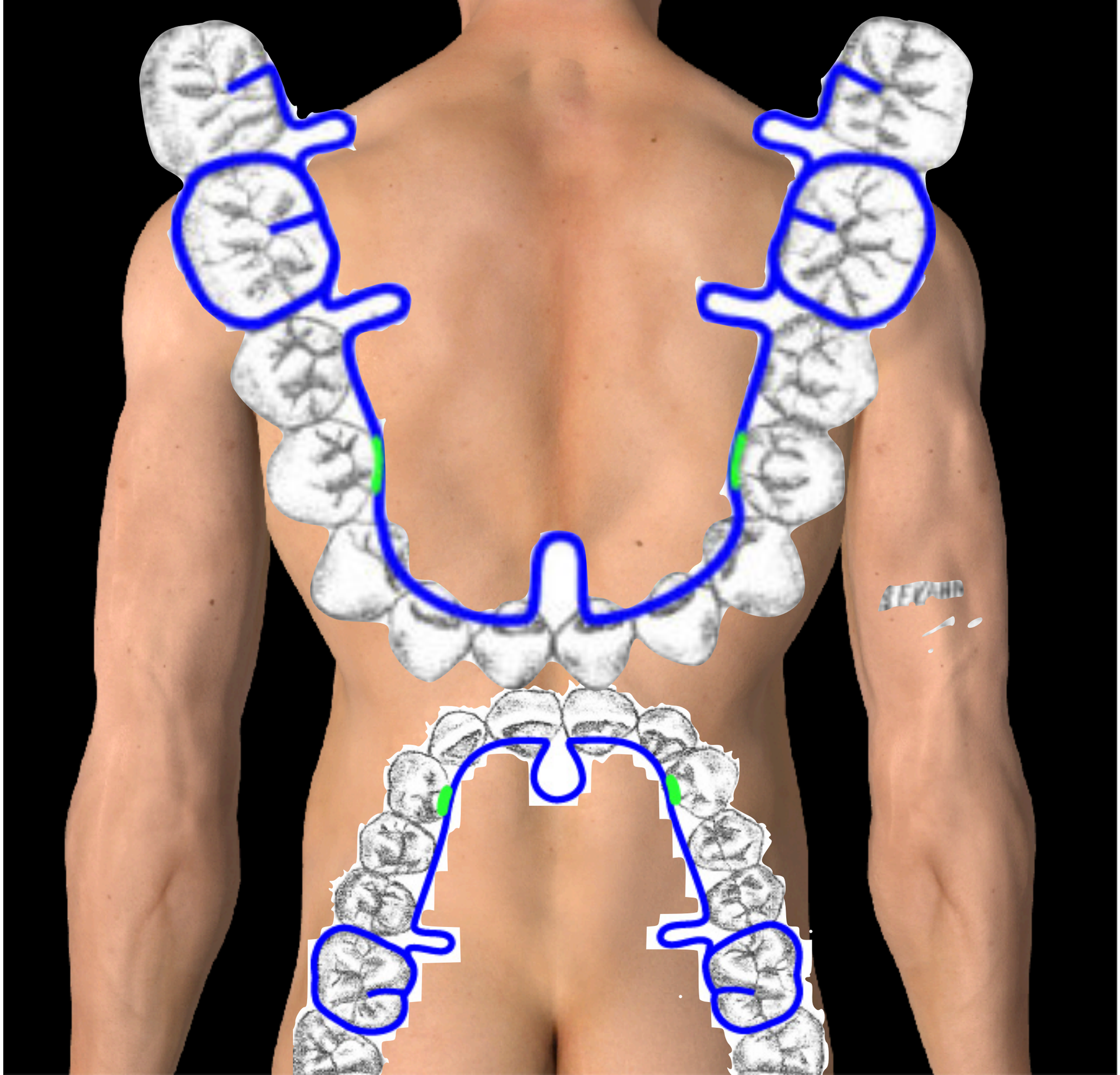

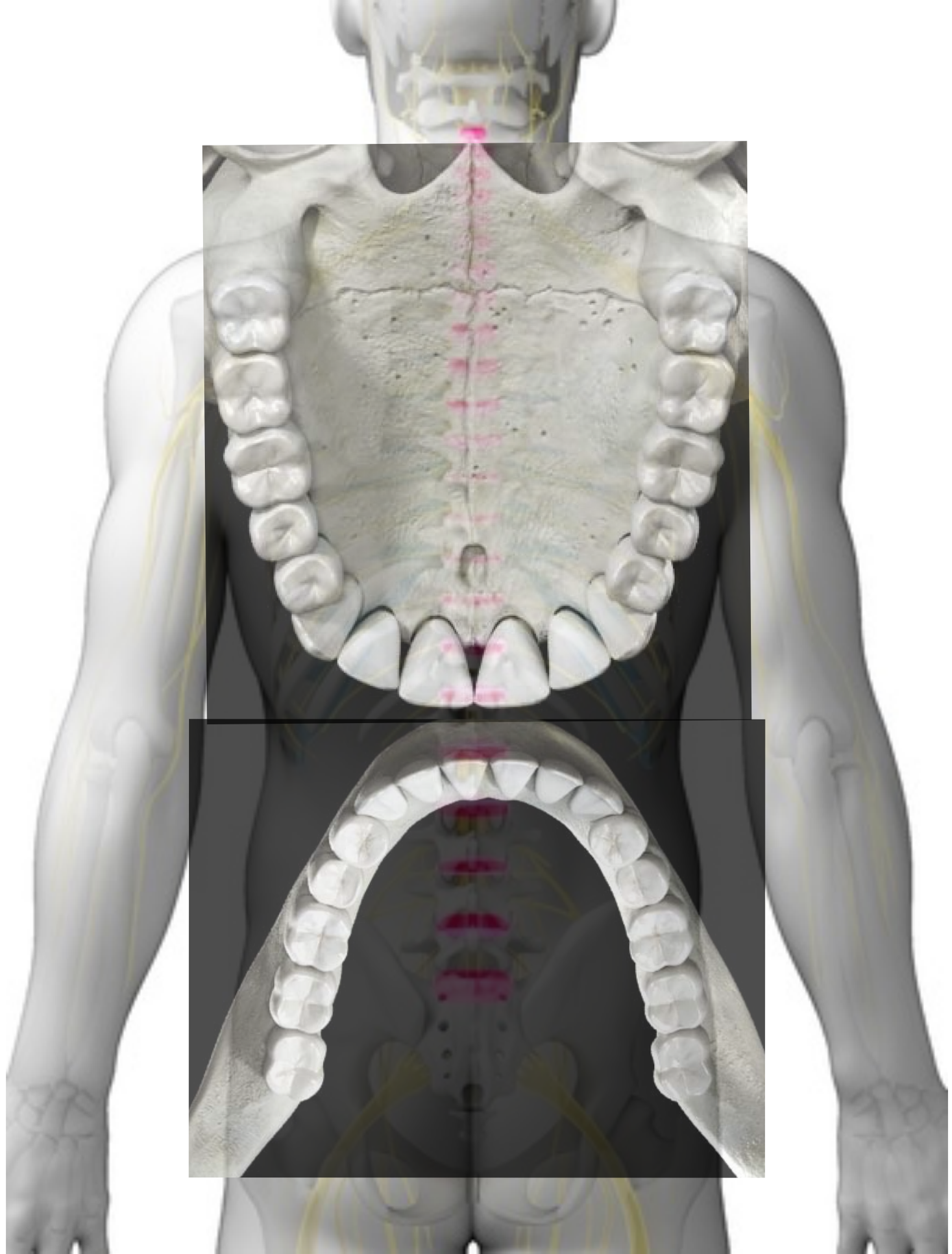

How to Tell if You Have Went Too Far with an ALF Adjustment

Appliance Adjustments

- We are looking for balance in the body…not doing too little or too much.
- The principles described here apply to the upper as well as the lower body. Not all possibilities are listed here. Use this as a guide to examine your patient.

Band of Tension that goes horizontally at approximately the T9 level

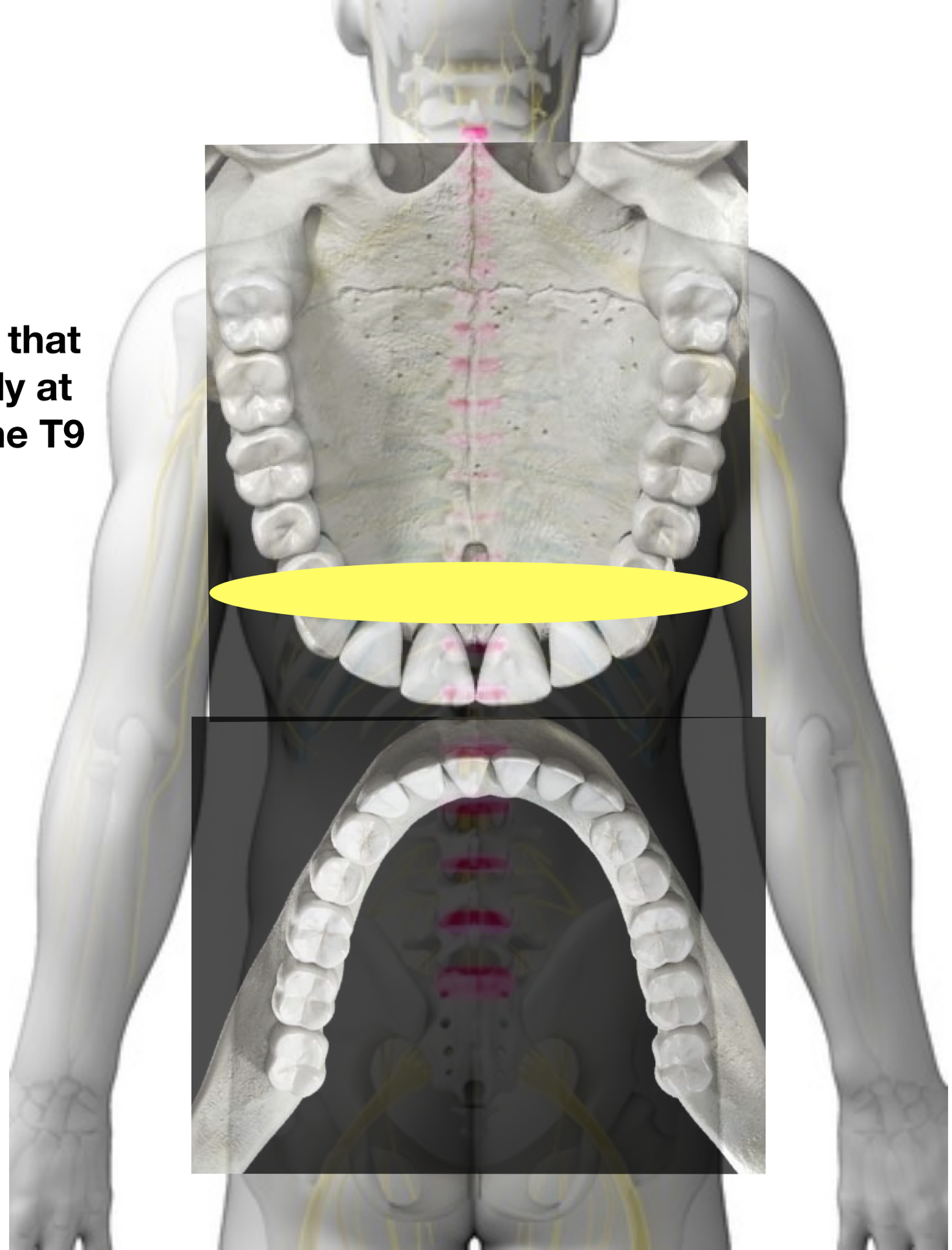

ALF Appliance Basic Anatomy

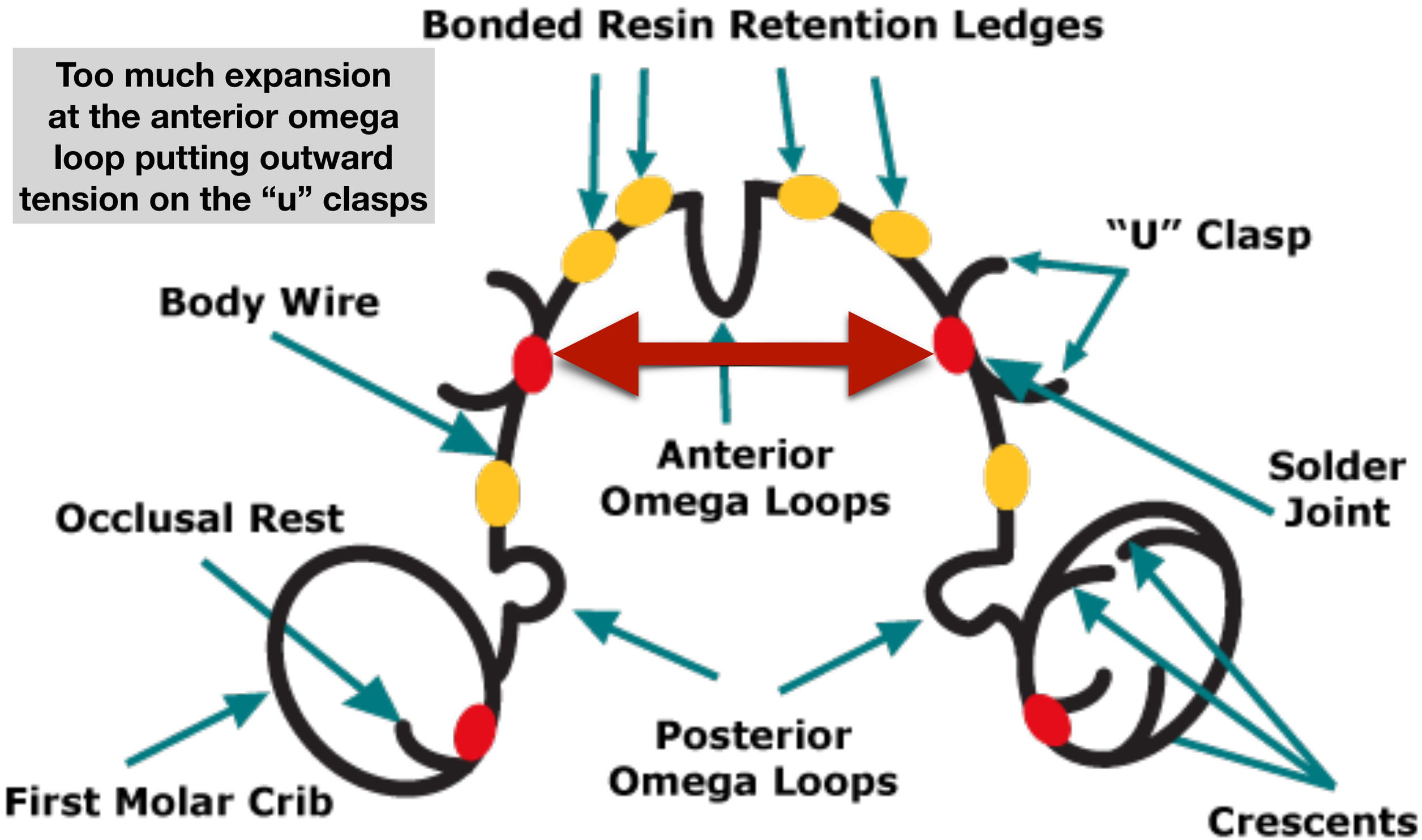

Tension in the back that is worse at the top, gets slightly better as you go down, and is gone by about T9.

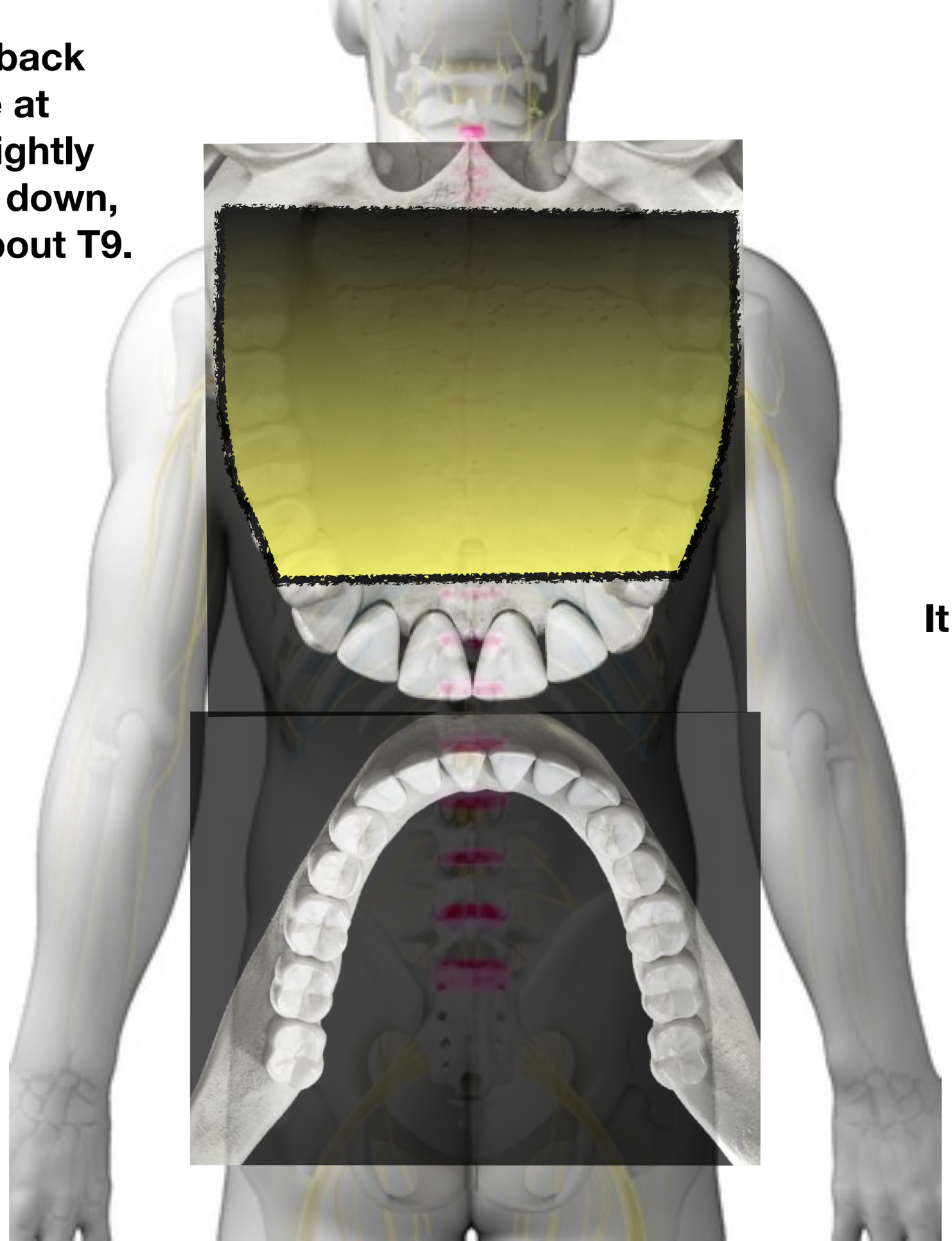

It can be worse on one side.

ALF Appliance Basic Anatomy

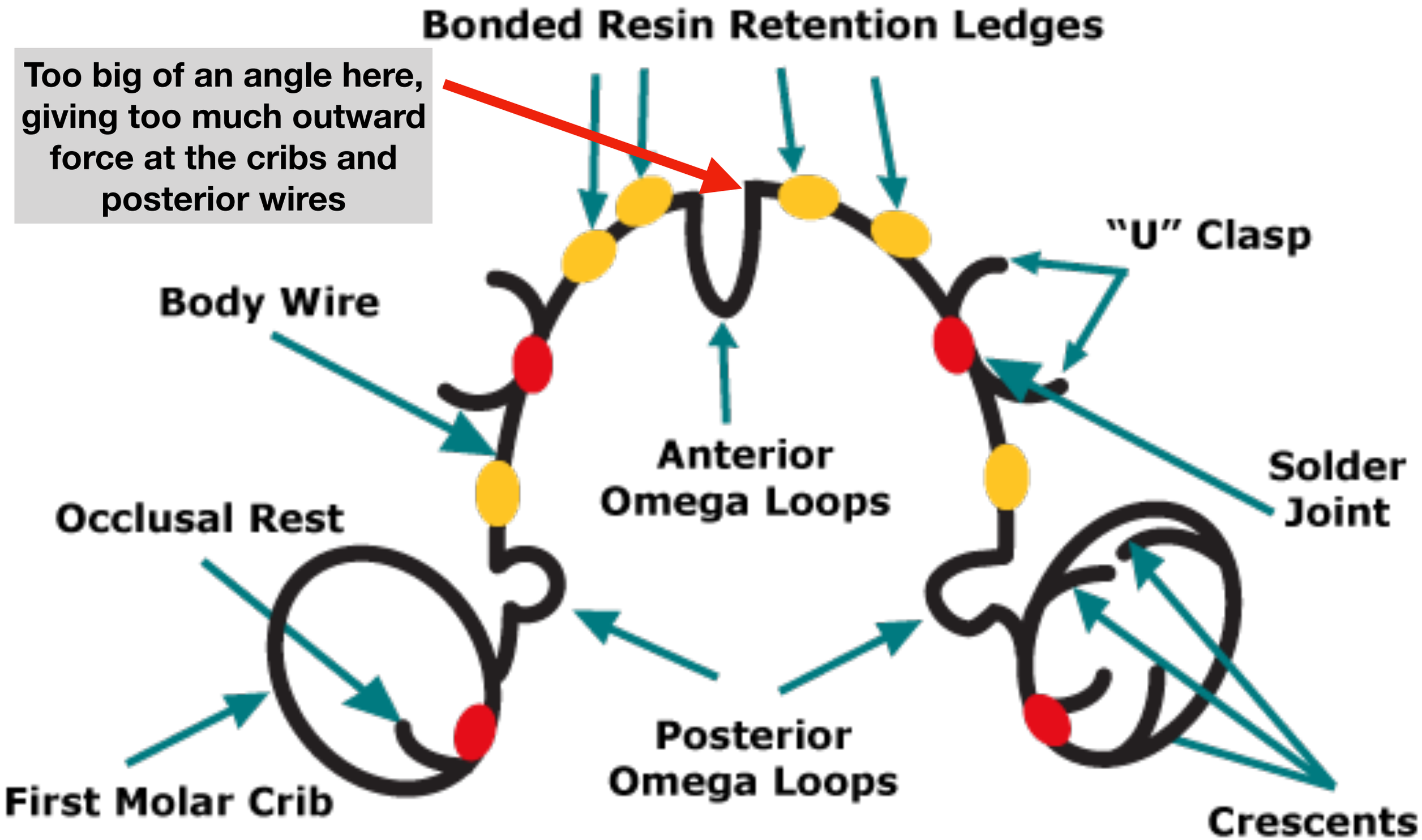

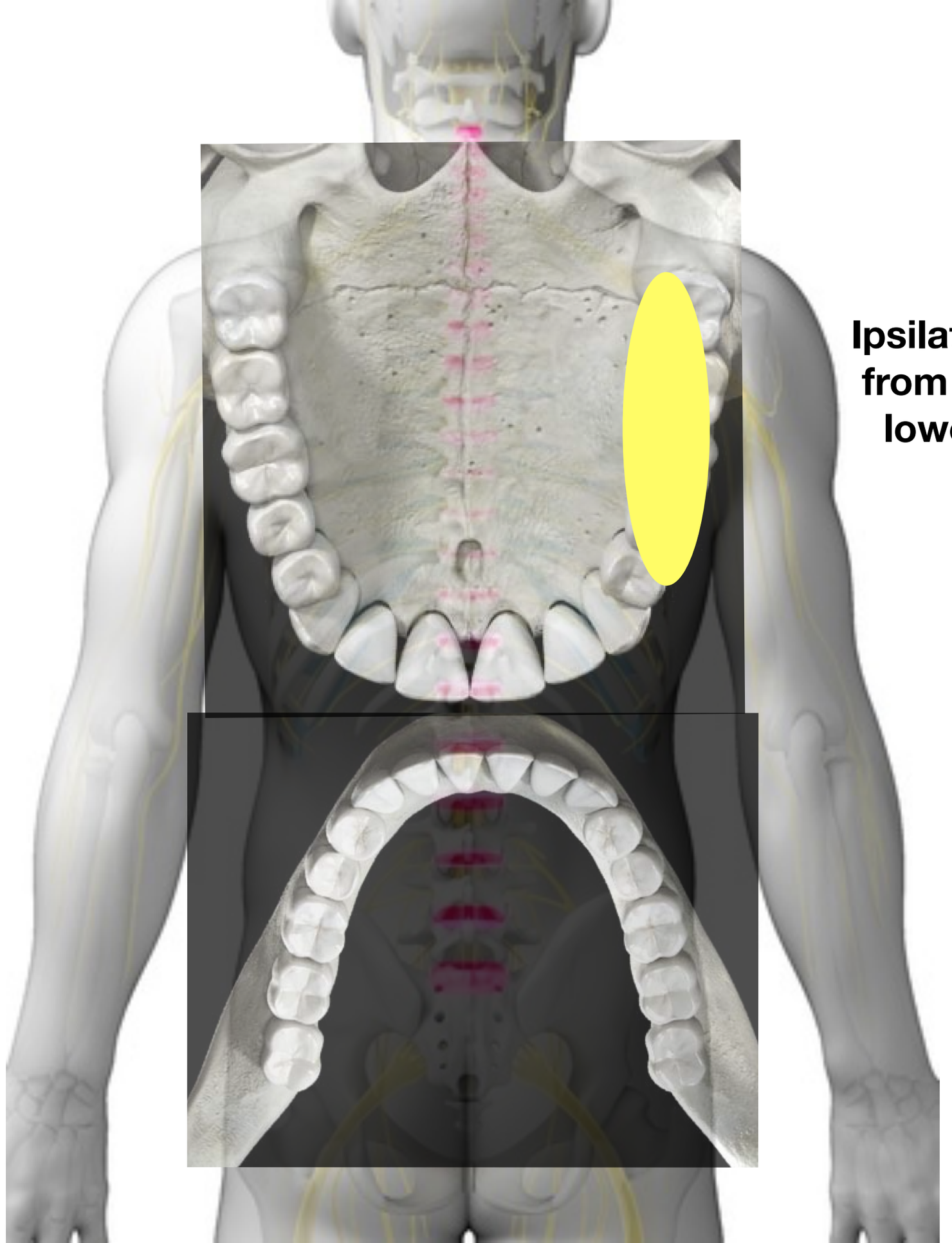

Ipsilateral tension from shoulder to lower rib cage

ALF Appliance Basic Anatomy

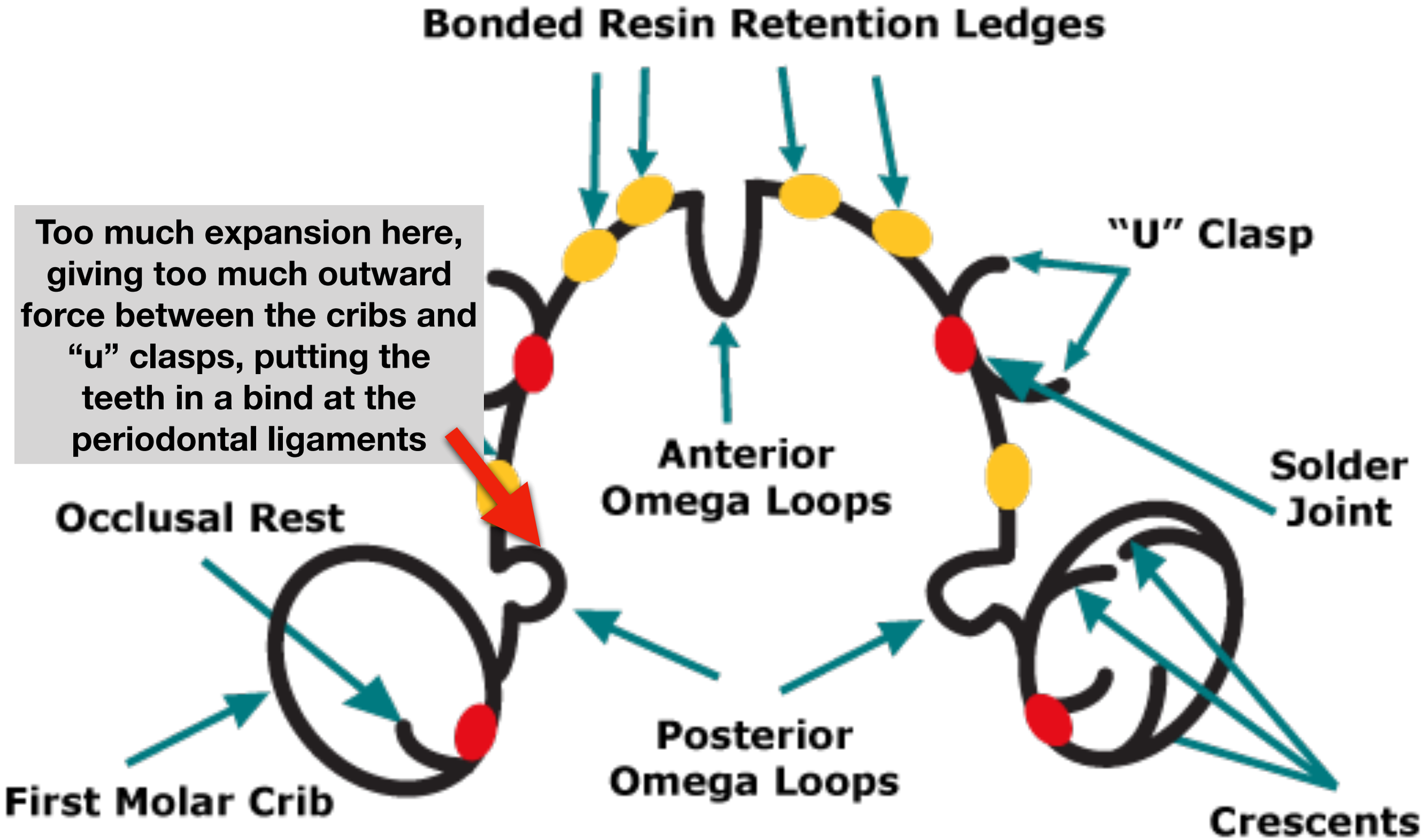

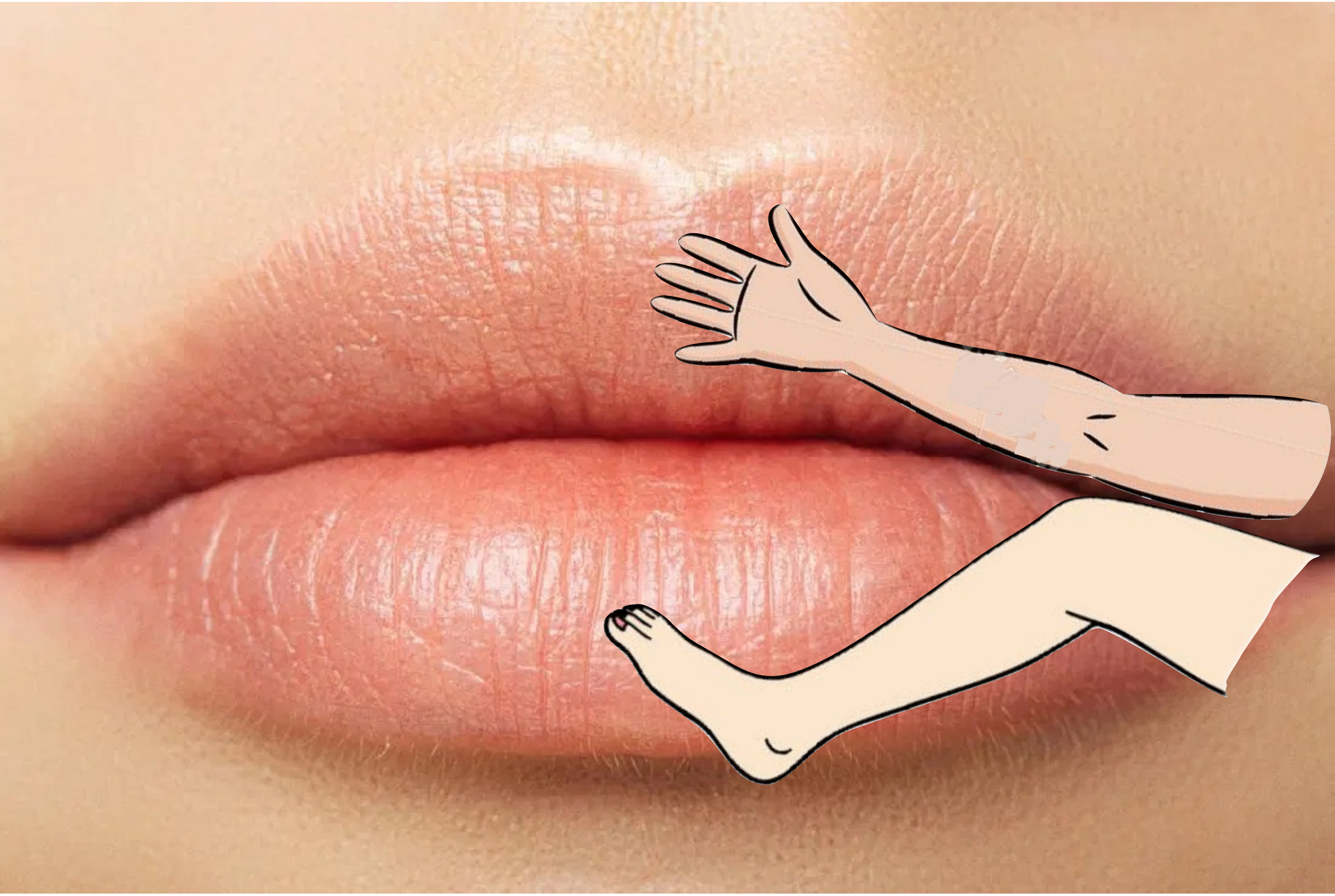

The Tongue

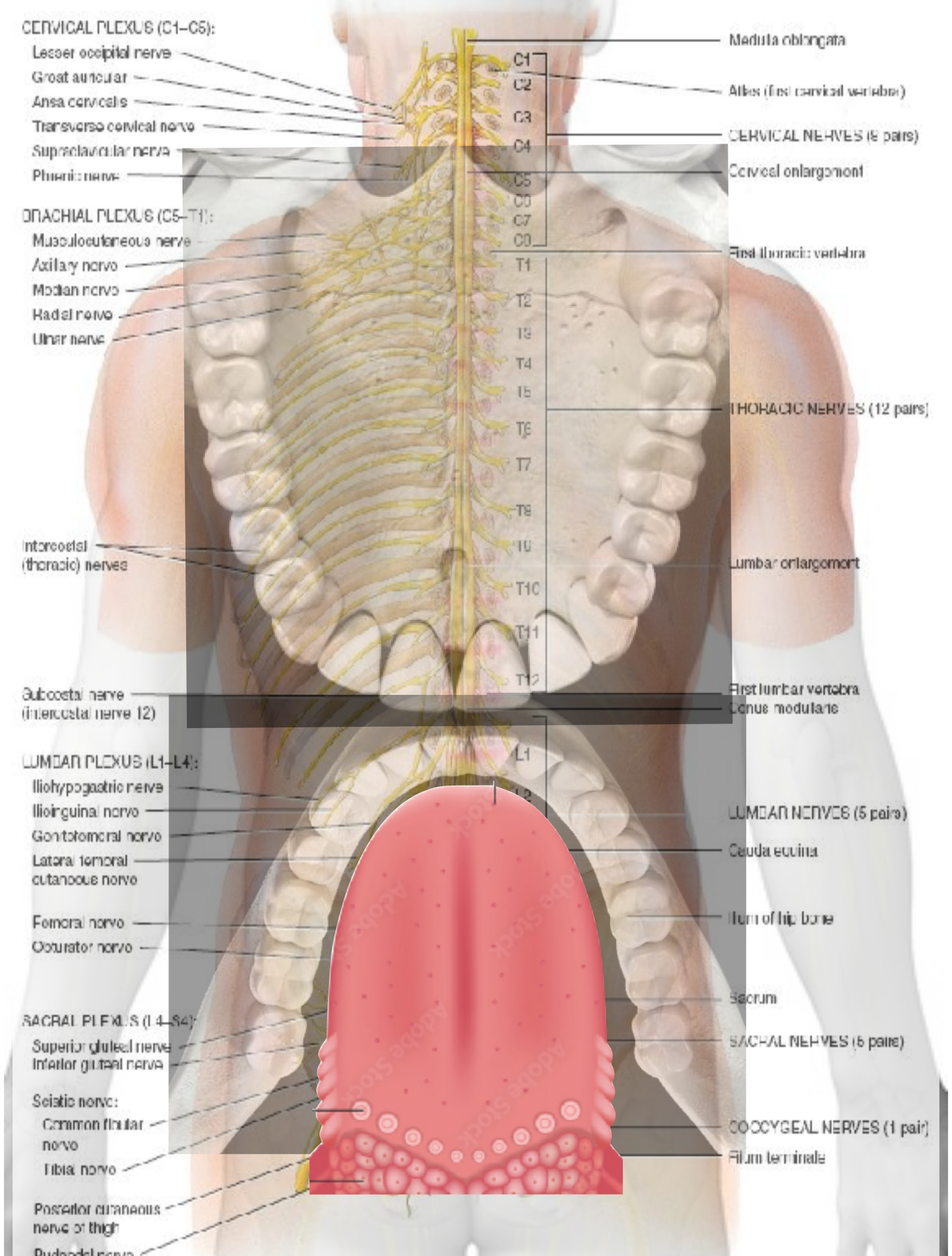
CERVICAL PLEXUS (C1–C5):
Lesser occipital nerve
Great auricular
Ansa cervicalis
Transverse cervical nerve
Supraclavicular nerve
Phrenic nerve
BRACHIAL PLEXUS (C5–T1):
Musculocutaneous nerve
Axillary nerve
Median nerve
Radial nerve
Ulnar nerve
Intercostal (thoracic) nerves
Subcostal nerve (intercostal nerve 12)
LUMBAR PLEXUS (L1–L4):
Iliohypogastric nerve
Ilioinguinal nerve
Genitofemoral nerve
Lateral femoral cutaneous nerve
Femoral nerve
Obturator nerve
SACRAL PLEXUS (L4–S4):
Superior gluteal nerve
Inferior gluteal nerve
Sciatic nerve:
Common fibular nerve
Tibial nerve
Posterior cutaneous nerve of thigh
Pudendal nerve
Medulla oblongata
C1
C2
C3
C4
C5
C6
C7
C8
Atlas (first cervical vertebra)
CERVICAL NERVES (8 pairs)
Cervical enlargement
First thoracic vertebra
T1
T2
T3
T4
T5
T6
T7
T8
T9
T10
T11
T12
THORACIC NERVES (12 pairs)
Lumbar enlargement
First lumbar vertebra
Conus medullaris
L1
L2
LUMBAR NERVES (5 pairs)
Cauda equina
Ilium of hip bone
Sacrum
SACRAL NERVES (5 pairs)
COCCYGEAL NERVES (1 pair)
Filum terminale

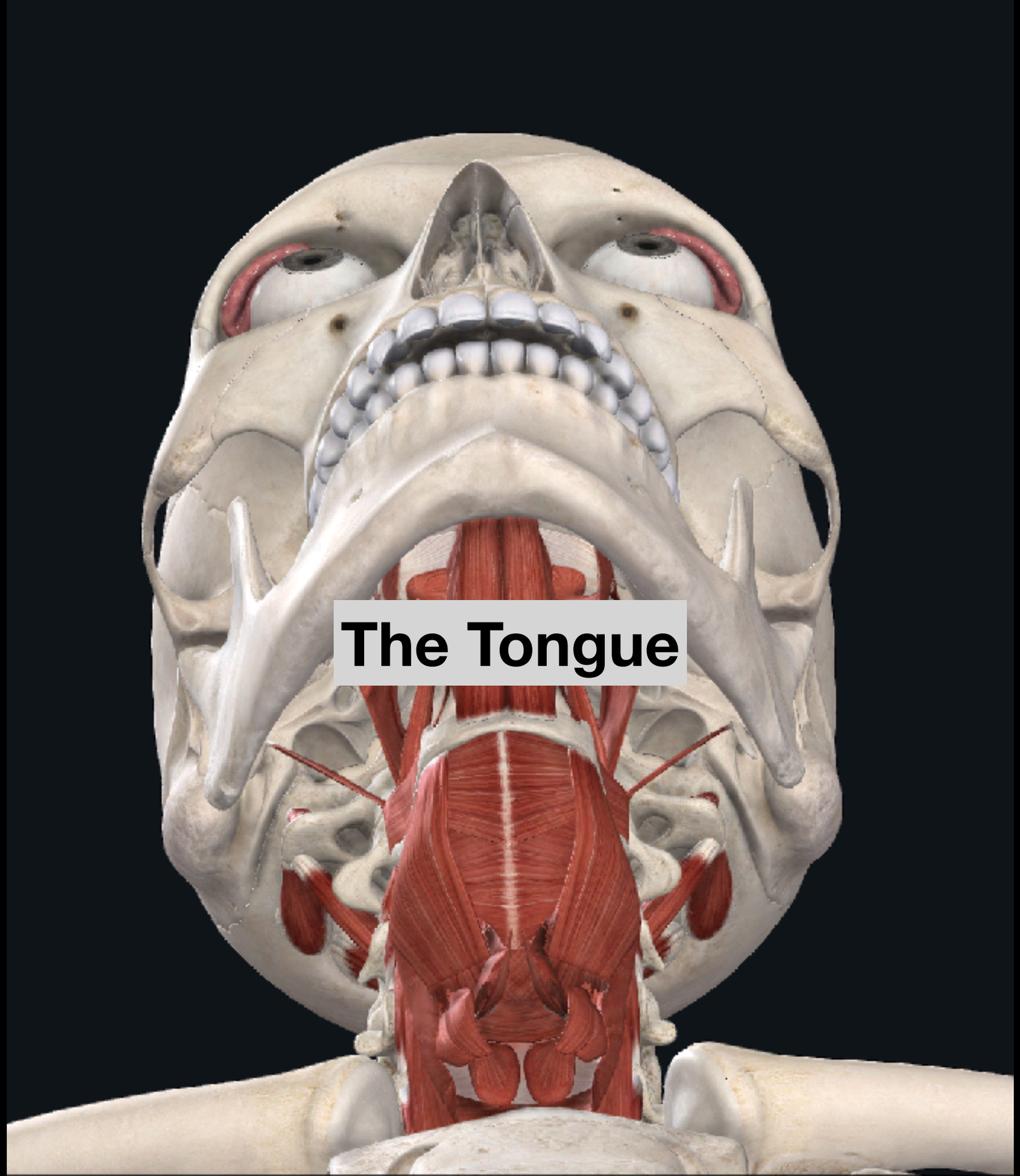

The Tongue

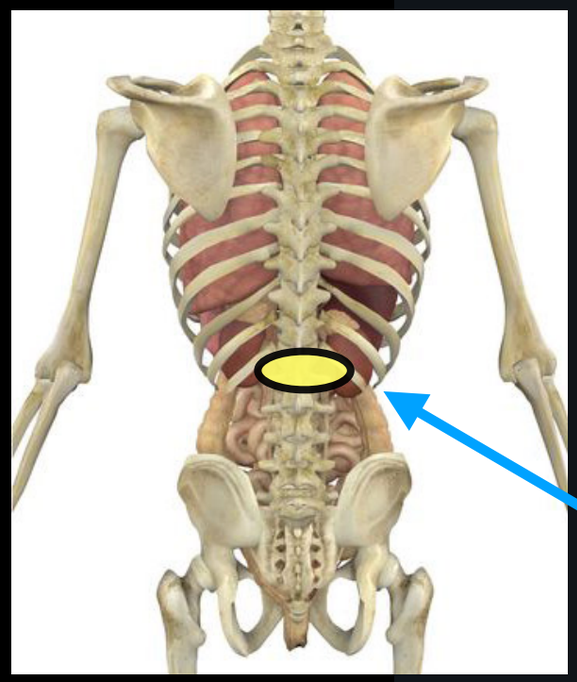

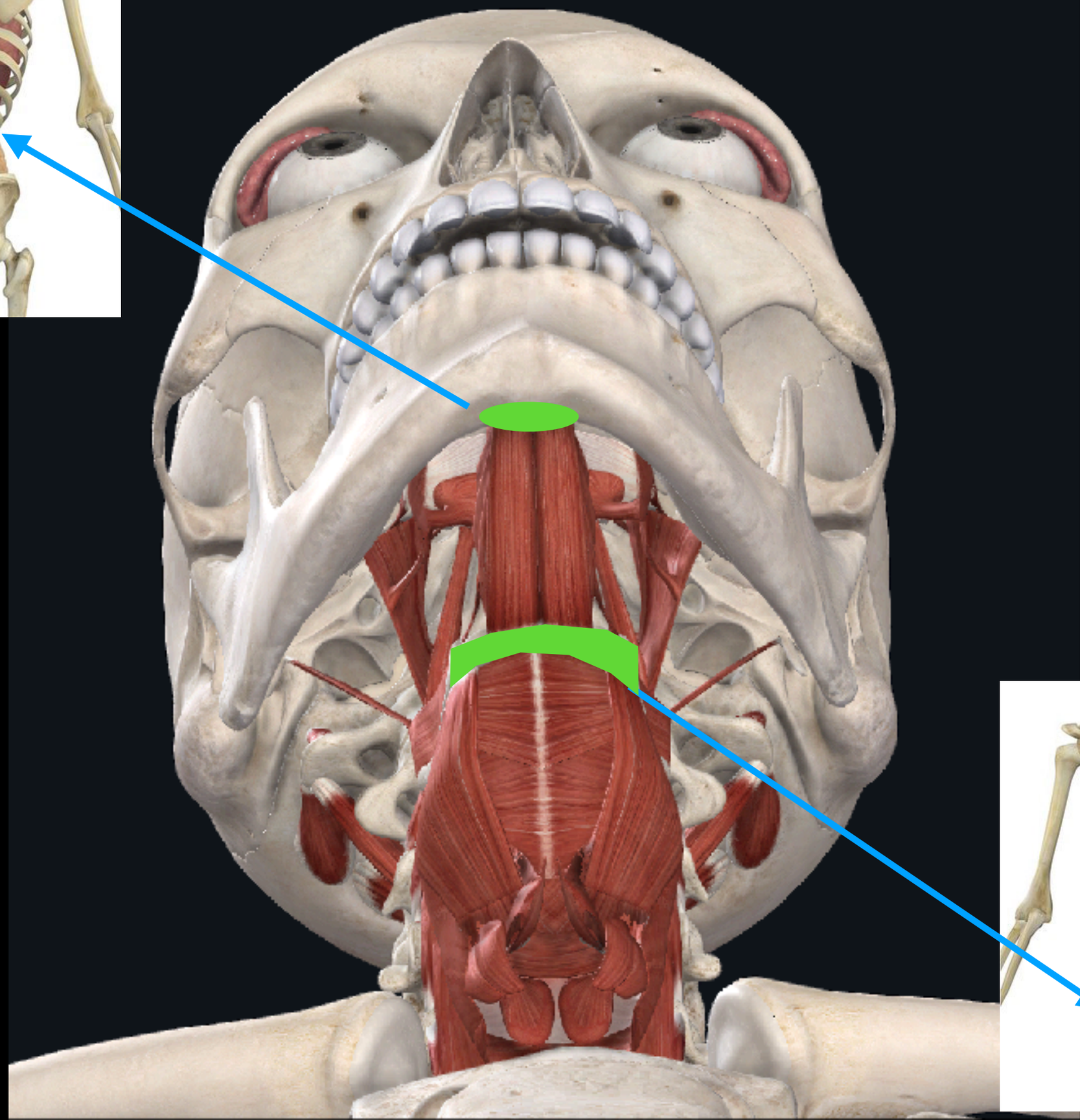

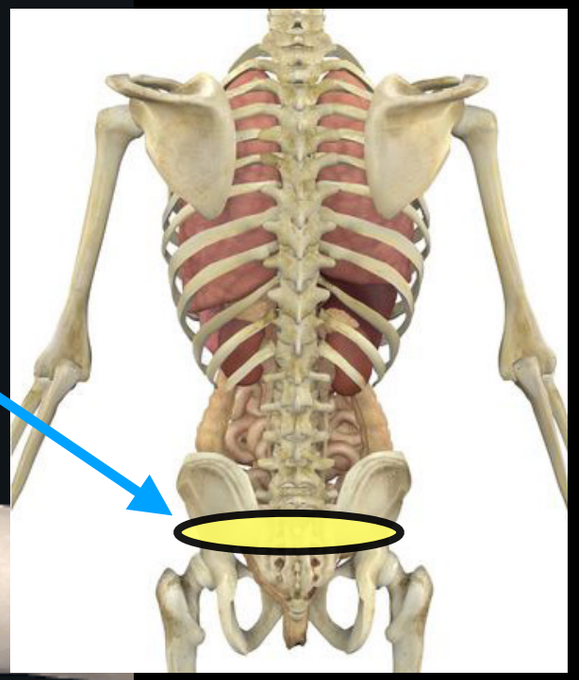

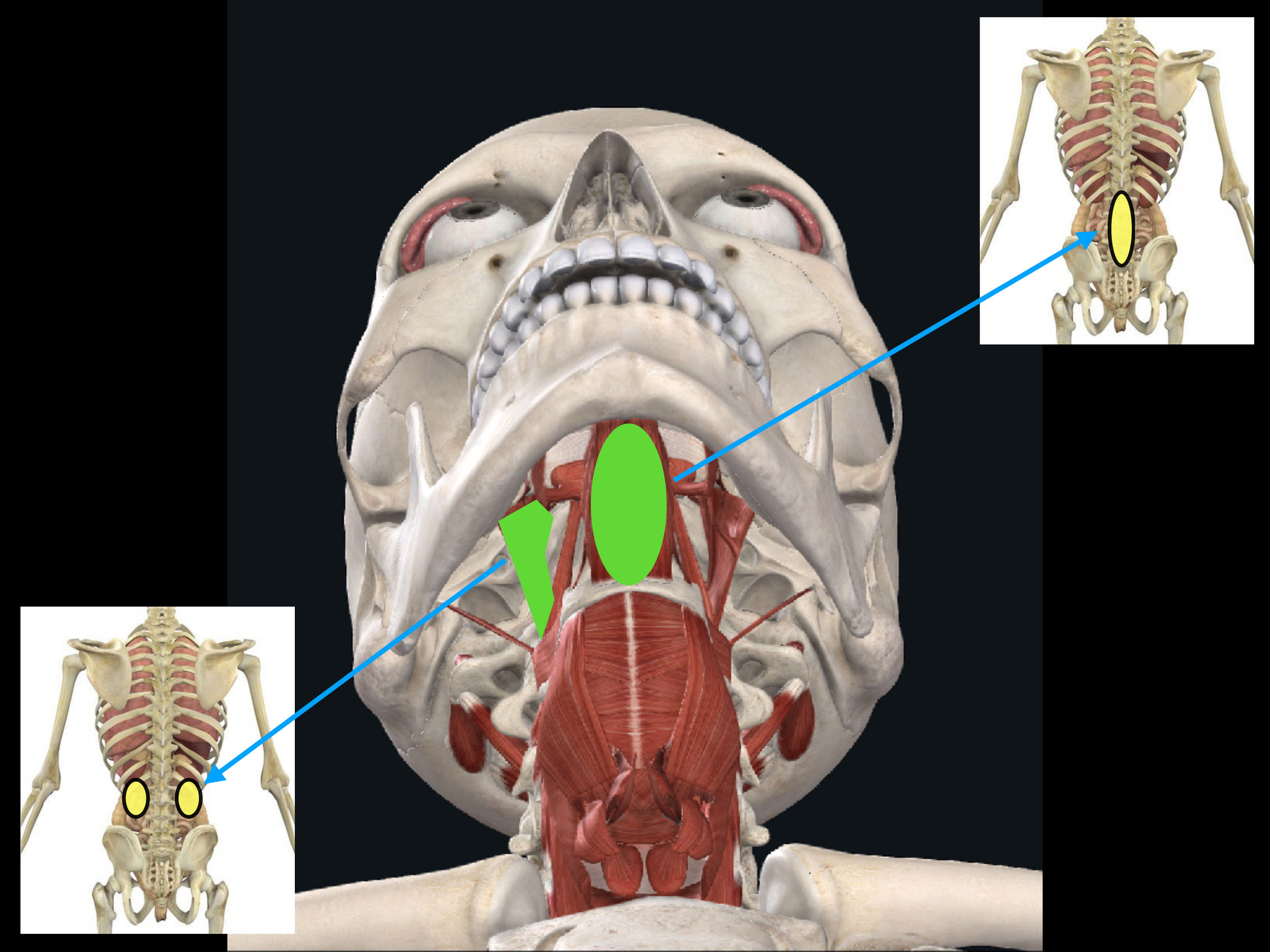

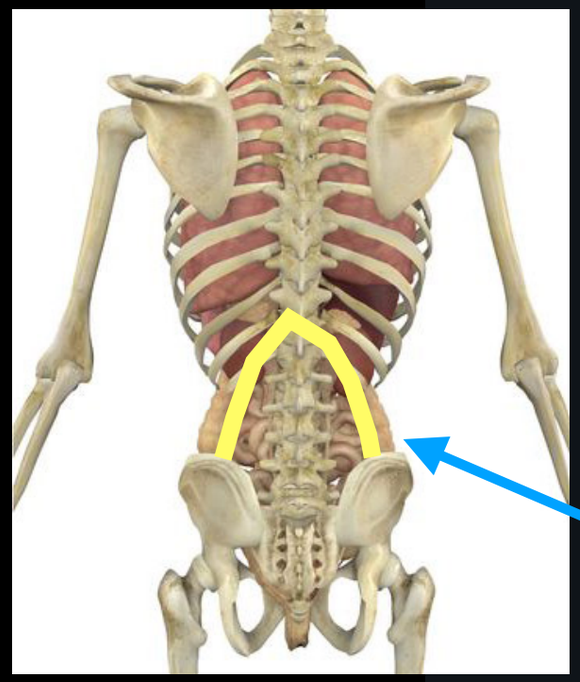

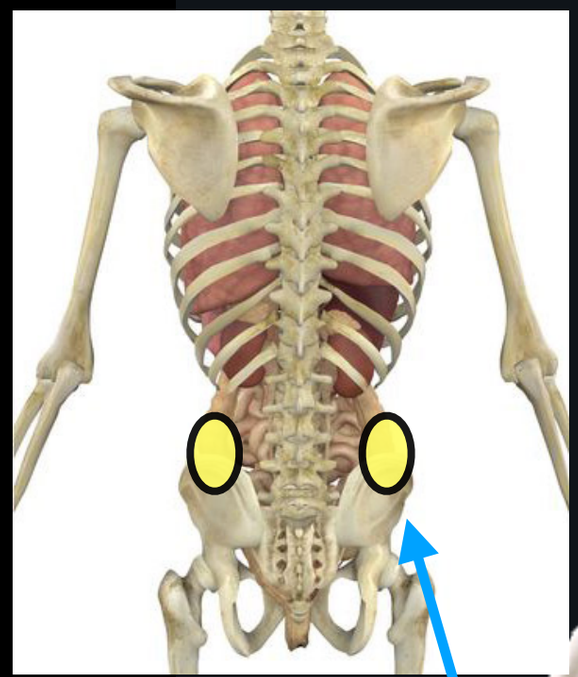

The Tongue

- You should be able to see a pattern in the way the muscles relate to the back (the lumbar spine). We have not covered every muscle, but the pattern will lead you to the specific muscle if it was not presented here.

The Hyoid

The Hyoid Bone

- The **hyoid bone** (lingual **bone** or tongue-**bone**) (/ˈhaɪɔɪd/) is a horseshoe-shaped **bone** situated in the anterior midline of the neck between the chin and the thyroid cartilage. At rest, it lies at the level of the base of the mandible in the front and the third cervical vertebra (C3) behind.

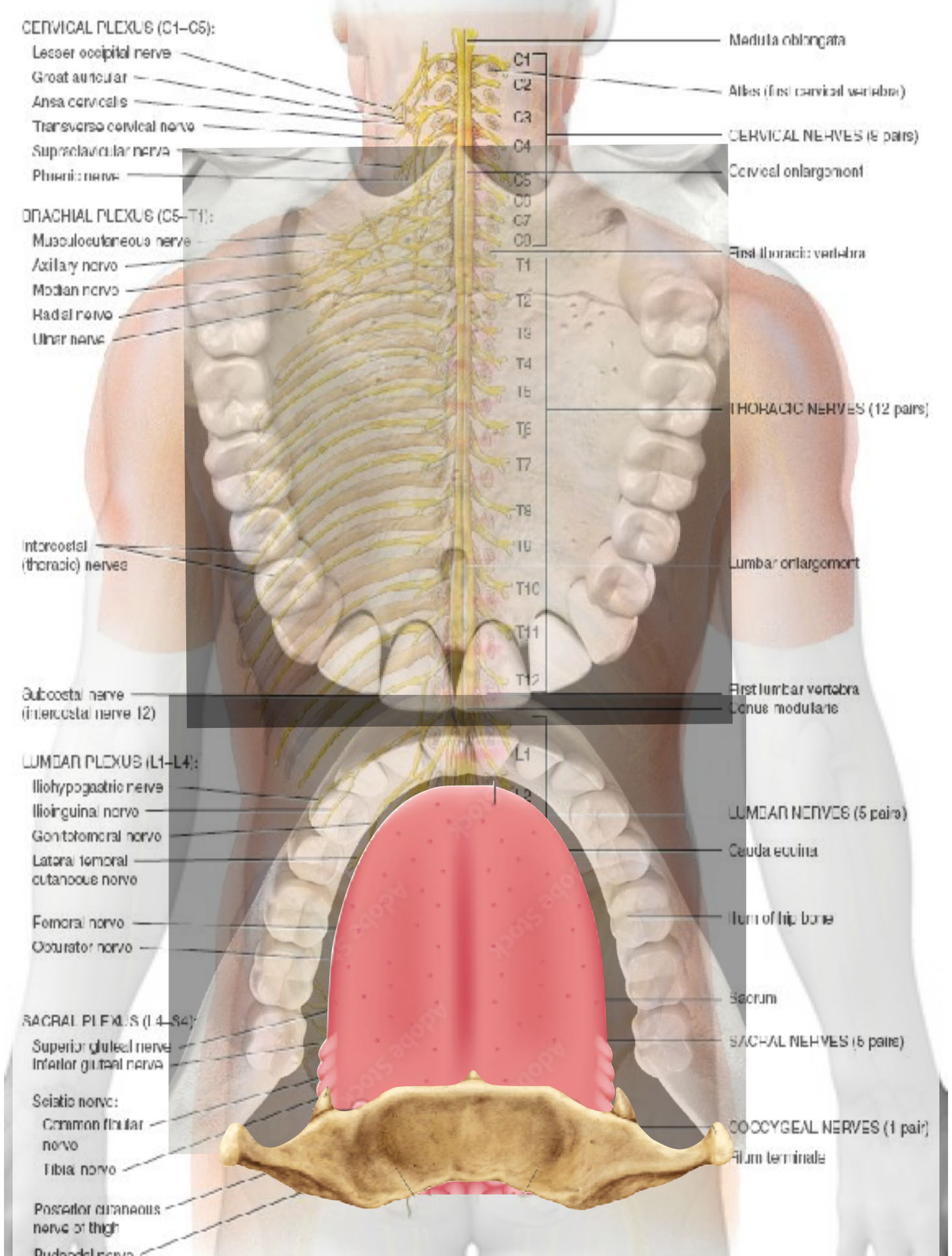
CERVICAL PLEXUS (C1–C5):
Lesser occipital nerve
Great auricular
Ansa cervicalis
Transverse cervical nerve
Supraclavicular nerve
Phrenic nerve
BRACHIAL PLEXUS (C5–T1):
Musculocutaneous nerve
Axillary nerve
Median nerve
Radial nerve
Ulnar nerve
Intercostal (thoracic) nerves
Subcostal nerve (intercostal nerve 12)
LUMBAR PLEXUS (L1–L4):
Iliohypogastric nerve
Ilioinguinal nerve
Genitofemoral nerve
Lateral femoral cutaneous nerve
Femoral nerve
Obturator nerve
SACRAL PLEXUS (L4–S4):
Superior gluteal nerve
Inferior gluteal nerve
Sciatic nerve:
Common fibular nerve
Tibial nerve
Posterior cutaneous nerve of thigh
Pudendal nerve
Medulla oblongata
C1
C2
C3
C4
C5
C6
C7
C8
Atlas (first cervical vertebra)
CERVICAL NERVES (8 pairs)
Cervical enlargement
First thoracic vertebra
T1
T2
T3
T4
T5
T6
T7
T8
T9
T10
T11
T12
THORACIC NERVES (12 pairs)
Lumbar enlargement
First lumbar vertebra
Conus medullaris
L1
L2
LUMBAR NERVES (5 pairs)
Cauda equina
Ilium of hip bone
Sacrum
SACRAL NERVES (5 pairs)
COCCYGEAL NERVES (1 pair)
Filum terminale

Human hyoid bone

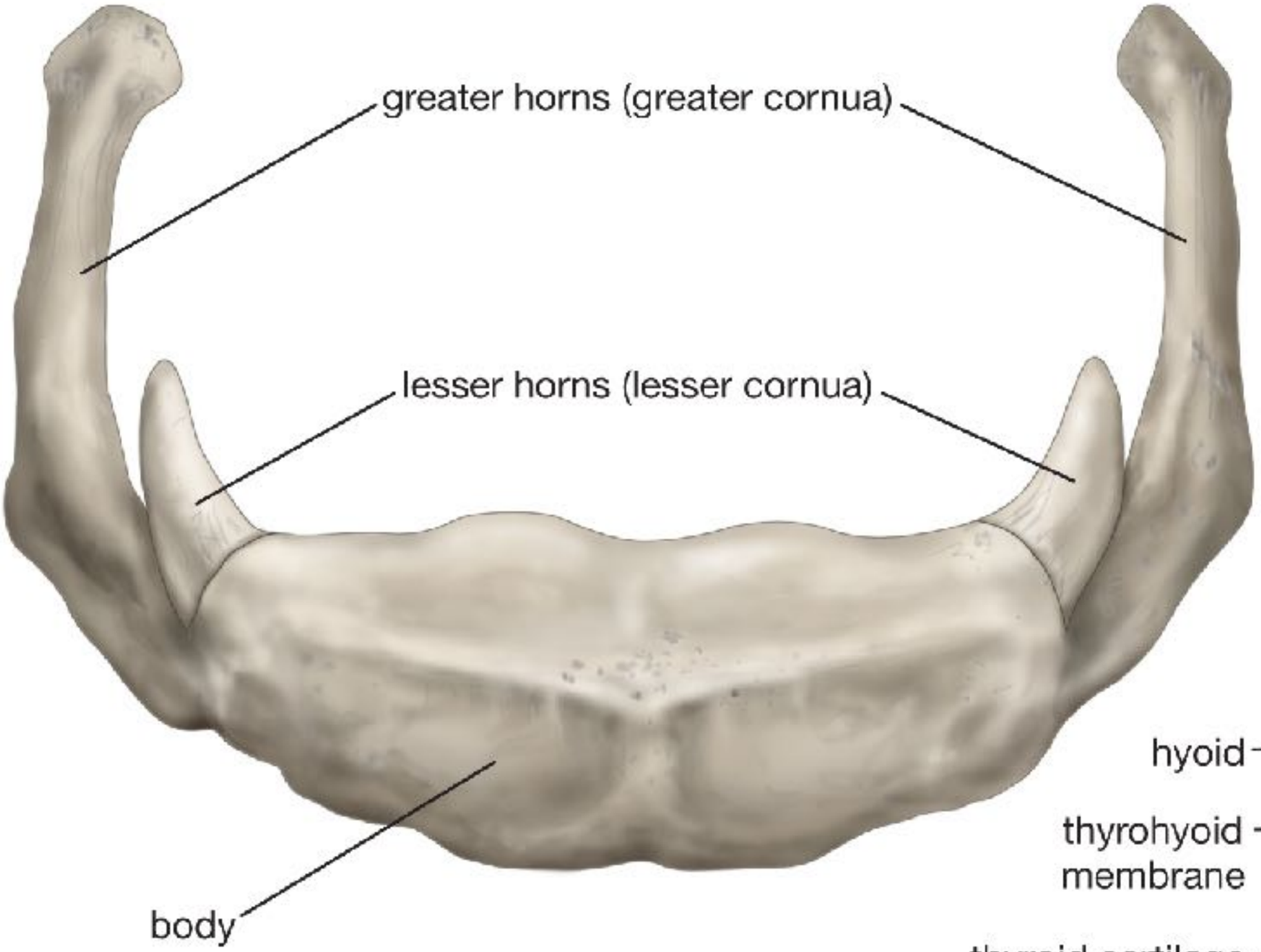

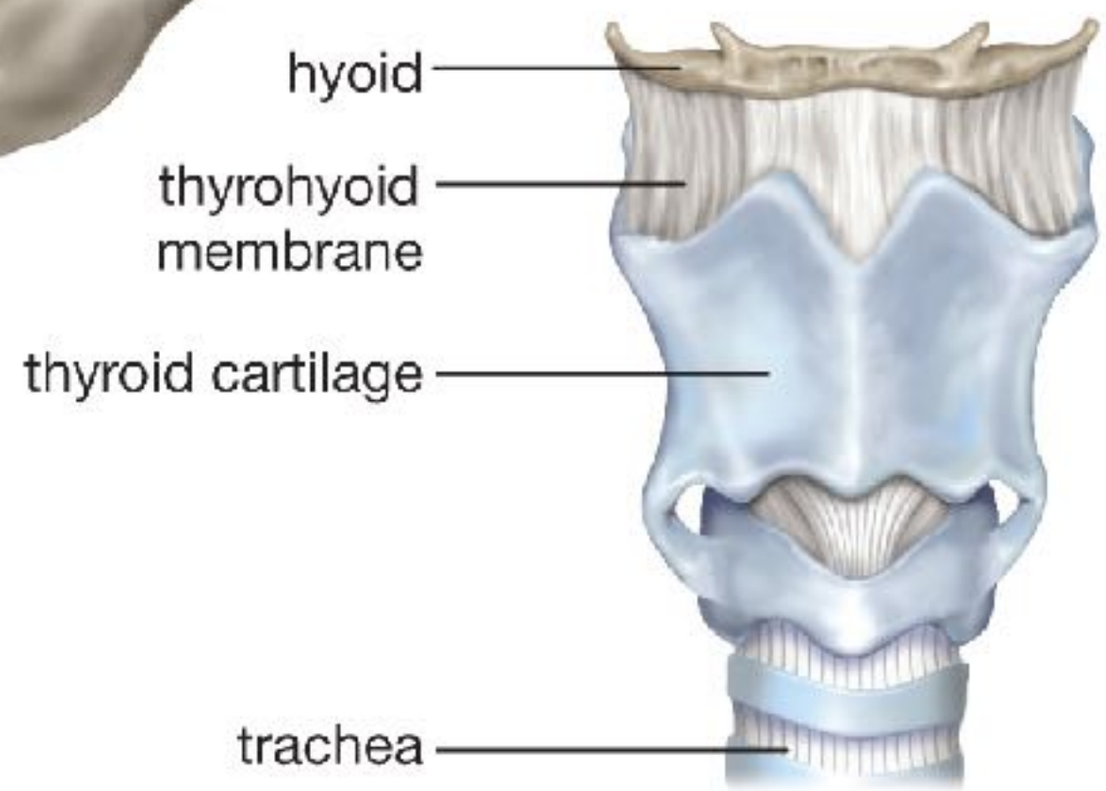

© 2013 Encyclopædia Britannica, Inc.

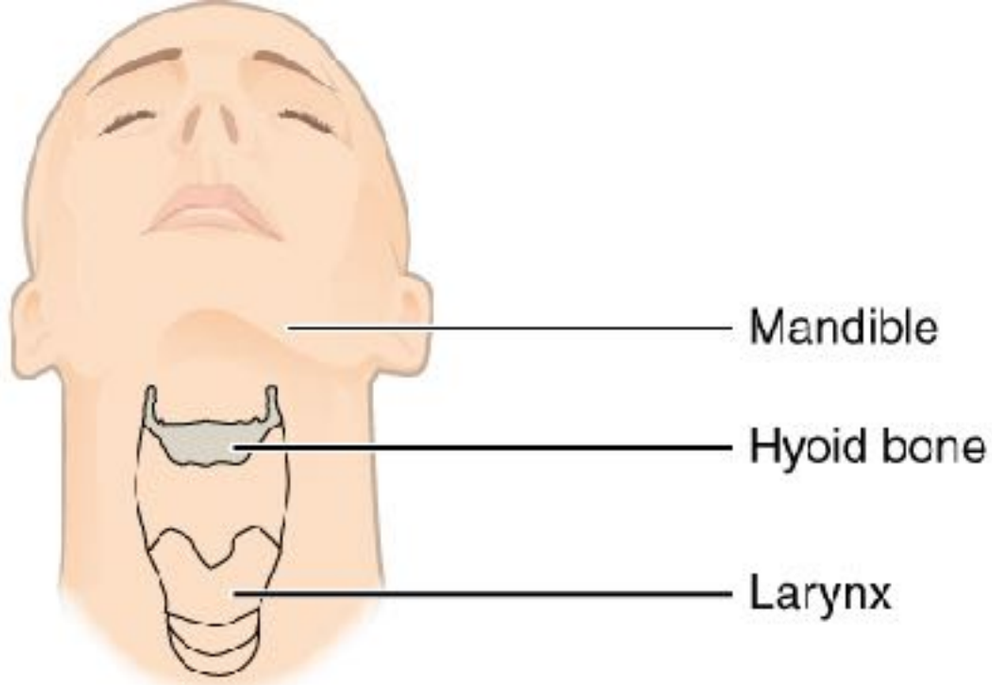

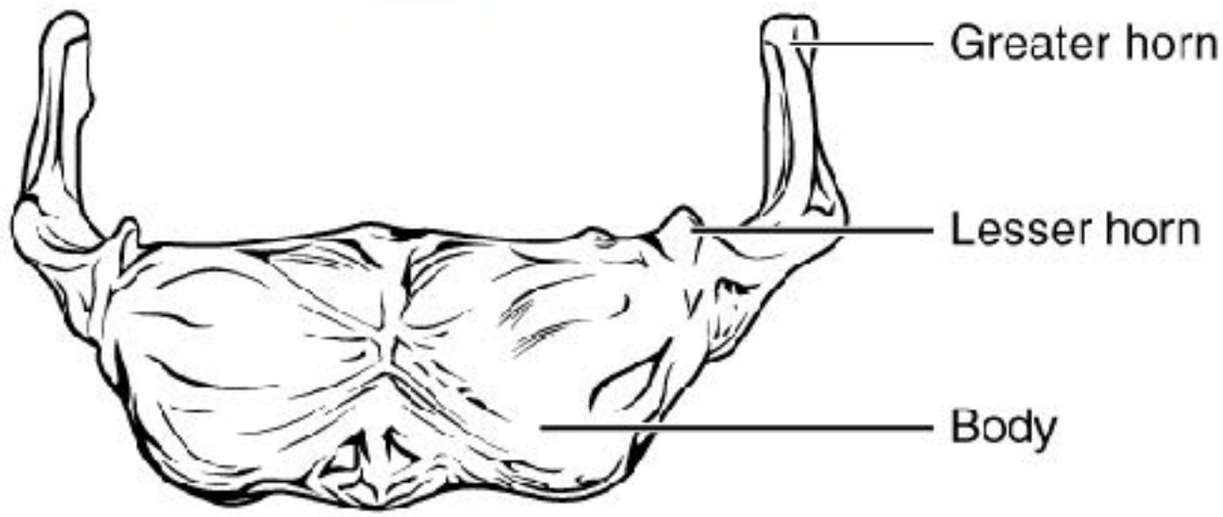

Anterior view

Right lateral view

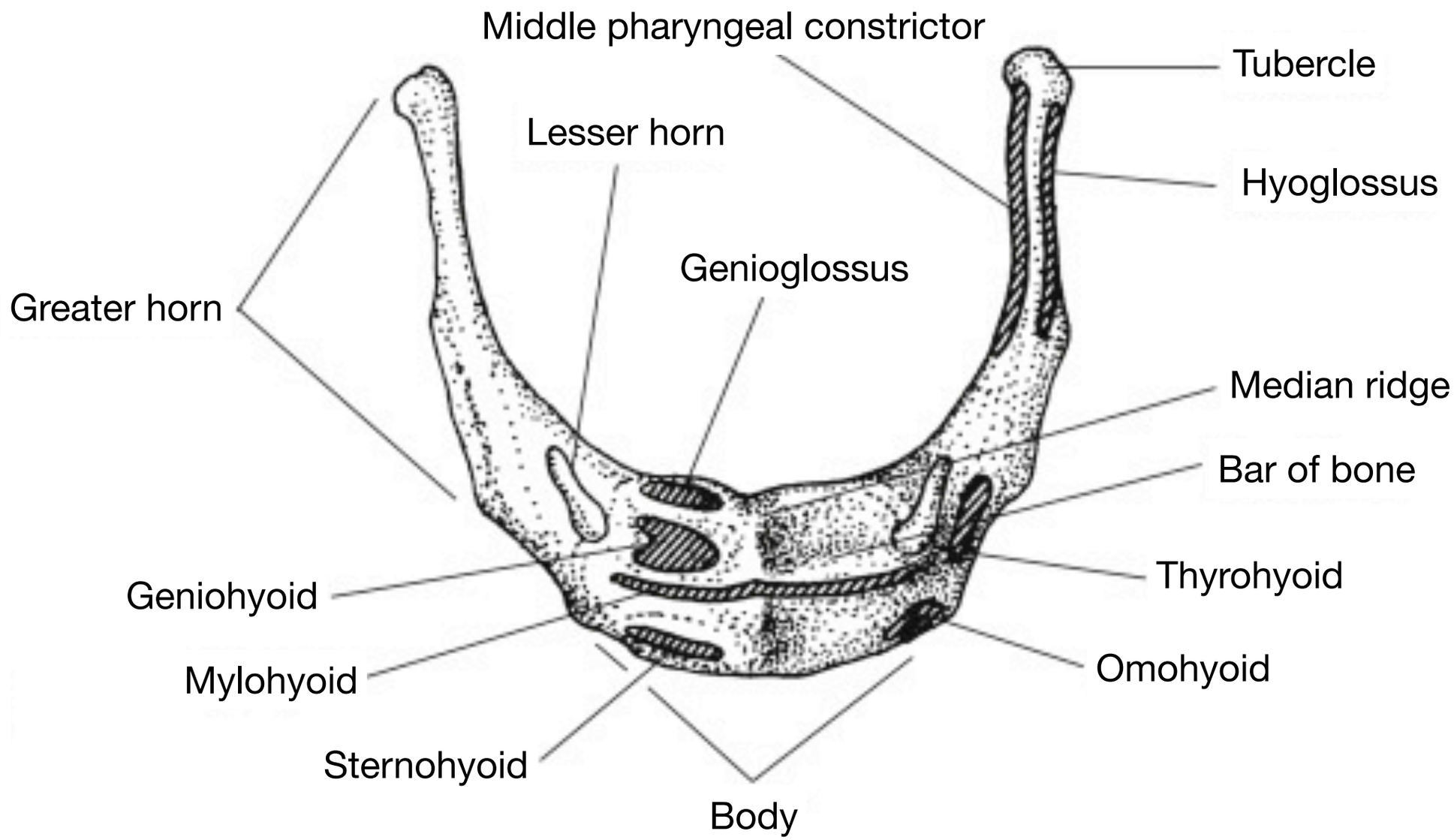
Middle pharyngeal constrictor
Tubercle
Lesser horn
Hyoglossus
Genioglossus
Greater horn
Median ridge
Bar of bone
Thyrohyoid
Geniohyoid
Omohyoid
Mylohyoid
Sternohyoid
Body

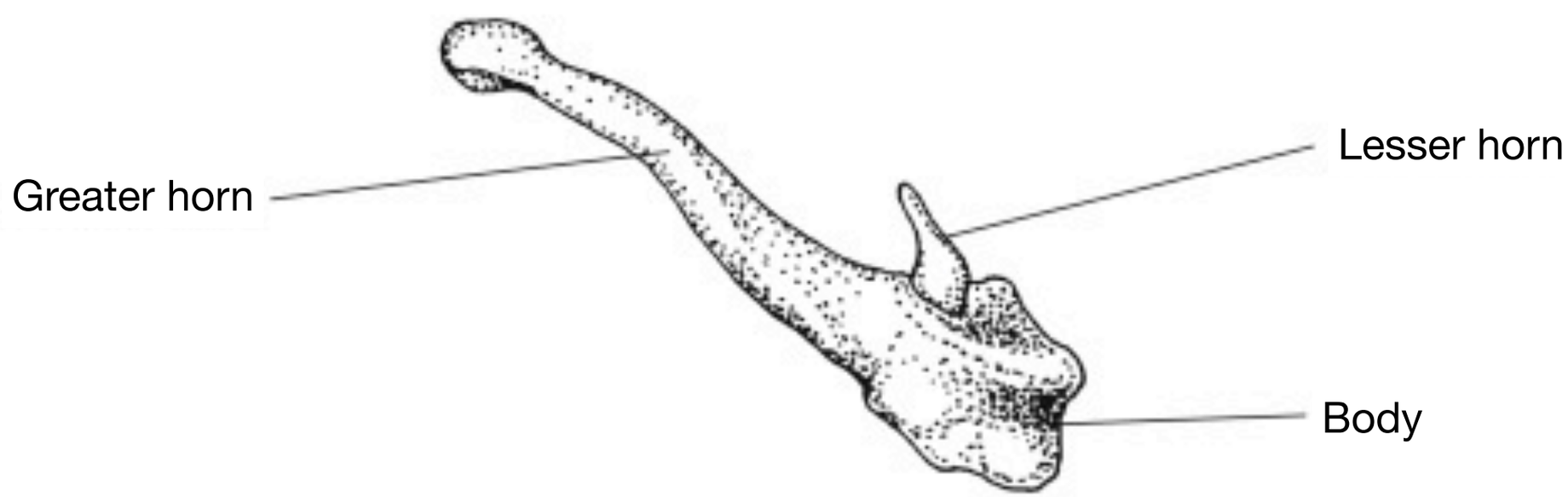
Lesser horn
Greater horn
Body

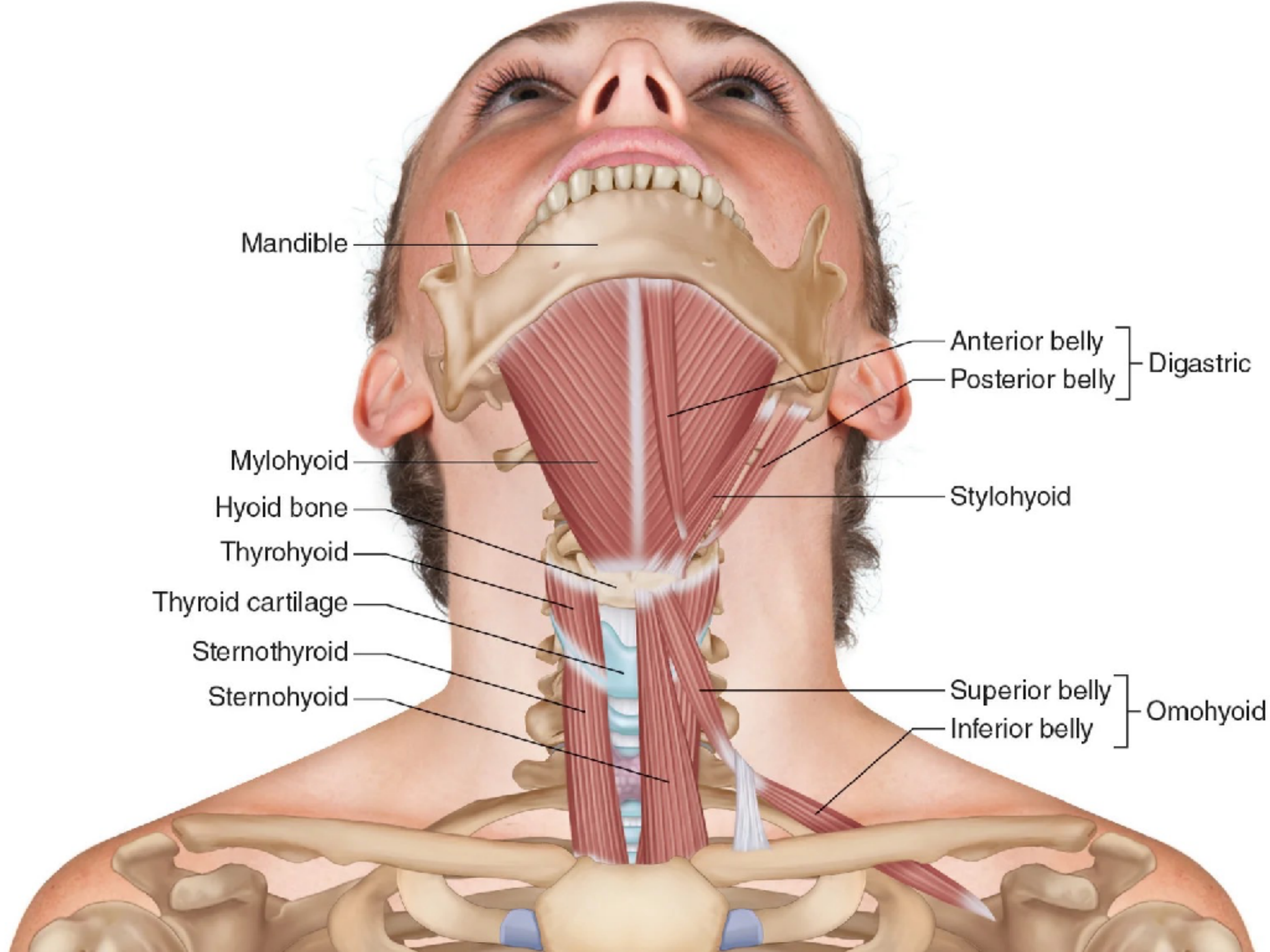
Mandible
Anterior belly
Posterior belly
Digastric
Mylohyoid
Hyoid bone
Stylohyoid
Thyrohyoid
Thyroid cartilage
Sternothyroid
Sternohyoid
Superior belly
Inferior belly
Omohyoid

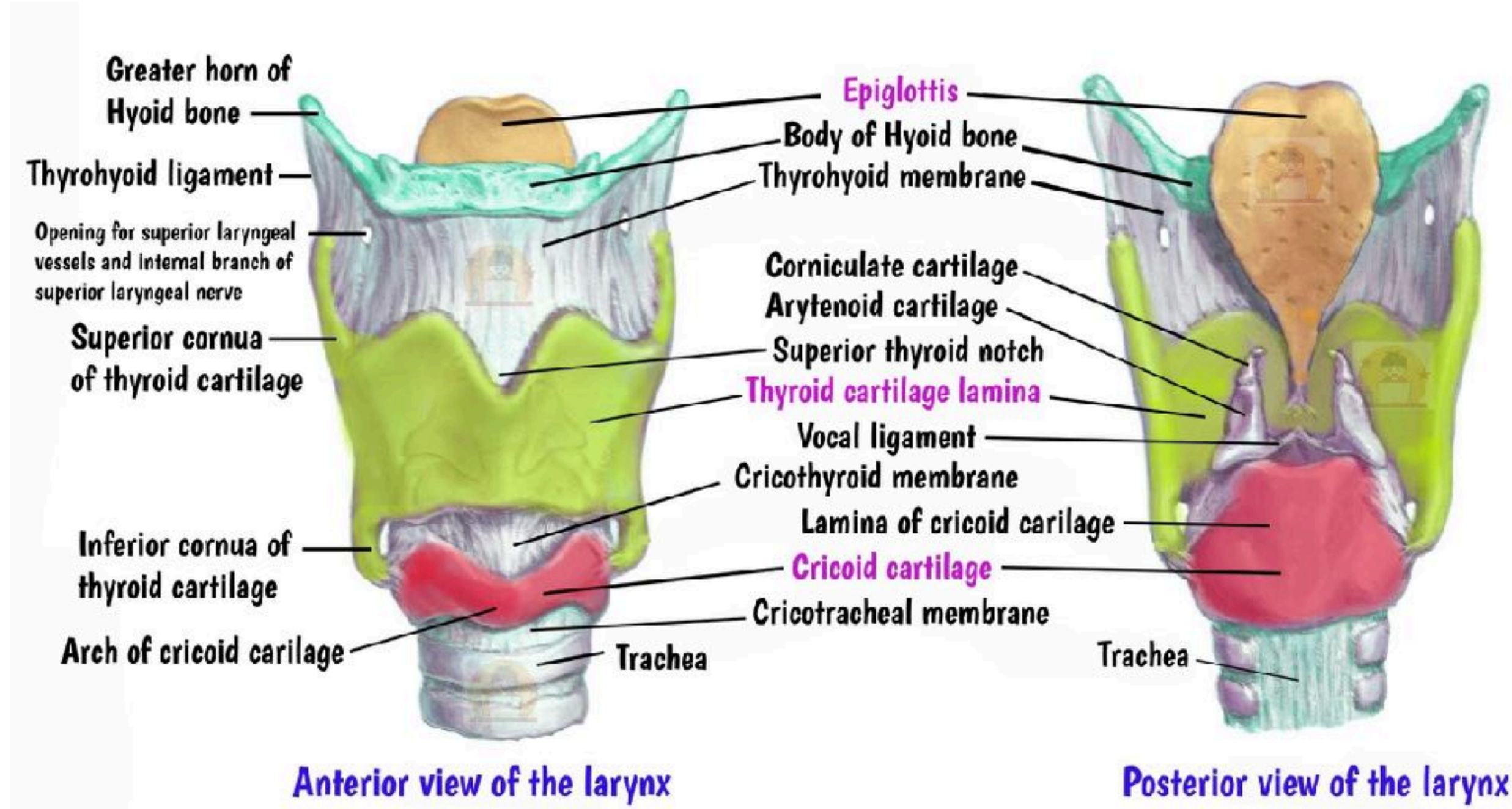

Anterior view of the larynx

Posterior view of the larynx

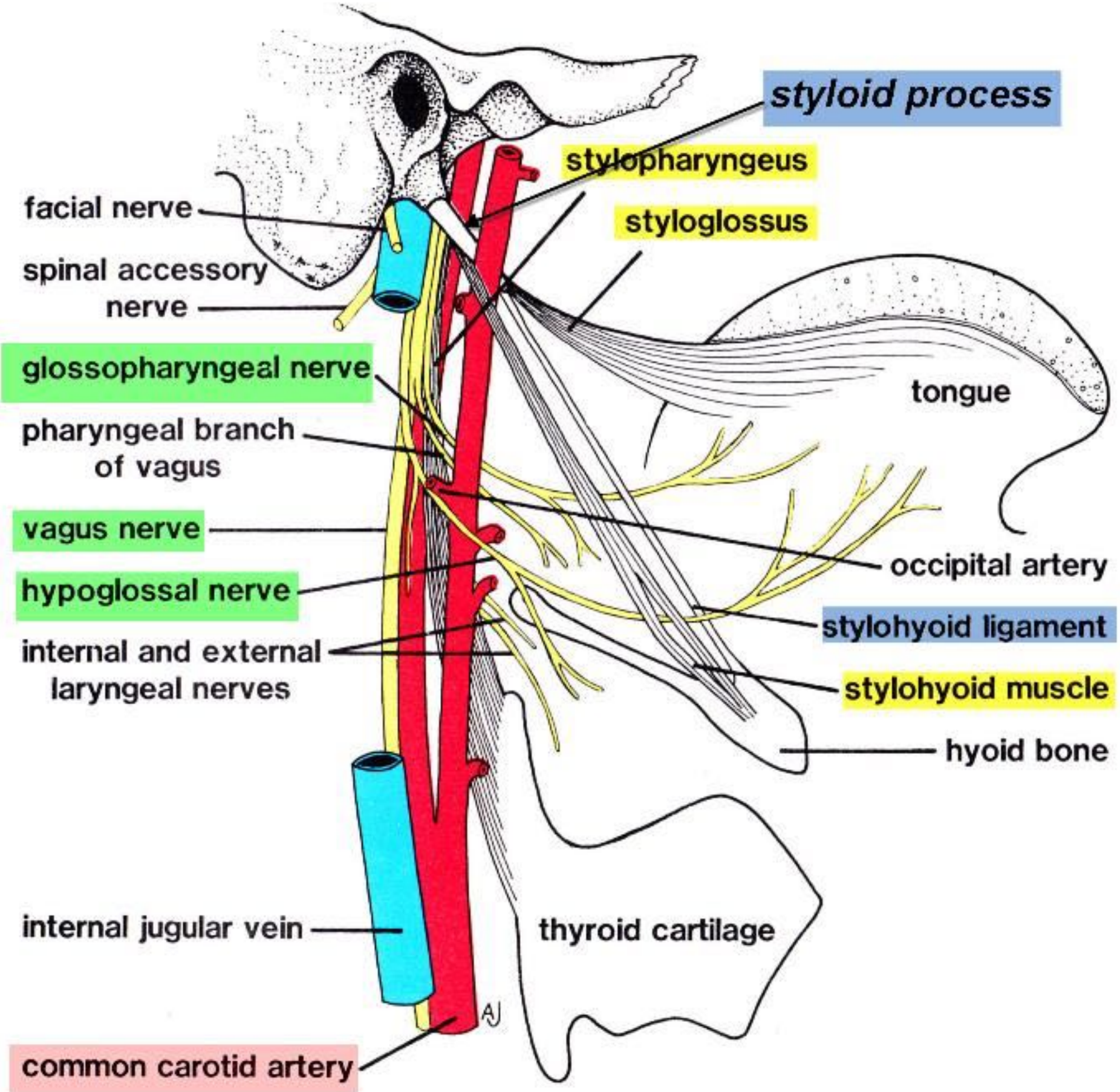
styloid process
stylopharyngeus
facial nerve
styloglossus
spinal accessory nerve
glossopharyngeal nerve
tongue
pharyngeal branch of vagus
vagus nerve
occipital artery
hypoglossal nerve
stylohyoid ligament
internal and external laryngeal nerves
stylohyoid muscle
hyoid bone
internal jugular vein
thyroid cartilage
AJ
common carotid artery

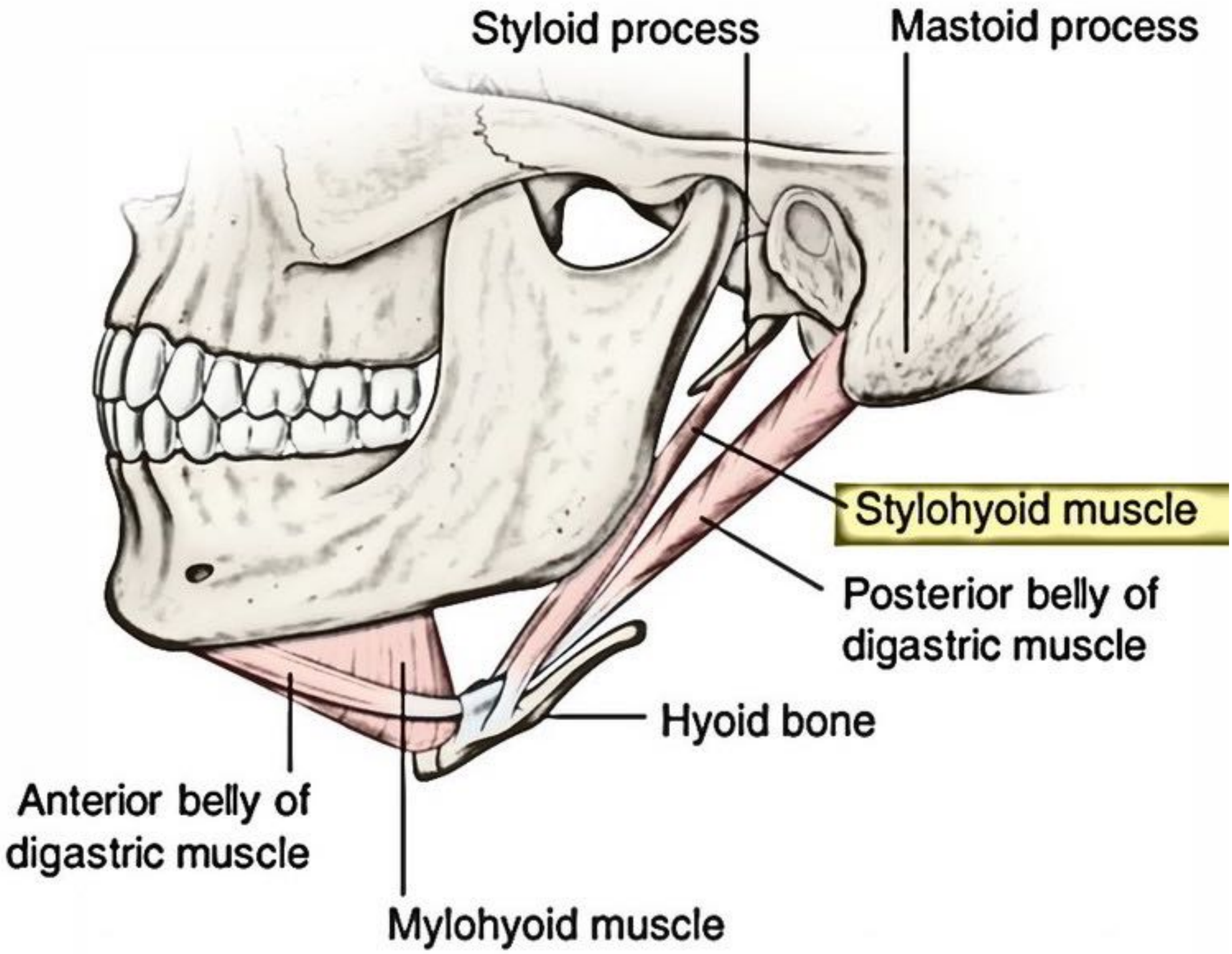
Styloid process
Mastoid process
Stylohyoid muscle
Posterior belly of digastric muscle
Hyoid bone
Anterior belly of digastric muscle
Mylohyoid muscle

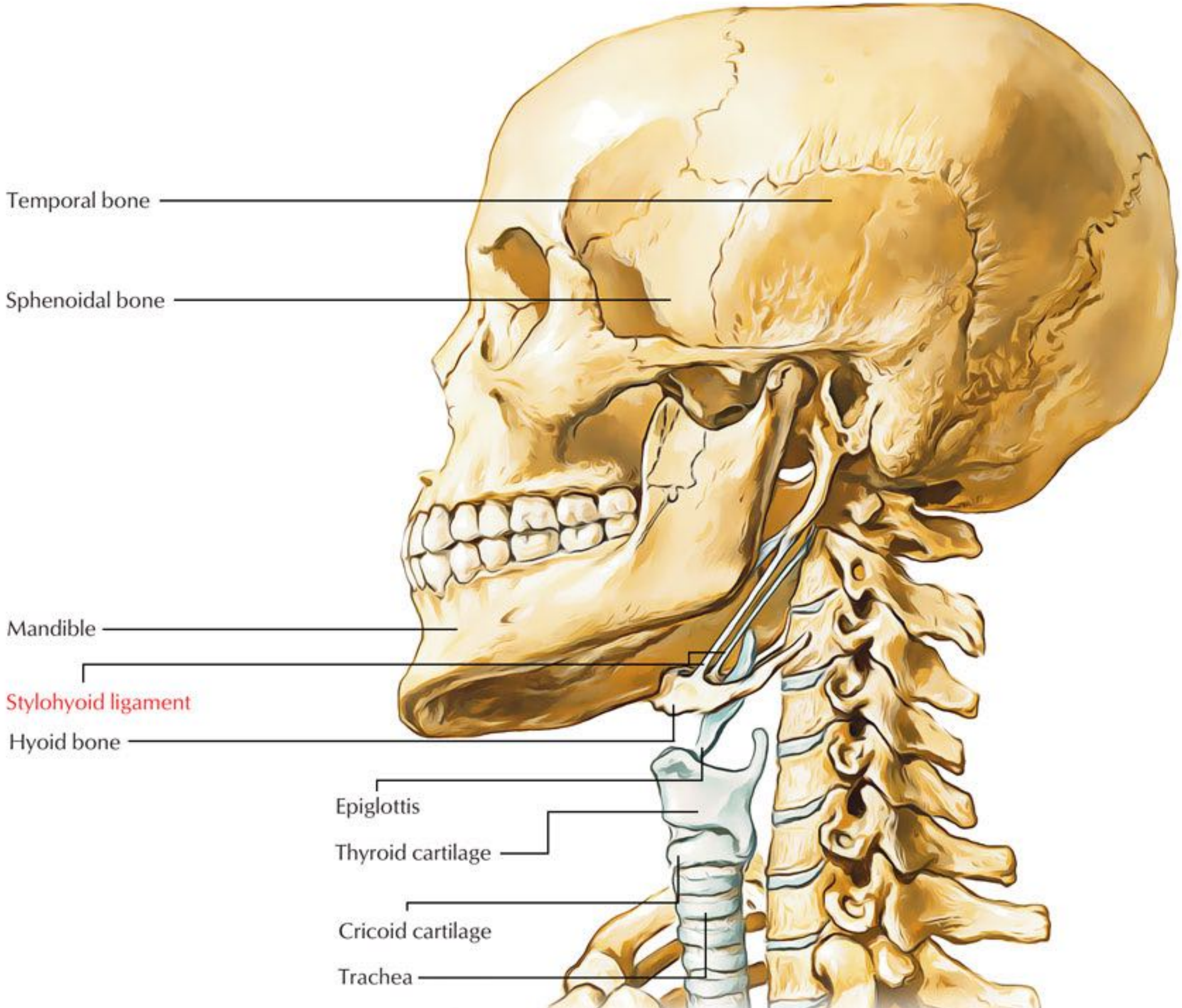
Temporal bone
Sphenoidal bone
Mandible
Stylohyoid ligament
Hyoid bone
Epiglottis
Thyroid cartilage
Cricoid cartilage
Trachea

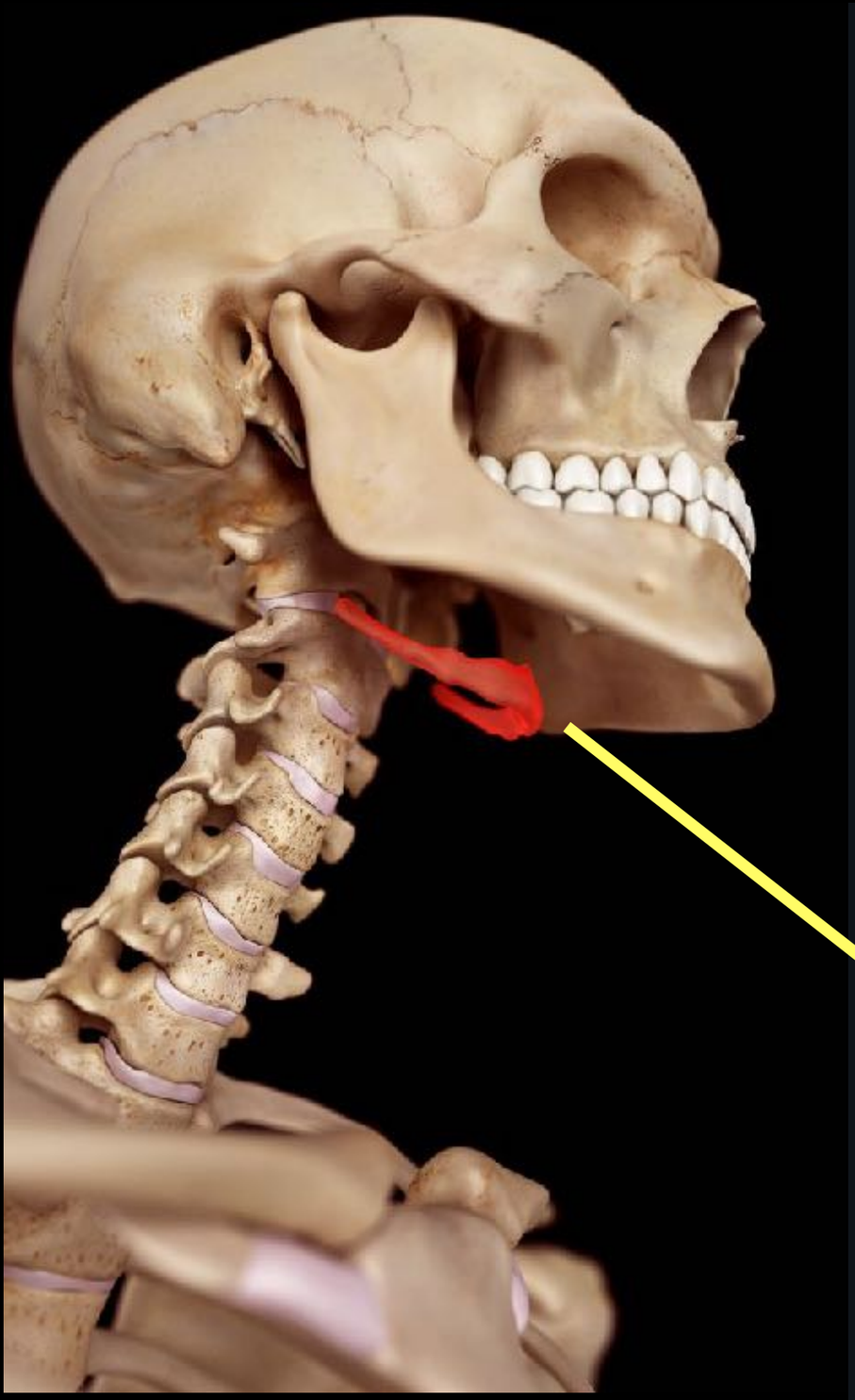

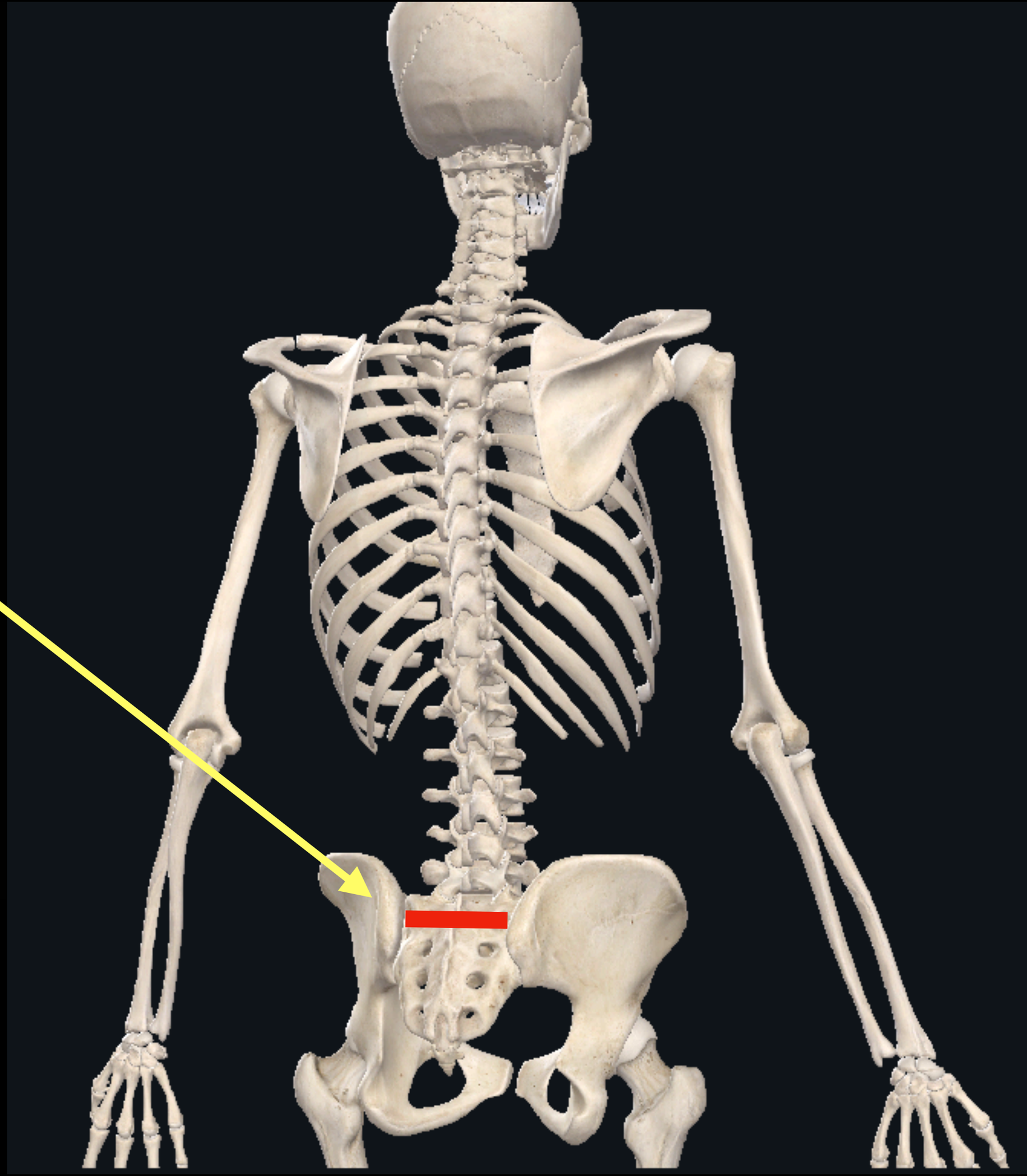

The Hyoid Bone

- Might be the most important bone in the body for posture, breathing and eating!

- Should be able to move freely in ANY direction!

Hyoid and Tongue Lab

Salad
(1st Course)

Treating the Hyoid/Tongue

- First, we will start with our heads upright, looking straight ahead.
- Then we will rotate slowly to the left and then rotate to the right, noting any tension or restriction.
- Then we will side bend our heads (ear toward shoulder) left and then right slowly, again noting any restriction or tension.

We start here, looking straight ahead

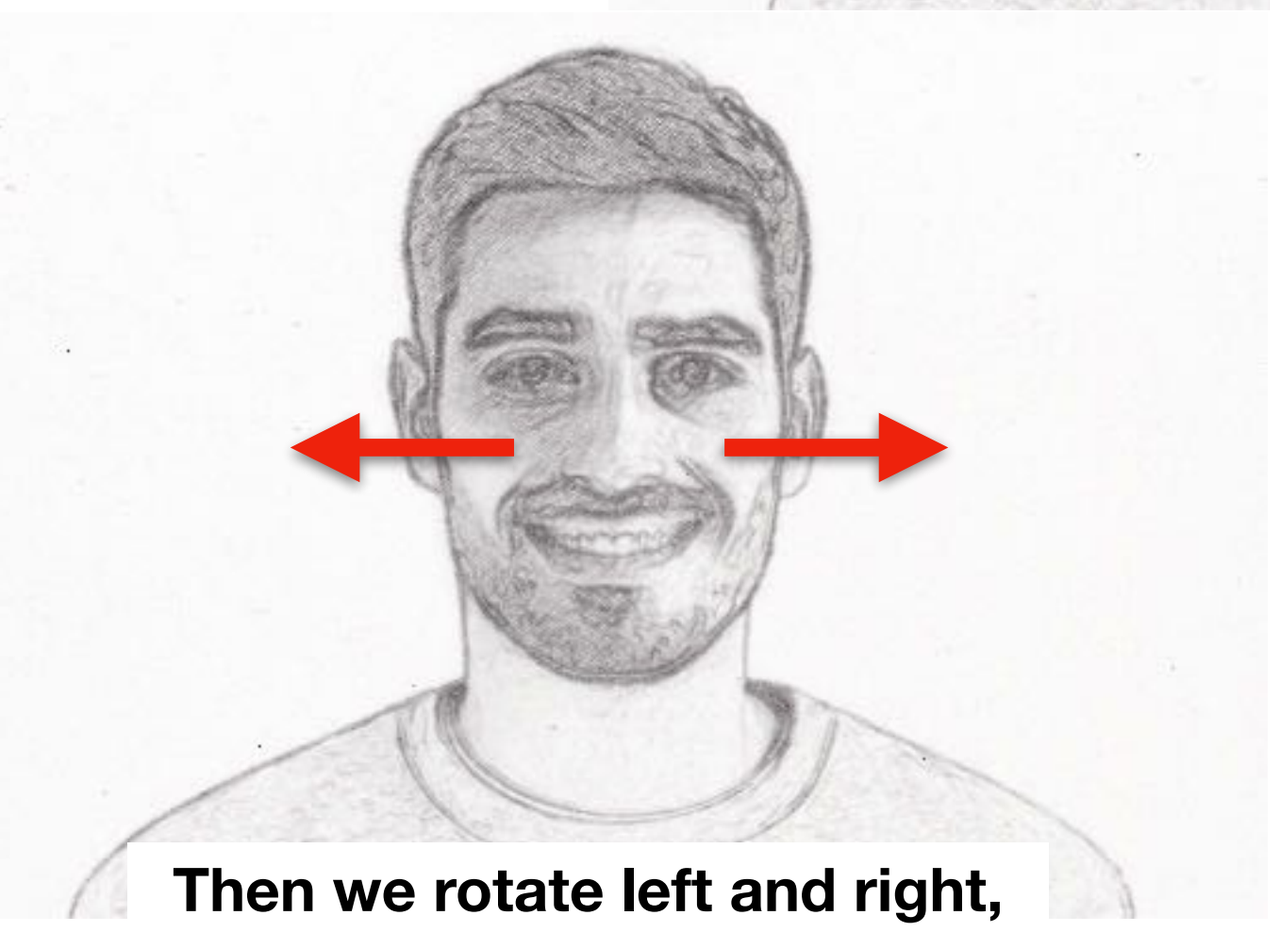

Then we rotate left and right, noting any tension

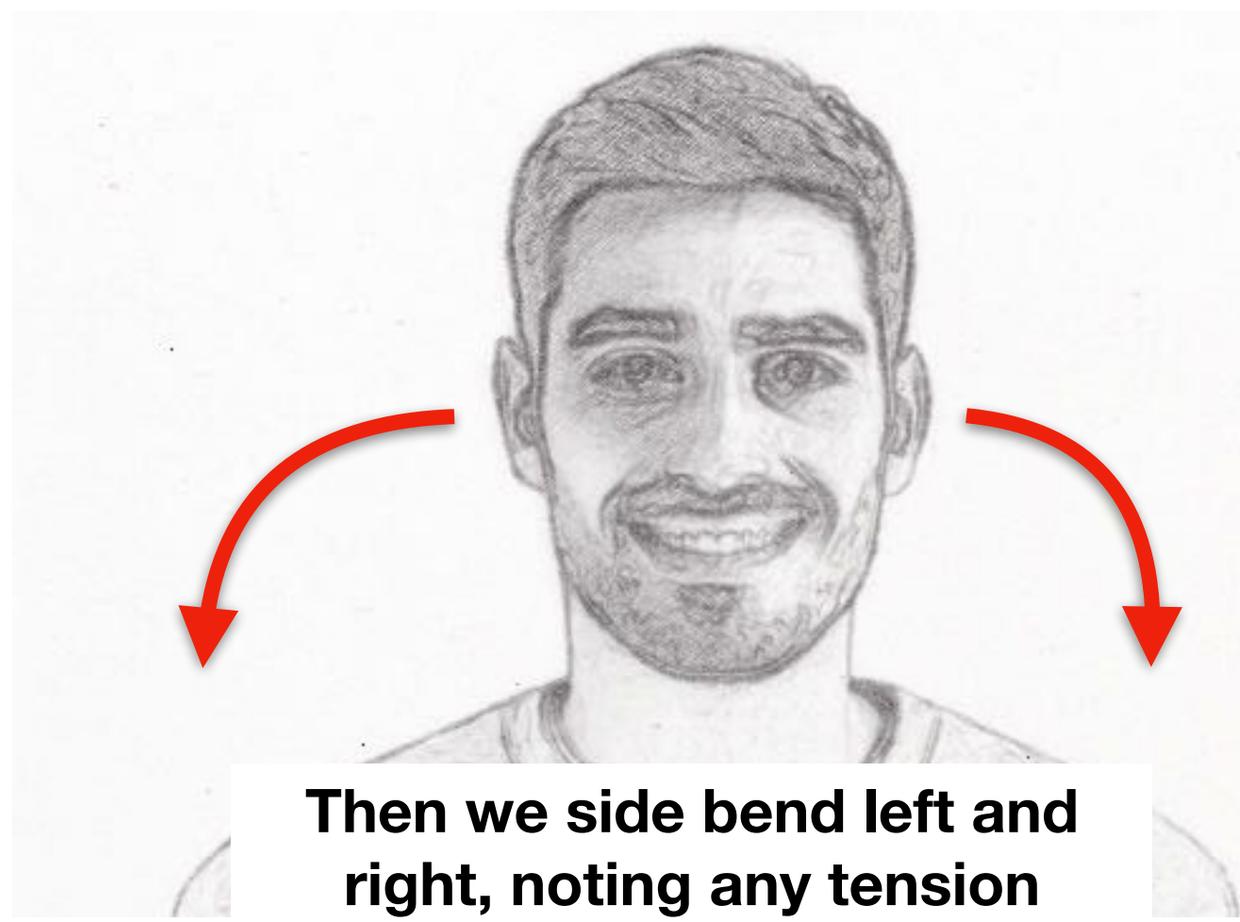

Then we side bend left and right, noting any tension

Treating the Hyoid/Tongue

- Now we are going to add a cave with the tongue and hold it while we:

- Rotate slowly to the left and then rotate to the right, noting any tension or restriction.

- Then side bend our heads (ear toward shoulder) left and then right slowly, again noting any restriction or tension.

Now do a cave with the tongue and hold it.

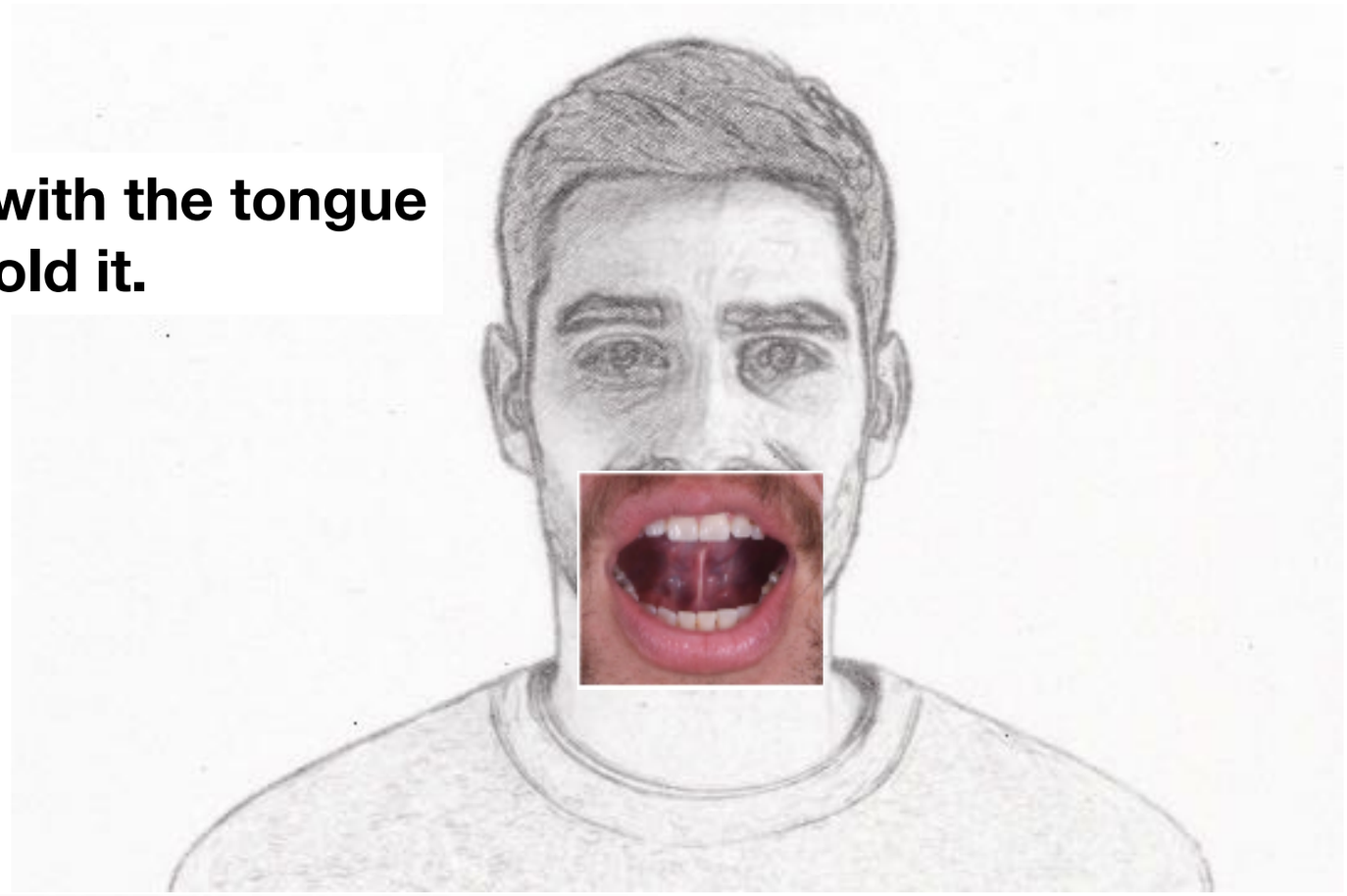

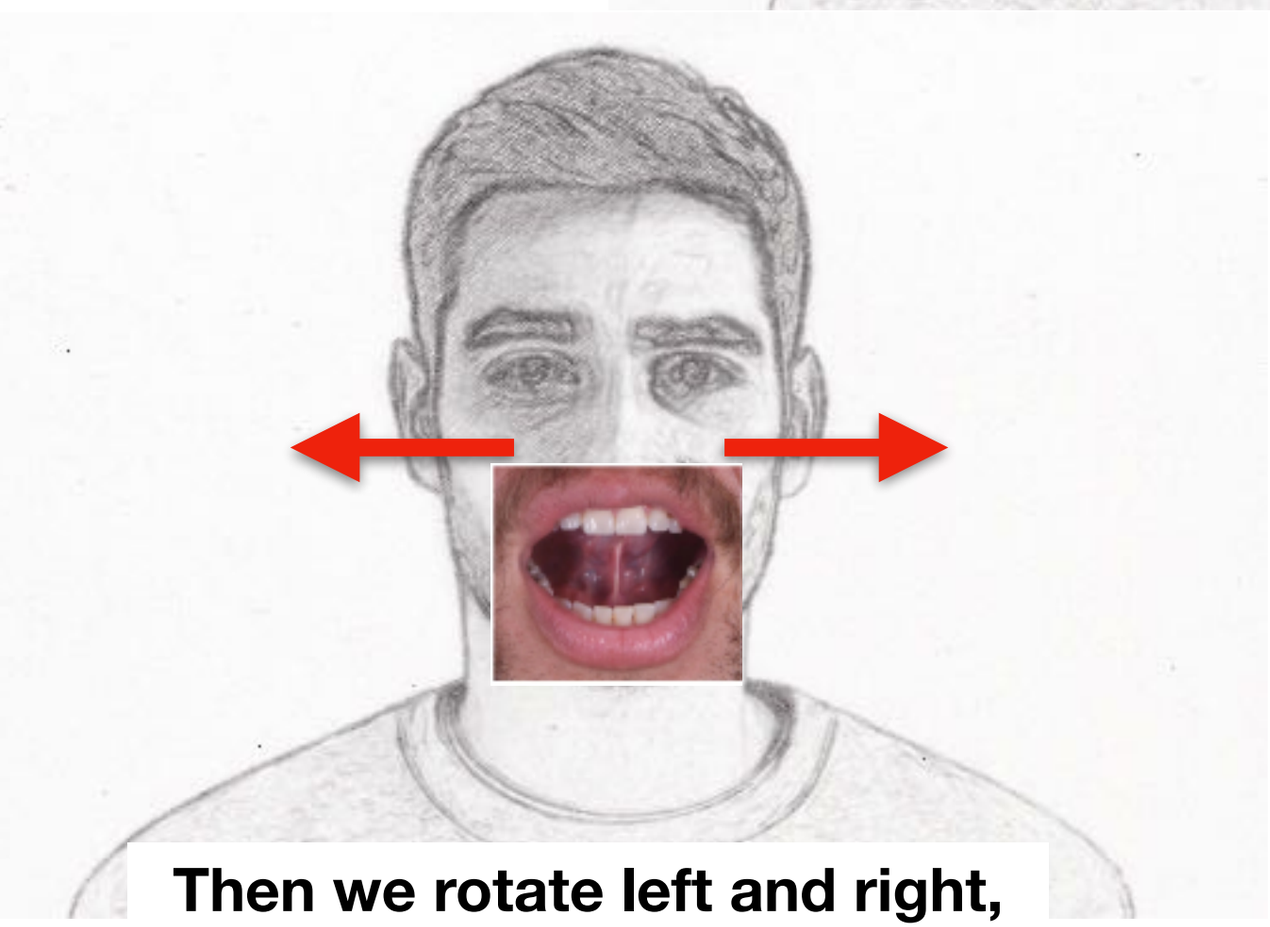

Then we rotate left and right, noting any tension

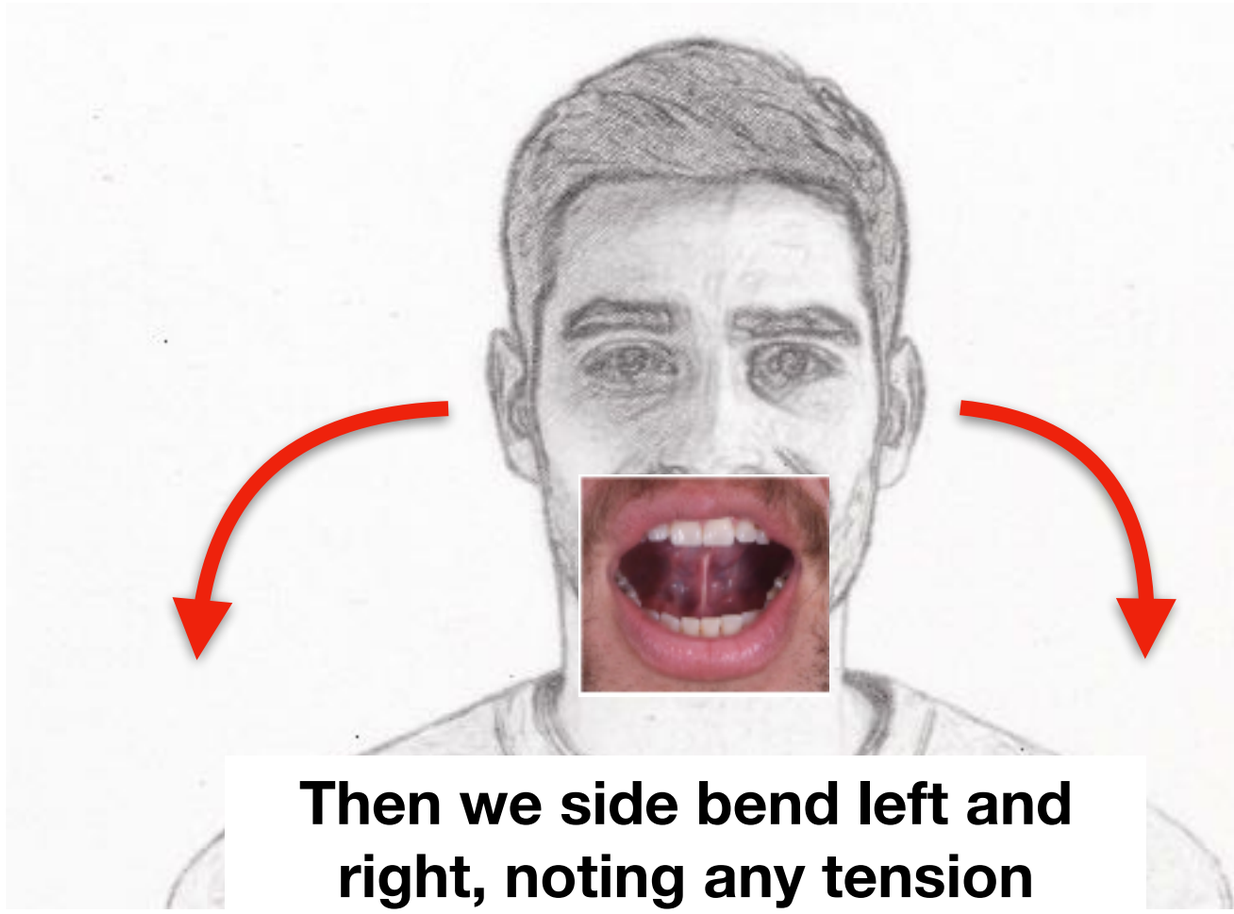

Then we side bend left and right, noting any tension

Treating the Hyoid/Tongue

- Now we stick the tongue out as far as it will comfortably go and hold it while we:

- Rotate slowly to the left and then rotate to the right, noting any tension or restriction.

- Then side bend our heads (ear toward shoulder) left and then right slowly, again noting any restriction or tension.

Then we stick out the tongue and hold it.



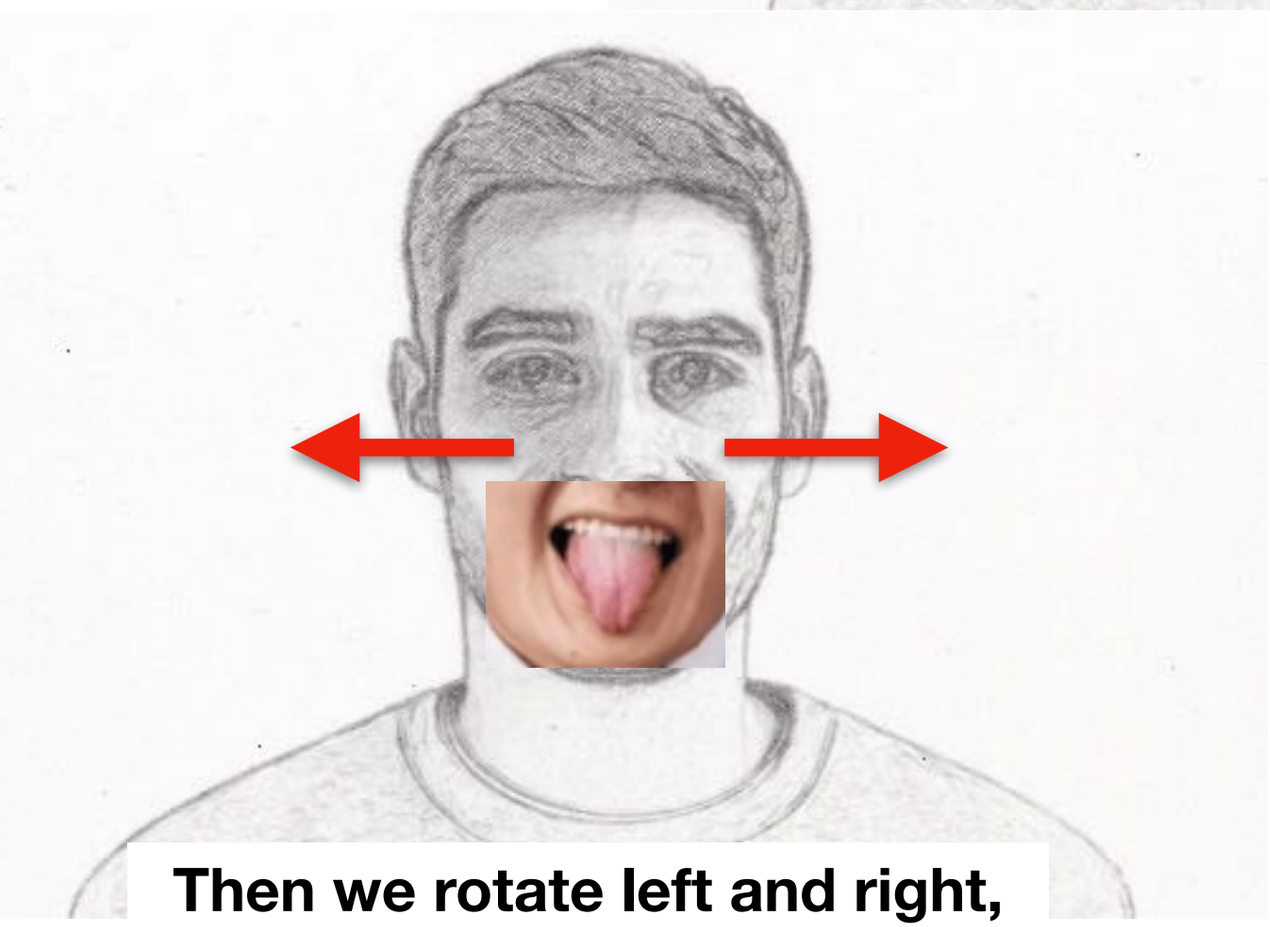

Then we rotate left and right, noting any tension

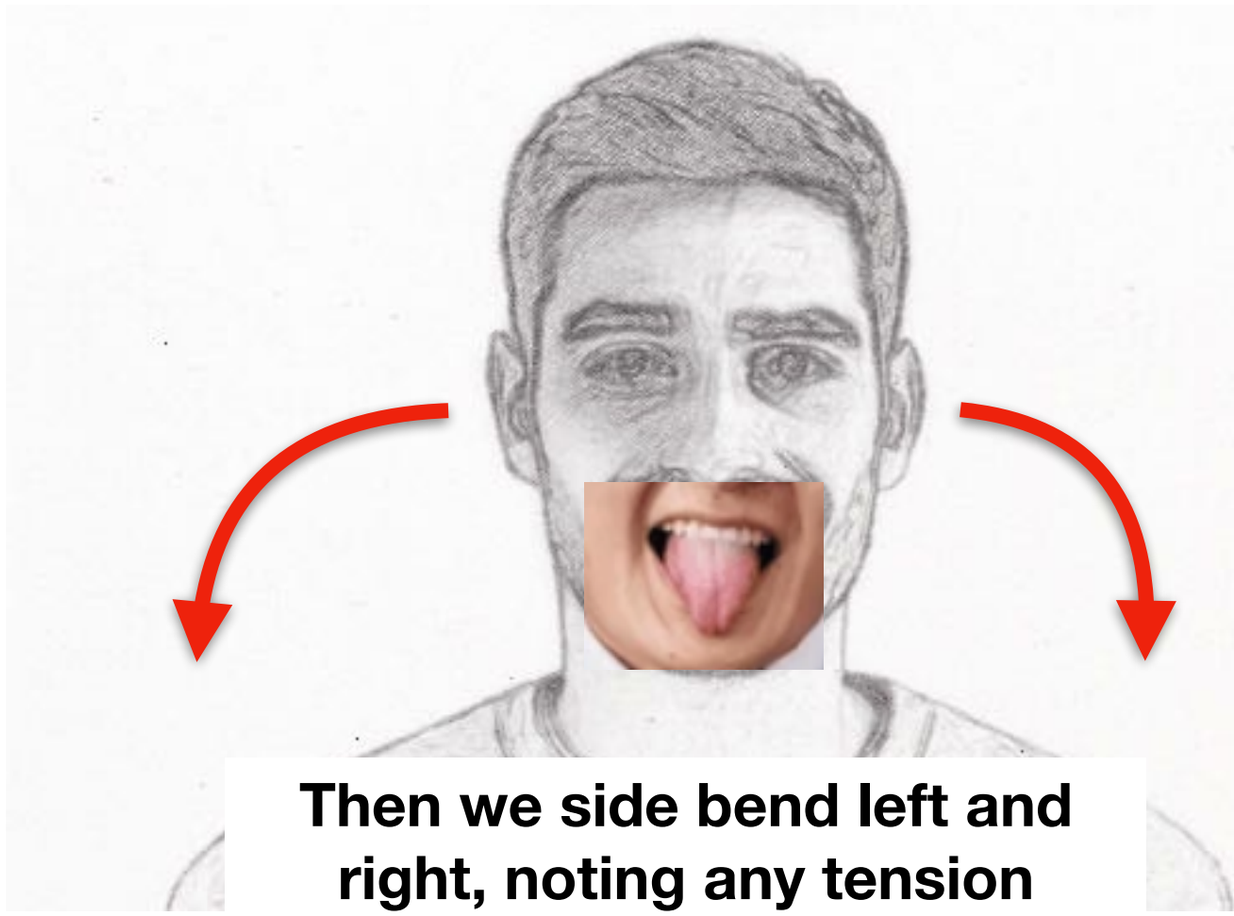

Then we side bend left and right, noting any tension

Treating the Hyoid/Tongue

- What did we just do?
- We tested to see if the muscles that attach to your hyoid move freely. We tested to see if the fascia attached to those muscles is restricted.
- Did you find tension? If so, how do we turn that into treatment?

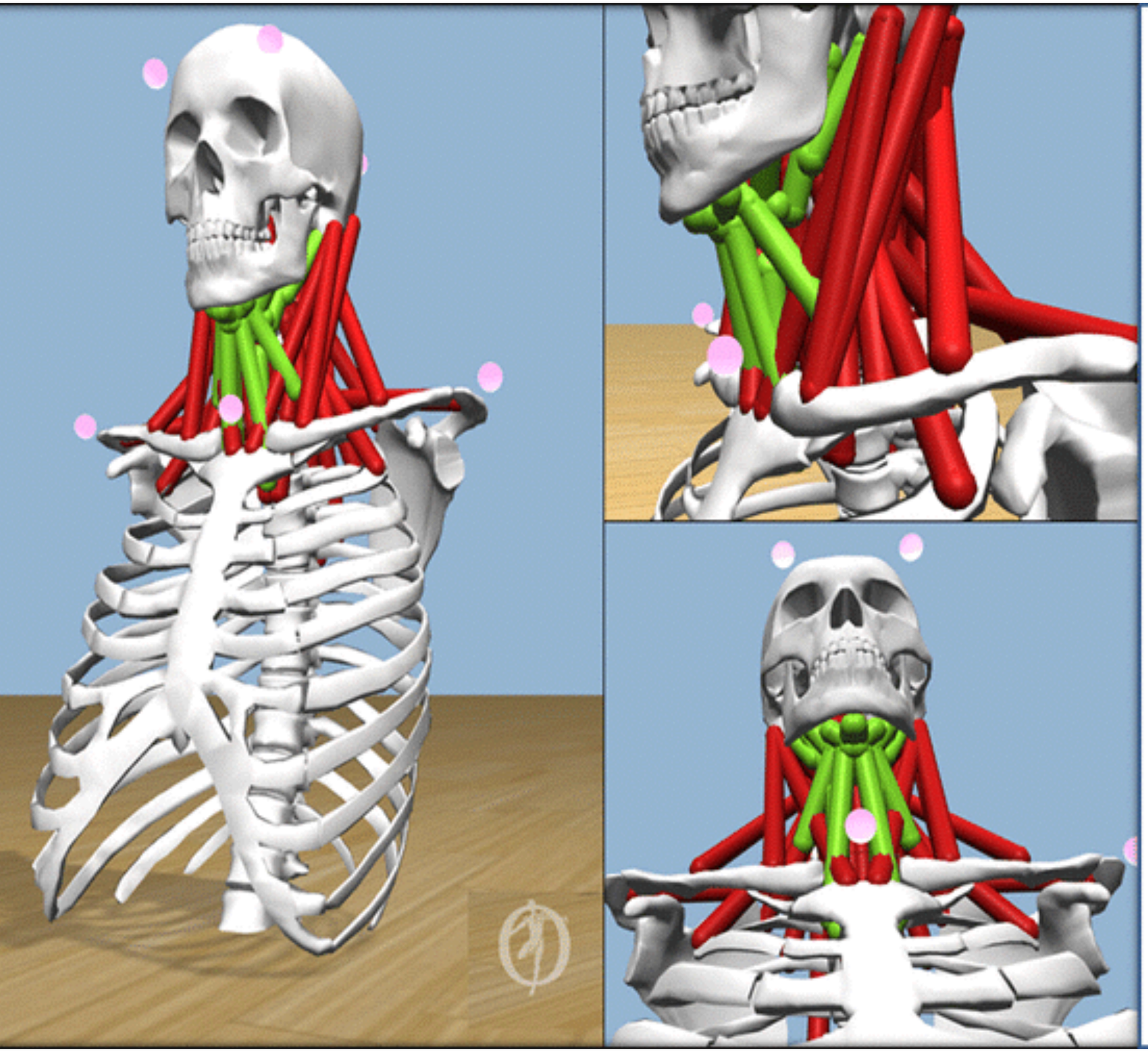

HYOID MUSCLES

Digastric
Geniohyoid
Mylohyoid
Stylohyoid
Sternohyoid
Thyrohyoid
Sternothyroid
Omohyoid etc.

https://www.researchgate.net/figure/Hyoid-Muscles-in-green-colour_fig3_339946441

Soup
(2nd Course)

Treating the Hyoid/Tongue

- For the next portion you will need a 4x4 gauze pad. I find the non-woven ones to work best (they stick to the tongue less).

- Fold the 4x4 into a manageable size, have the patient stick out their tongue to its maximum range and grab the tongue with the 4x4.

- Hold the tongue firmly and traction (anteriorly) till the beginning of discomfort for the patient.

Grip the tongue with a 4x4 gauze pad and pull forward

Treating the Hyoid/Tongue

- As we hold, the tongue will subtly move in four directions - up and left, up and right, down and left and down and right. It will do it in whatever order it needs to to release. Follow these motions as it releases.

- When this treatment is complete, the tongue will begin to retract.

- Release your grip and make certain all parts of the 4x4 come out with you (thus the preference for non-woven).

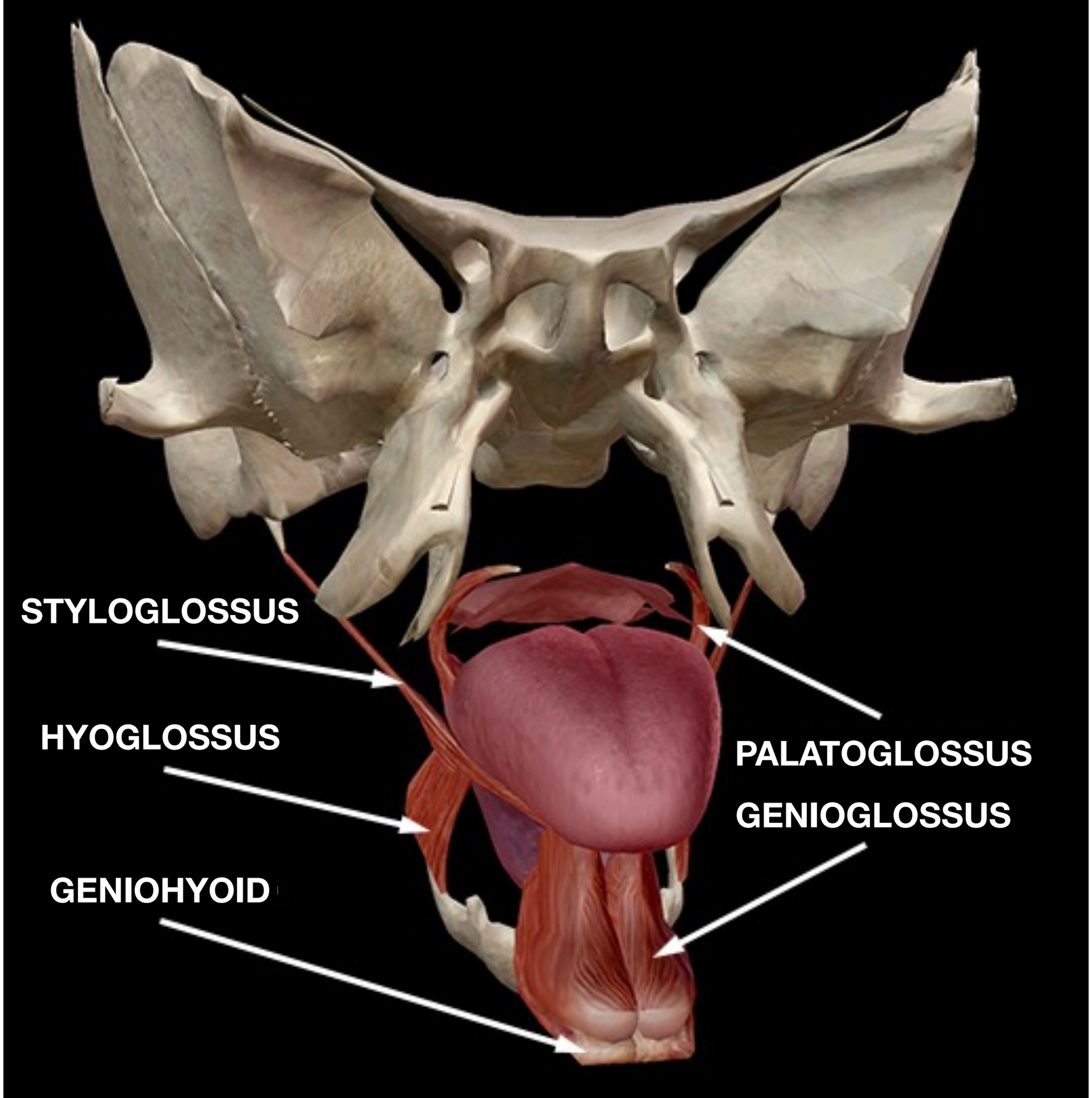
STYLOGLOSSUS
HYOGLOSSUS
GENIOHYOID
PALATOGLOSSUS
GENIOGLOSSUS

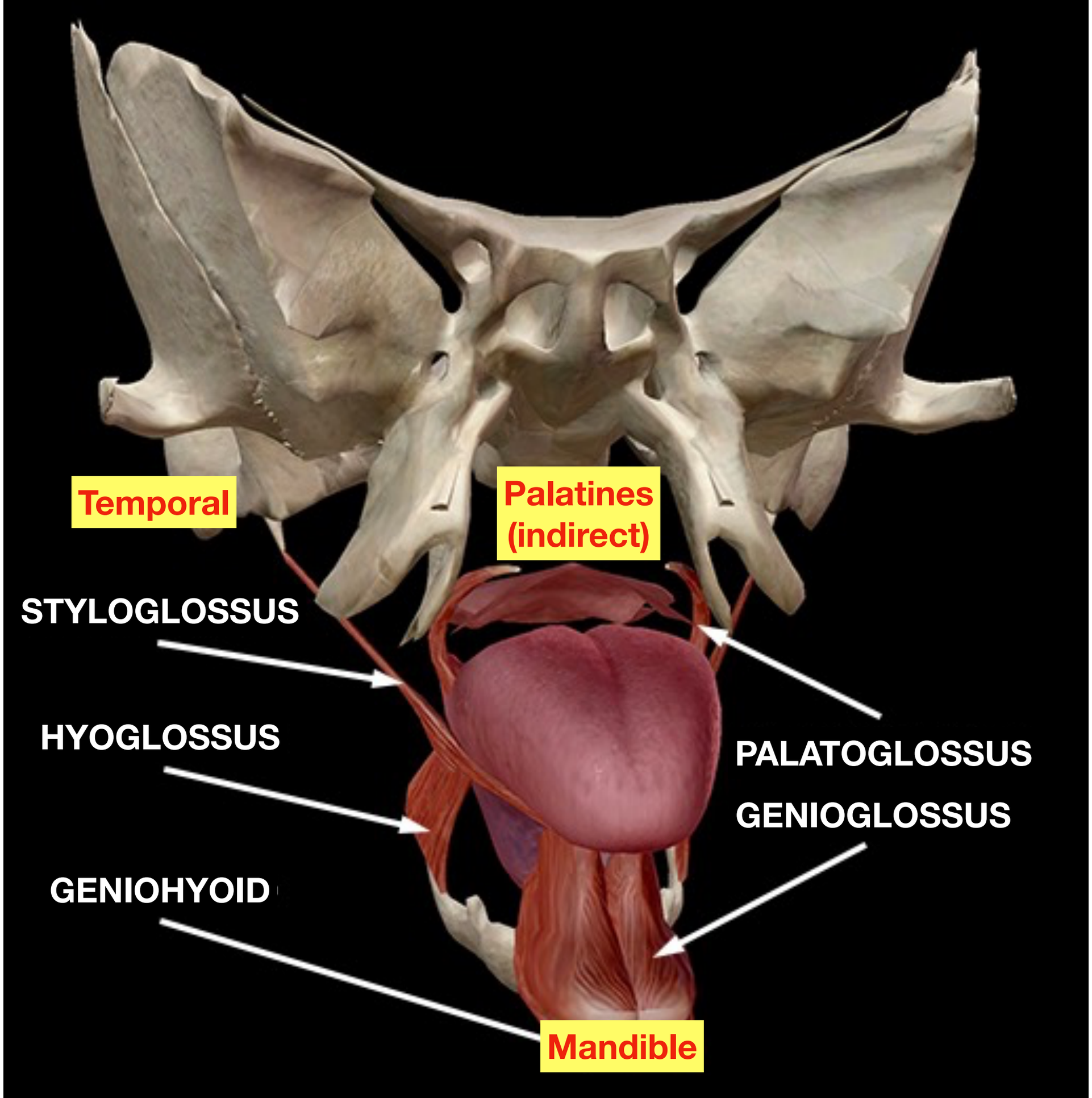
Temporal
Palatines
(indirect)
STYLOGLOSSUS
HYOGLOSSUS
GENIOHYOID
PALATOGLOSSUS
GENIOGLOSSUS
Mandible

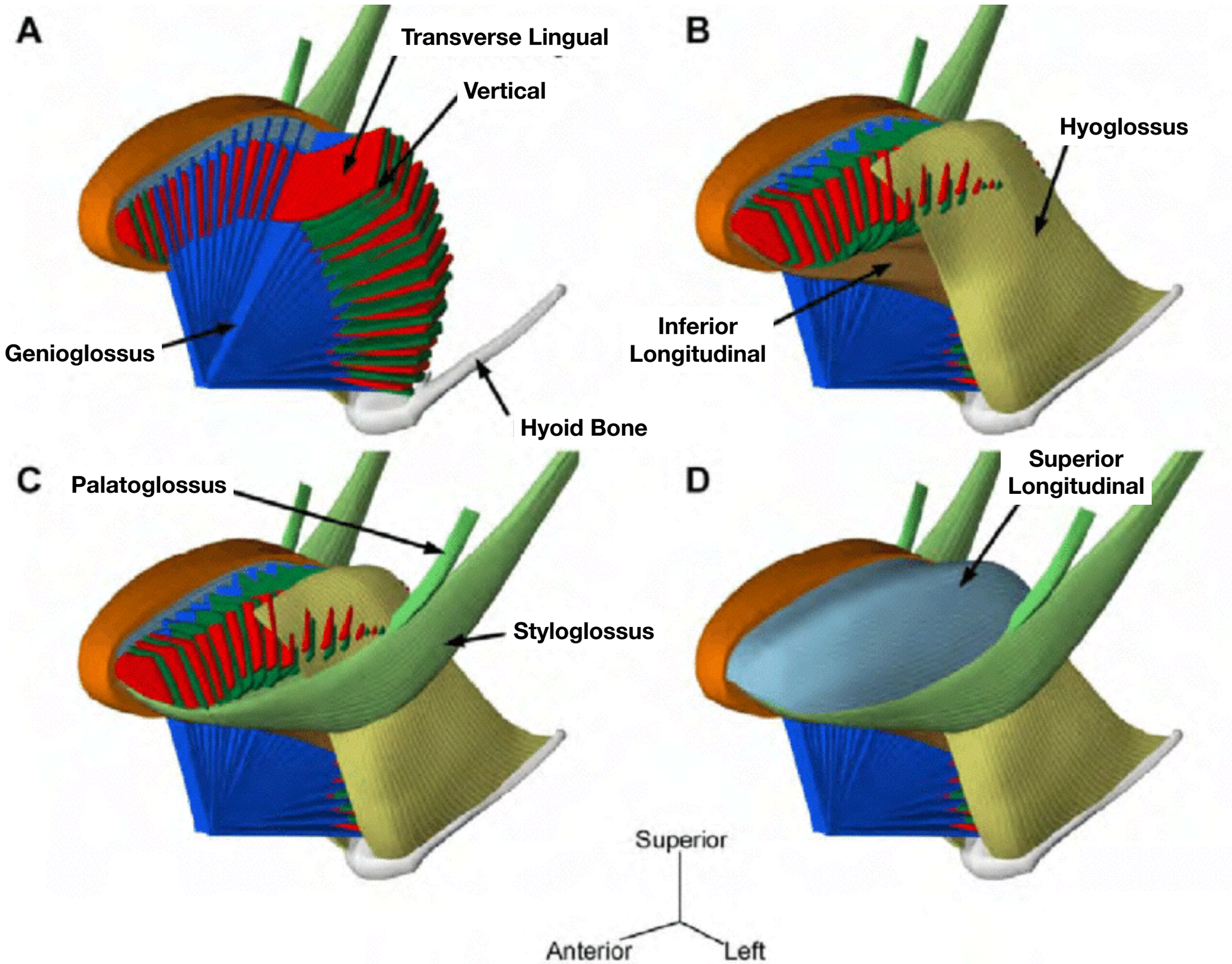

Notice how the fibers from the muscles move in different directions.

Treating the Hyoid/Tongue

- Advanced…
- Do exactly the same treatment while stabilizing the lateral parts (the transverse process) of C2.
- This will give you a bigger impact on the tongue since movement of the tongue also moves C2.

Mains
(3rd Course)

Hyoid Anatomy

- The hyoid bone is very important in the body.
- It is the only free floating bone in the entire skeletal system.
- It is the only bone not impacted by a retained Moro reflex.
- Because it is free floating, it is profoundly impacted by abnormal tension in the muscles and fascia.

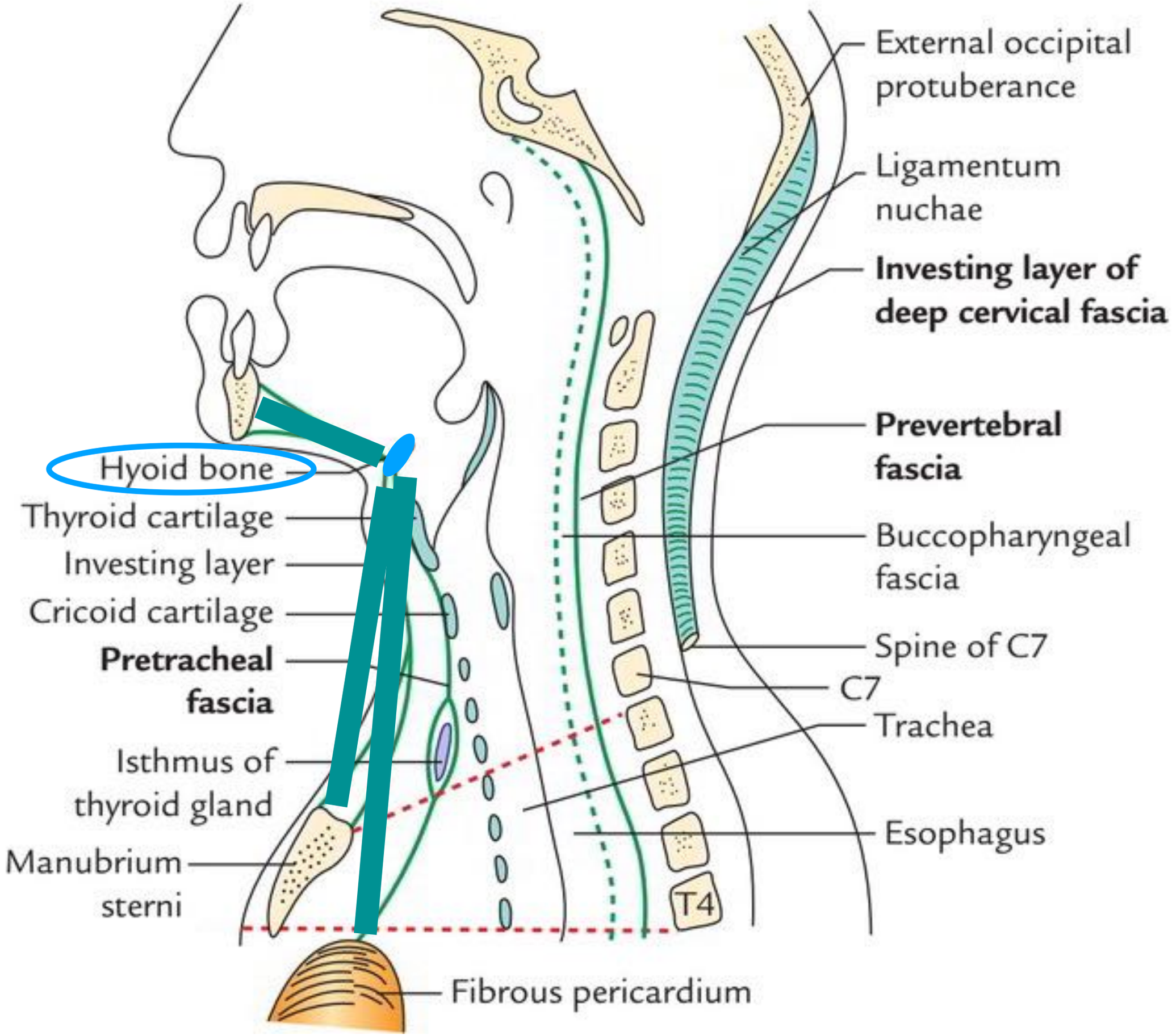
External occipital protuberance
Ligamentum nuchae
Investing layer of deep cervical fascia
Prevertebral fascia
Buccopharyngeal fascia
Spine of C7
C7
Trachea
Esophagus
T4
Hyoid bone
Thyroid cartilage
Investing layer
Cricoid cartilage
Pretracheal fascia
Isthmus of thyroid gland
Manubrium sterni
Fibrous pericardium

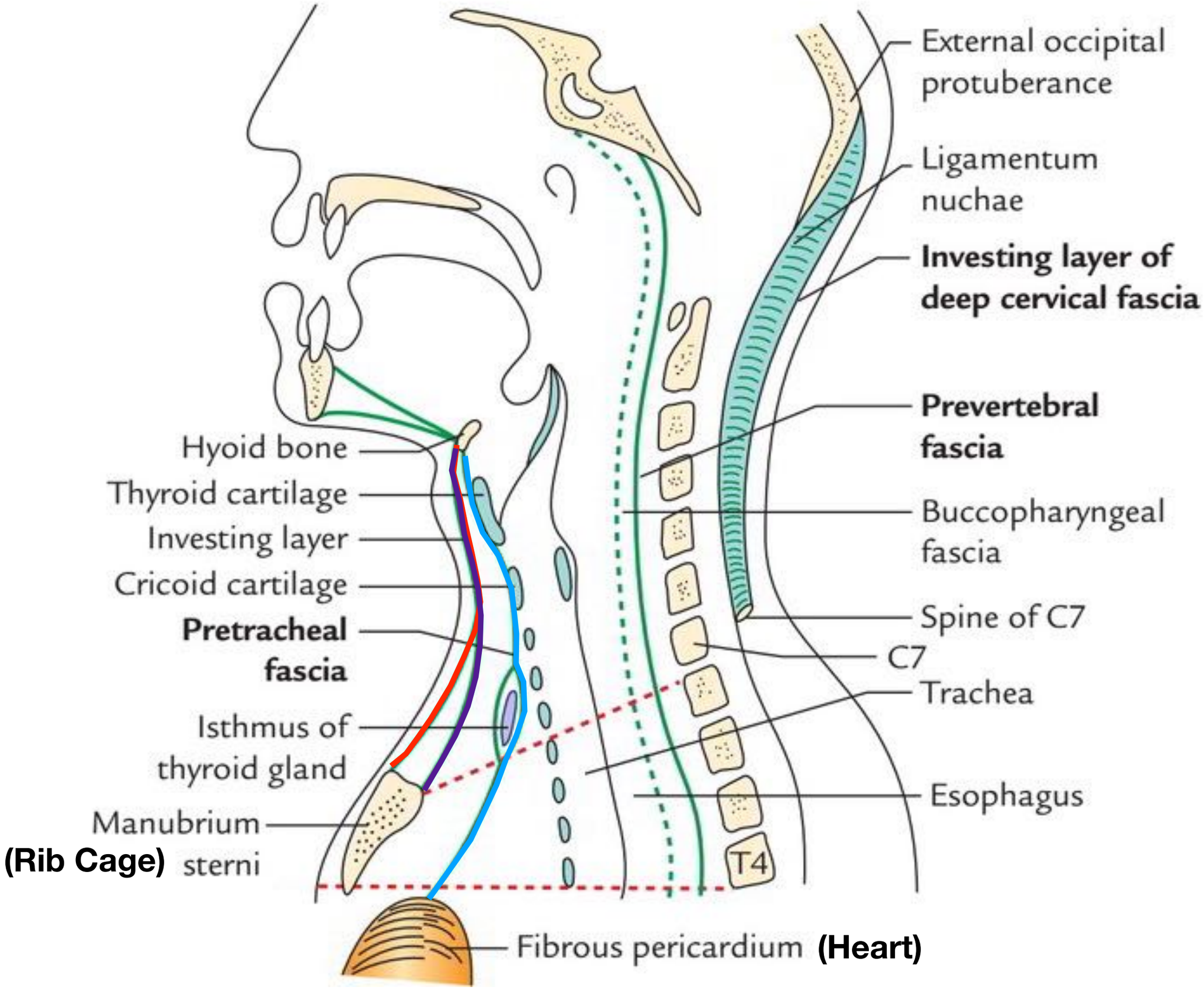
External occipital protuberance
Ligamentum nuchae
Investing layer of deep cervical fascia
Prevertebral fascia
Buccopharyngeal fascia
Spine of C7
C7
Trachea
Esophagus
T4
Hyoid bone
Thyroid cartilage
Investing layer
Cricoid cartilage
Pretracheal fascia
Isthmus of thyroid gland
Manubrium sterni
(Rib Cage)
Fibrous pericardium (Heart)

If we place an appliance that proclines the teeth (and thus changes the tension on the mandible), it could also place increased tension on this fascia.

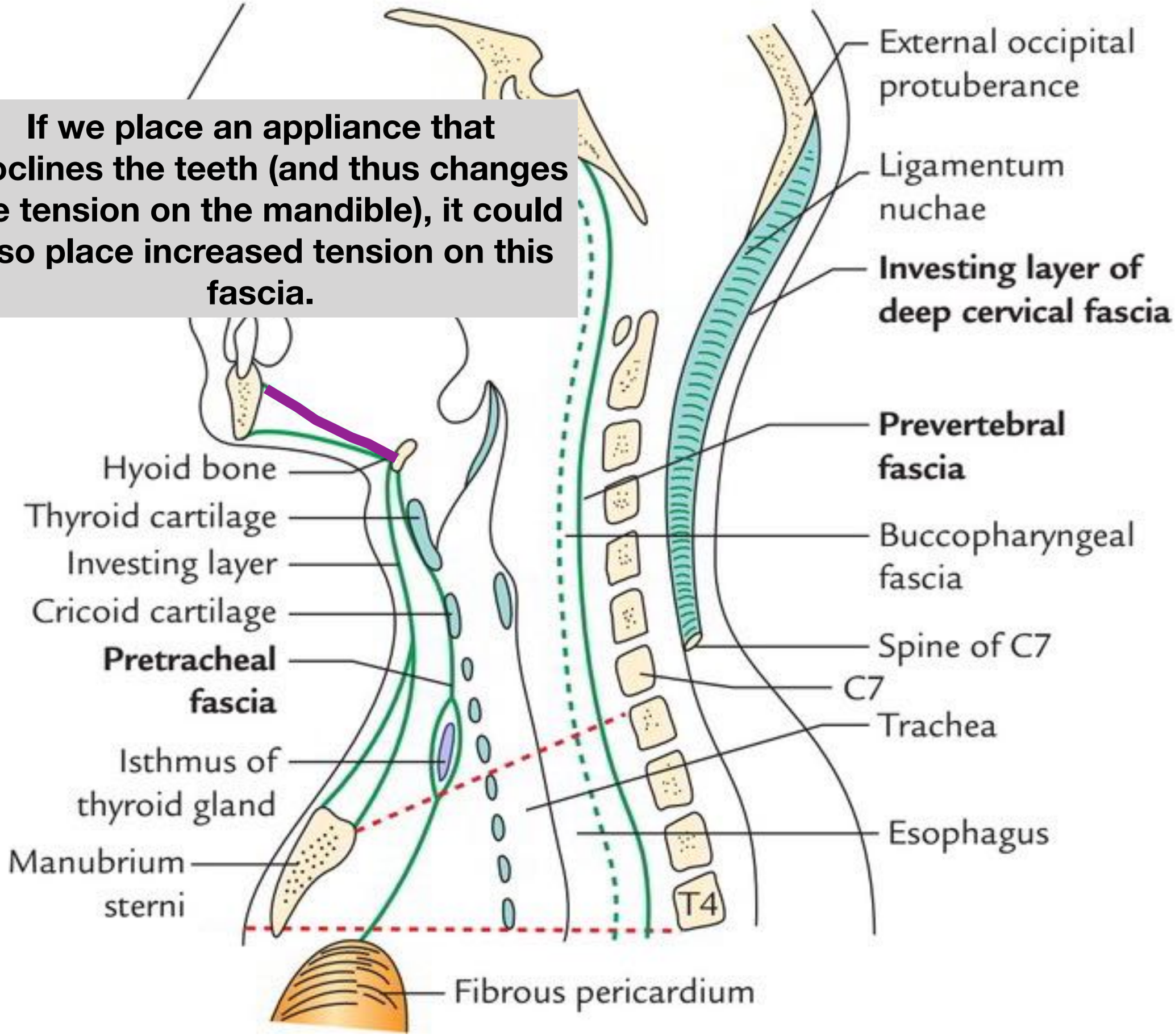

The investing layer of fascia surrounds the entire neck

The prevertebral layer surrounds the muscles of the neck

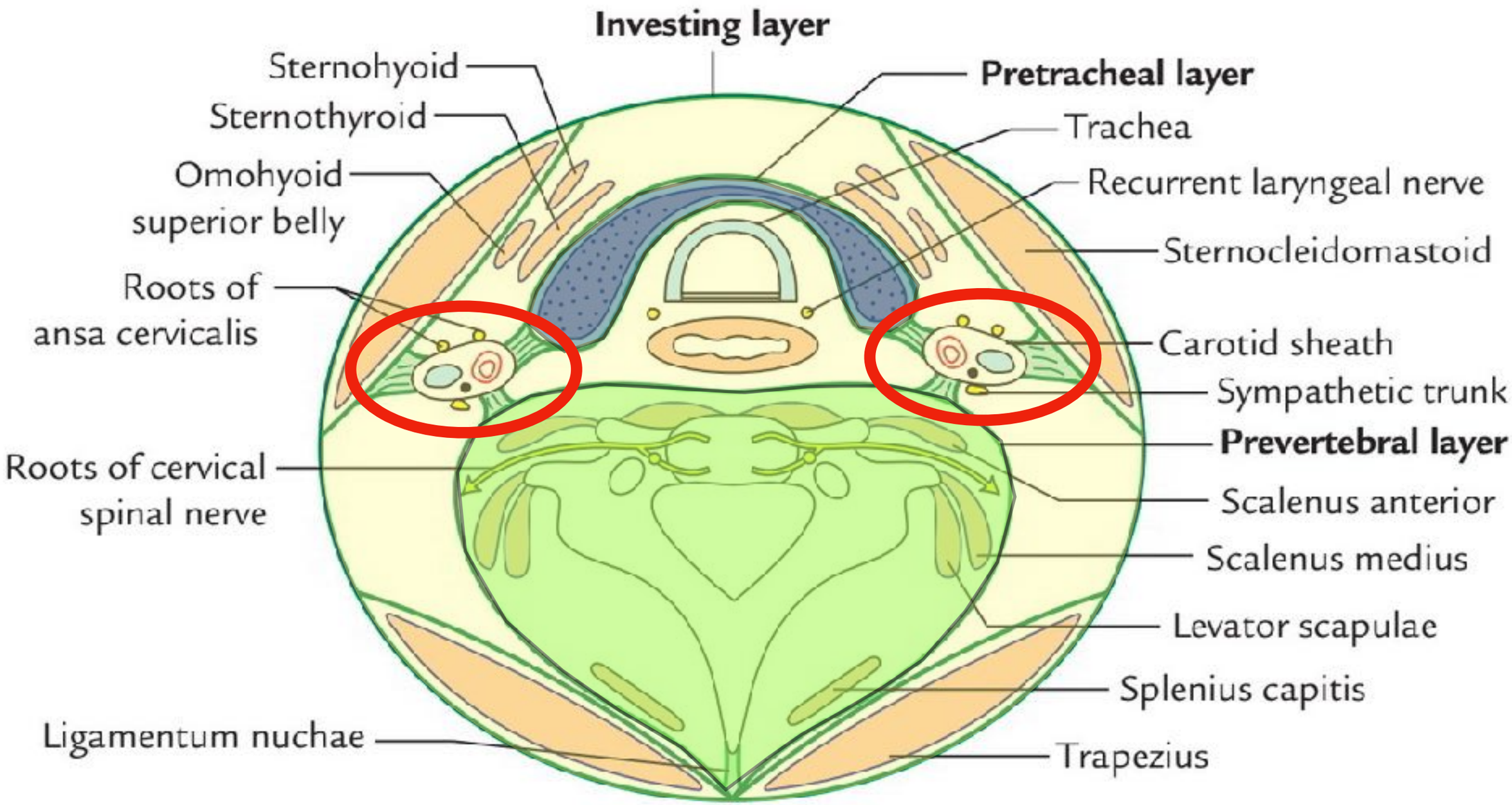

The pretracheal layer lies in front of the airway

Notice that if the connective tissue that surrounds the carotid sheath is too tight, the airway can become compressed.

The glands of the neck are surrounded by fascia

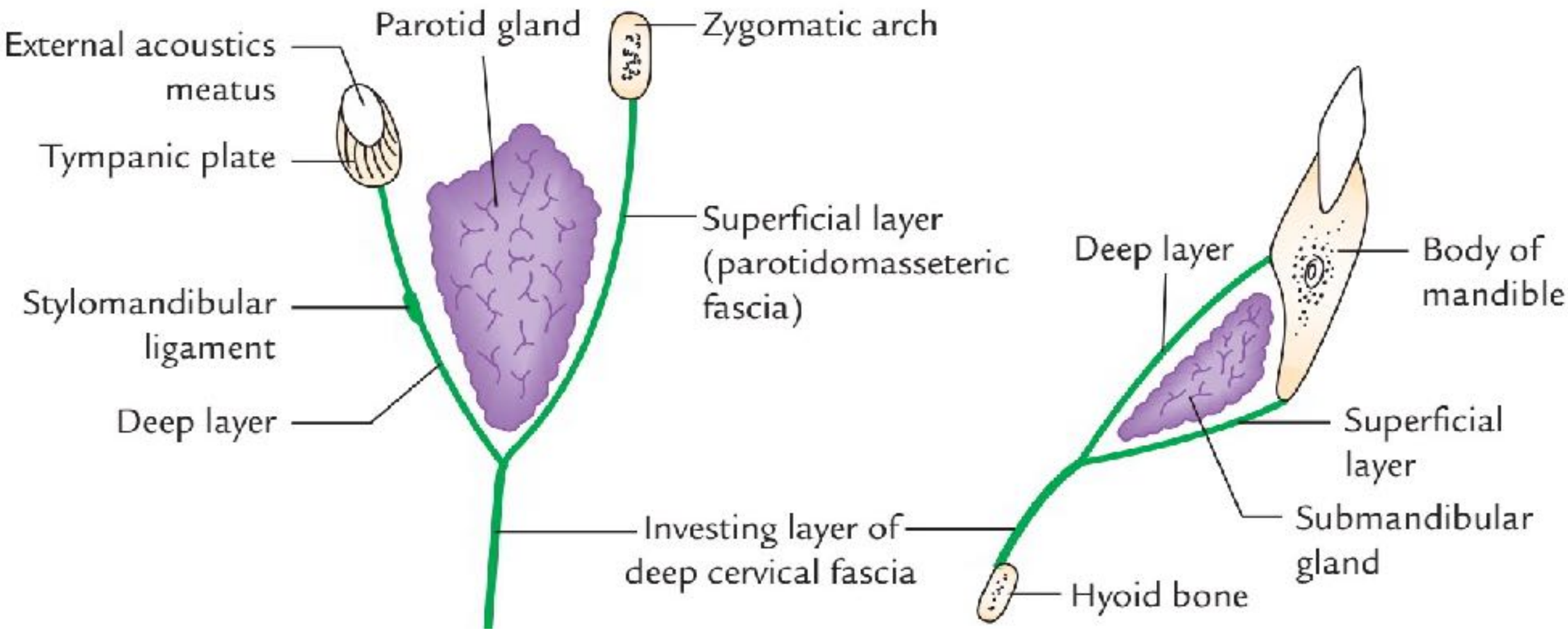

So, any glandular issues will directly connect to a fascial issue

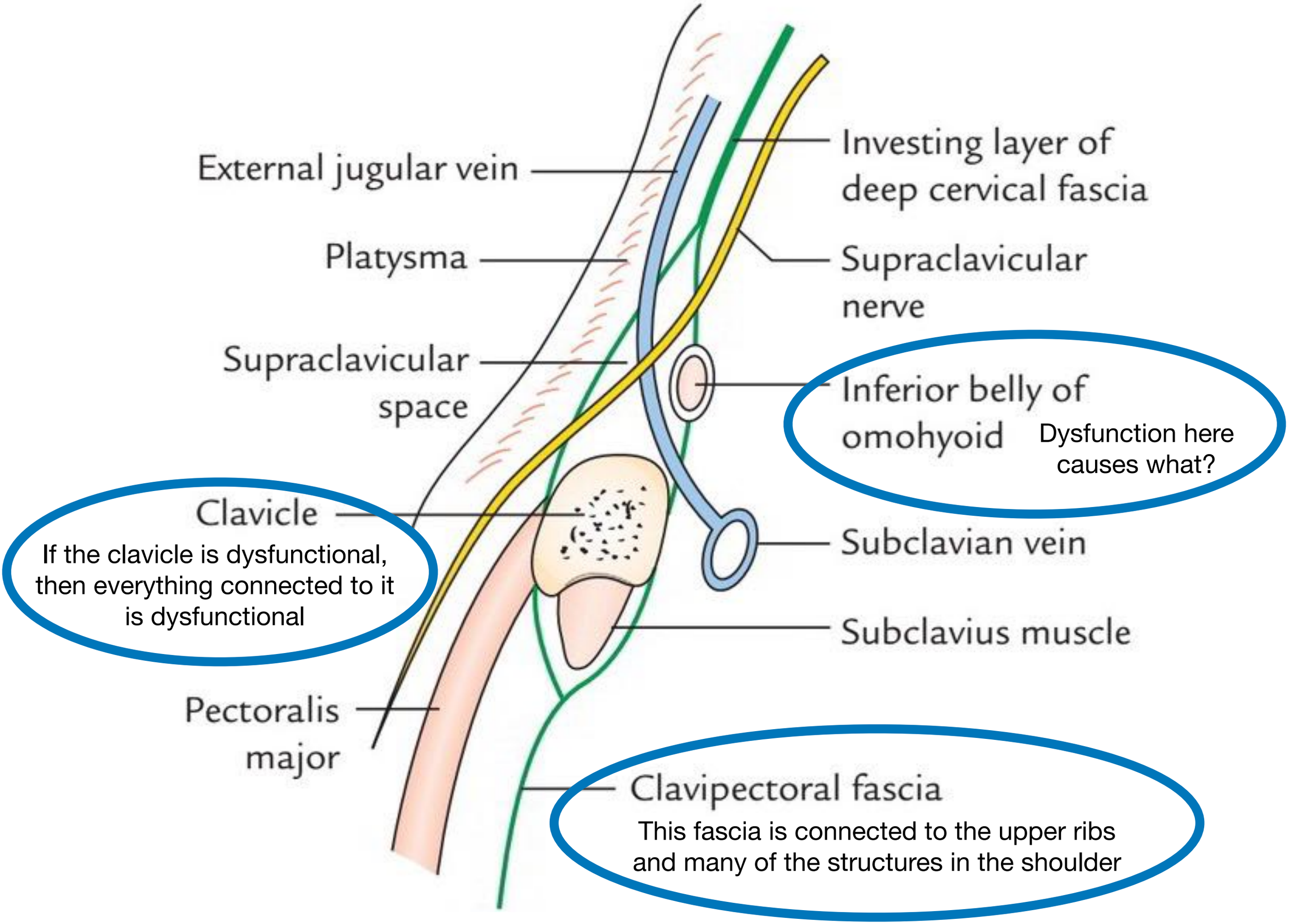
External jugular vein
Platysma
Supraclavicular space
Clavicle
If the clavicle is dysfunctional, then everything connected to it is dysfunctional
Pectoralis major
Investing layer of deep cervical fascia
Supraclavicular nerve
Inferior belly of omohyoid
Dysfunction here causes what?
Subclavian vein
Subclavius muscle
Clavipectoral fascia
This fascia is connected to the upper ribs and many of the structures in the shoulder

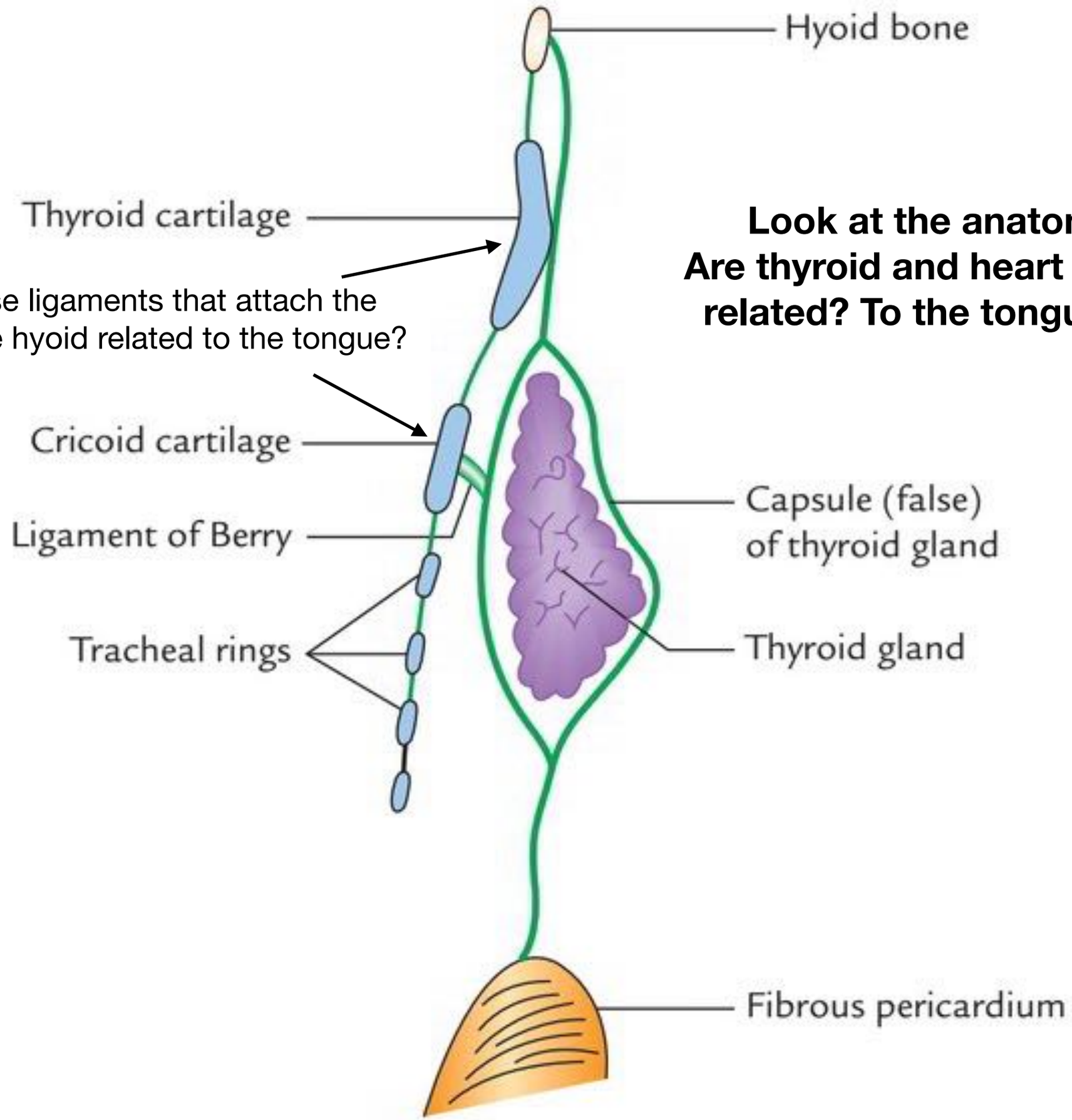

And are these ligaments that attach the cartilage to the hyoid related to the tongue?

Look at the anatomy.
Are thyroid and heart issues related? To the tongue???

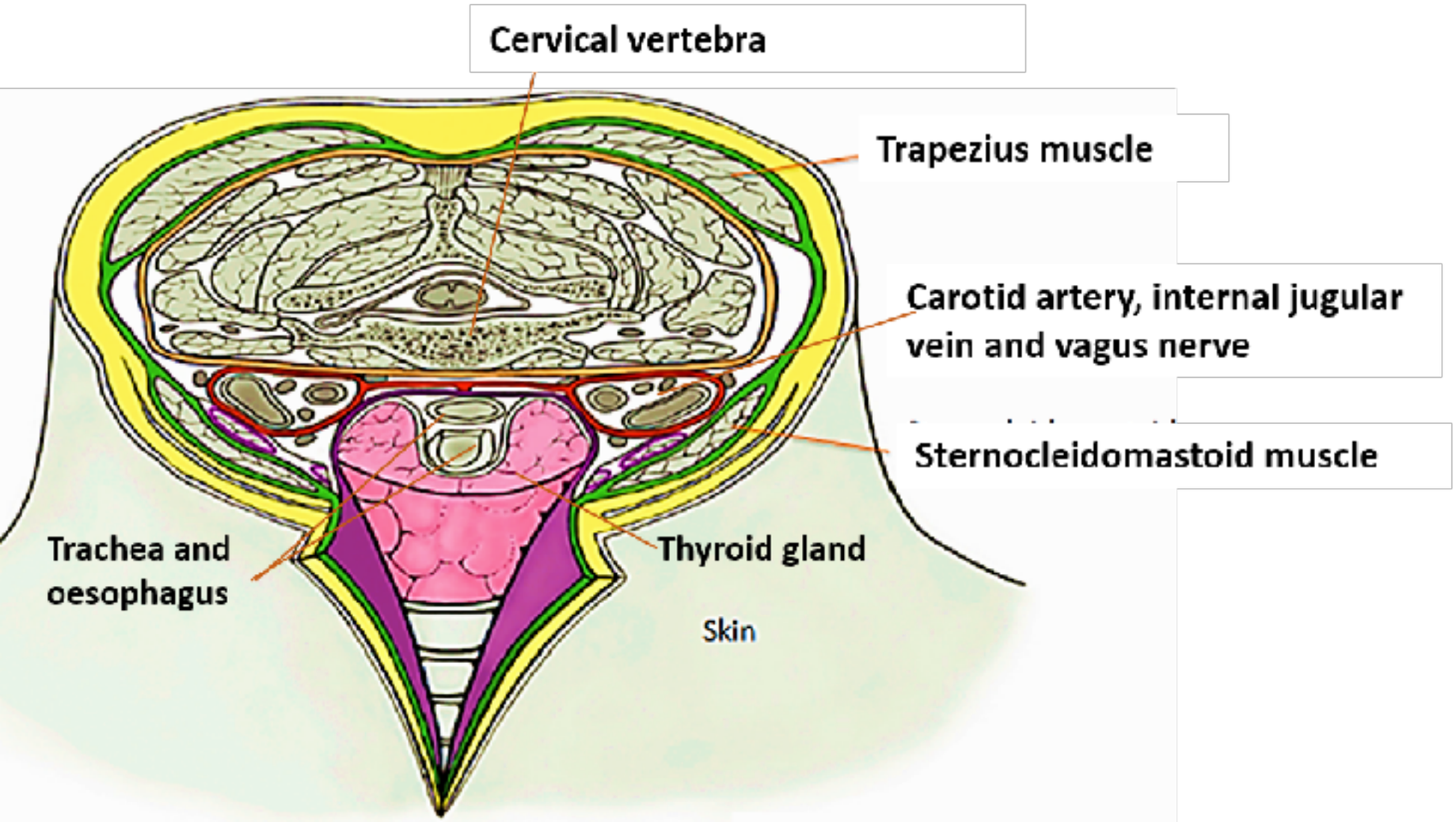

Layers of deep cervical fascia

- Investing layer
- Prevertebral layer
- Carotid sheath
- Pretracheal layer

Treatments for the anterior cervical fascia

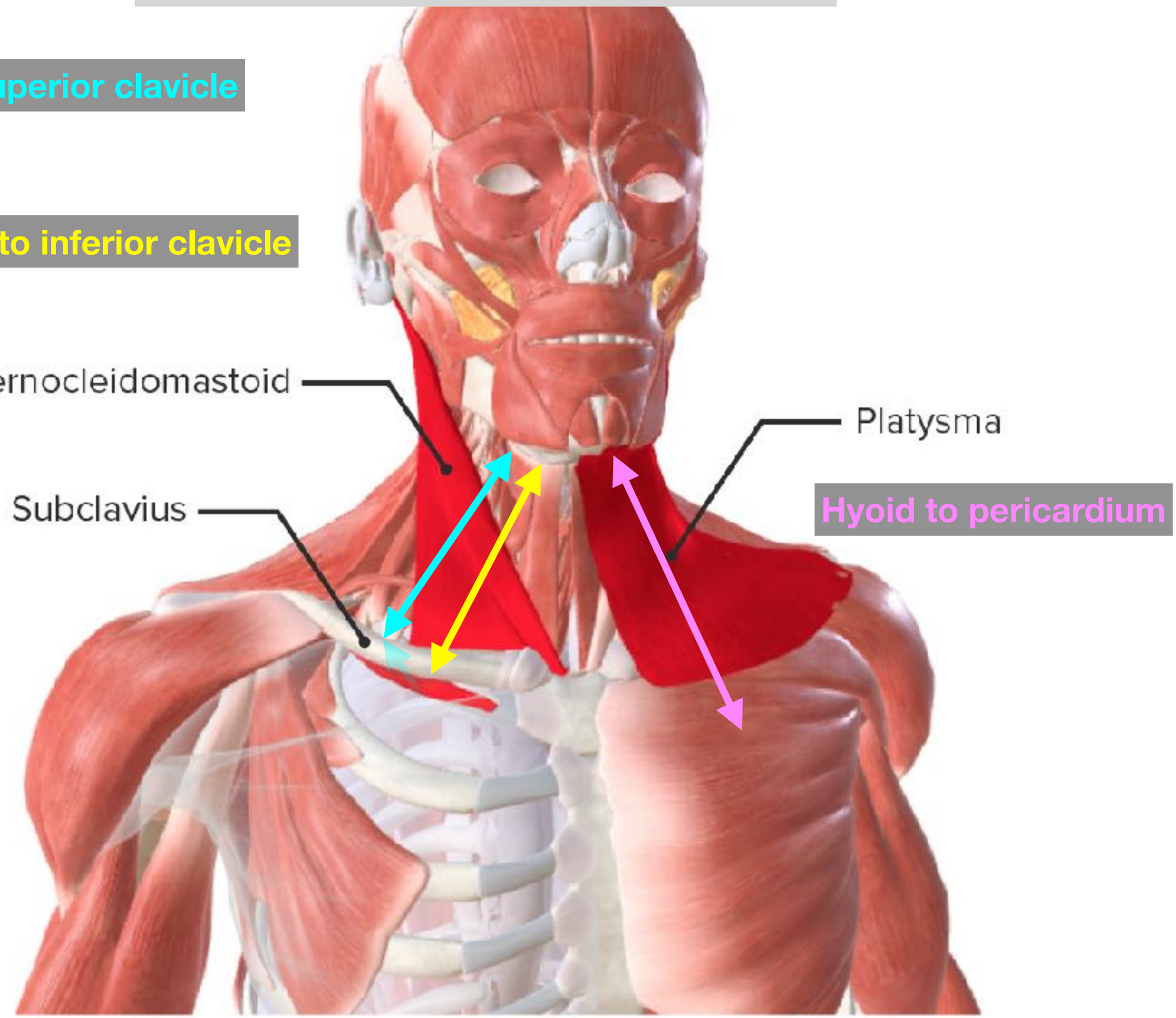

Dessert
(4rd Course)

Treating the Hyoid/Tongue

- For the last portion of our treatment, we will be working on integrating the tongue with the body. This is a precise treatment…
- While you can do this treatment while seated, it is most comfortable on the patient with them side lying.

Treating the Hyoid/Tongue

- We will start with a 4x4 wrapped around your index finger. Wrap it tightly and make certain there are no dangly bits.
- Then the patient opens wide and sticks their tongue out as far as they can.
- You place your finger on the tongue about mid-way back and push down (caudal) and anterior (to get it out of the airway).

Treating the Hyoid/Tongue

- Then bring the tongue forward (anterior) and down (inferior/caudal) and hold it there with one hand (like the motion of a tongue depressor).
- The other hand goes on the diaphragm or hip bone.
- This gives you in your hand the biggest players in the deep anterior fascial line.
- Hold and let the body unwind.
- This can be a very profound treatment.

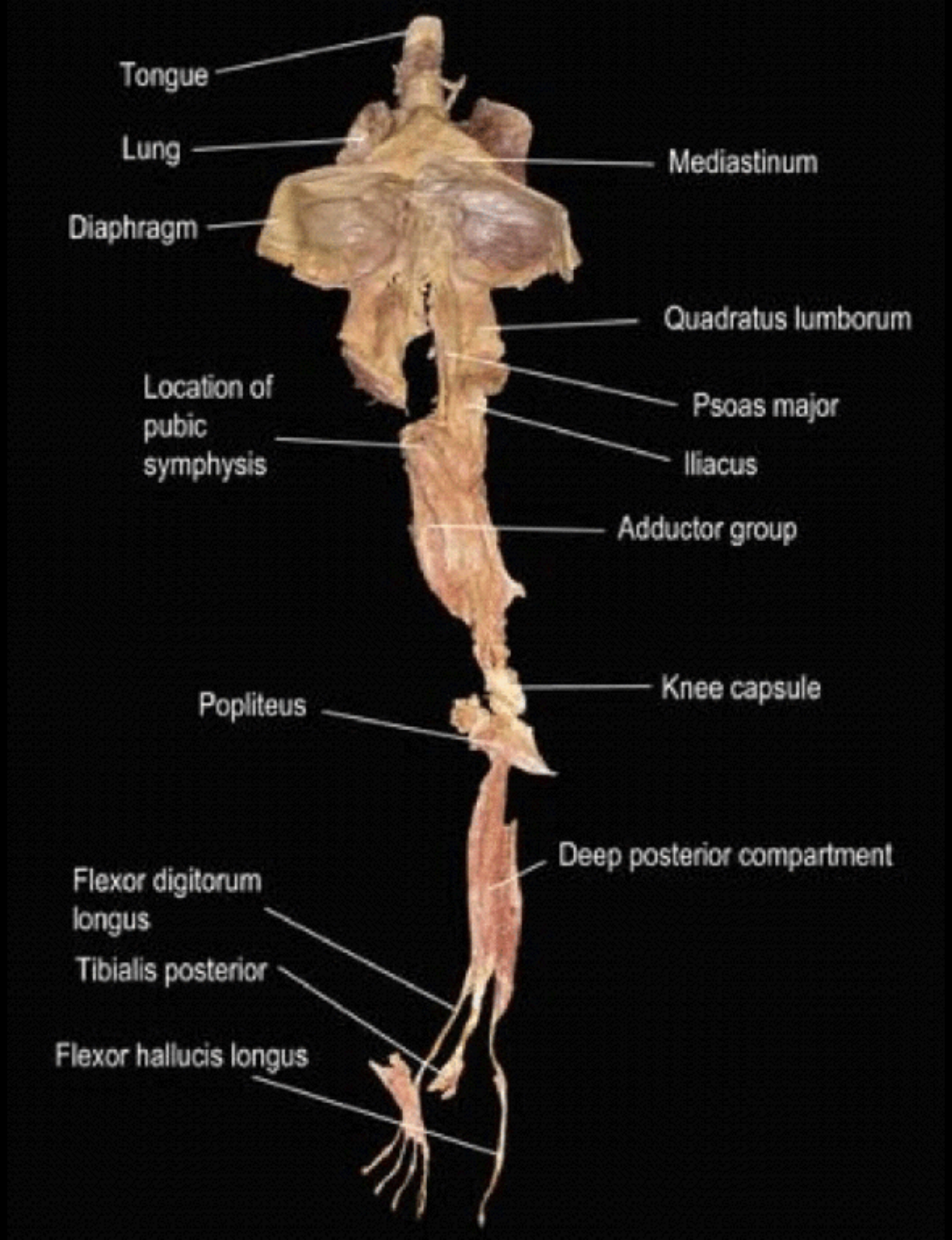
Tongue
Lung
Diaphragm
Mediastinum
Quadratus lumborum
Location of pubic symphysis
Psoas major
Iliacus
Adductor group
Knee capsule
Popliteus
Deep posterior compartment
Flexor digitorum longus
Tibialis posterior
Flexor hallucis longus

Push Down

Then bring forward (anterior) to move the tongue out of the airway

Coffee
(5th Course)

When things don’t work as planned

- What happens when the exercises you give don’t last?
- How do you start the process of determining what’s going on?
- This test is one way to determine if the patient is struggling with stress/adrenal issues. Although more likely to be found in adults, this can be a problem in children too.

Use your cell phone flashlight to transilluminate the eye. Shine the light at a 90 degree angle to the eye and observe the pupil.



When things don’t work as planned

- If the adrenals are healthy, the pupil will shrink (constrict) and stay that way.

- If the adrenals are struggling, the pupil will shrink (constrict) and then relax (dilate) and may go back and forth, constricting and dilating. If this happens, your muscle exercises may not give consistent results.

Why this matters

- If you perform a tongue tie or TOT release, you should NOT do that on a patient who is exhibiting adrenal fatigue. Their body is struggling too much to achieve a good, consistent post-surgical outcome.

- They would need to see a (perhaps a functional medicine) physician to get their issues addressed prior to their surgery.

For Our Next Segment,
We Will look At
Embryology

Embryology

- Embryology is a look at where tissues originate in the body and how they develop into adulthood from the embryo.
- It can tell us a great deal about the symptoms a patient presents with.

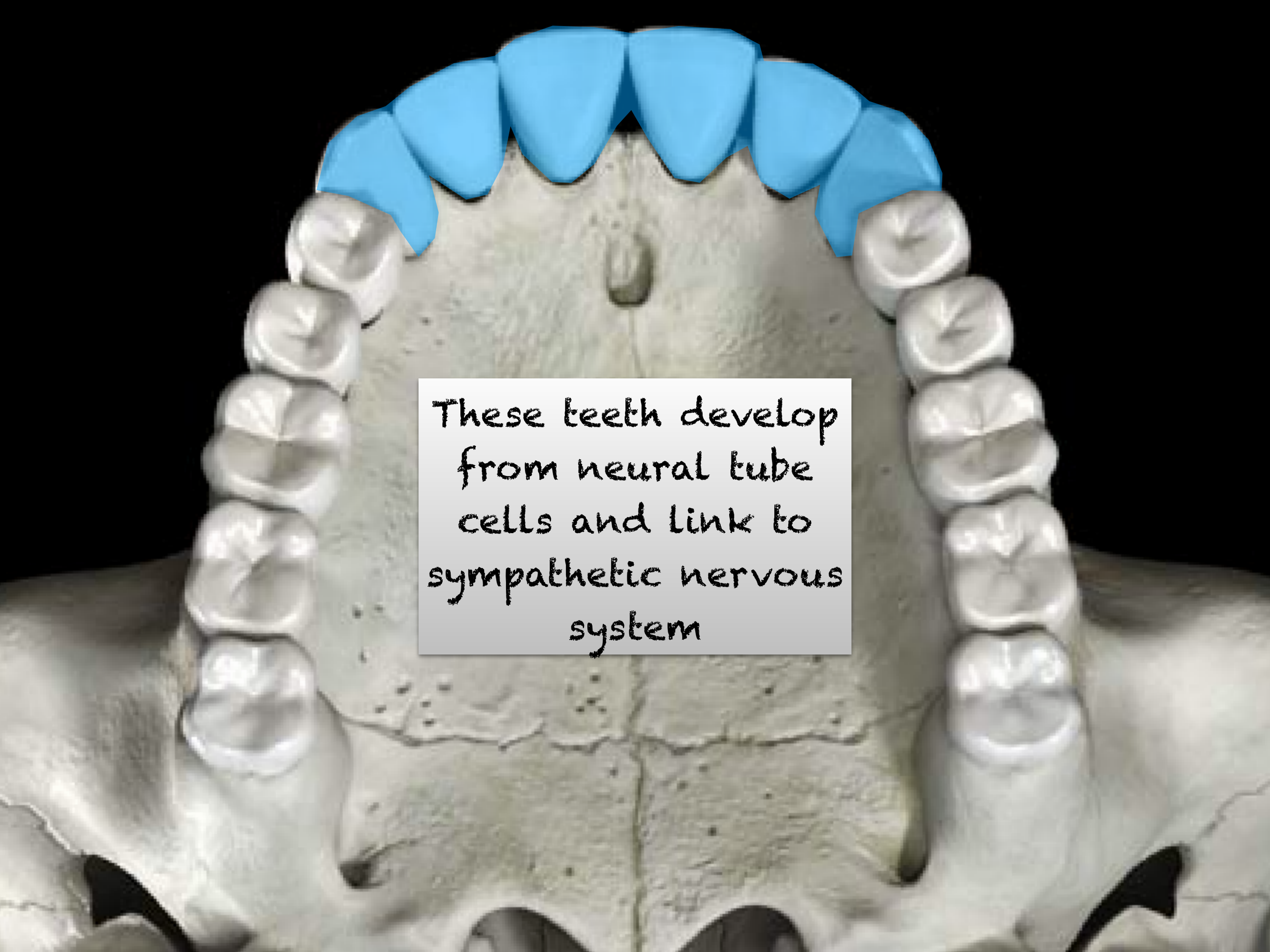

These teeth develop from neural tube cells and link to sympathetic nervous system

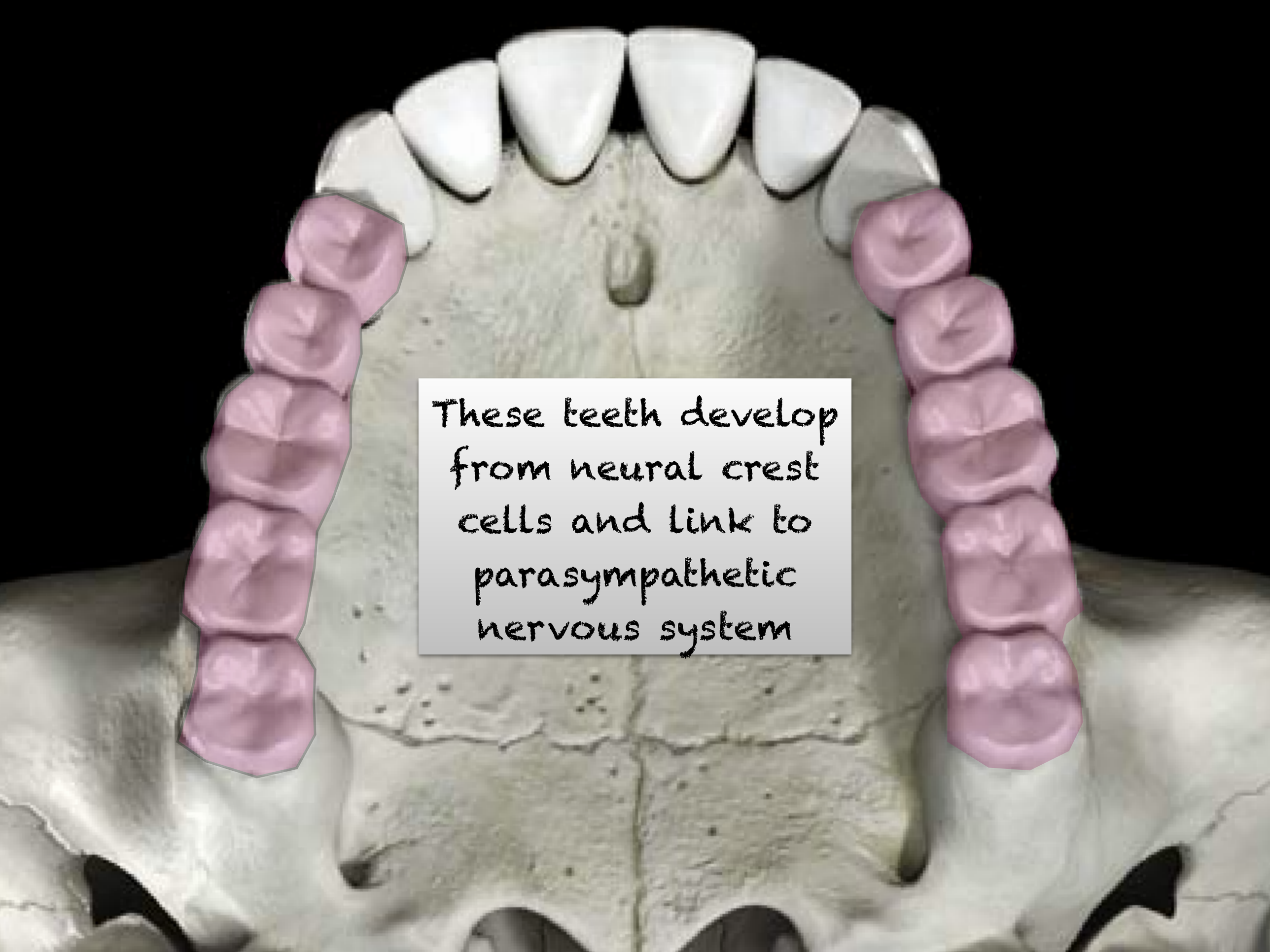
These teeth develop
from neural crest
cells and link to
parasympathetic
nervous system

Then We Will Add In The Chinese Medicine Tongue Map

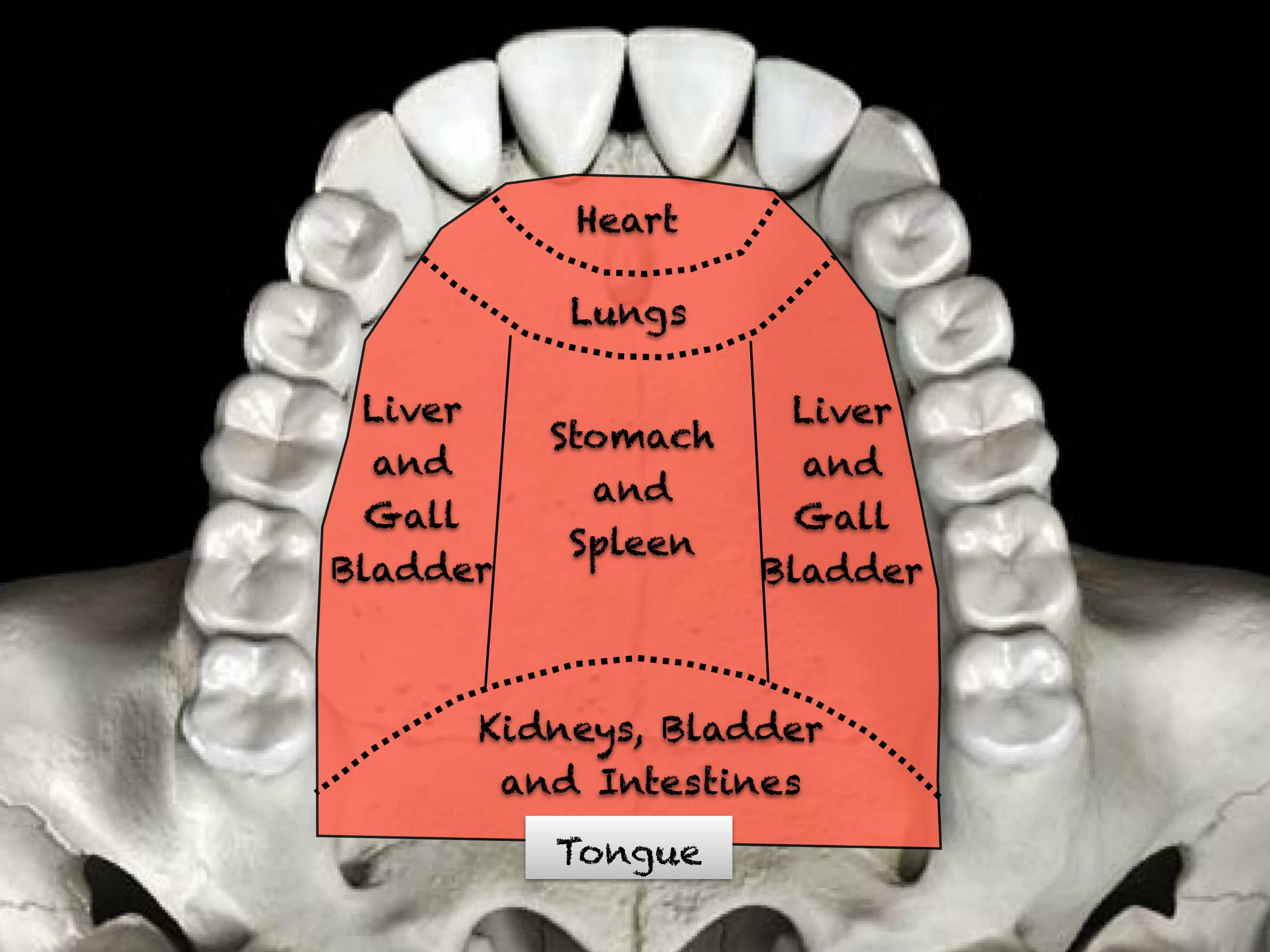
Heart
Lungs
Liver and Gall Bladder
Stomach and Spleen
Liver and Gall Bladder
Kidneys, Bladder and Intestines
Tongue

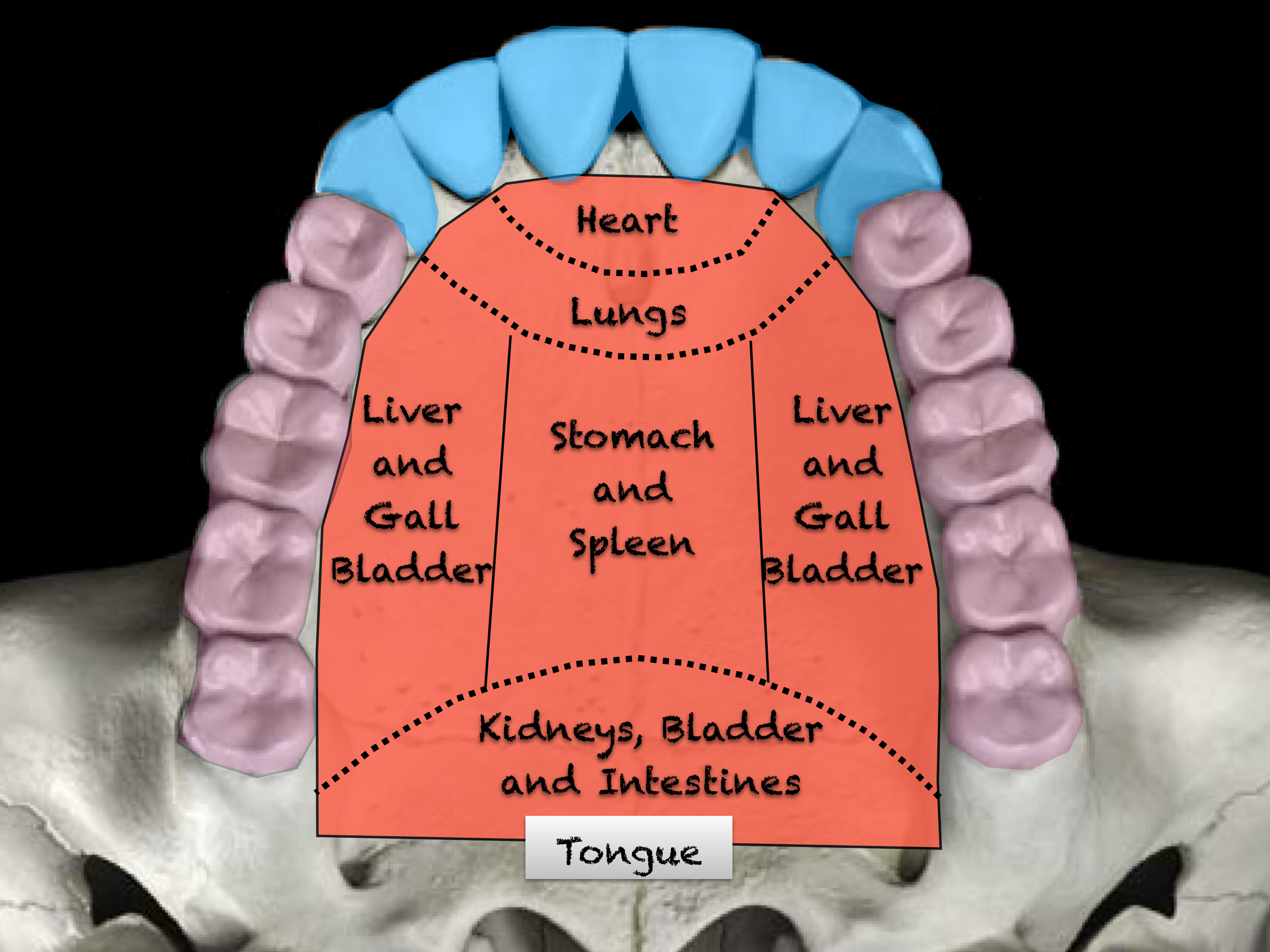
Heart
Lungs
Liver and Gall Bladder
Stomach and Spleen
Liver and Gall Bladder
Kidneys, Bladder and Intestines
Tongue

Chinese Medicine Tongue Diagnosis

by @hayley_stobbs

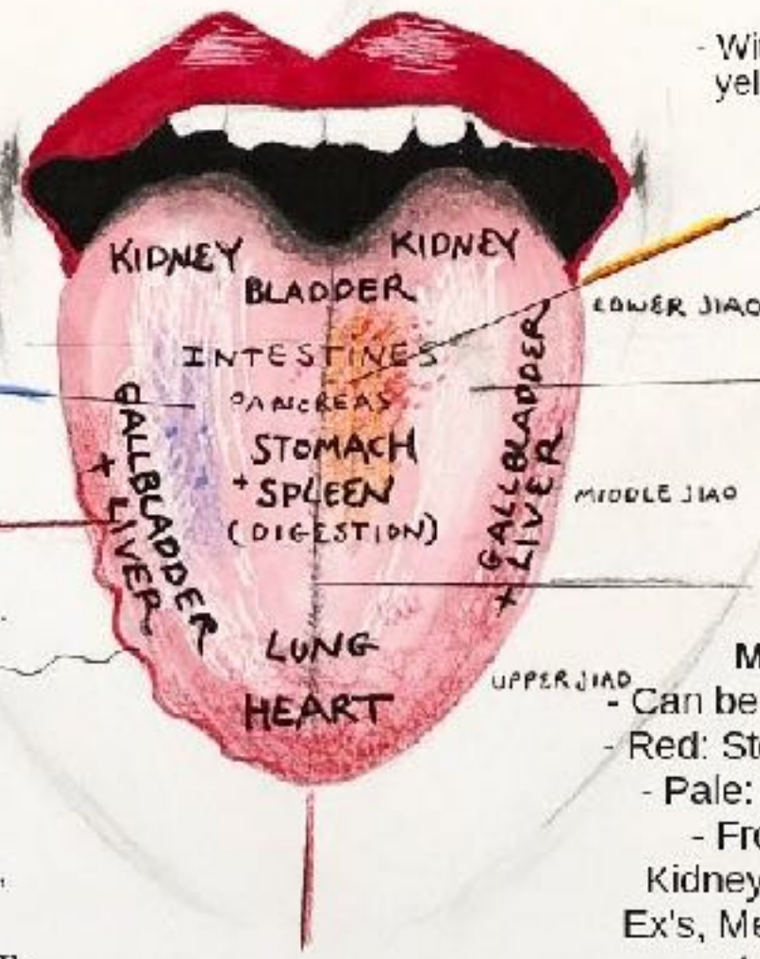

Red:
- Heat (too much yang or too little yin)
- Prickles: usually on tip: heat
- Geographic: yin deficiency
- With yellow coat: damp-heat (greasy yellow) or heat with pathogen, Ex's, skin disorders, bronchitis
- With no coat: yin deficiency

Purple:
- Blood stasis: Ex's, blood circulation disorder, sharp pain.
- Dusky purple: Liver qi stagnation or Internal cold.
- Blue: Severe internal cold, blood stasis

Pale:
- Blood deficiency, Ex. anemia, dizziness, absorption imbalance
- Internal cold
- Thick white pale coat: cold pathogen such as cold virus, food retention
- Greasy (mucousy): damp, phlegm, food retention

Liver Imbalance
- Red sides (often raised): Qi stagnation: stress, emotional imbalance, depression, anger, migraines, PMS, dull pain.
- Pale sides: Liver blood deficiency.

Midline Crack:
- Can be constitutional/normal
- Red: Stomach yin deficiency
- Pale: Qi/blood deficiency
- From back to front: Kidney heart disharmony: Ex's, Menopause, insomnia, trauma, panic, congenital heart disorder.
- Horizontal cracks: yin deficiency

Scalloped:
- Dampness: Ex's, water retention, metabolic disorders such as hypothyroidism, diabetes, dwelling and ruminating, achey pain.
- Qi deficiency: Ex's, fatigue, shortness of breath, overthinking and worrying.

Heart Heat (red tip):
- Chronic stress
- Anxiety and obsessions
- Mania
- Rage
- Repressed emotions
- Over-working
- Excess joy or passion

Small thin tongue = Yin/blood xu

Large puffy tongue = Yang/qi xu

Deviated (crooked) & Quivering = Internal wind

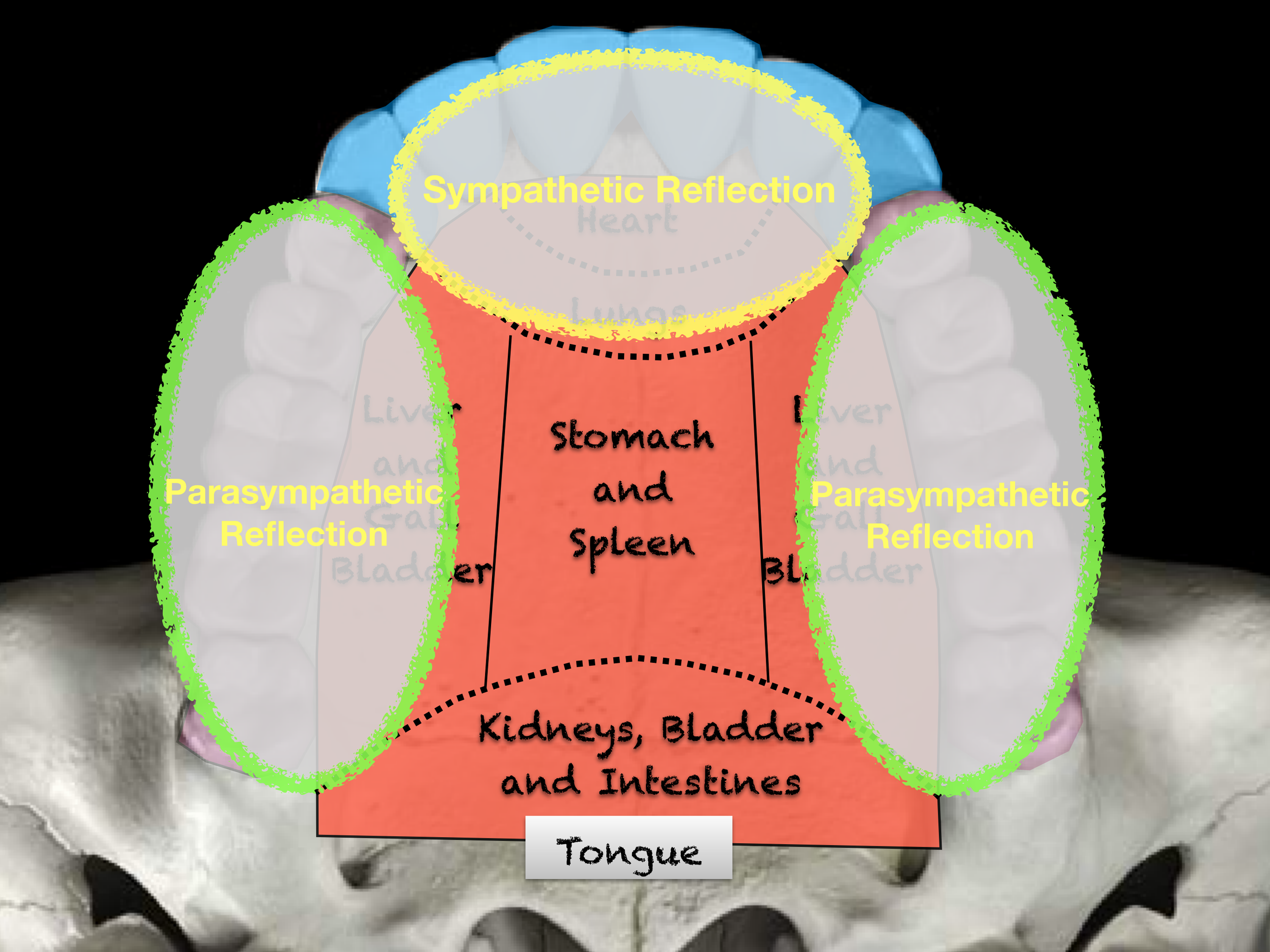
Sympathetic Reflection
Parasympathetic Reflection
Parasympathetic Reflection
Stomach and Spleen
Kidneys, Bladder and Intestines
Tongue

Then We Will Add In The Emotions Associated With the Tongue Map

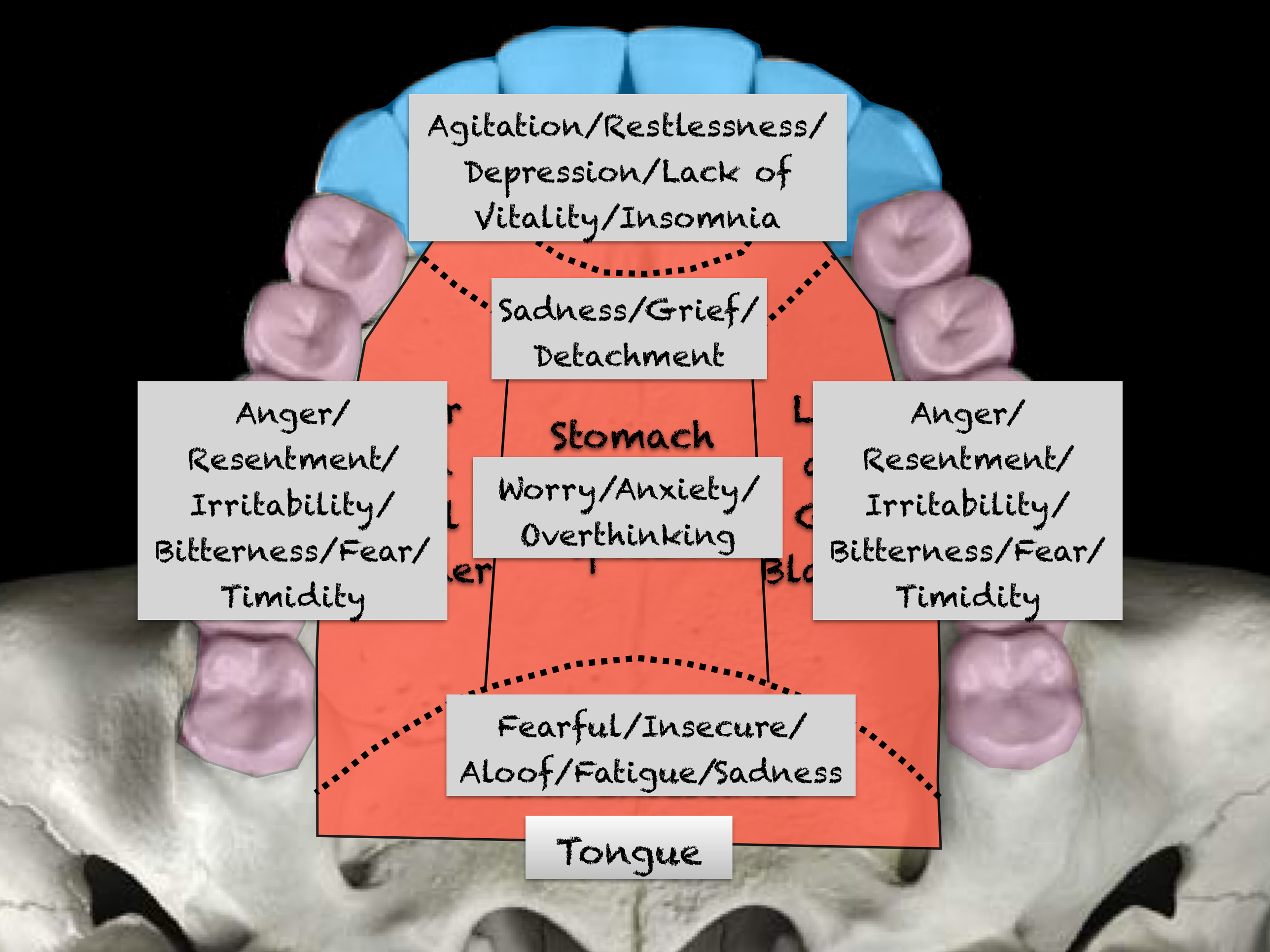
Agitation/Restlessness/
Depression/Lack of
Vitality/Insomnia
Sadness/Grief/
Detachment
Anger/
Resentment/
Irritability/
Bitterness/Fear/
Timidity
Stomach
Worry/Anxiety/
Overthinking
Anger/
Resentment/
Irritability/
Bitterness/Fear/
Timidity
Fearful/Insecure/
Aloof/Fatigue/Sadness
Tongue

This Can Then Reflect Into Dental Appliance Design or Adjustment

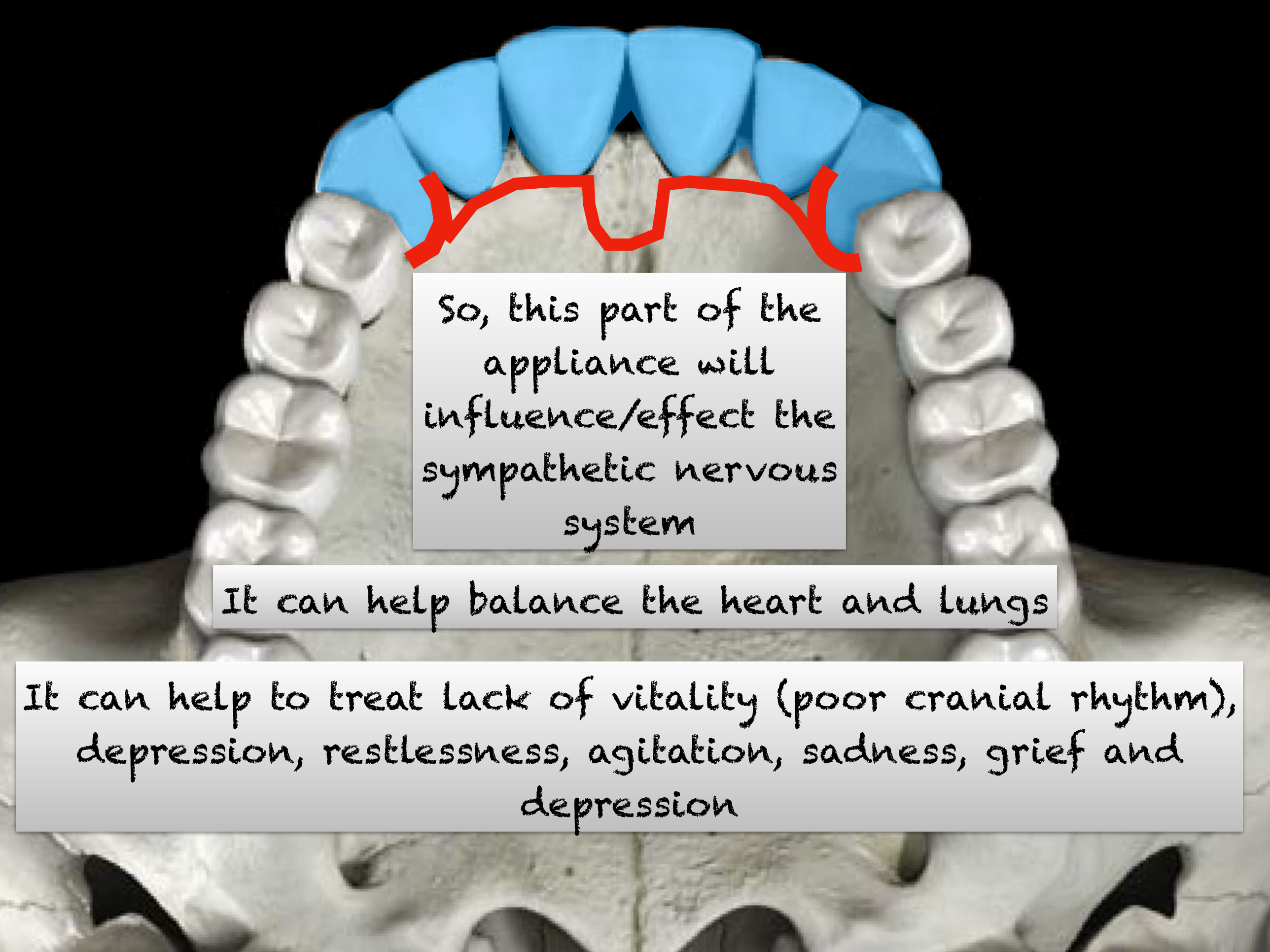

So, this part of the appliance will influence/effect the sympathetic nervous system

It can help balance the heart and lungs

It can help to treat lack of vitality (poor cranial rhythm), depression, restlessness, agitation, sadness, grief and depression

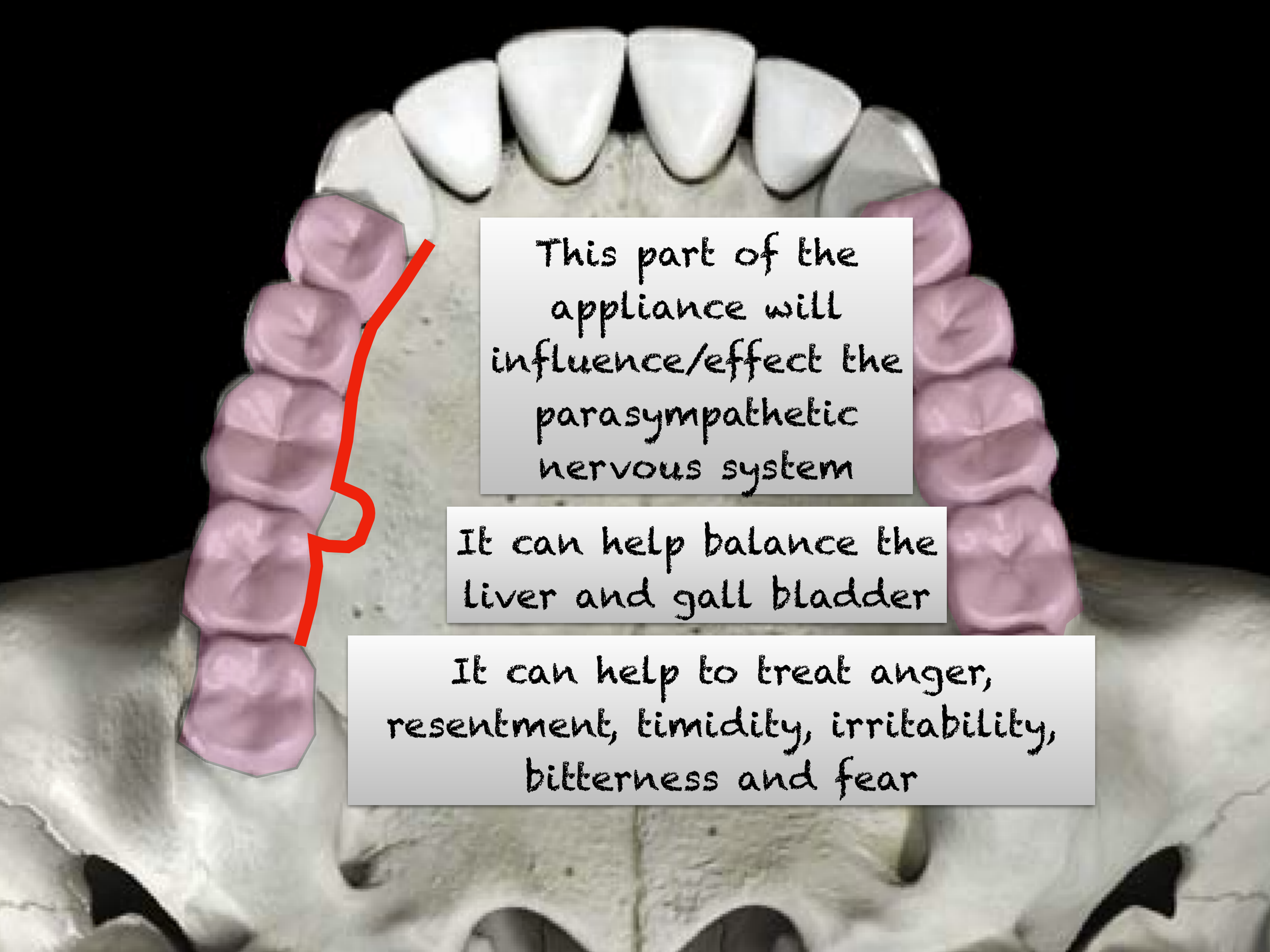
This part of the appliance will influence/effect the parasympathetic nervous system
It can help balance the liver and gall bladder
It can help to treat anger, resentment, timidity, irritability, bitterness and fear

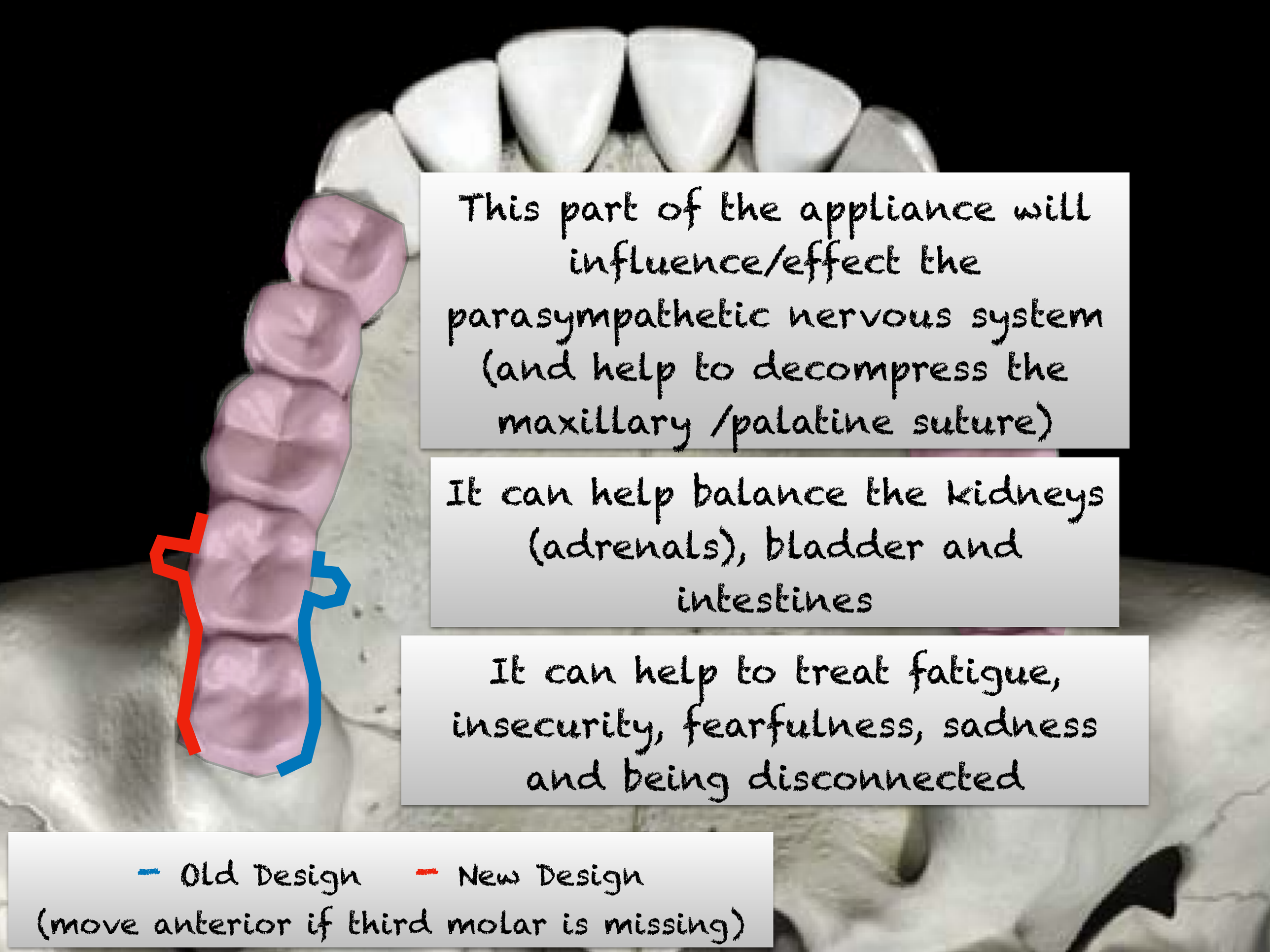

This part of the appliance will influence/effect the parasympathetic nervous system (and help to decompress the maxillary /palatine suture)

It can help balance the kidneys (adrenals), bladder and intestines

It can help to treat fatigue, insecurity, fearfulness, sadness and being disconnected

Old Design New Design
(move anterior if third molar is missing)

How????

- This is not the way that most people would look at the mouth and a dental appliance, but it does offer a few possible explanations as to what we see when we treat our patients…

The Impact of Wire Placement

If the body wire is more at the gingival margin, then the impact on the cranial component is more pronounced than the mechanical portion.

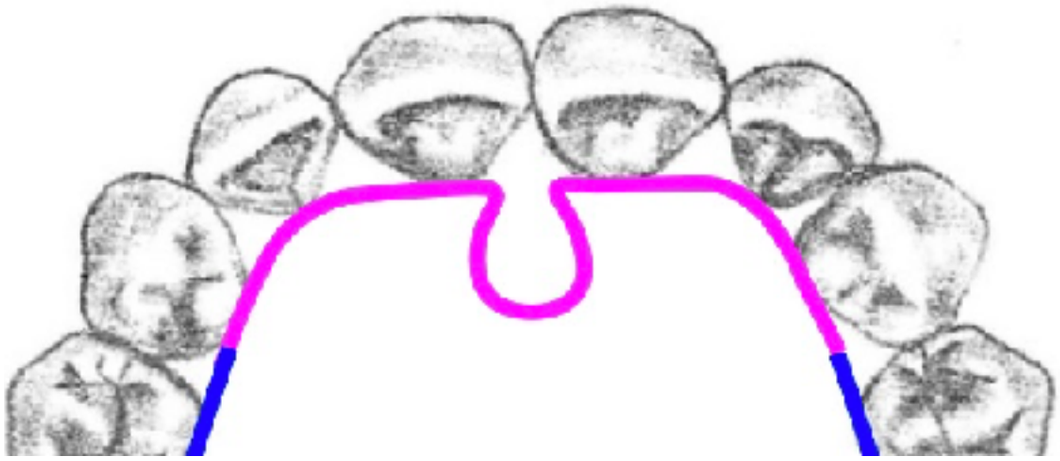

From Ljuba Lemke, DMD, PhD, ND

The Impact of Wire Placement

If the body wire is off the gingival margin and more on the cingulae, then the proclination of the teeth will be more prominently affected than the cranial motion.

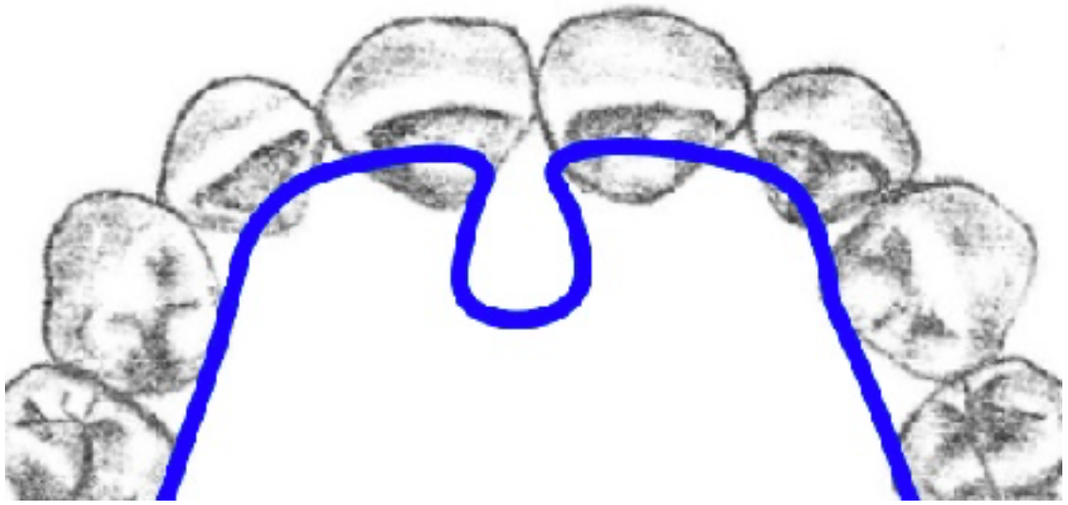

From Ljuba Lemke, DMD, PhD, ND

The Impact of Wire Placement

Blue line - body wire closer to incisal edges > more mechanical > more proclination

Violet line: body wire at the gingival margin > maximizes cranial effect > minimal proclination

From Ljuba Lemke, DMD, PhD, ND

Some Appliance Types

The Real World

- You will see your patients come in with these types of appliances. Each will have certain strengths and pitfalls in how they impact the body.

- Let’s discuss a few:

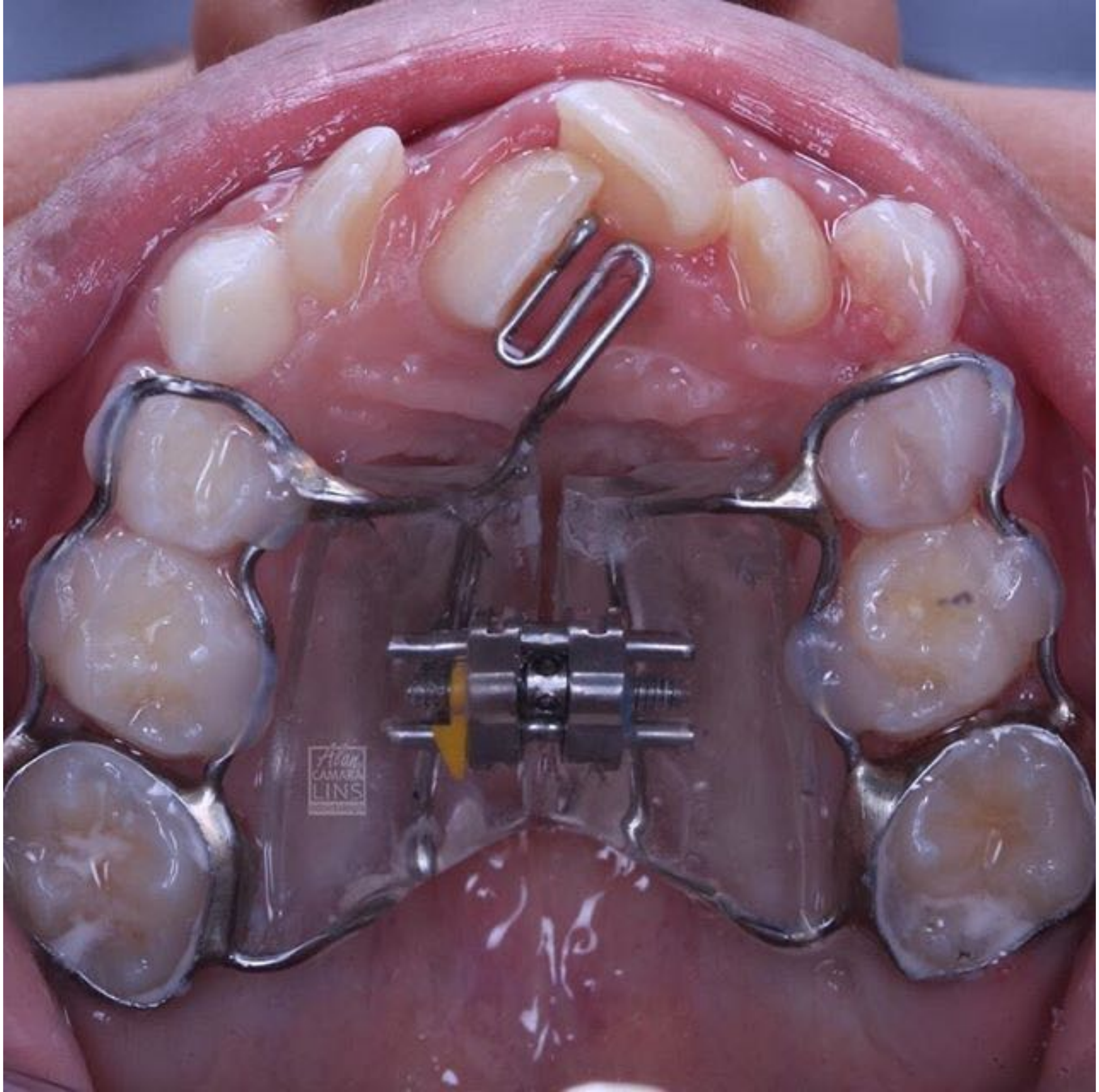
Alan
CAMARA
LINS

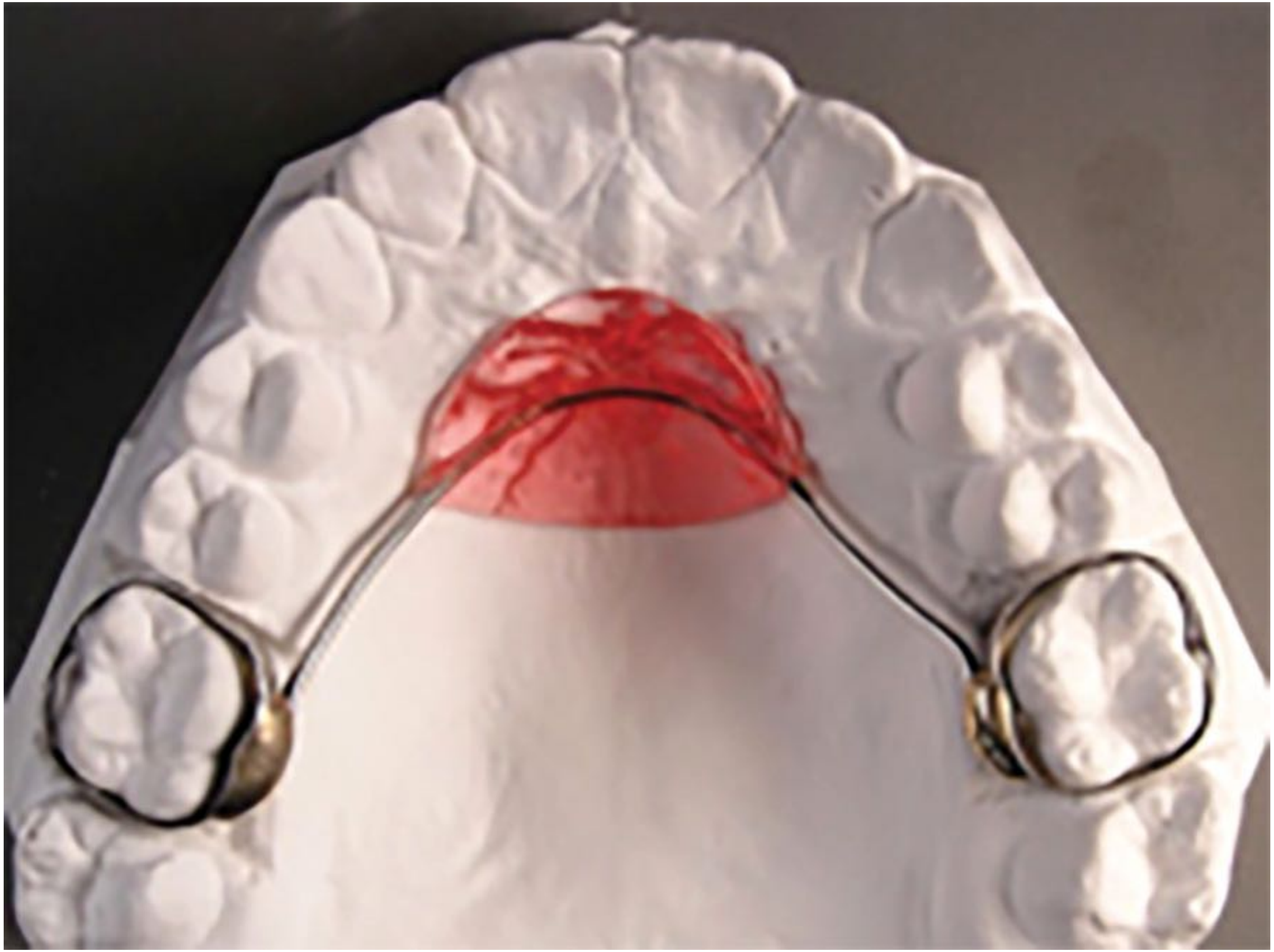

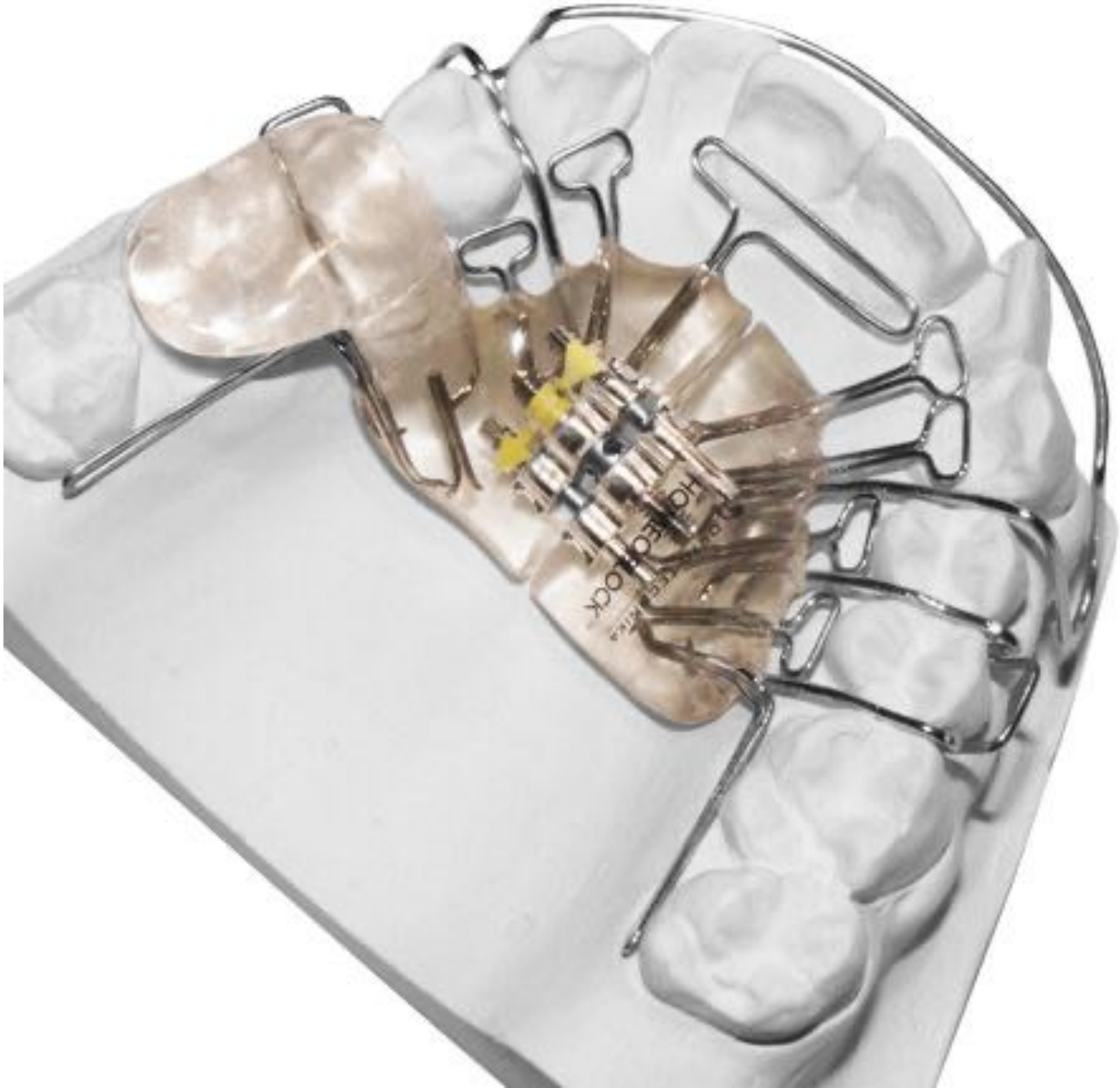

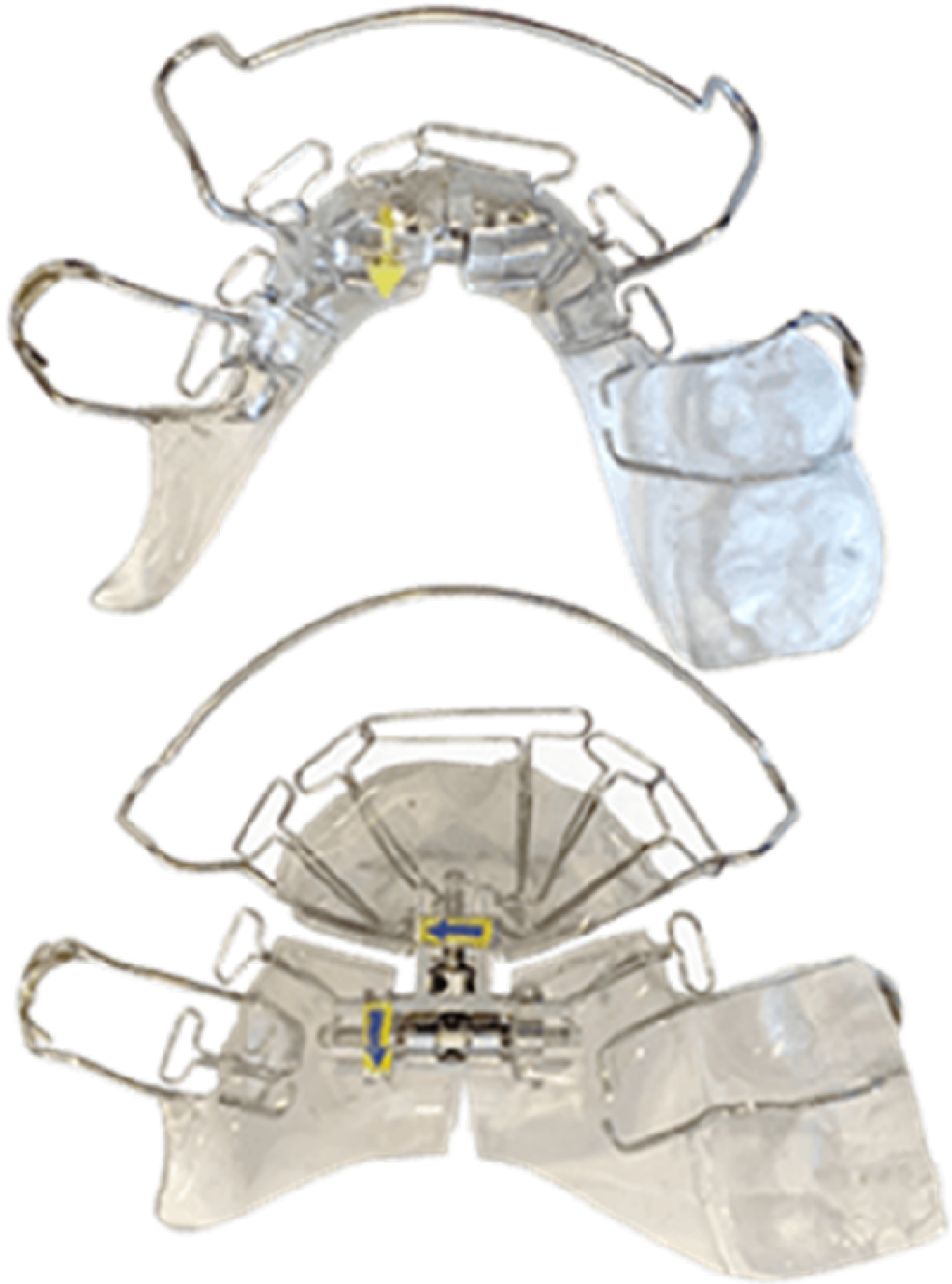

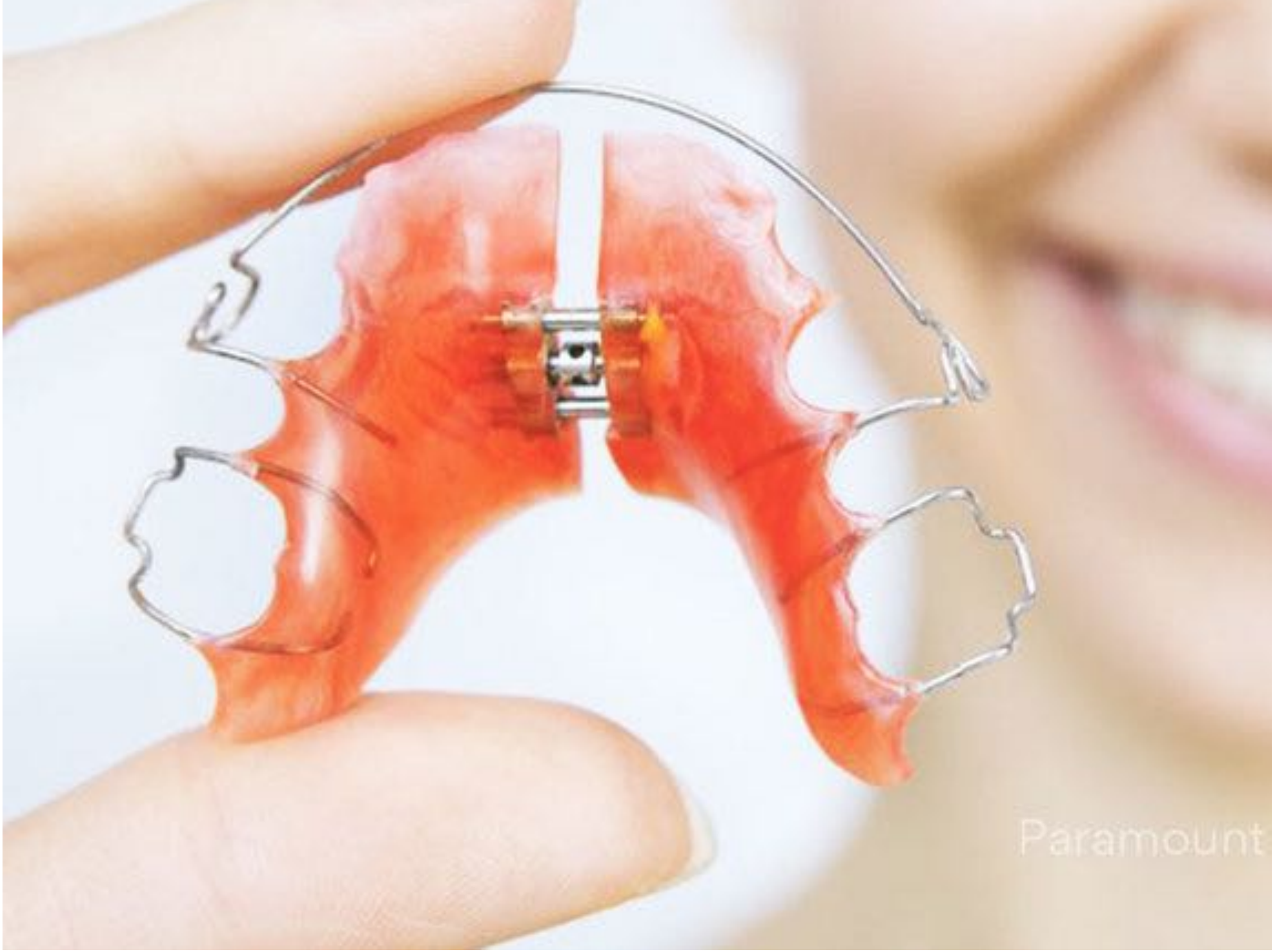
Paramount

Way Appliance

en and well and lengthen the arch. T
forward using the incisors. Alternati
al screws, one to widen and two
the posterior section. As with
aximum retention with Adam
s between the pre-molars
he anterior incisors and
providing additional

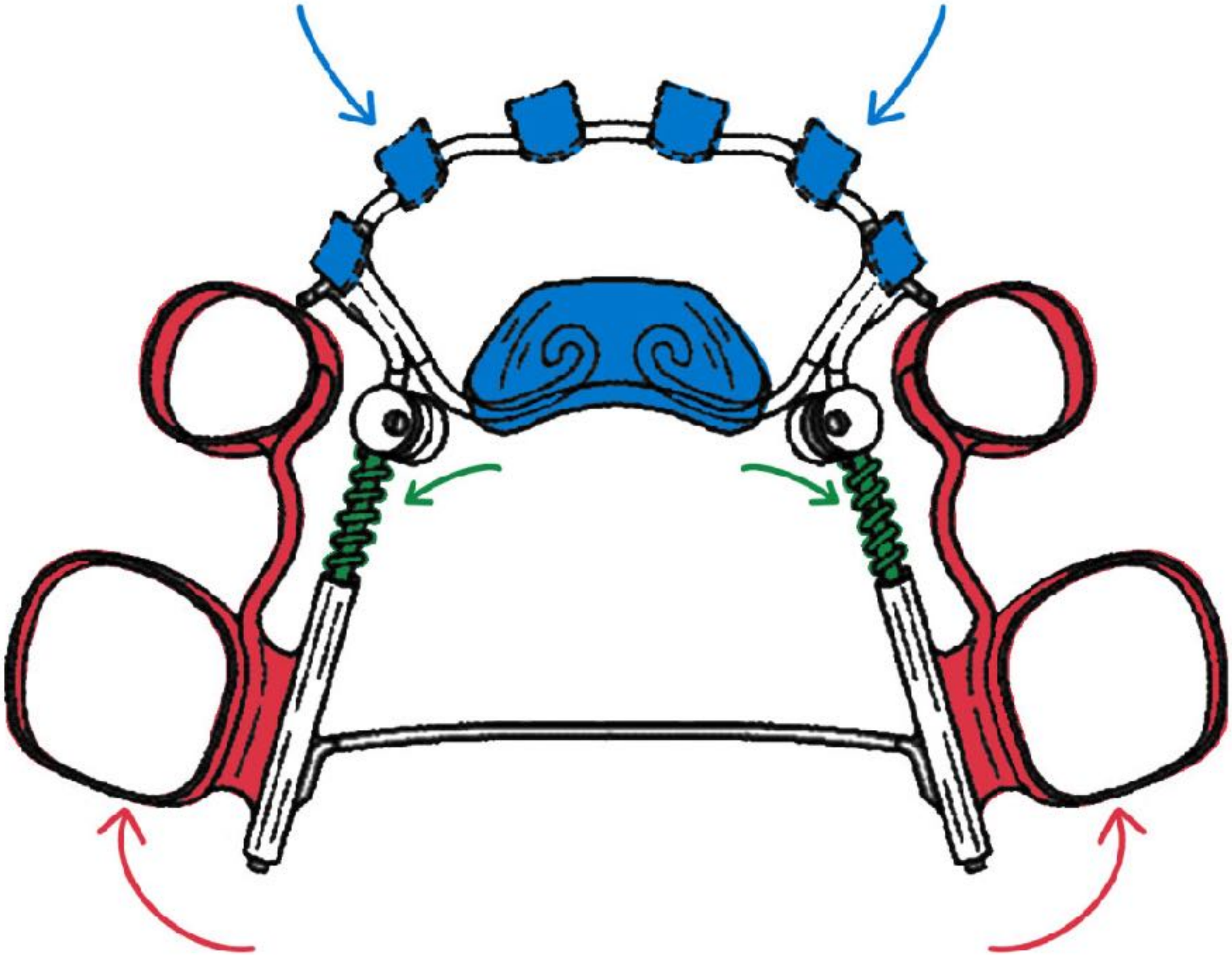

Posterior Chapman's Reflexes and their Relationship to the Mouth

Occur bilaterally unless otherwise noted

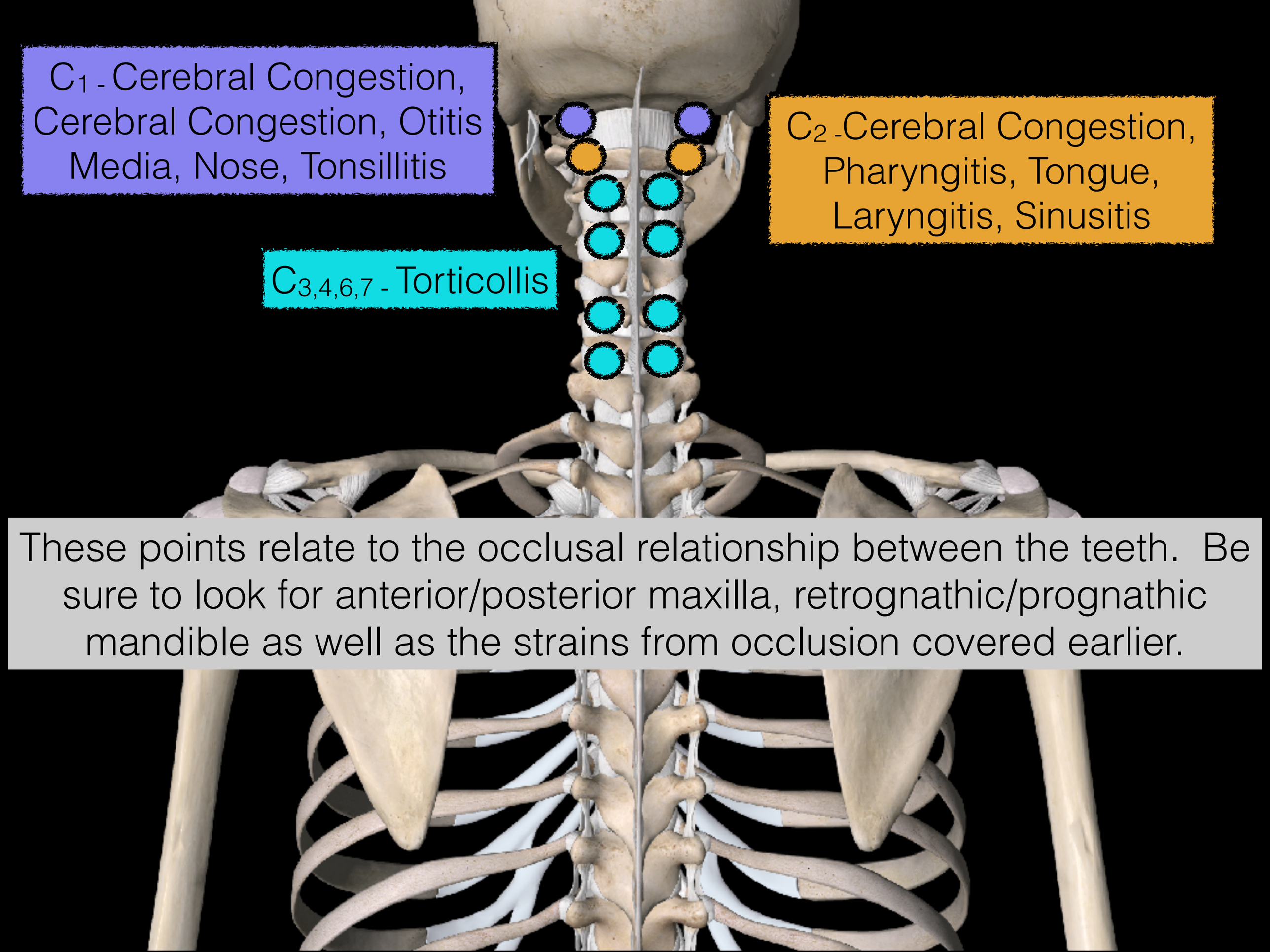

These points relate to the occlusal relationship between the teeth. Be sure to look for anterior/posterior maxilla, retrognathic/prognathic mandible as well as the strains from occlusion covered earlier.

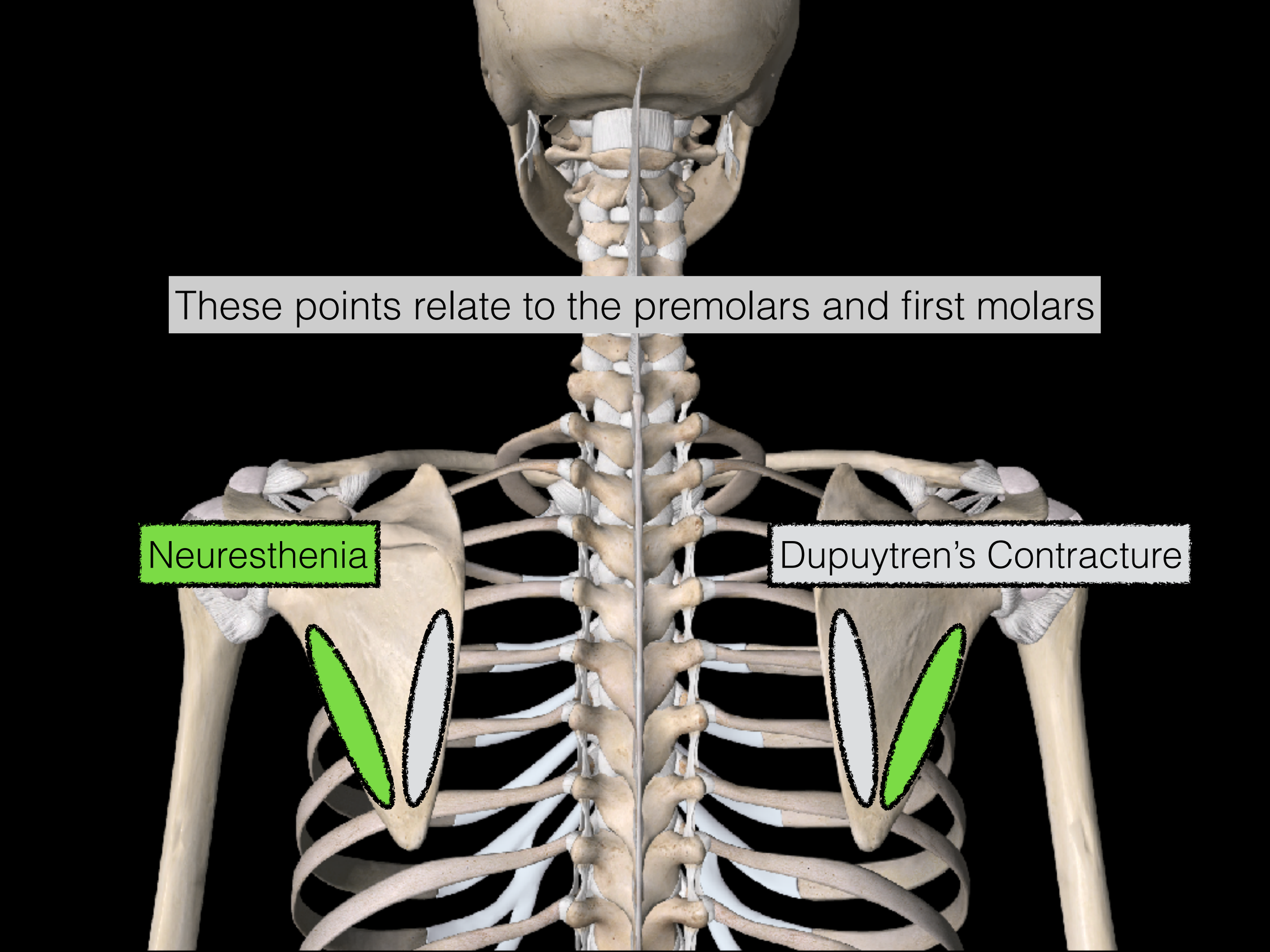
These points relate to the premolars and first molars
Neurasthenia
Dupuytren's Contracture

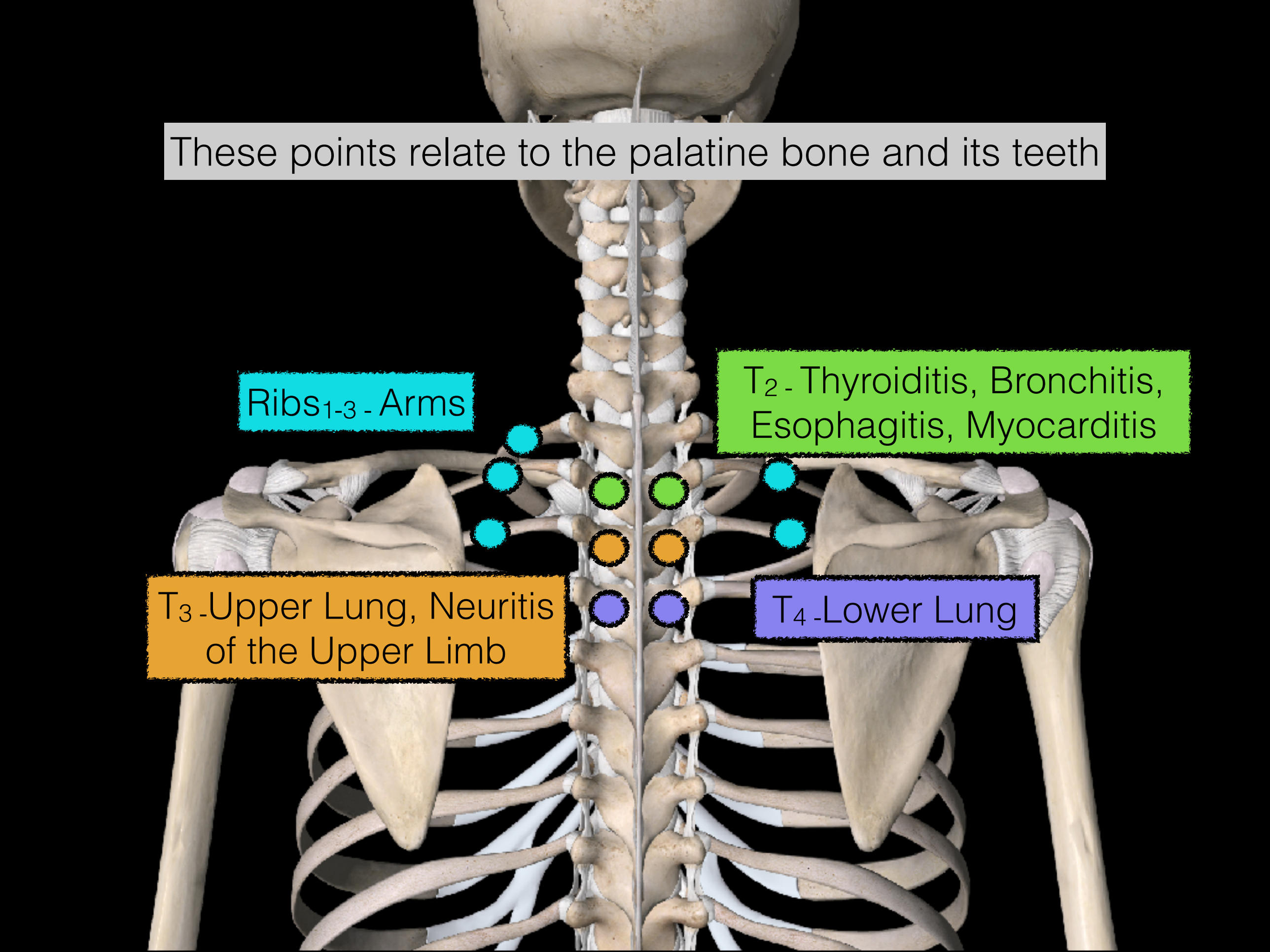
These points relate to the palatine bone and its teeth
Ribs1-3 - Arms
T2 - Thyroiditis, Bronchitis, Esophagitis, Myocarditis
T3 -Upper Lung, Neuritis of the Upper Limb
T4 -Lower Lung

These points relate to the back half of the maxillary palate/ intermaxillary suture

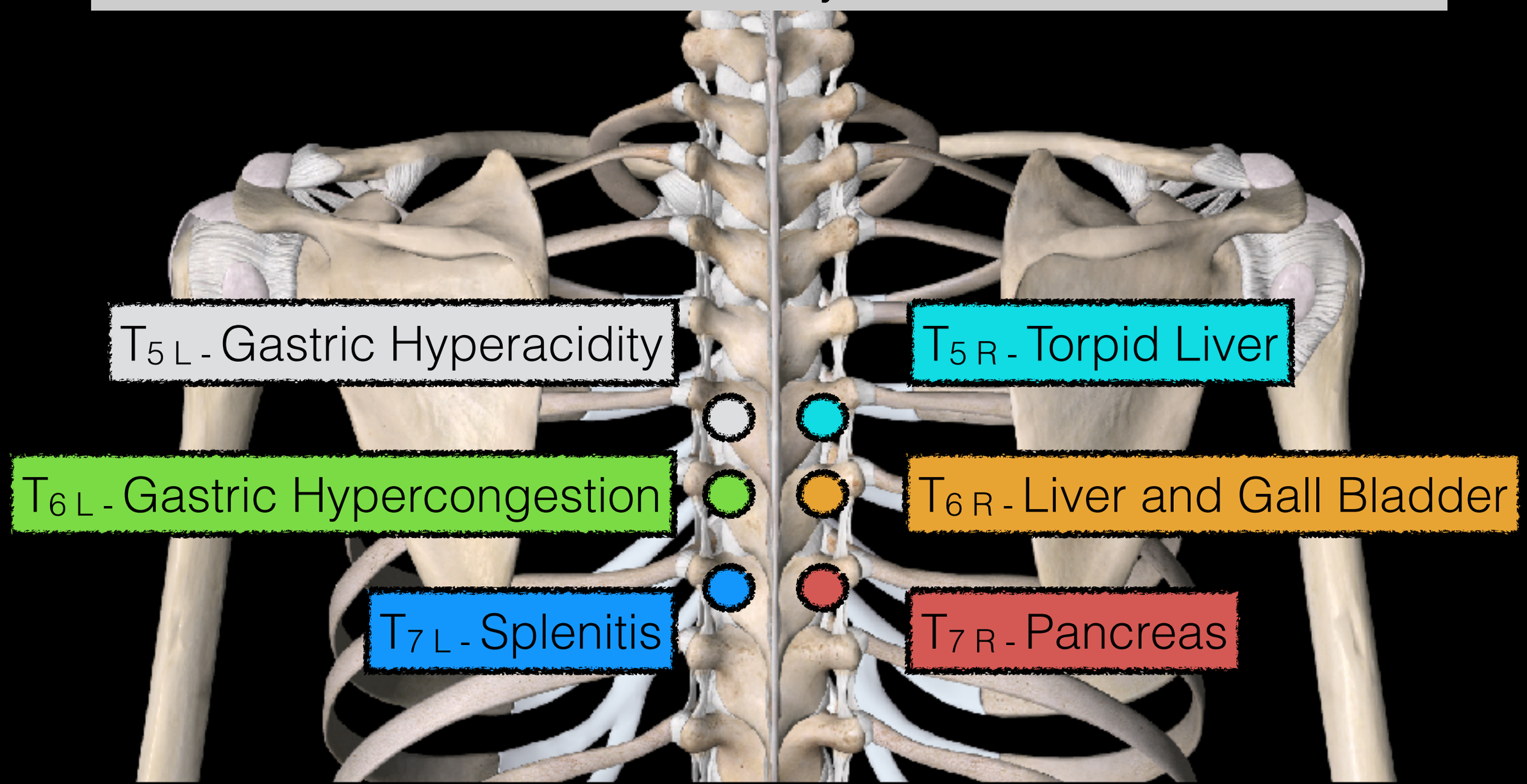

These points relate to the front half of the maxillary palate/ intermaxillary suture/premaxilla/premaxilla-maxiallary suture

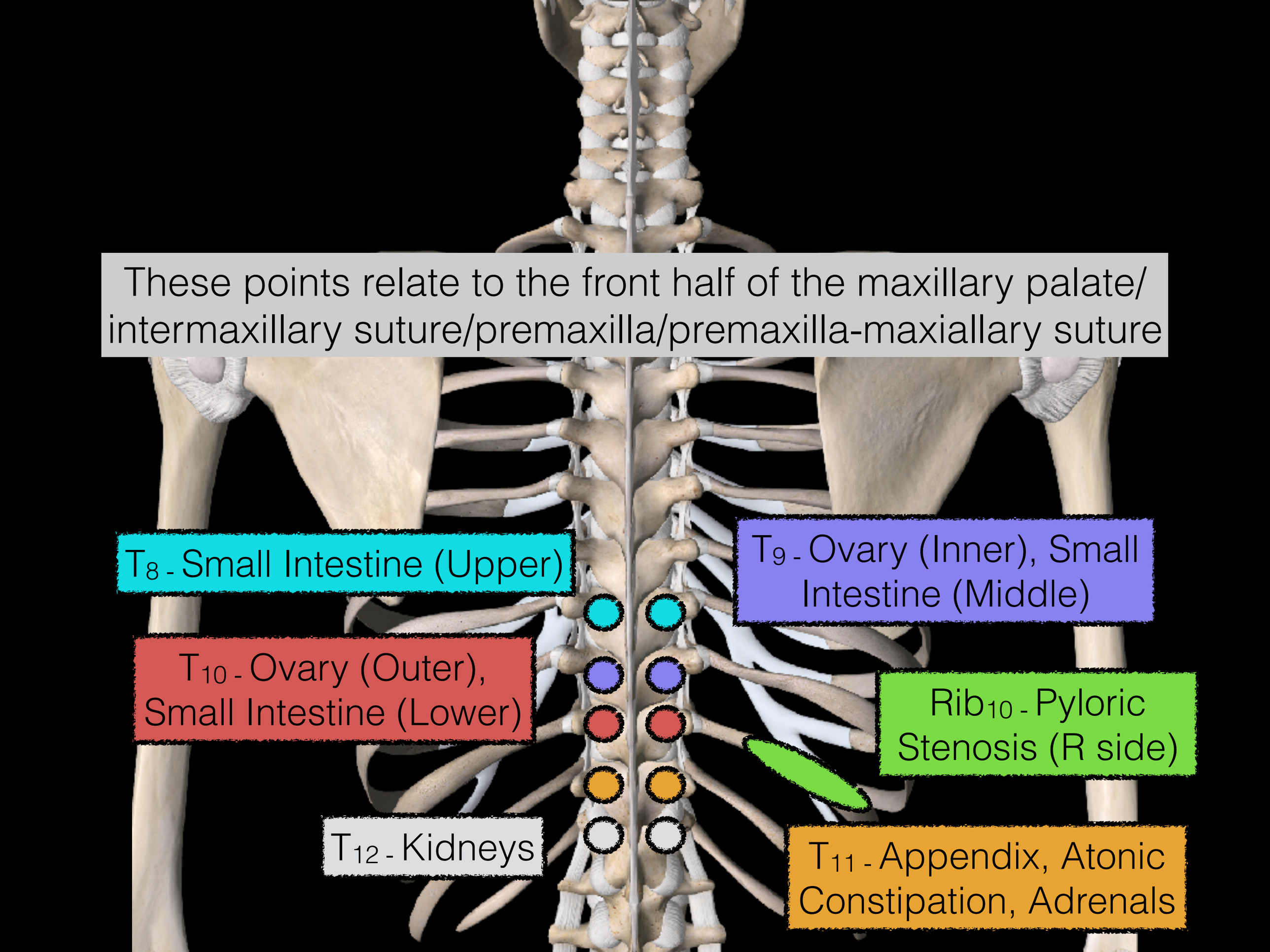

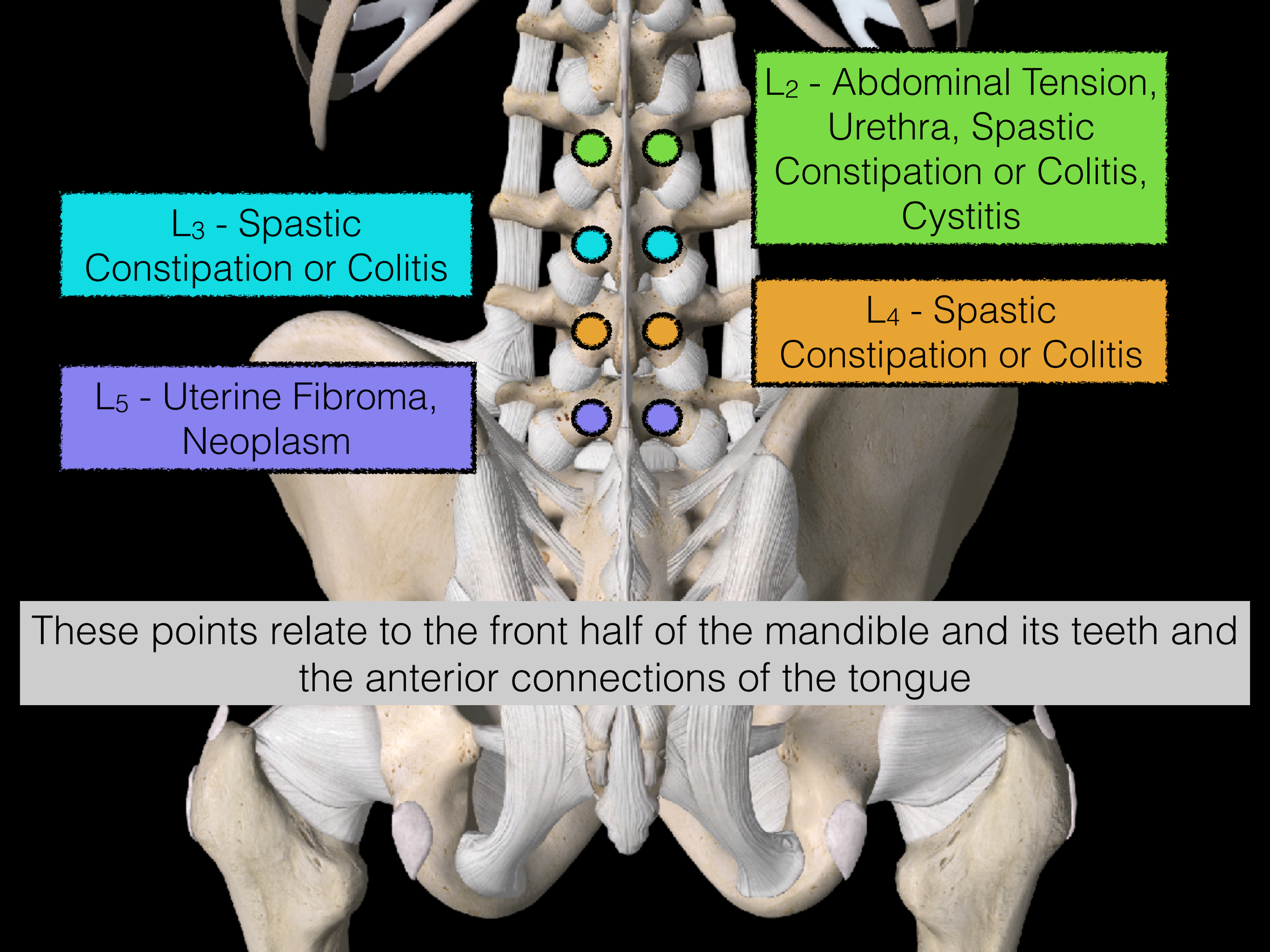

These points relate to the front half of the mandible and its teeth and the anterior connections of the tongue

These points relate to the back half of the mandible and its teeth and the posterior connections of the tongue/hyoid bone

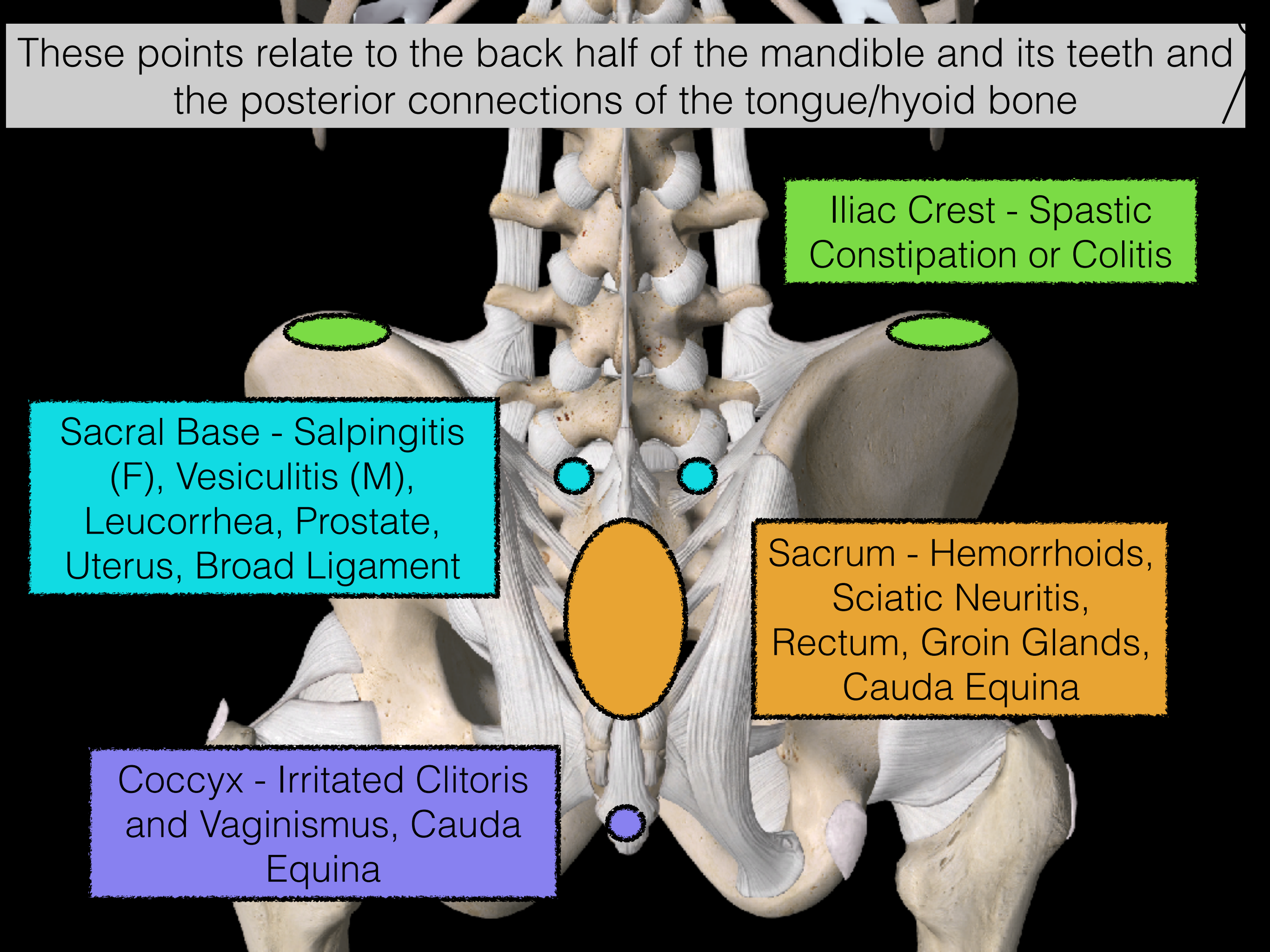

Traditional Ortho Items

and their effect on the body

“It has become appallingly obvious that our technology has exceeded our humanity.”

–Albert Einstein

Molar (or other tooth) Bands

Molar Bands

- Springs placed here
- Cause a rotational force here, which can effect the body (refer to tooth chart for body correlation)



Springs

- This causes and anterior rotational force in the front tooth and a posterior rotational force in the rear tooth.
- This configuration also puts force on the transeptal ligament (which can open a vertebral facet pair on the ipsilateral side or close one on the contralateral side)

Springs

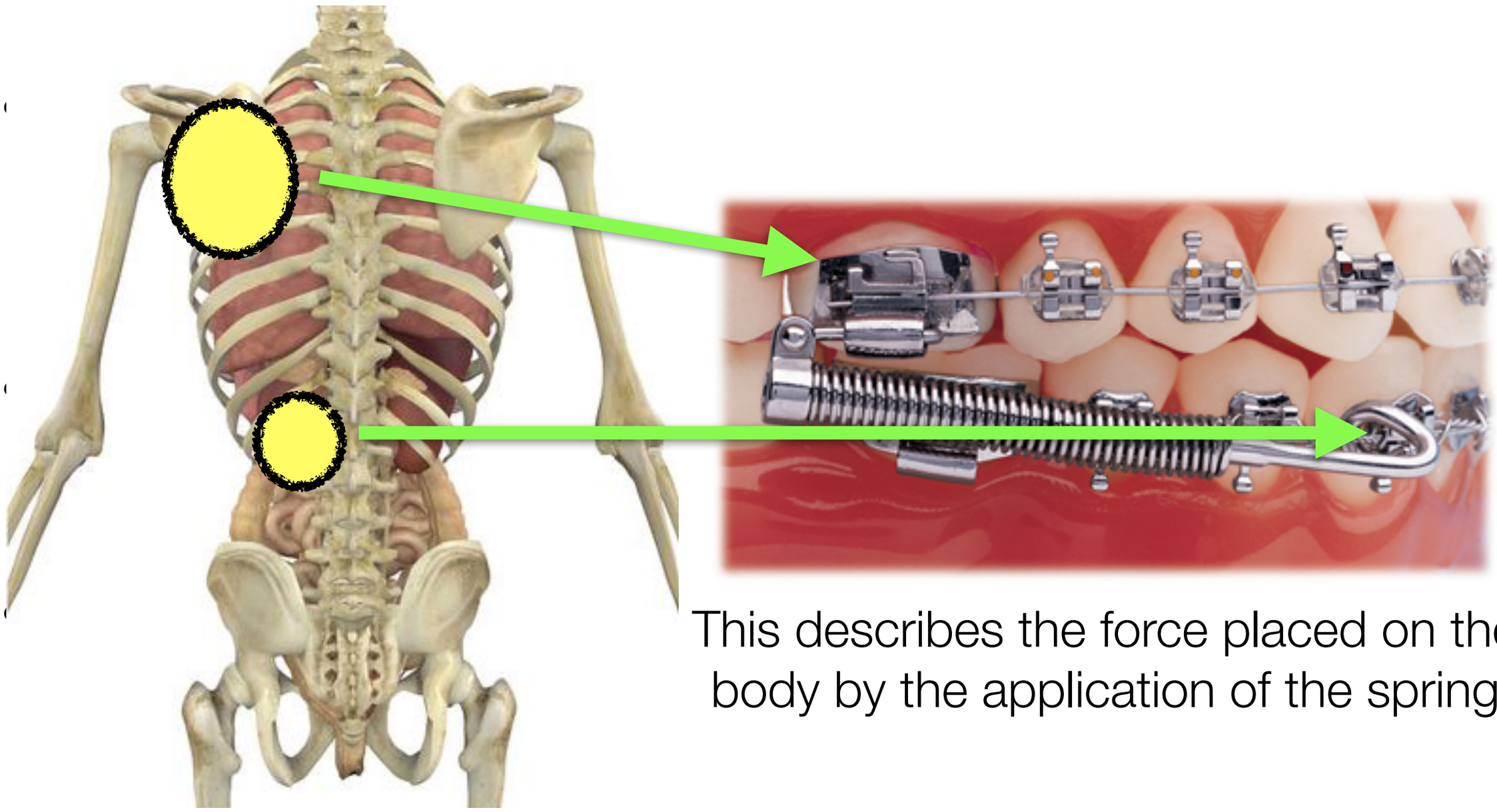

This describes the force placed on the body by the application of the spring

Molar Bands/Elastics

- Elastics placed here
- Cause a pitch and yaw force, which can effect the body (refer to tooth chart for body correlation)
- This causes a lingual tipping force on the tooth, and, perhaps rotational forces as well



Molar Bands

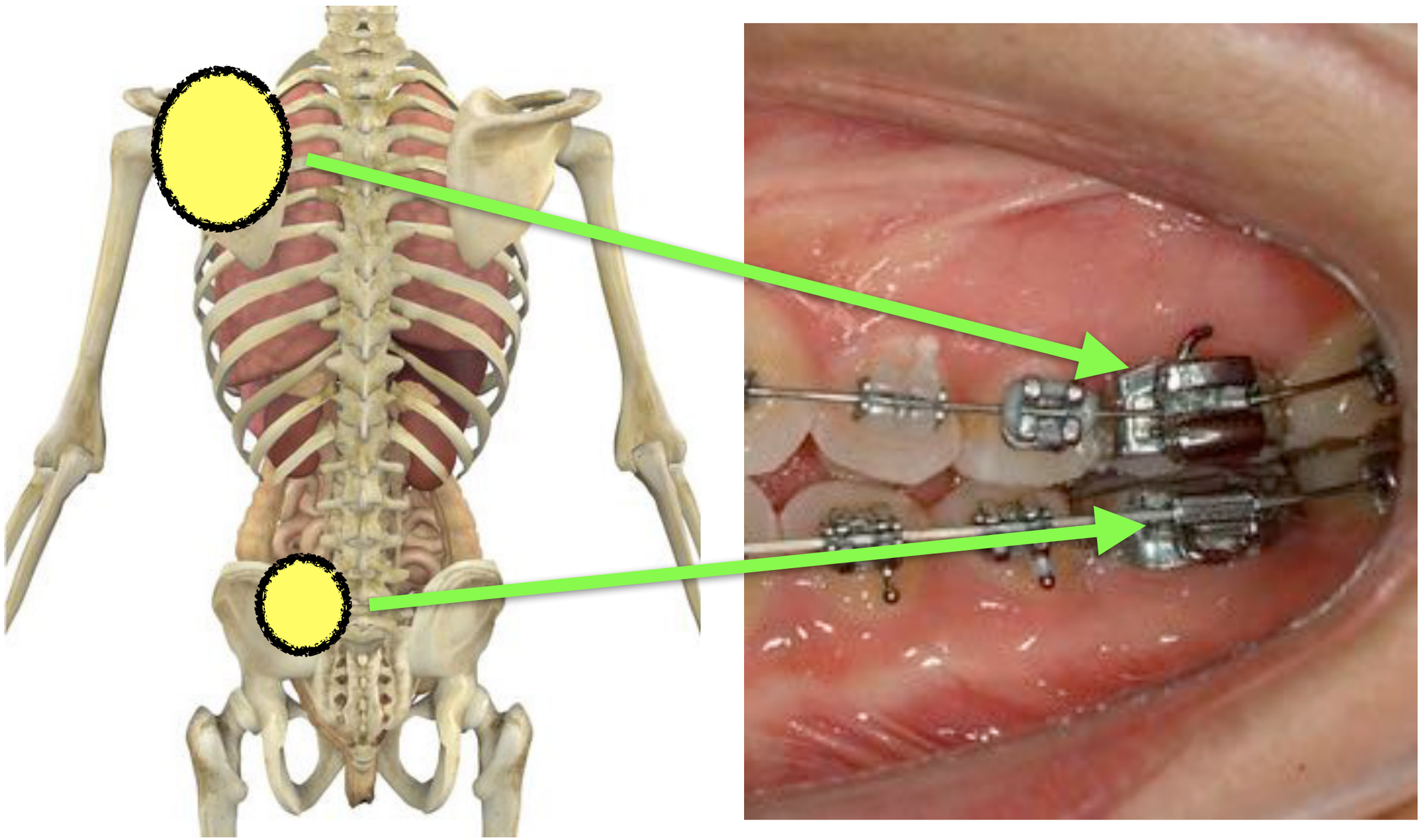

Molar Bands

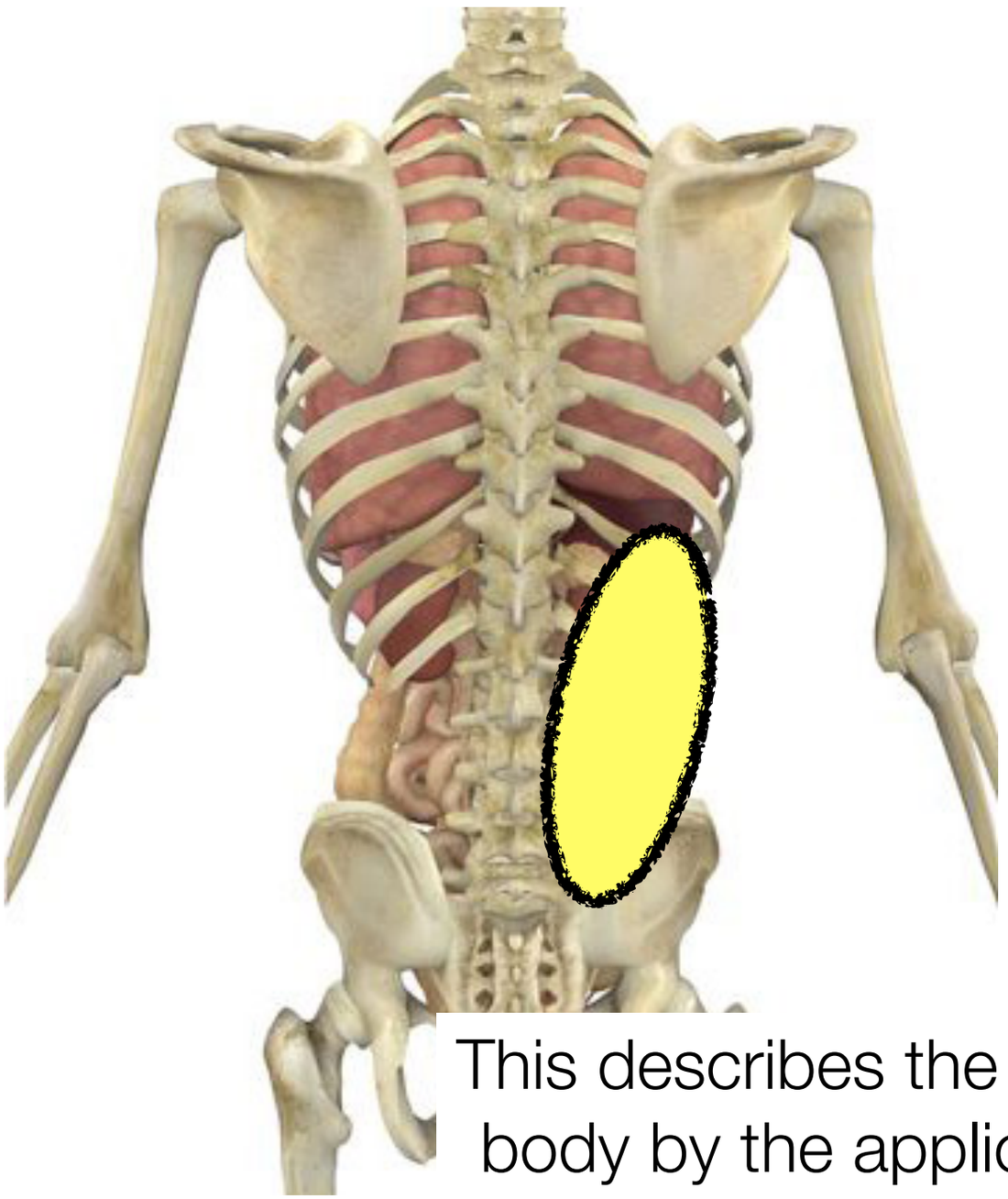

This describes the force placed on the body by the application of the elastic

Elastics

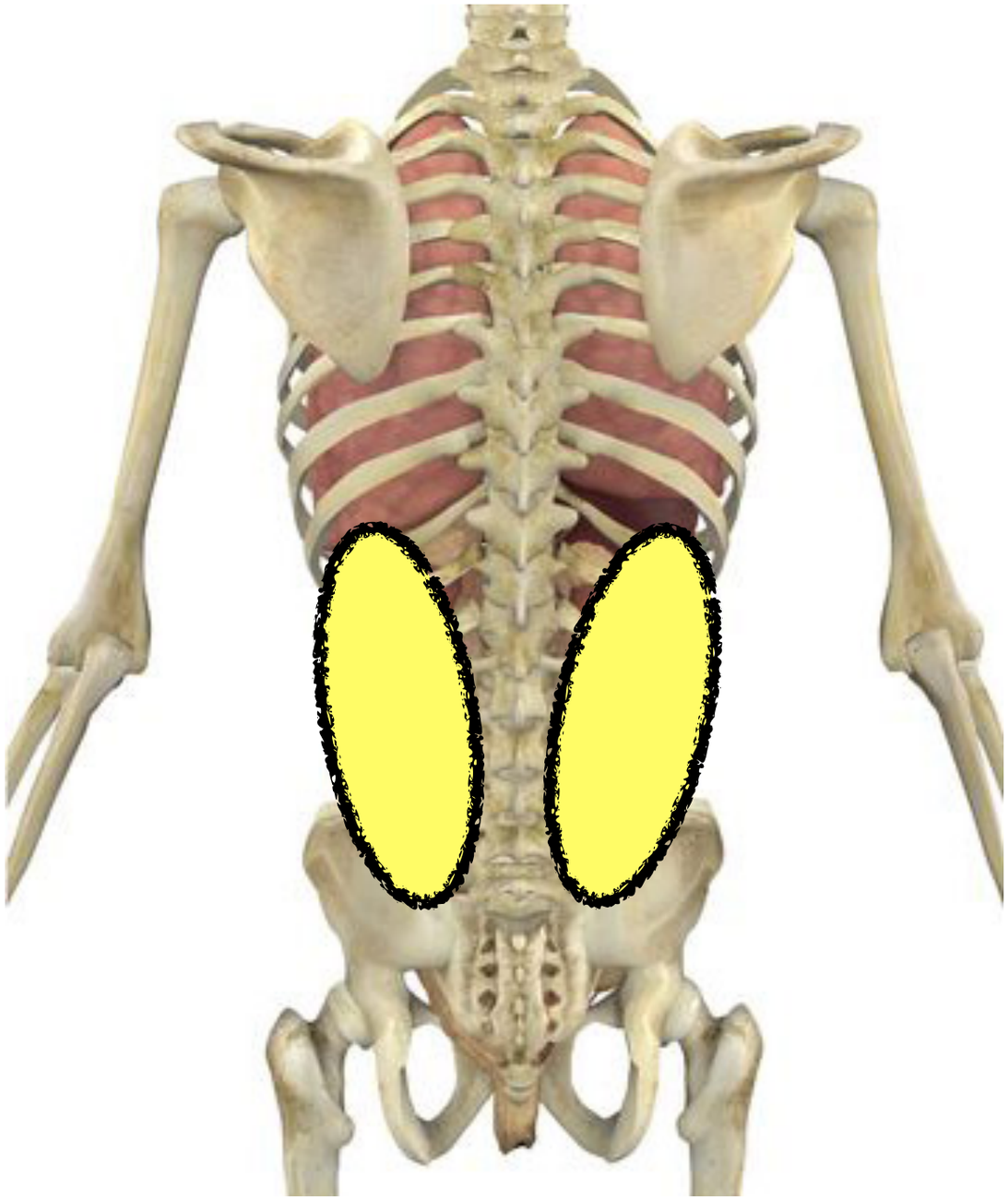

Elastics

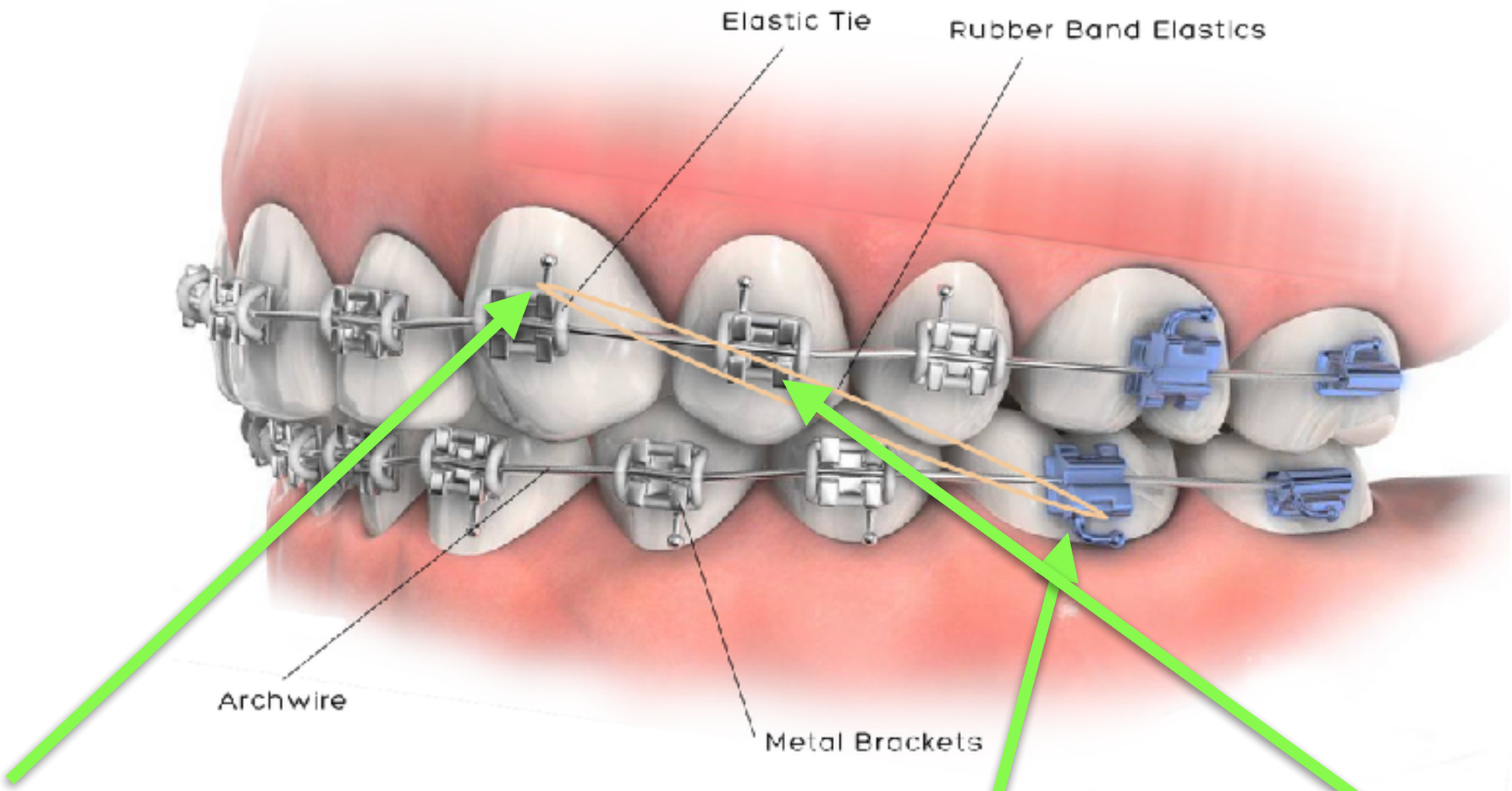

- In this setup, the tension on the premaxilla/maxilla border can cause ipsilateral tension in the lower rib cage and a potential side bending of the rib cage due to the rotary force placed on the tooth.
- The tension on the lower molar can restrict the SI joint.
- Inward force on any tooth the elastic touches can tip the tooth potentially causing body issues.

Elastics

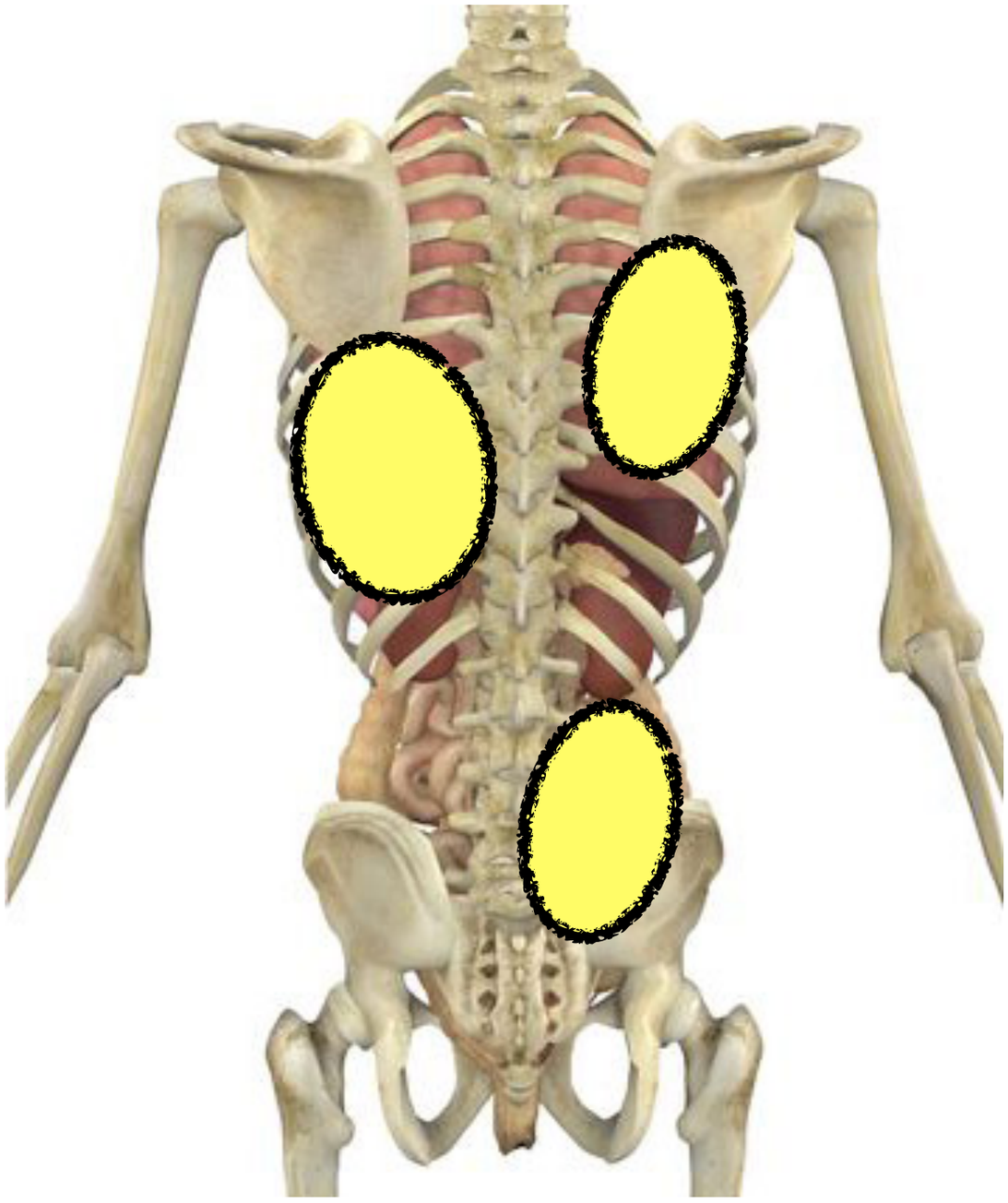

Posture and Dentition

This portion is still mostly theory, so please take it that way.

This is where we SHOULD be. In this posture, the head is well positioned over the shoulders, which are well positioned over the hips, which are well positioned over the ankles…

In this position, the Reciprocal Tension Membrane is optimally balanced and walking motion and swallowing stimulates Sutherland's Fulcrum.

The pelvic floor, SI joints, respiratory diaphragm, shoulders and TMJ's are relaxed and working well.

This is the optimal position for the patient with each ALF adjustment.

Good Posture

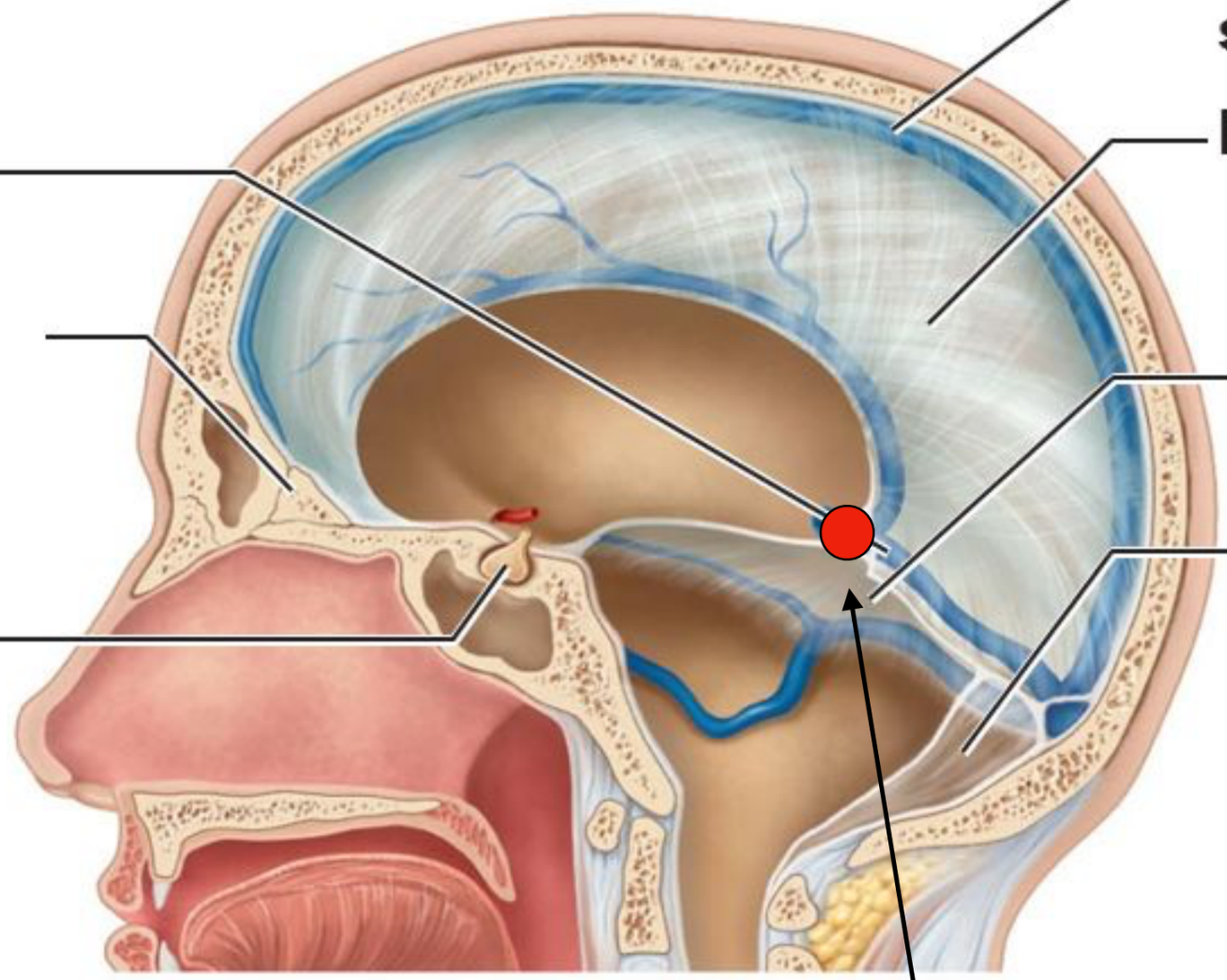
Superior sagittal sinus
Falx cerebri
Straight sinus
Crista galli of the ethmoid bone
Tentorium cerebelli
Falx cerebelli
Pituitary gland
Sutherland's Fulcrum

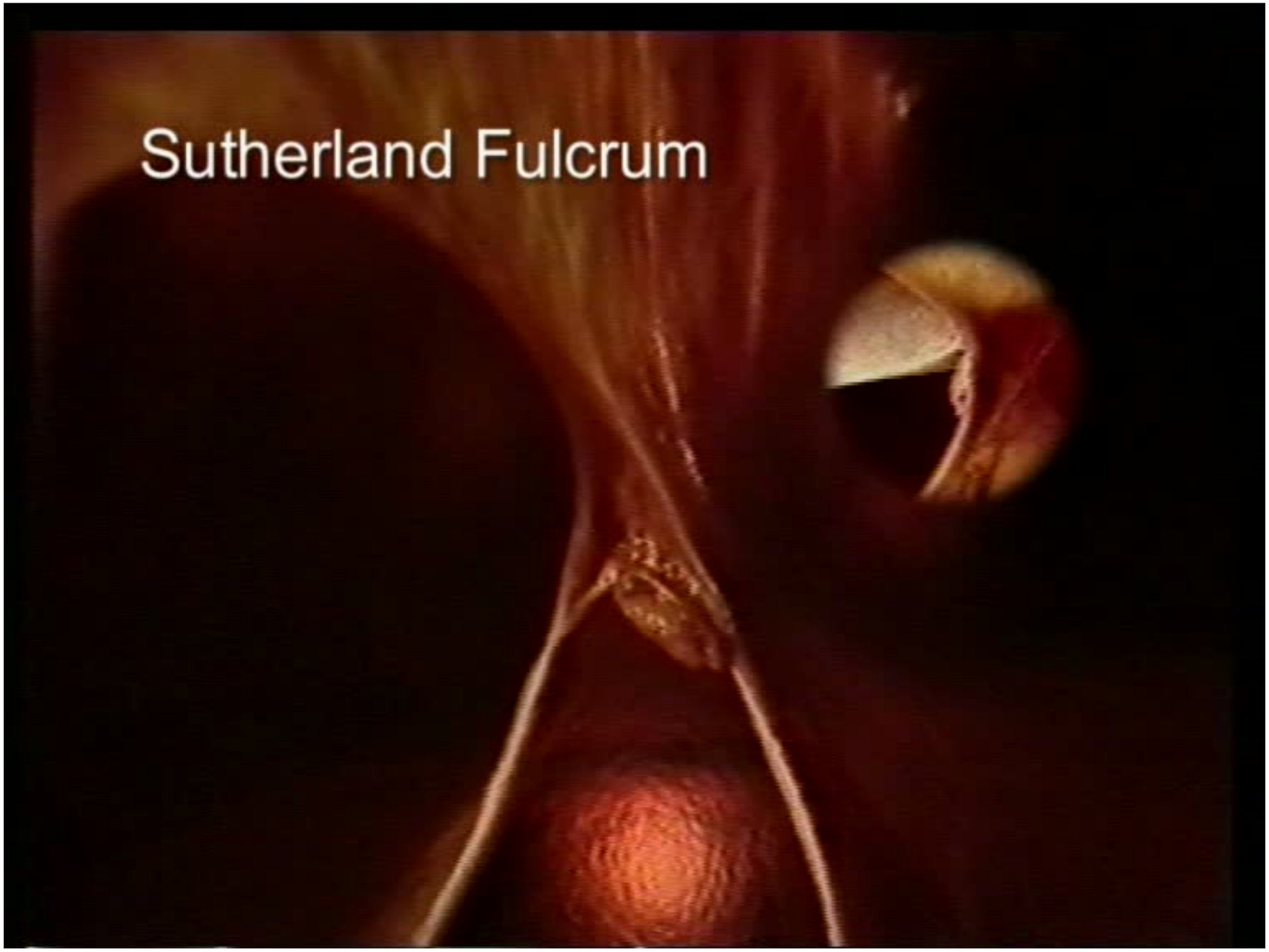
Sutherland Fulcrum

In a forward head carriage, there is tension from the dura being stressed that shows up in the falx cerebri.

The Reciprocal Tension Membrane is out of balance and walking motion and swallowing do not stimulate Sutherland's Fulcrum.

This effects swallowing and tongue position!

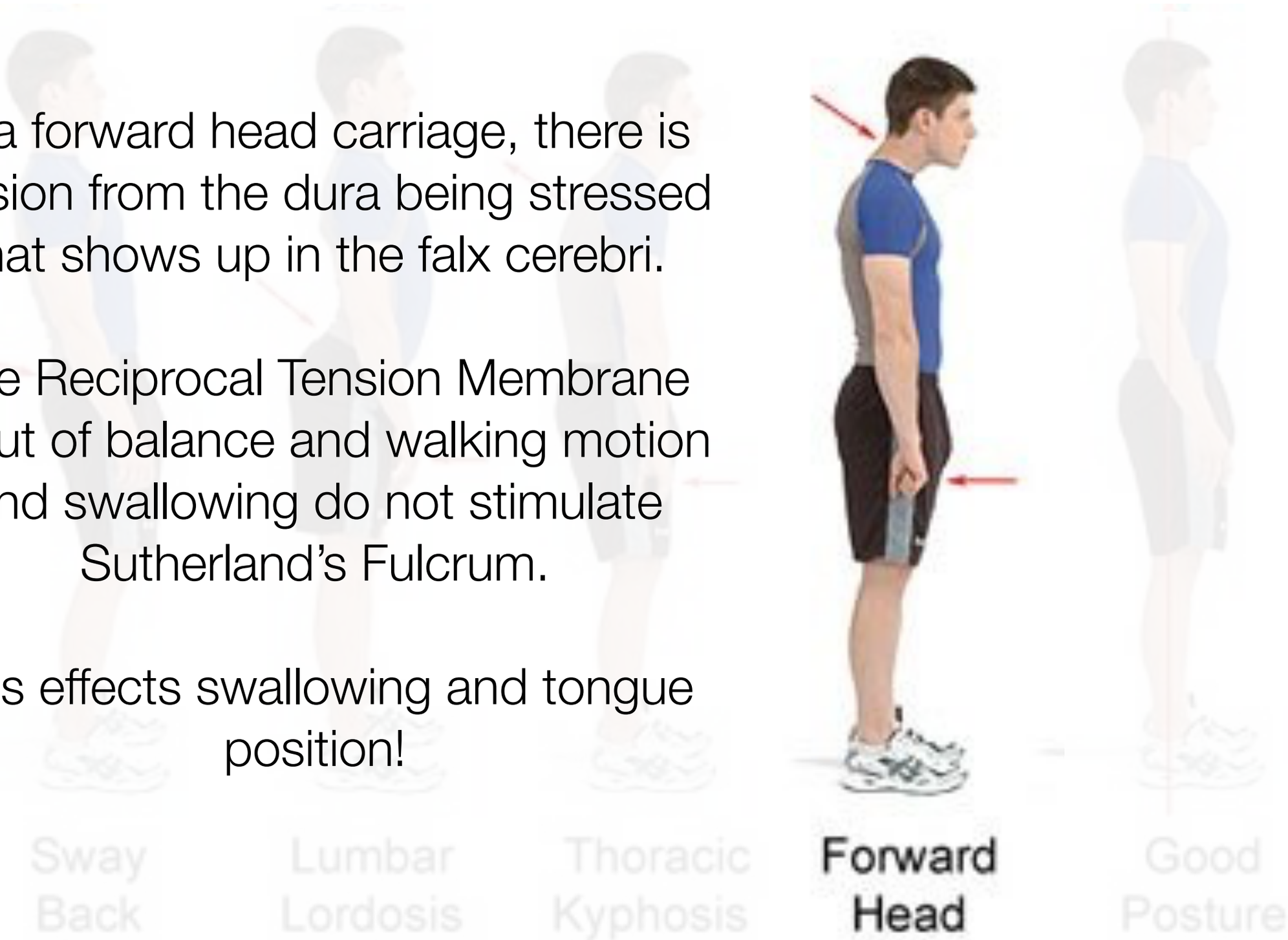

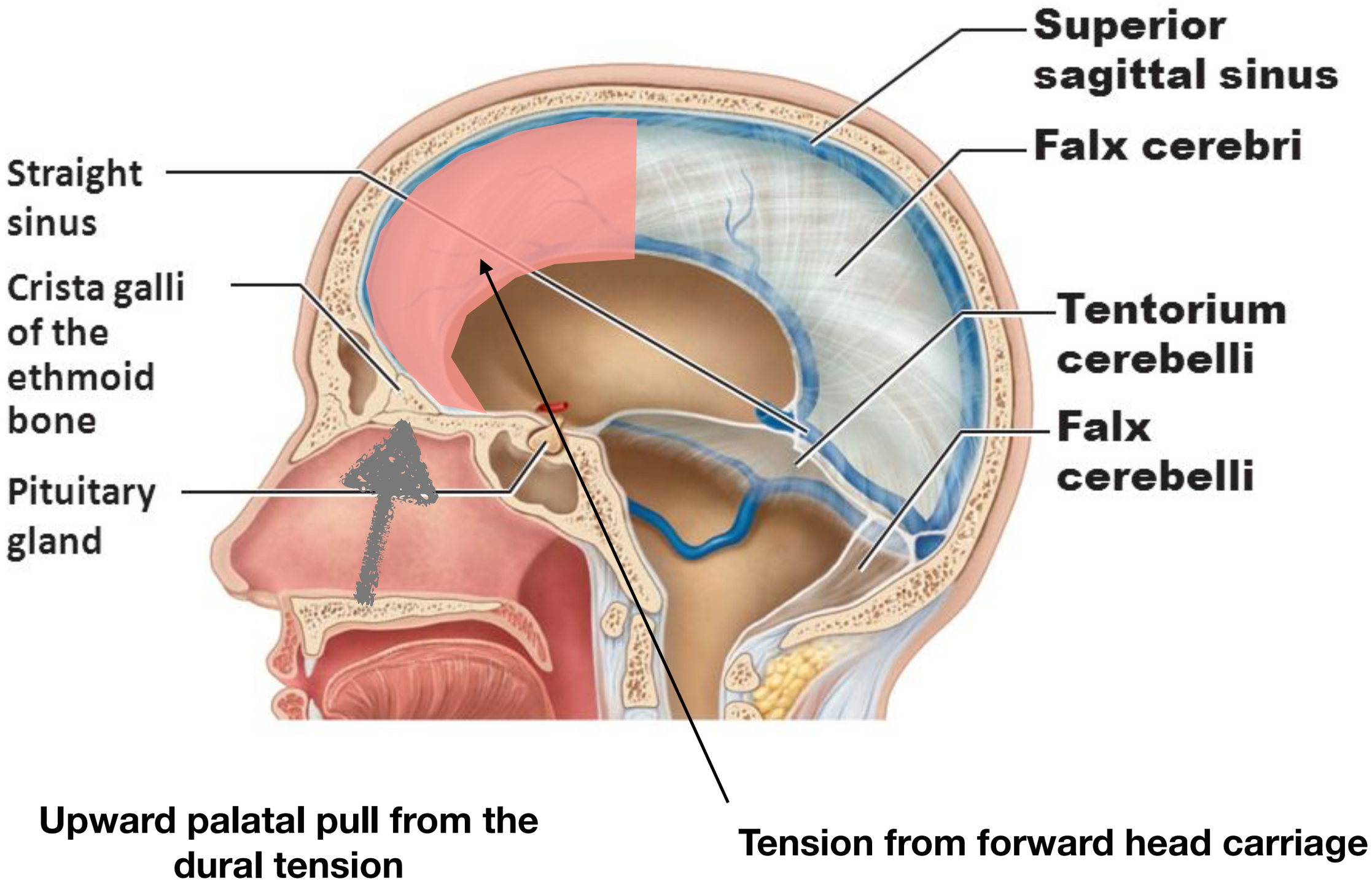
Superior sagittal sinus
Falx cerebri
Straight sinus
Crista galli of the ethmoid bone
Tentorium cerebelli
Falx cerebelli
Pituitary gland
Upward palatal pull from the dural tension
Tension from forward head carriage

Tongue Connection

Muscle Tension Here

Relates to Tongue Tension Here

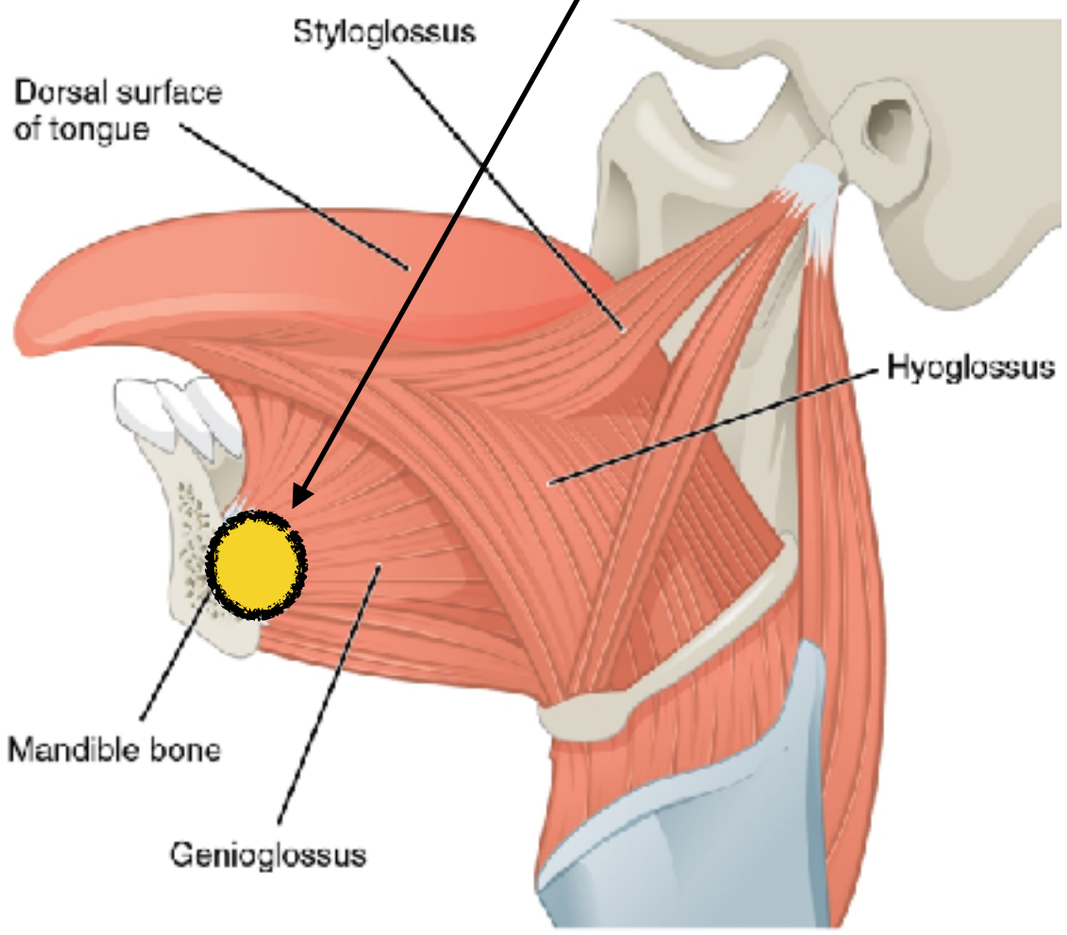

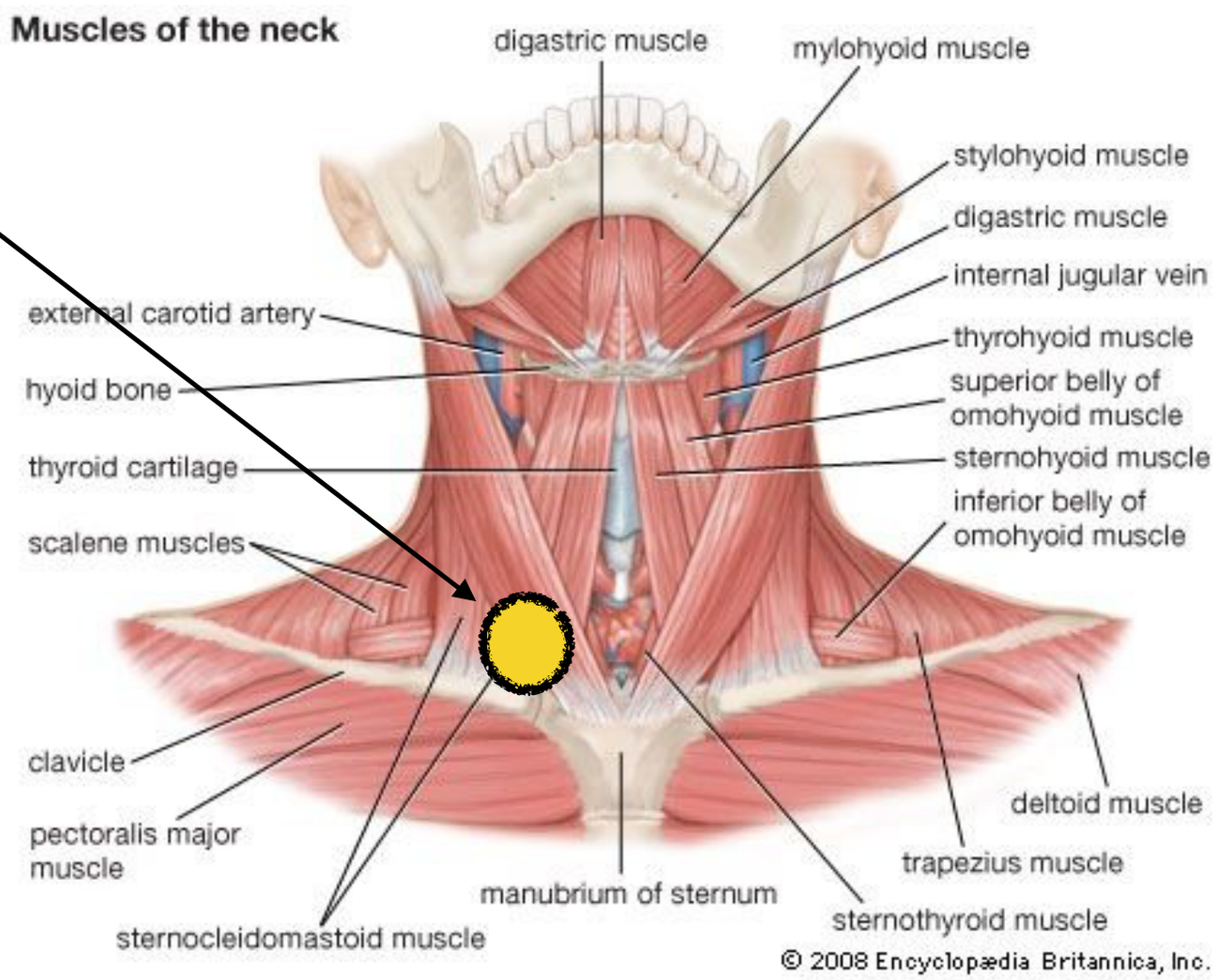

In thoracic kyphosis, there is a restriction in the inter-maxillary suture.

The Reciprocal Tension Membrane
is out of balance and walking motion and swallowing do not stimulate Sutherland's Fulcrum.

This effects swallowing and tongue position!

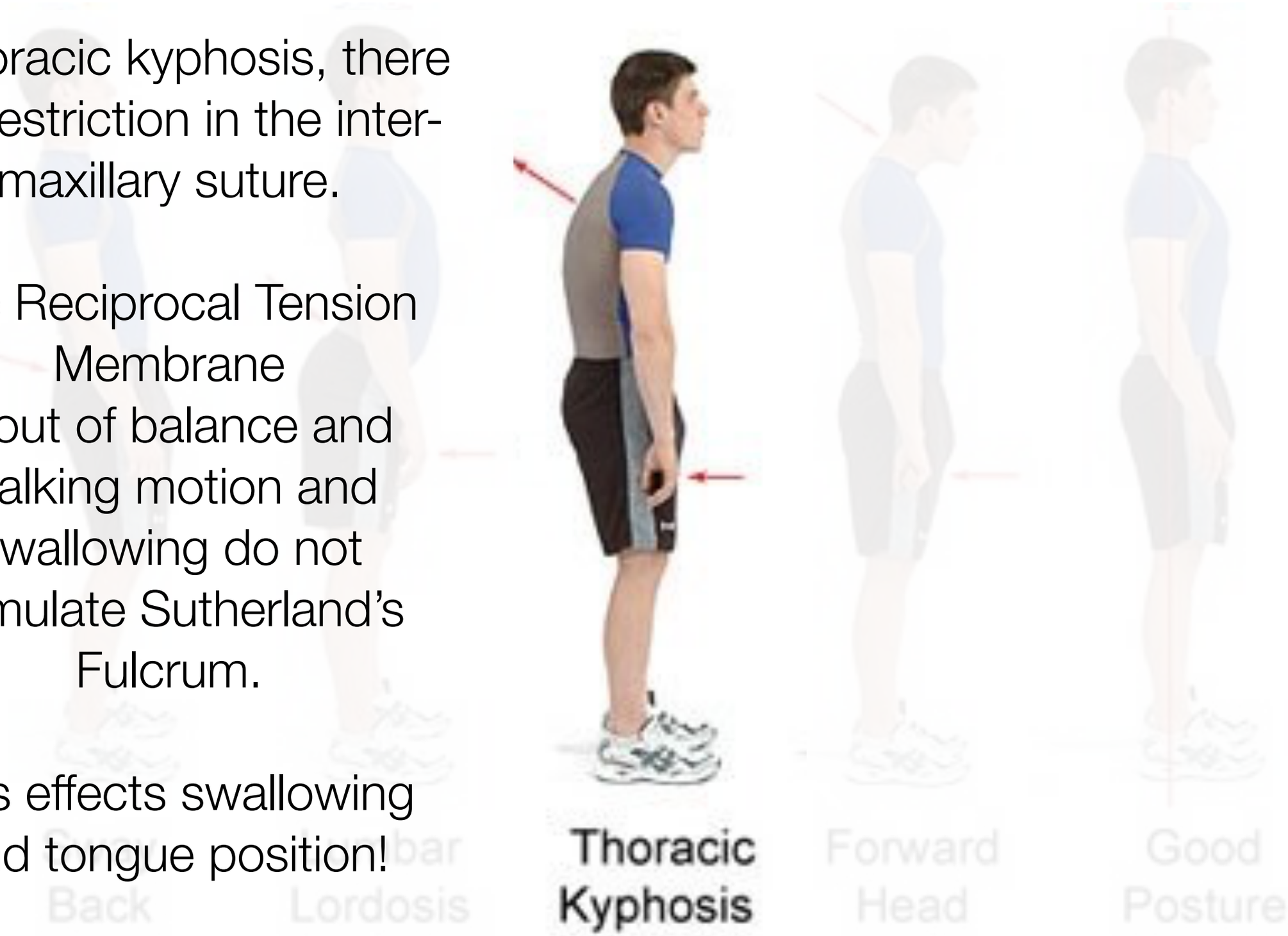

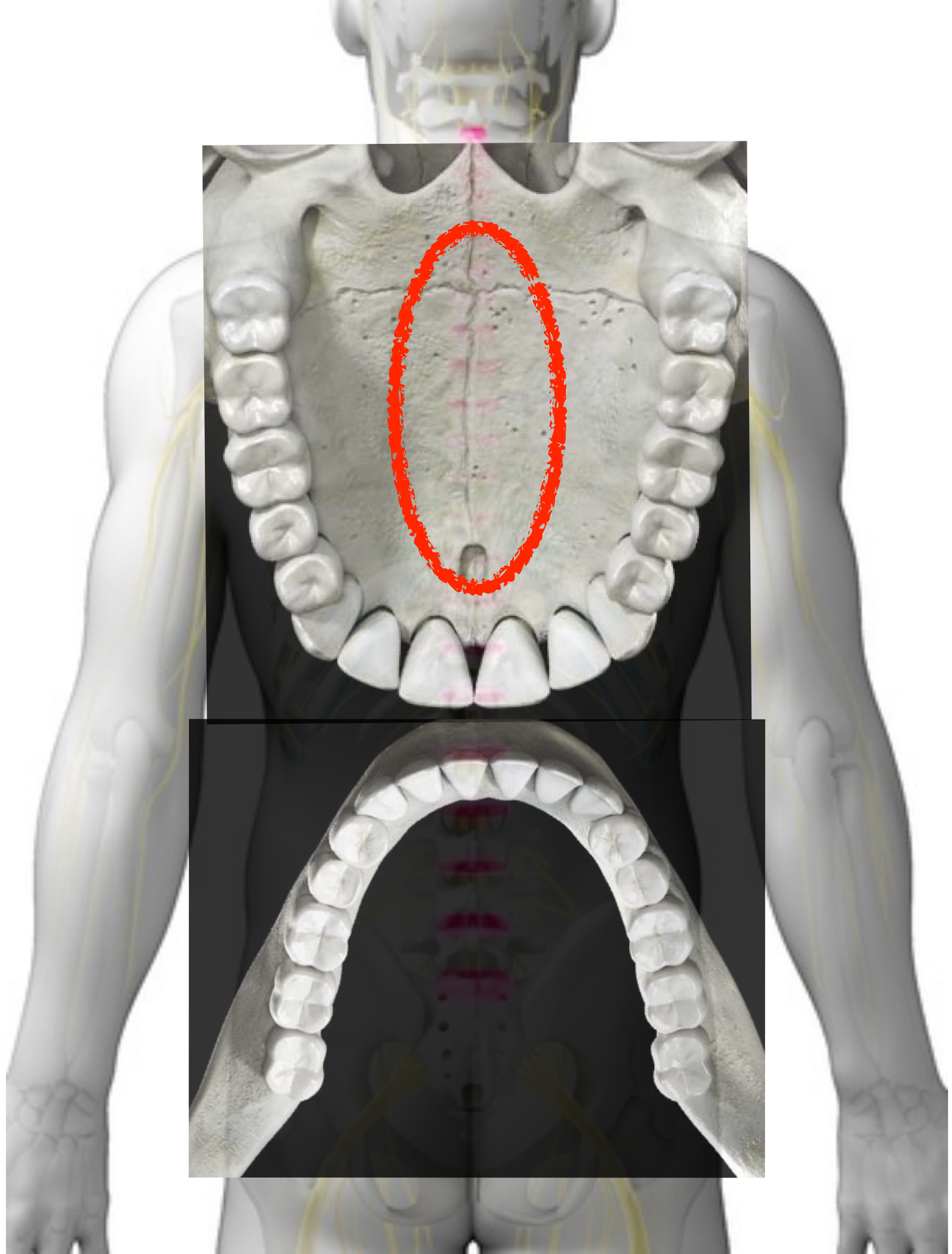

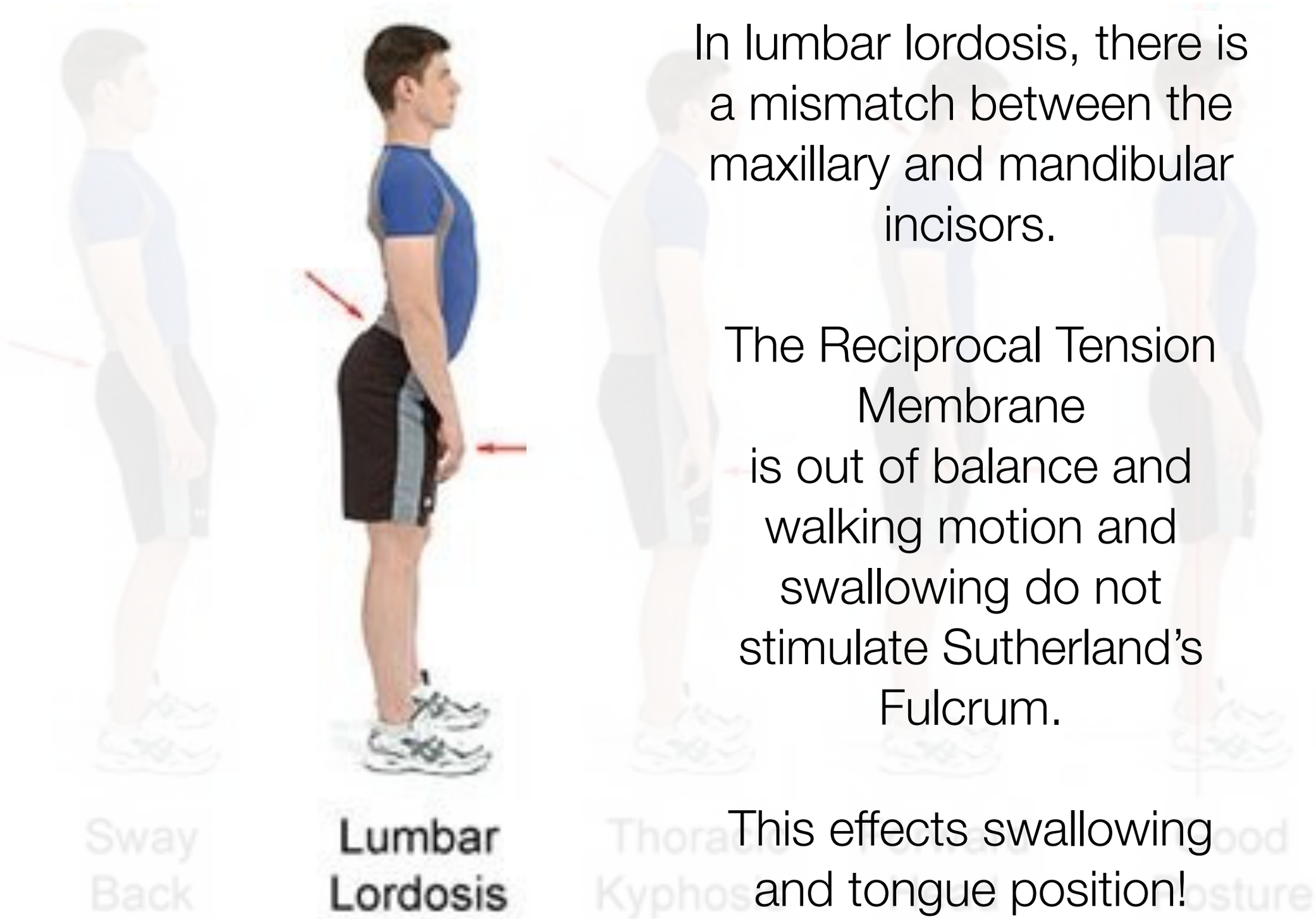

In lumbar lordosis, there is a mismatch between the maxillary and mandibular incisors.

The Reciprocal Tension Membrane
is out of balance and walking motion and swallowing do not stimulate Sutherland's Fulcrum.

This effects swallowing and tongue position!

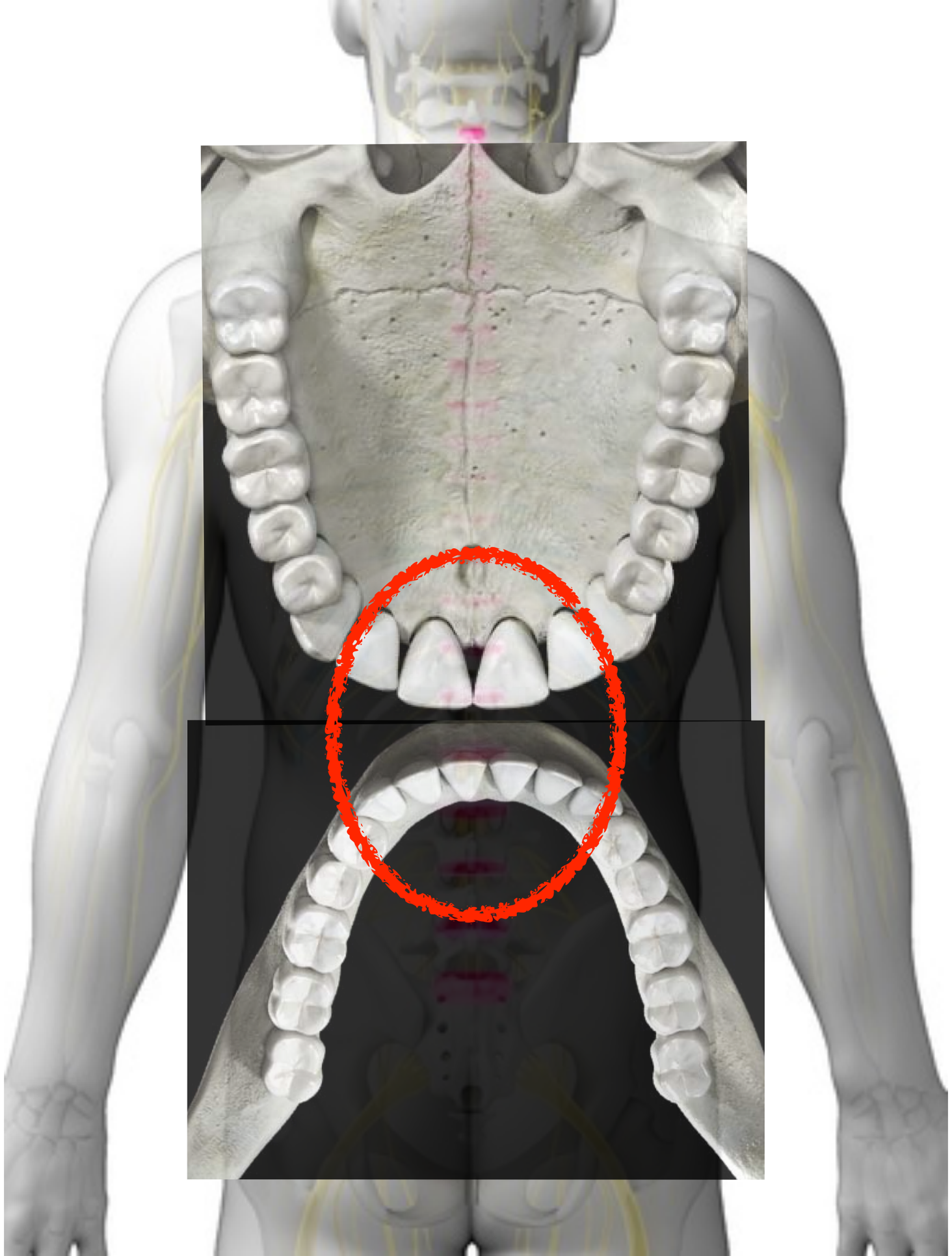

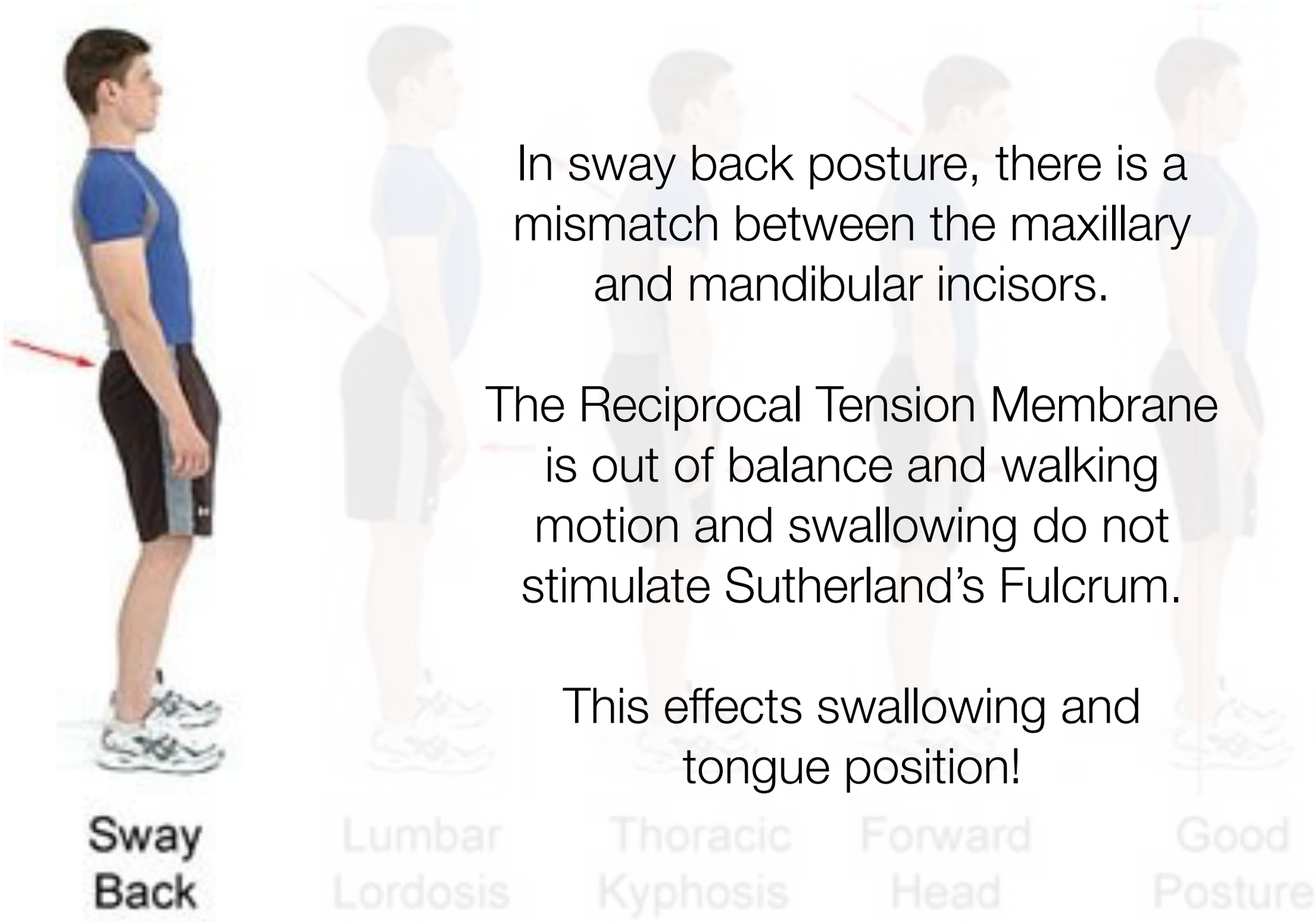

In sway back posture, there is a mismatch between the maxillary and mandibular incisors.

The Reciprocal Tension Membrane is out of balance and walking motion and swallowing do not stimulate Sutherland's Fulcrum.

This effects swallowing and tongue position!

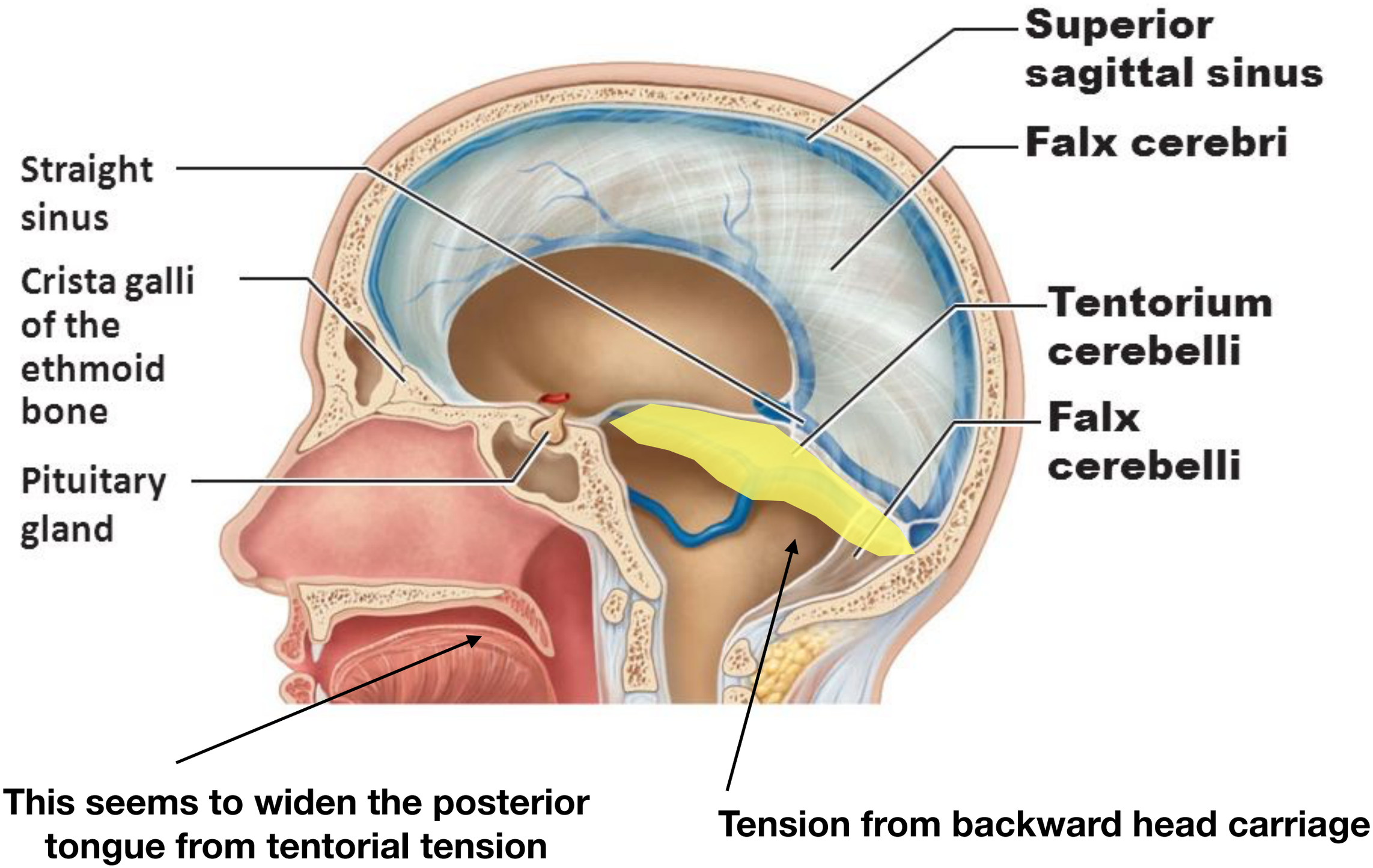
Superior sagittal sinus
Falx cerebri
Straight sinus
Crista galli of the ethmoid bone
Tentorium cerebelli
Falx cerebelli
Pituitary gland
This seems to widen the posterior tongue from tentorial tension
Tension from backward head carriage

Tongue Connection

Muscle Tension Here

Relates to Tongue Tension Here

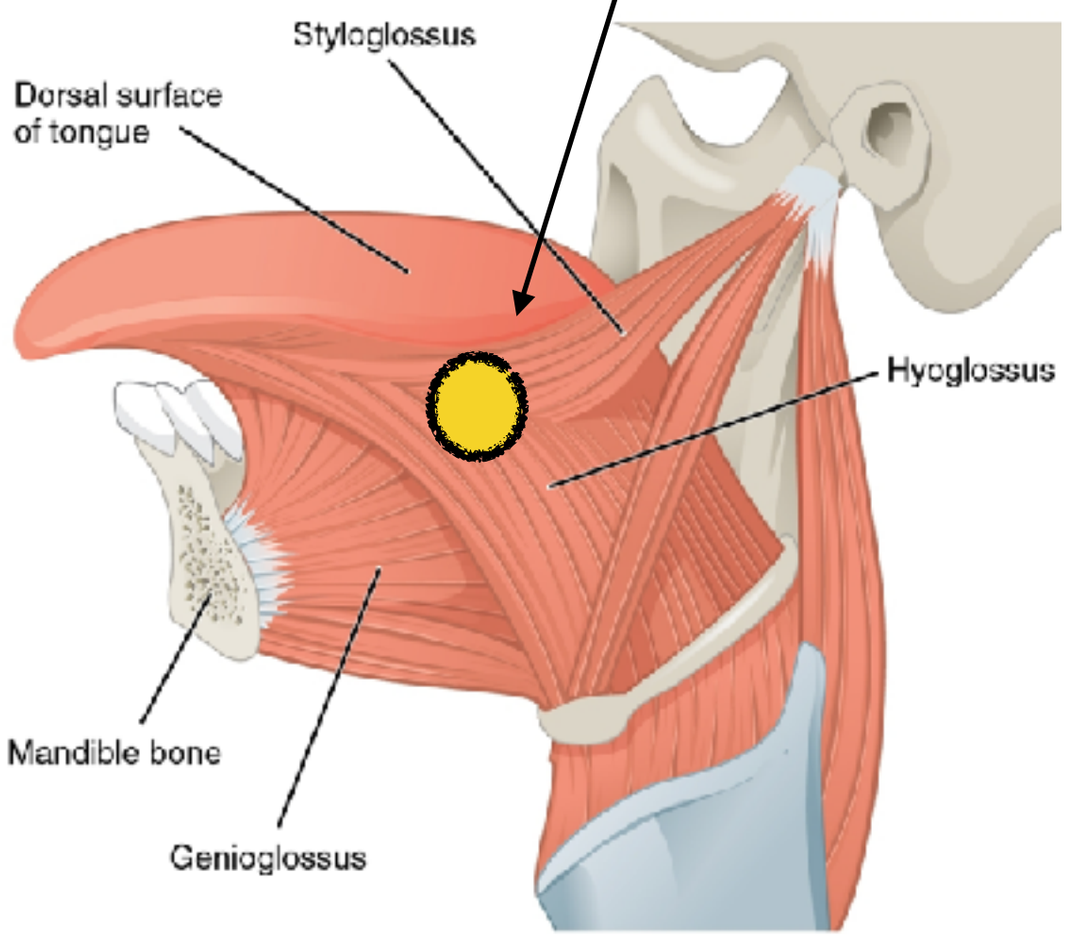

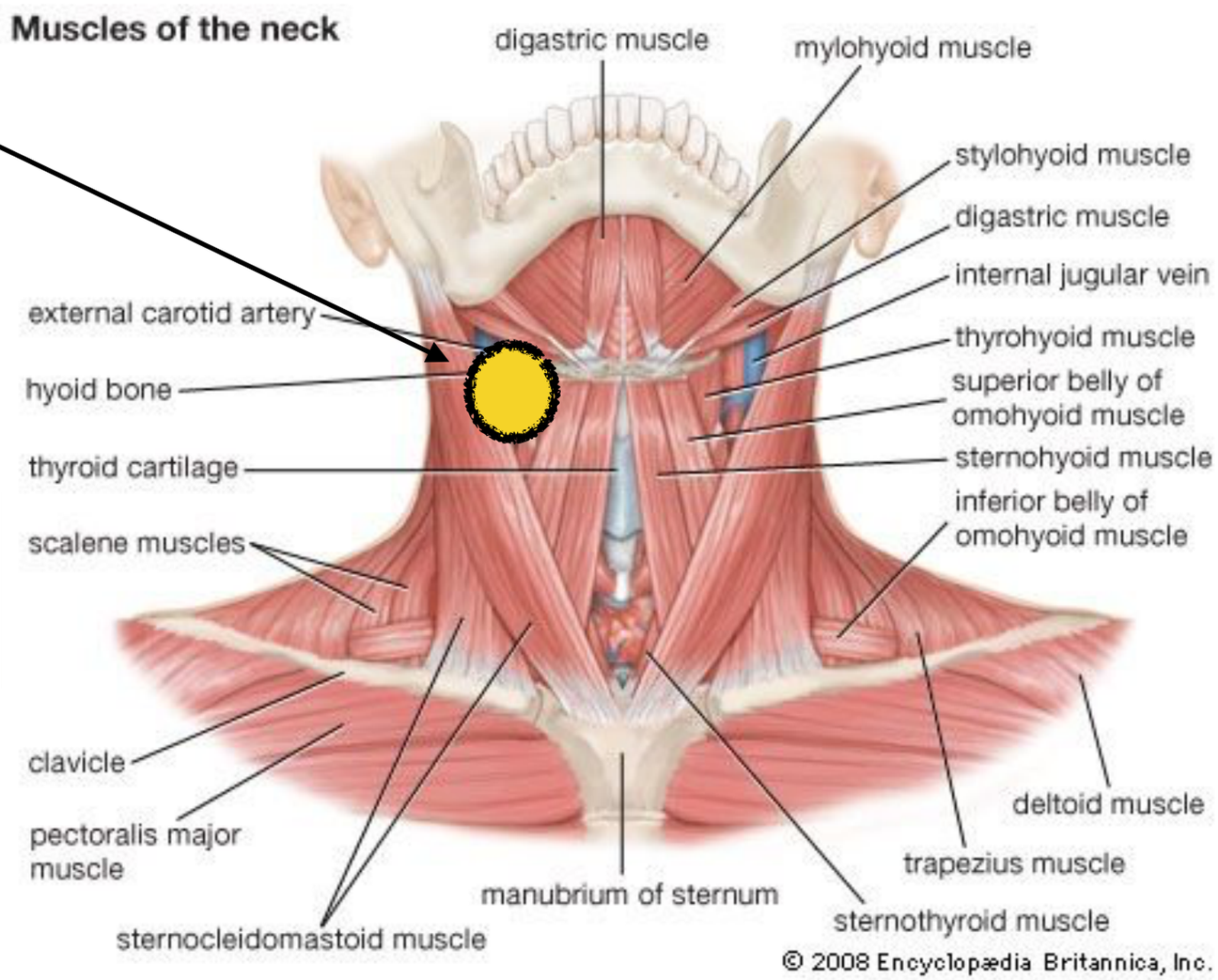

"How does a tongue tie affect so many things? Torticollis, scoot crawling, recessed chins, forward head posture, dowager's humps and scoliosis? It's mind boggling!"

"Well, the tongue is connected to your entire body. It is like the rudder of the spine. When it's out of alignment, other body parts can go off kilter and cause issues that seem unrelated."

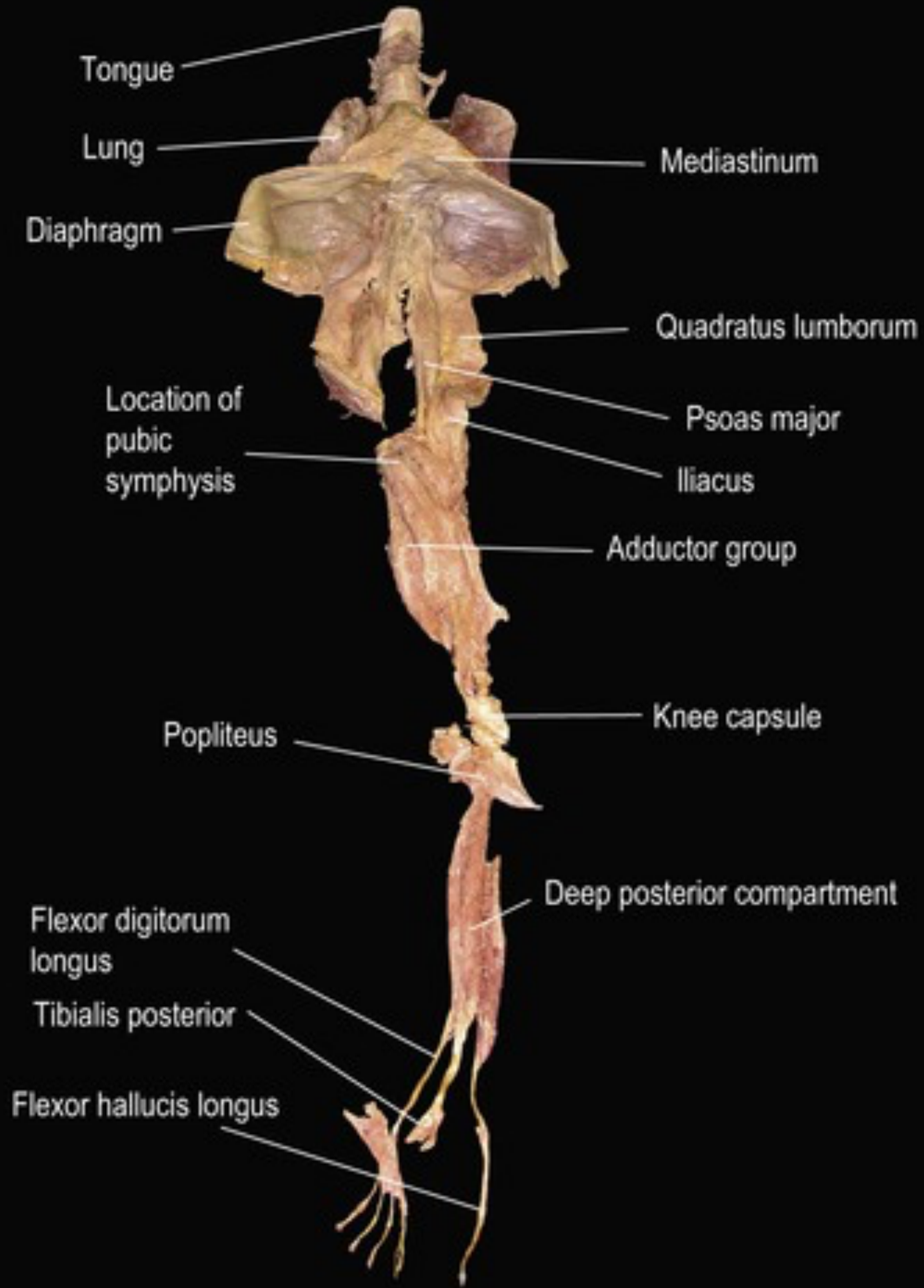

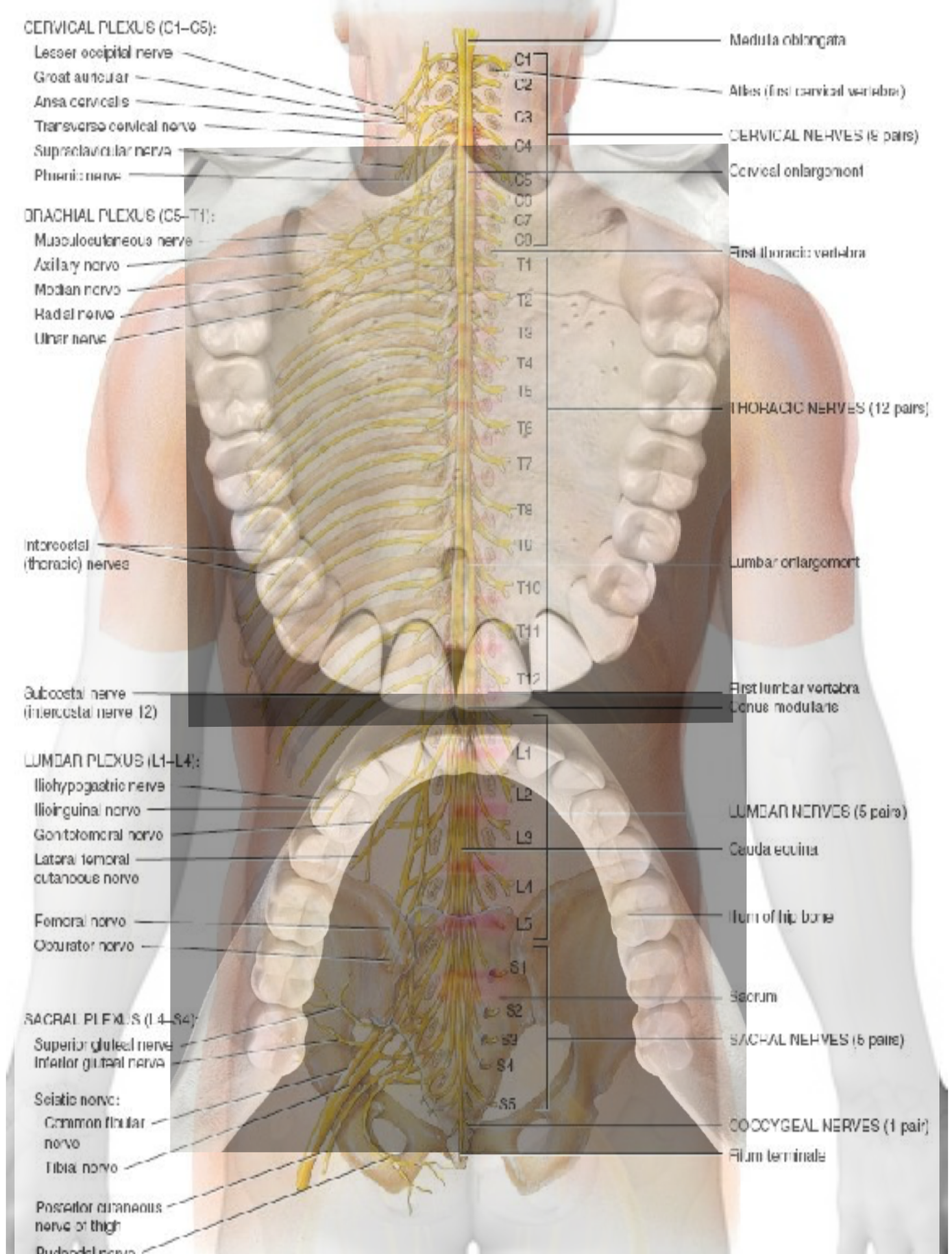
CERVICAL PLEXUS (C1–C5):
Lesser occipital nerve
Great auricular
Ansa cervicalis
Transverse cervical nerve
Supraclavicular nerve
Phrenic nerve
BRACHIAL PLEXUS (C5–T1):
Musculocutaneous nerve
Axillary nerve
Median nerve
Radial nerve
Ulnar nerve
Intercostal (thoracic) nerves
Subcostal nerve (intercostal nerve 12)
LUMBAR PLEXUS (L1–L4):
Iliohypogastric nerve
Ilioinguinal nerve
Genitofemoral nerve
Lateral femoral cutaneous nerve
Femoral nerve
Obturator nerve
SACRAL PLEXUS (L4–S4):
Superior gluteal nerve
Inferior gluteal nerve
Sciatic nerve:
Common fibular nerve
Tibial nerve
Posterior cutaneous nerve of thigh
Pudendal nerve
Medulla oblongata
C1
C2
C3
C4
C5
C6
C7
C8
Atlas (first cervical vertebra)
CERVICAL NERVES (8 pairs)
Cervical enlargement
T1
T2
T3
T4
T5
T6
T7
T8
T9
T10
T11
T12
First thoracic vertebra
THORACIC NERVES (12 pairs)
Lumbar enlargement
First lumbar vertebra
Conus medullaris
L1
L2
L3
L4
L5
LUMBAR NERVES (5 pairs)
Cauda equina
Ilium of hip bone
S1
S2
S3
S4
S5
Sacrum
SACRAL NERVES (5 pairs)
COCCYGEAL NERVES (1 pair)
Filum terminale

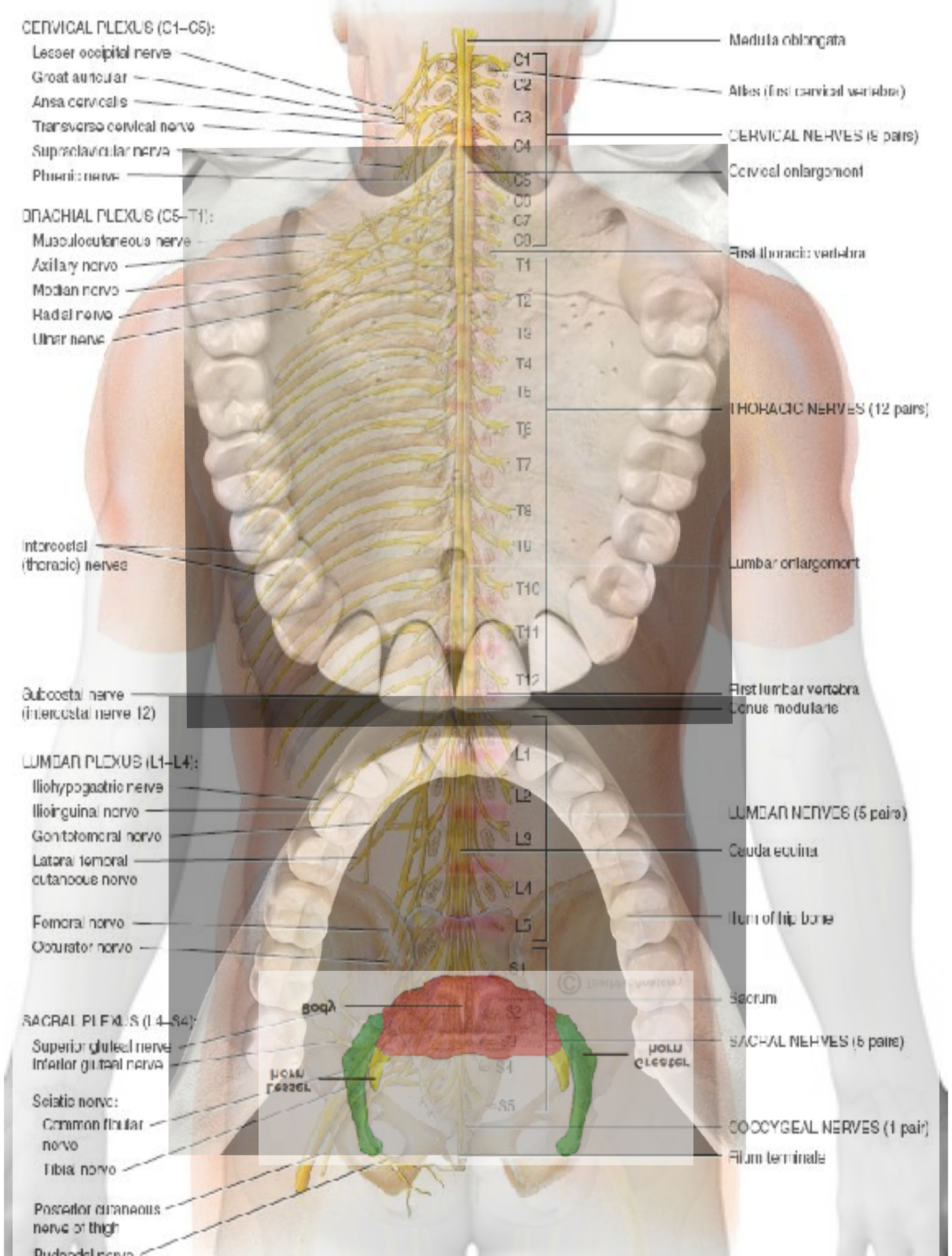
CERVICAL PLEXUS (C1–C5):
Lesser occipital nerve
Great auricular
Ansa cervicalis
Transverse cervical nerve
Supraclavicular nerve
Phrenic nerve
BRACHIAL PLEXUS (C5–T1):
Musculocutaneous nerve
Axillary nerve
Median nerve
Radial nerve
Ulnar nerve
Intercostal (thoracic) nerves
Subcostal nerve (intercostal nerve 12)
LUMBAR PLEXUS (L1–L4):
Iliohypogastric nerve
Ilioinguinal nerve
Genitofemoral nerve
Lateral femoral cutaneous nerve
Femoral nerve
Obturator nerve
SACRAL PLEXUS (L4–S4):
Superior gluteal nerve
Inferior gluteal nerve
Sciatic nerve:
Common fibular nerve
Tibial nerve
Posterior cutaneous nerve of thigh
Pudendal nerve
Medulla oblongata
Atlas (first cervical vertebra)
CERVICAL NERVES (8 pairs)
Cervical enlargement
First thoracic vertebra
THORACIC NERVES (12 pairs)
Lumbar enlargement
First lumbar vertebra
Conus medullaris
LUMBAR NERVES (5 pairs)
Cauda equina
Ilium of hip bone
Sacrum
SACRAL NERVES (5 paire)
COCCYGEAL NERVES (1 pair)
Filum terminale
C1
C2
C3
C4
C5
C6
C7
C8
T1
T2
T3
T4
T5
T6
T7
T8
T9
T10
T11
T12
L1
L2
L3
L4
L5
S1
S2
S3
S4
S5

Let’s look at one way this fits together.

There is a curve here that moves…
with chewing

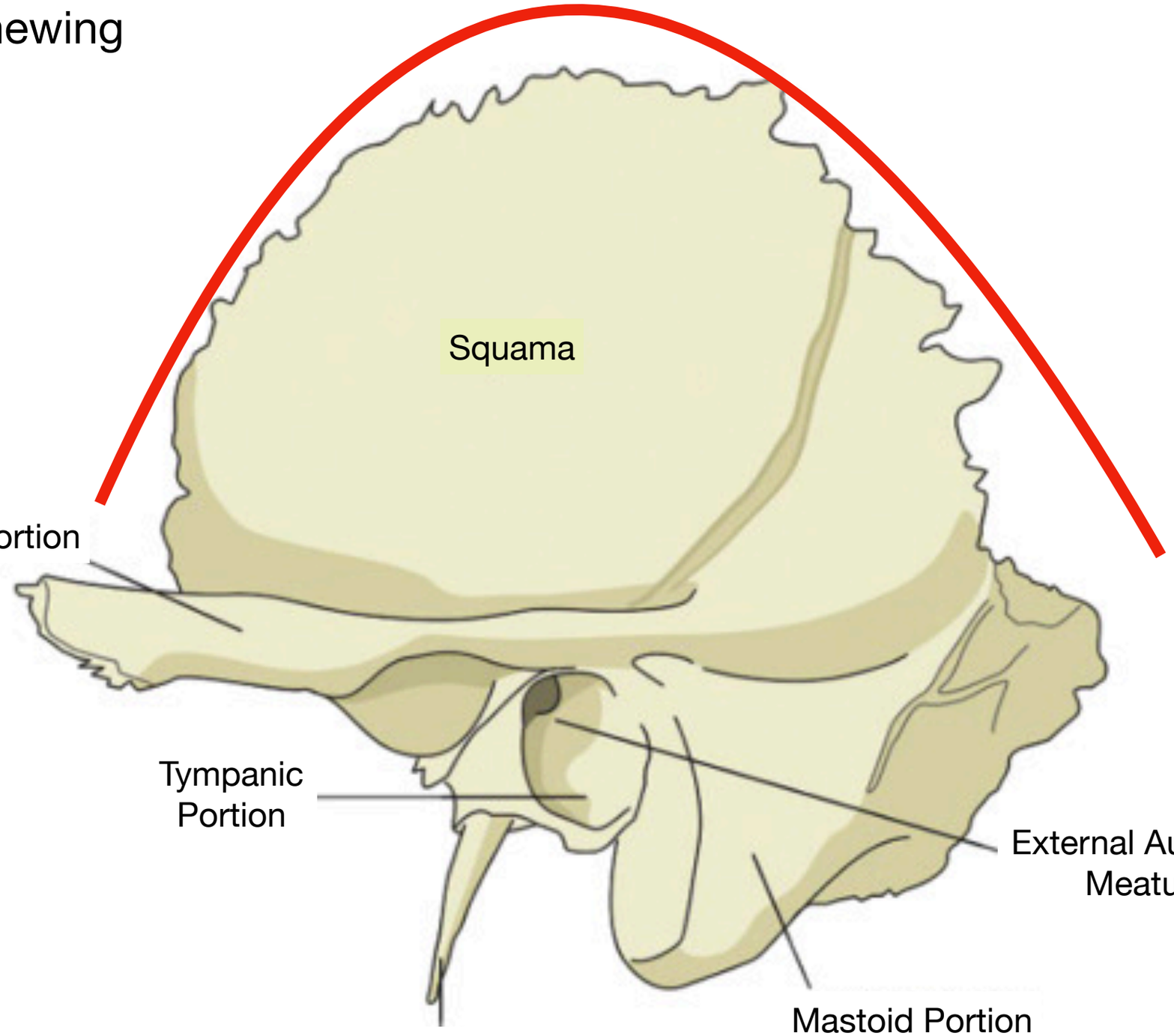

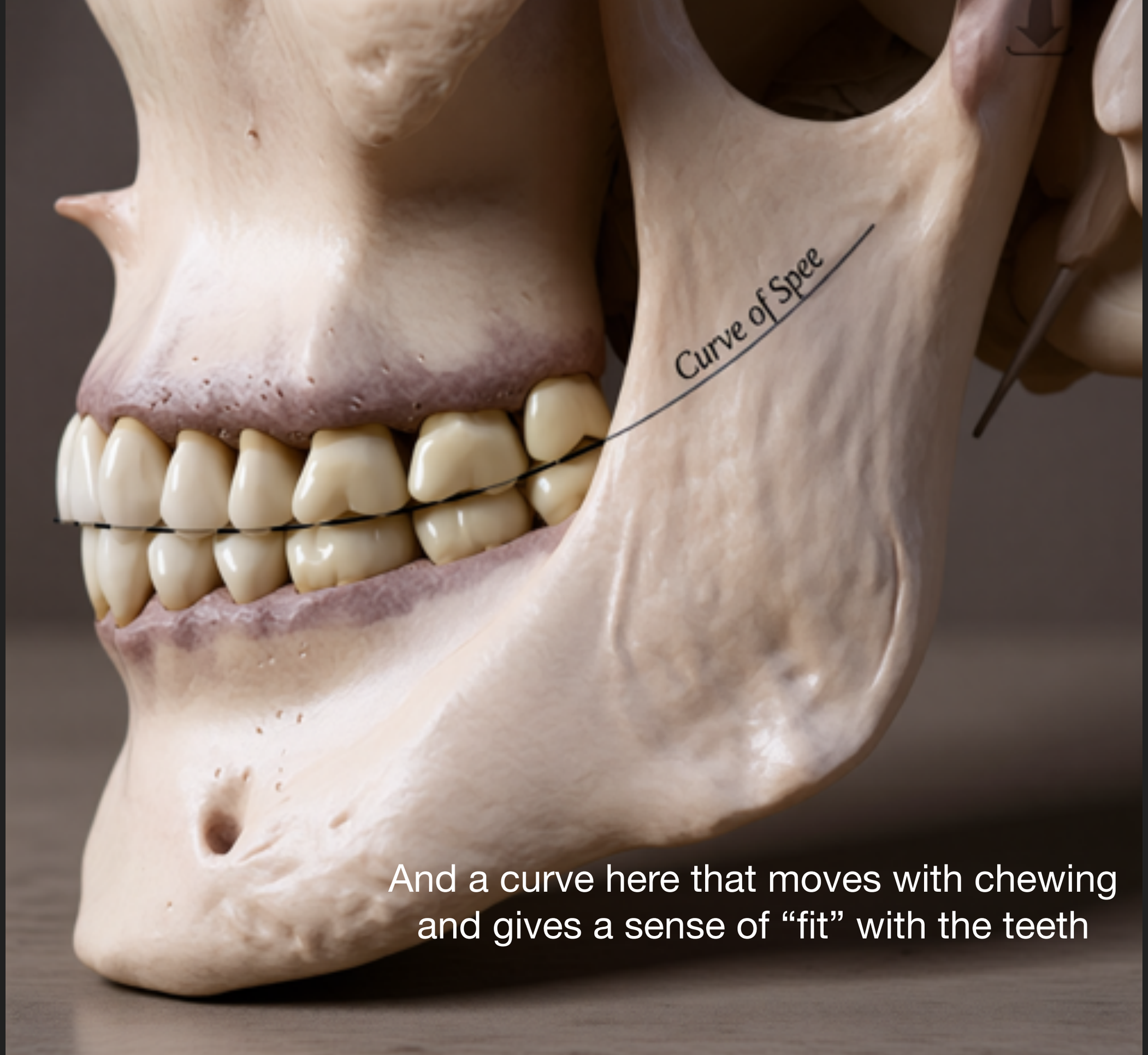

And a curve here that moves with chewing
and gives a sense of “fit” with the teeth

Question

- Notice that they make a rough circle.
- Could that be important?

There is another curve here that moves… with chewing

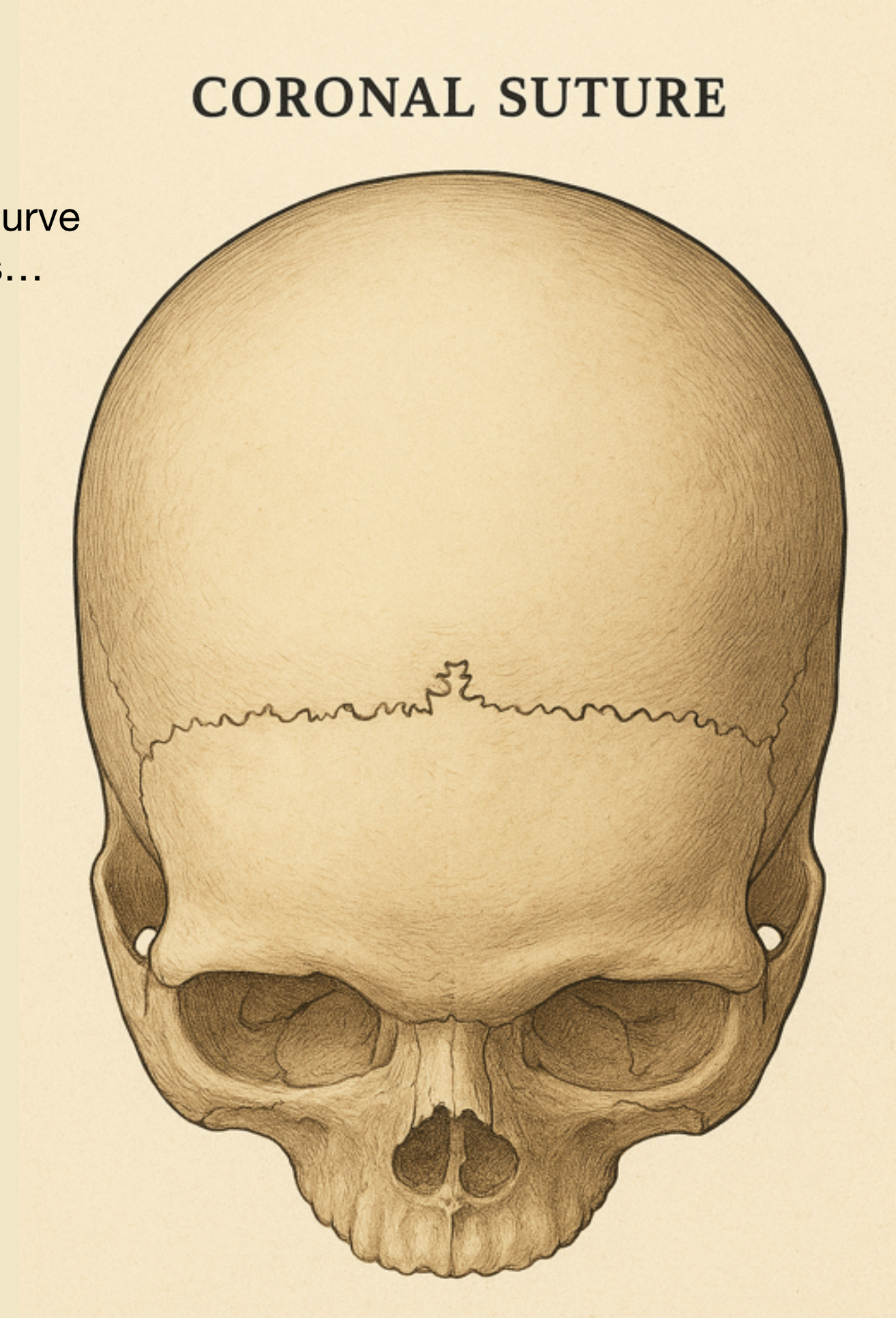

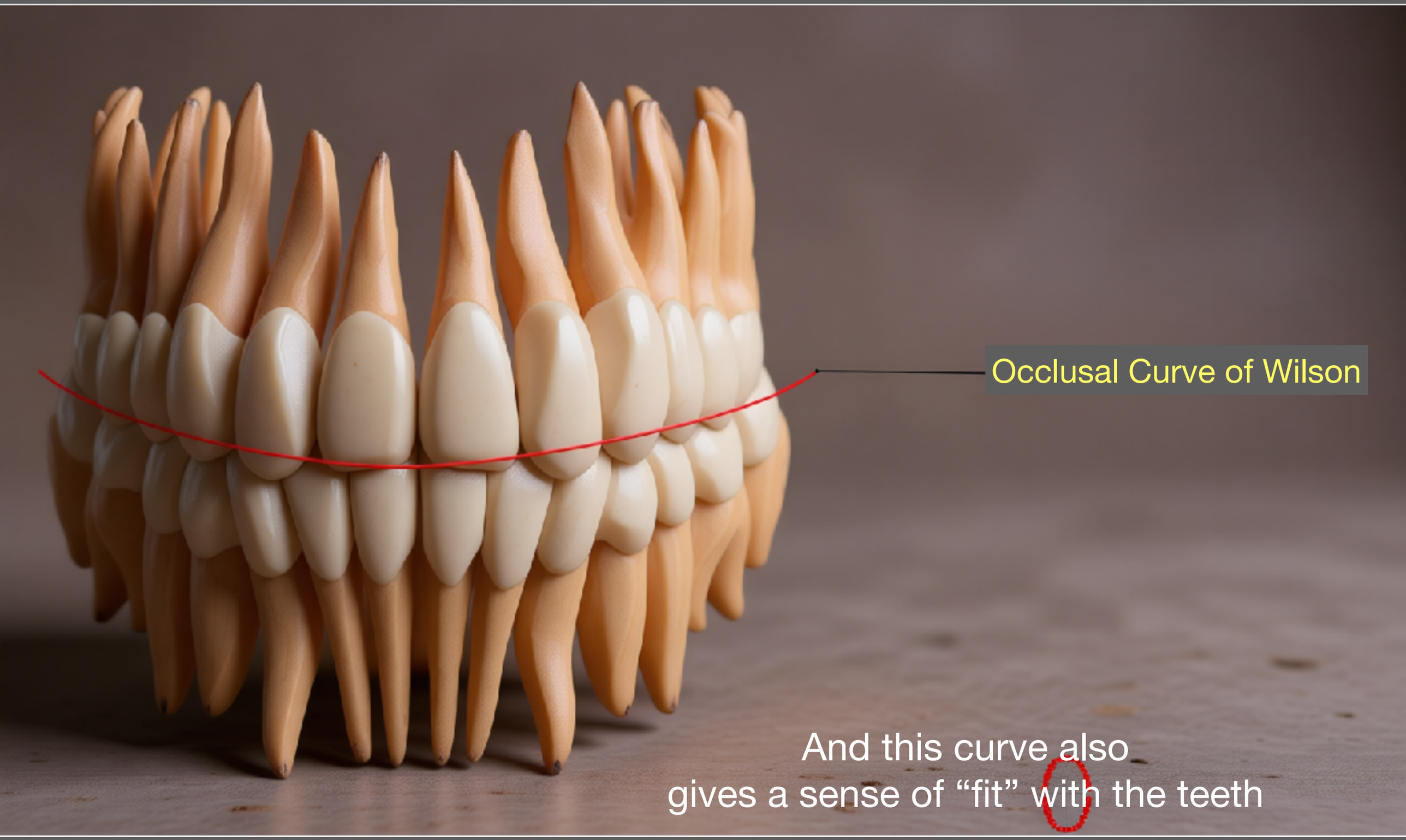
Occlusal Curve of Wilson
And this curve also
gives a sense of “fit” with the teeth

Question

- Notice that they make a rough circle.
- Might that be important?

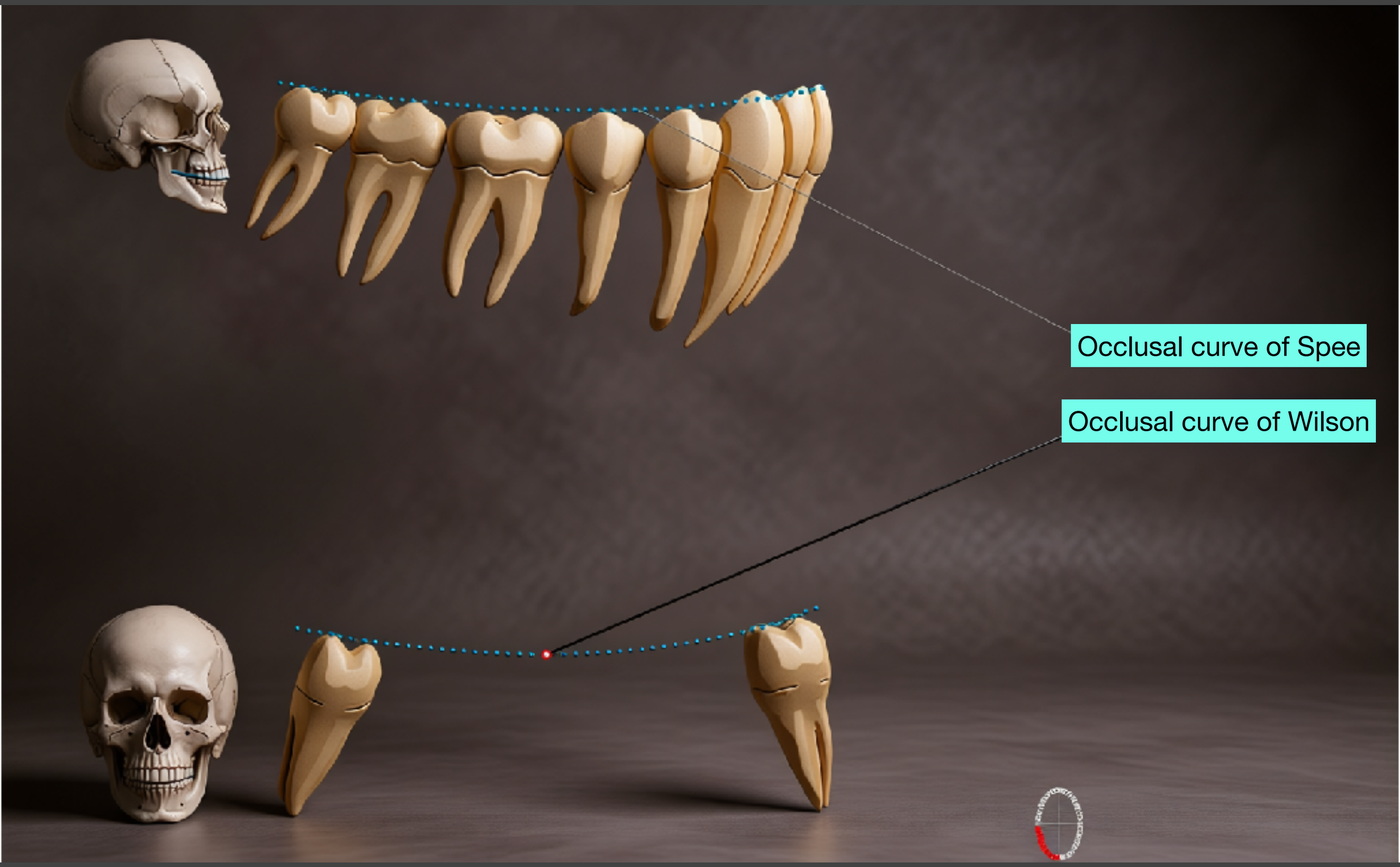

Together, these two curves create a “home” position for the occlusion



This home position allows the jaw to always return to a set place, which helps to down regulate the nervous system.

It is like a cannon ball sitting in its base. It does not move our of resting position easily.

Together with the angles of the teeth in the bone, these curves place the biting force at a point, the curve or sphere of Monson, that, in a perfect head, is focused onto the pituitary gland.

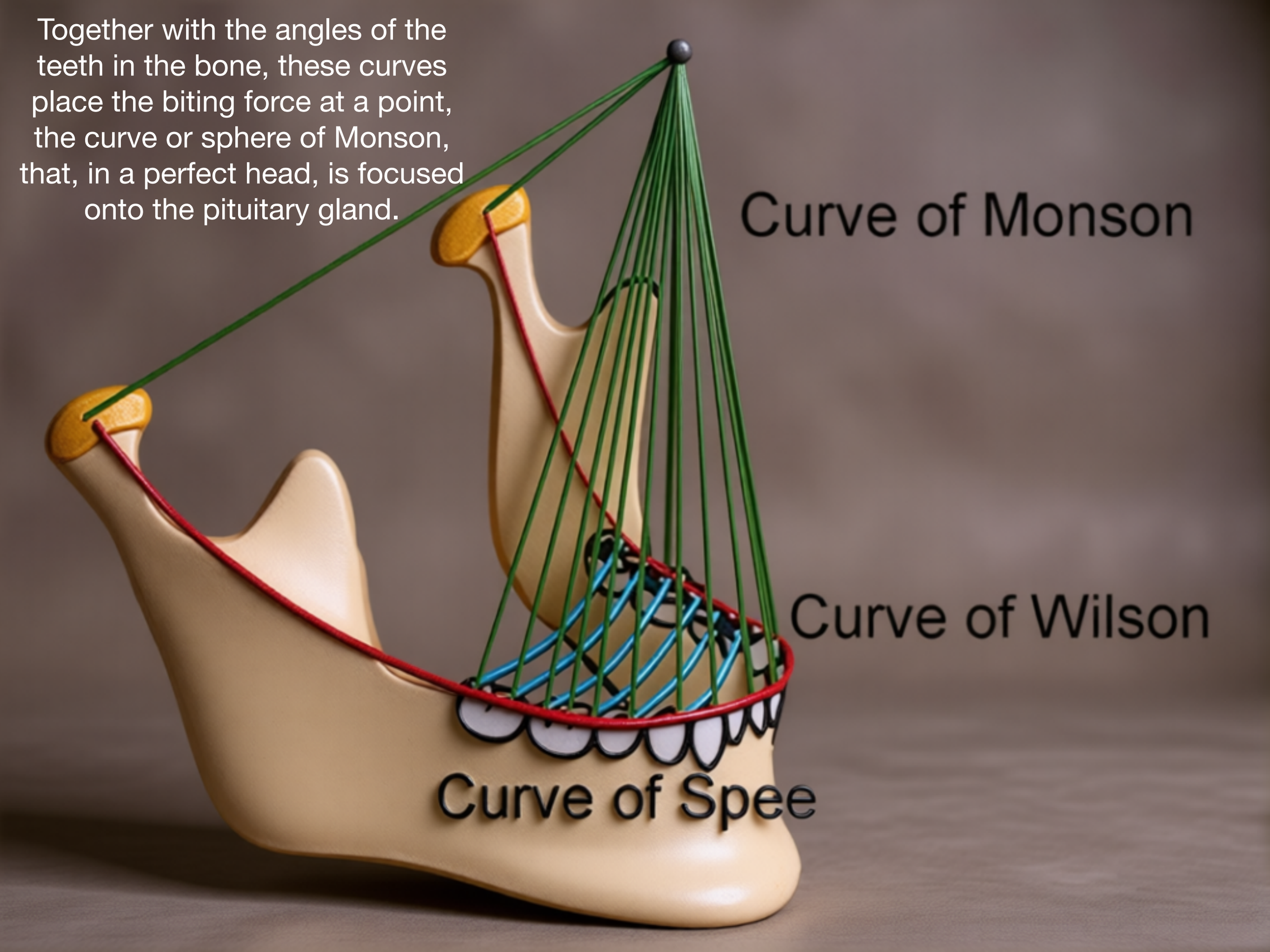

Fitting things together

- That means that the occlusion of the teeth will pump and move the pituitary gland when everything works as it should.
- That gives a new importance to the “S” in the SNA angle (sella), and it brings cephalometric into a different light.

Fitting things together

- As a dentist, how to you get those teeth focused on the sella? How do you know if the curve of Spee or Wilson are optimal for that patient?

- This is where a bodyworker who can feel where the forces come together in the head would be a huge benefit for that patient’s case.

Tongue and Airway Considerations

An Osteopathic Approach

Disclaimer

- Although I may have figured these ideas out (with the help of a dear friend, Mark Westaway, MD, DO (UK), and lots of input from upper management), these are too important to health to lay a “claim” to. PLEASE share them. PLEASE test them and see if they work for you. PLEASE refine them if you feel the need. PLEASE help as many people as you can.

- And please be kind and give credit where it is due.

The Order

- Please play with this to prove to yourself that this is true:
- In this presentation we are going to find data points. There may/could be many more.
- The order that you apply them to the body makes a difference. They are listed here in the order that it seems that the body needs to fully unlock under *my* hands. Play with/test to determine how to make this specific to that patient on your table/chair.
- Again, test this to prove it right or wrong for you.

Where To Begin?

- Typically we would begin a case with images - things that let us see the teeth, roots, surrounding bones, airway, and the three dimensional relationships of all of the involved structures. This may include photos, x-rays, CT scans, etc.

- The more precise we are at taking those images, the more consistent our measurements (and thus treatment) can be.

- We can measure the space between teeth, angles that let us determine relationships between bony structures and examine the health of the TMJ.

An I-CAT Cone Beam CT (CBCT) scan is a good place to start with imaging.

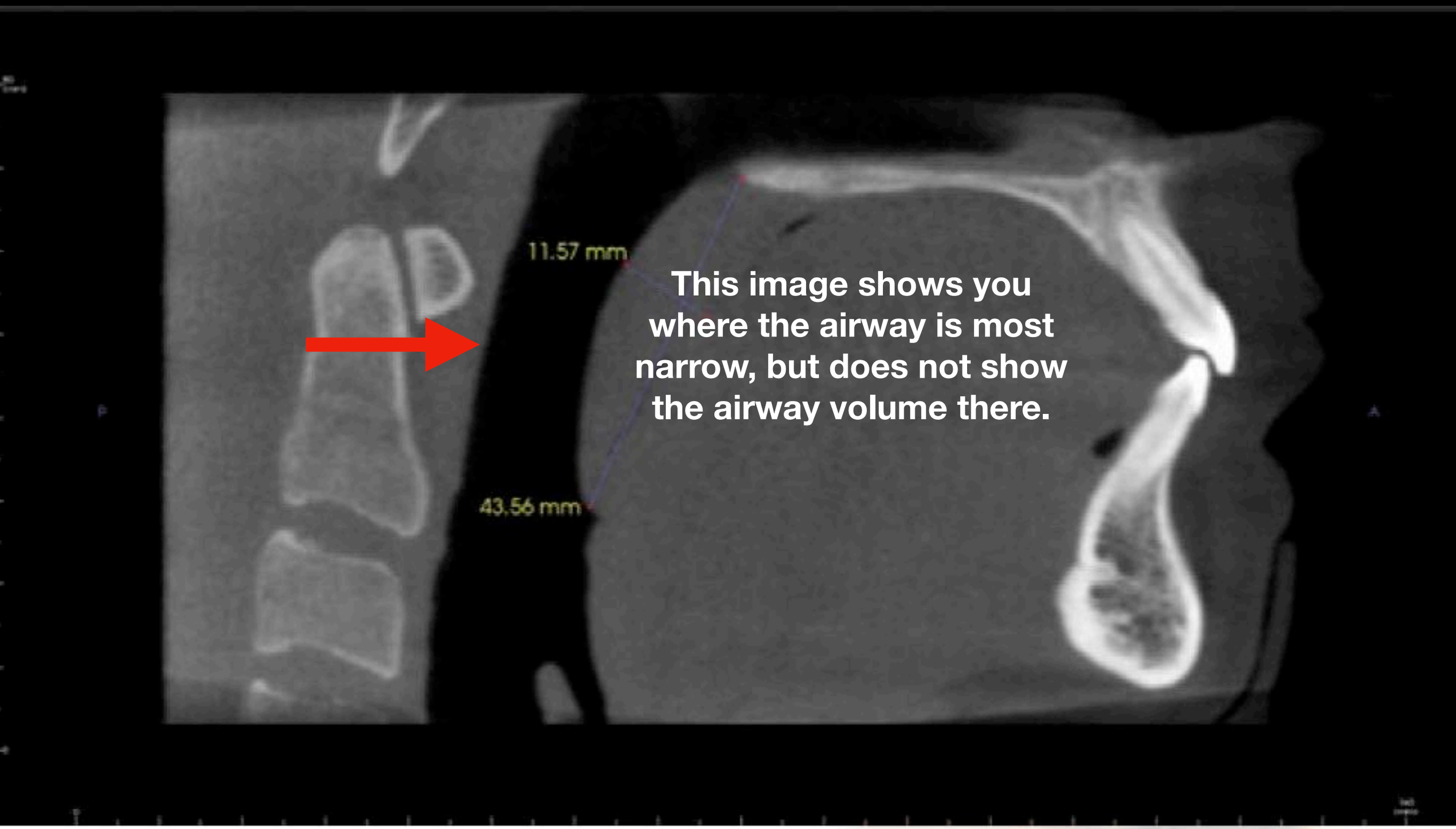

Figure 2A: Sagittal slice showing patient with large soft palate.

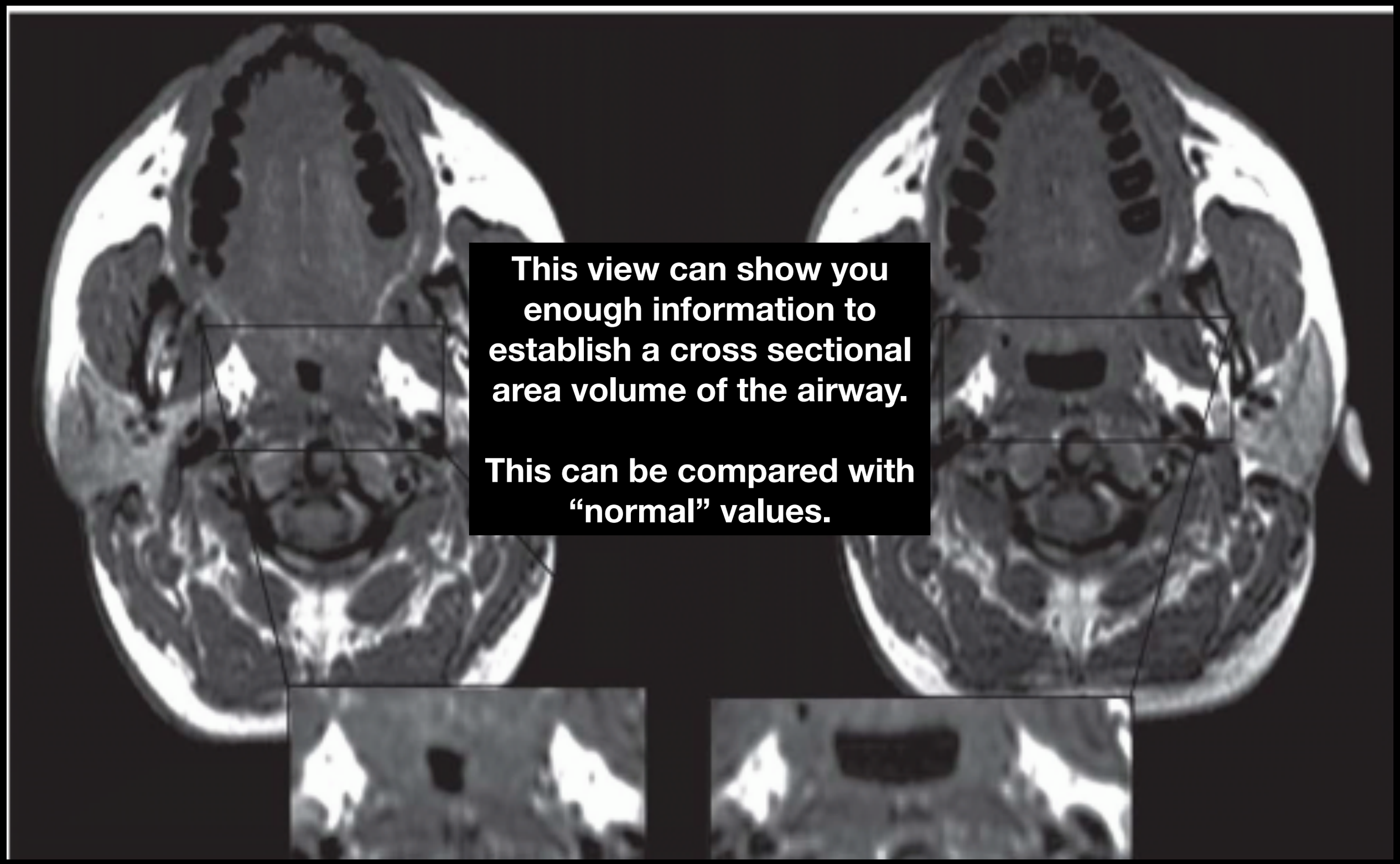

These measurements of the airway tell you about volume, but DO NOT indicate function.

Cephalometrics

The Pituitary Gland sits inside the **Sella Tursica.** This measurement begins at the midpoint of the pituitary gland.

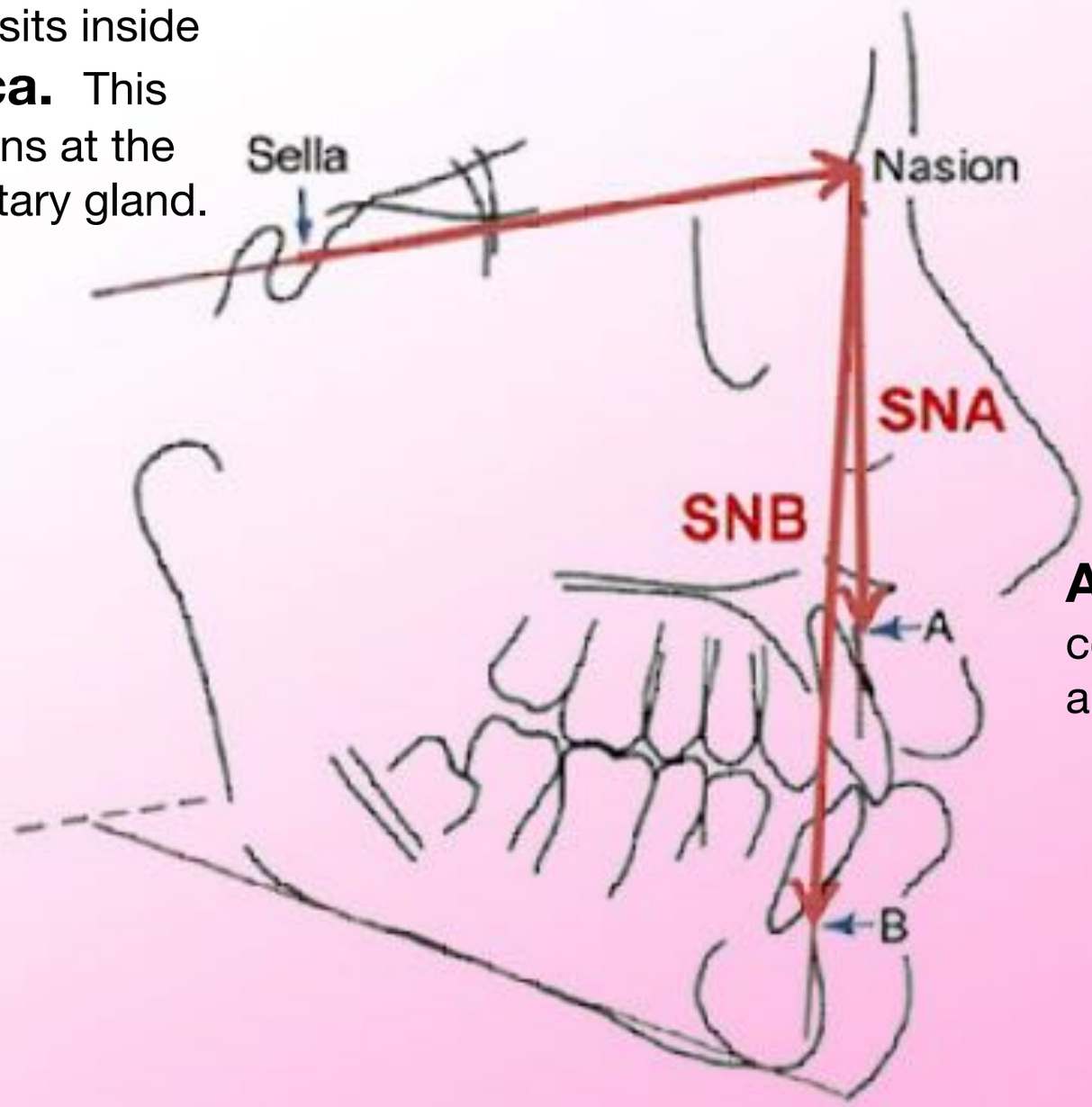

Nasion is the most anterior point of the frontonasal suture that joins the nasal part of the frontal bone and the nasal bones.

A Point is the most concave point of the anterior maxilla.

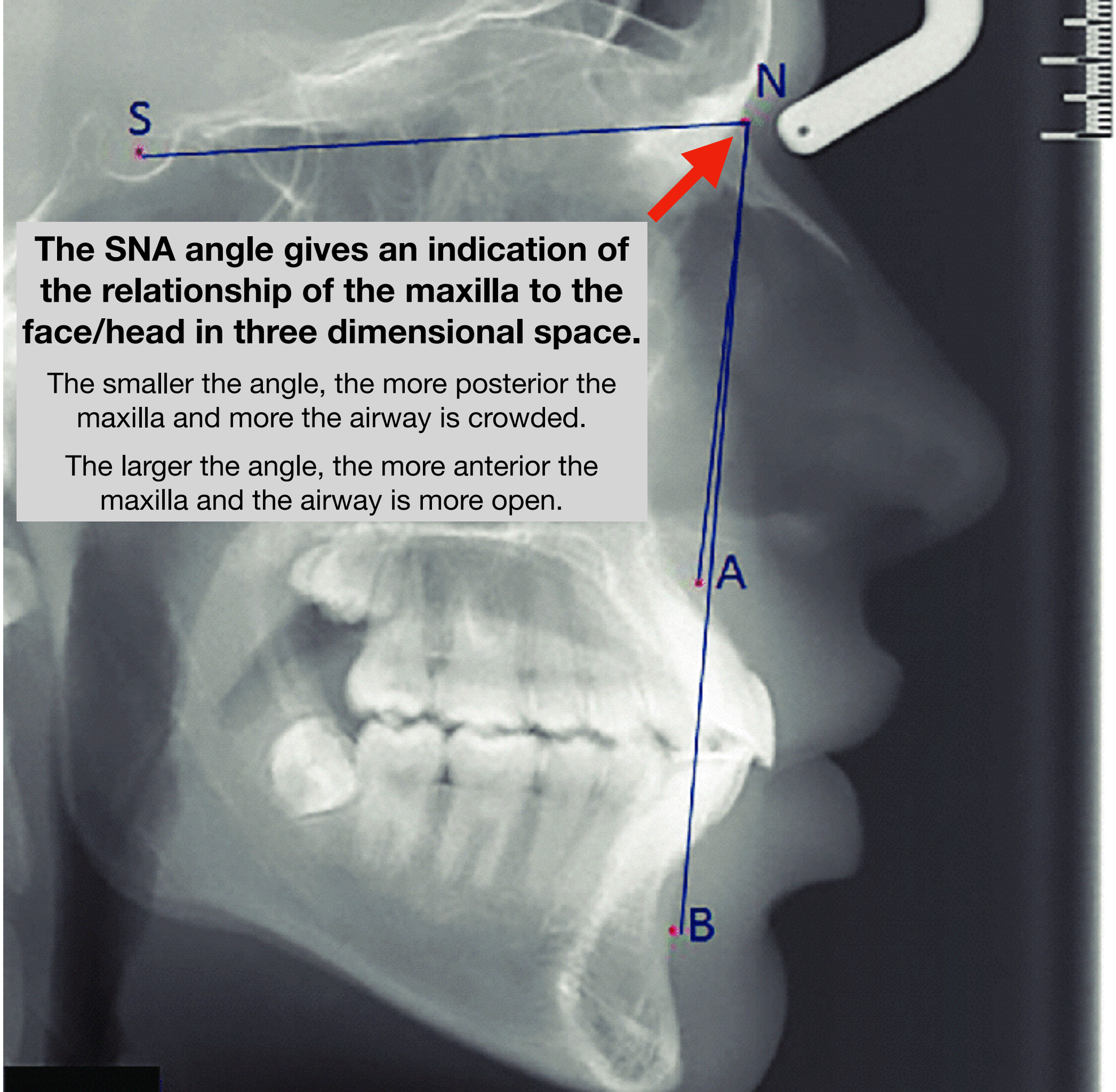

The SNA angle gives an indication of the relationship of the maxilla to the face/head in three dimensional space.

The smaller the angle, the more posterior the maxilla and more the airway is crowded.

The larger the angle, the more anterior the maxilla and the airway is more open.

Principles

- Once we have measurements, we can come up with a left brained idea of what the mouth/teeth/head need. (Don't forget that this creates an ASSUMPTION that we understand what is going on in a way that thoughts = application = results).

- But our measurements don't necessarily equate to proper function or consistent results. For this we will need feedback from the body. These are principles that can be applied everywhere.

The Interface

- These measurements allow dentists to measure where the patient starts and where the end point is (with some possible mid points as well).

- As osteopaths, we tend not to think that way. Most of our training is based upon feel (not measurements). This testing allows us to bridge the gap with the dentist. We can test to determine guidelines (numbers) to assist the dentist in appliance design and adjustment.

Intermolar Width

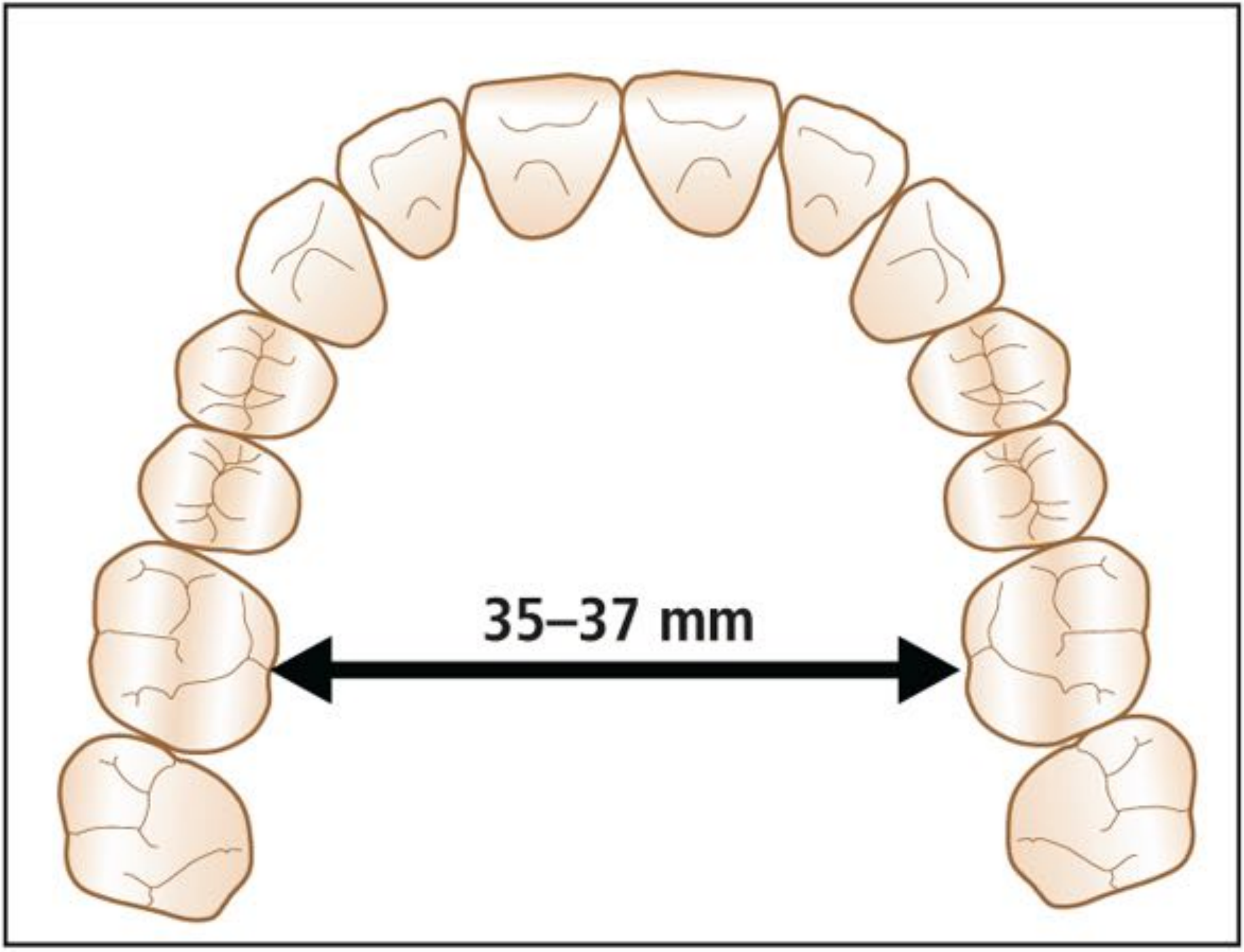
35–37 mm

Intermolar Width

- The measurement between the 1st molars is 35-38mm in the adult male when optimal. According to the dental model, this is the preferred width of the inter molar spacing.

- How do we test that osteopathically?

Intermolar Width

- Place the index and middle finger from each hand on each side of the occiptomastoid suture.
- Clearly in your mind ask the question - “what happens if I add 1mm to the current intermolar width between the 1st molars?” and palpate the result.
- Then go to 2, 3, 4, etc. and see which gives freedom to the occipitomastoid suture.
- This is a fluid layer palpation.

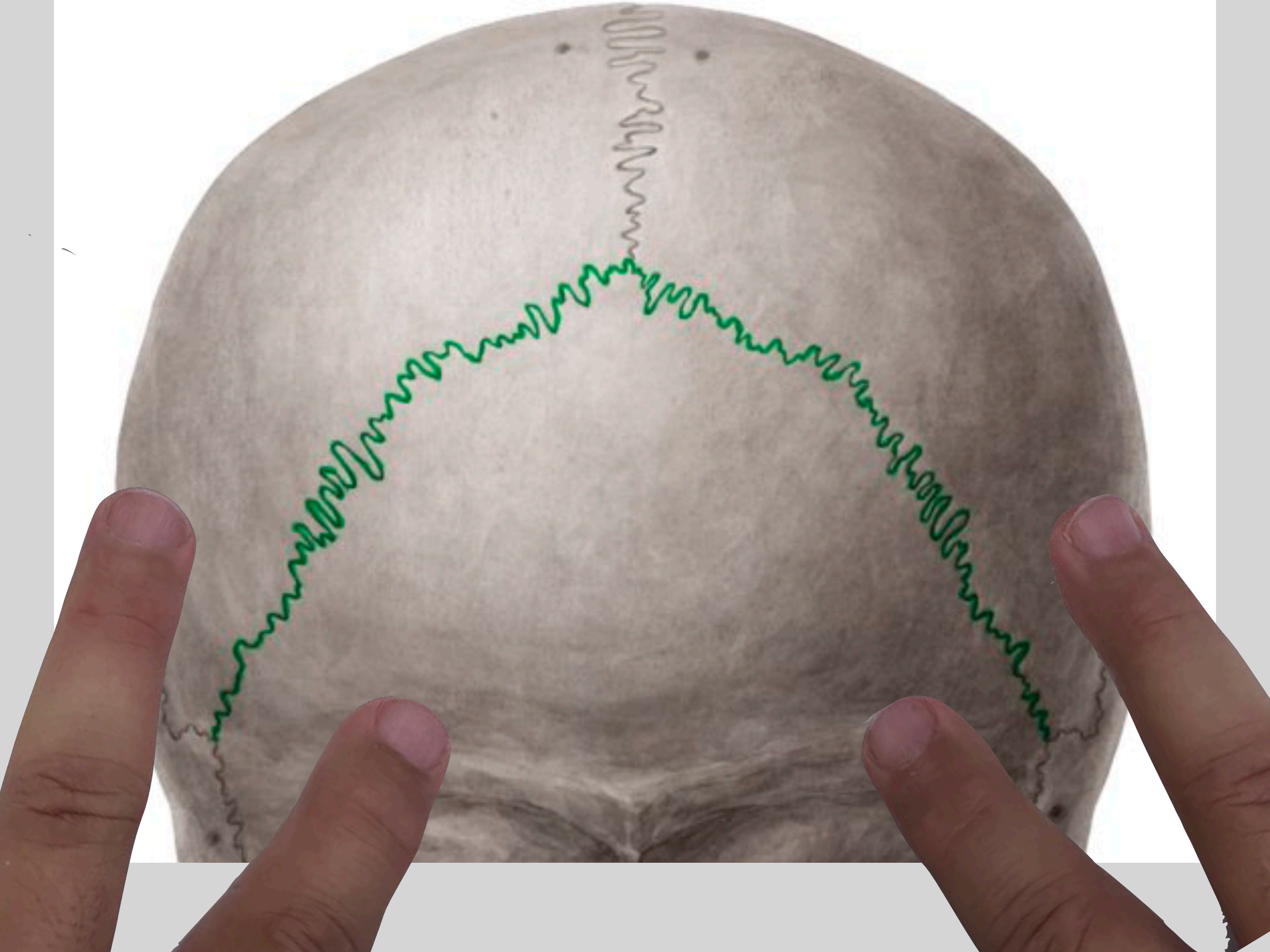

Intermolar Width

- The result is the body's preference. Whatever the number, it must also meet (and not exceed) the requirements of the dentist.

- For example, if the body says it wants 50mm, that greatly exceeds the optimal dental width. That may indicate that the body needs significant treatment BEFORE it is able to give you a reasonable width.

- If the dentist says 38mm and the body says 39mm or 40mm, listen to the body and work with the dentist to achieve that measurement.

Intermolar Width

- When the body achieves this optimal intermolar width for that particular person, the occipitomastoid suture (one of the controllers of the TMJ) will be optimized in its cranial motion - it will be in neutral.

- If you add too much or too little width, one or both sides of the O/M suture will become restricted. You can palpate this if you intentionally go over the optimal width (this is like straddling a fence - each direction other than optimal will induce a strain).

Tooth Height

Tooth Height

- How do we assess if the height of the teeth (maxillary and mandibular) are optimal for that patient osteopathically?

- If the teeth are not high enough, a strong biting force can cause the sphenoid to flex (body will move in relation to the greater wings). This can then put pressure on the alar ligaments of the dens and, in extreme cases, cause a hangman's fracture. Think of this in the case of worn dentures…especially in someone with ligament laxity (eg. Downs Syndrome).

Tooth Height

- The closest dental term for what we are measuring is called freeway space, interocclusal clearance or interocclusal space.
- It would be more precise in terminology by saying that we are looking for the stacked height of the upper and lower teeth in mm on very gentle occlusion. This height is going to give the mandible a position in three dimensional space that will either inhibit the motion of the bones of the head (if too small or too large) or optimize the bony movement when it is perfect for that patient.

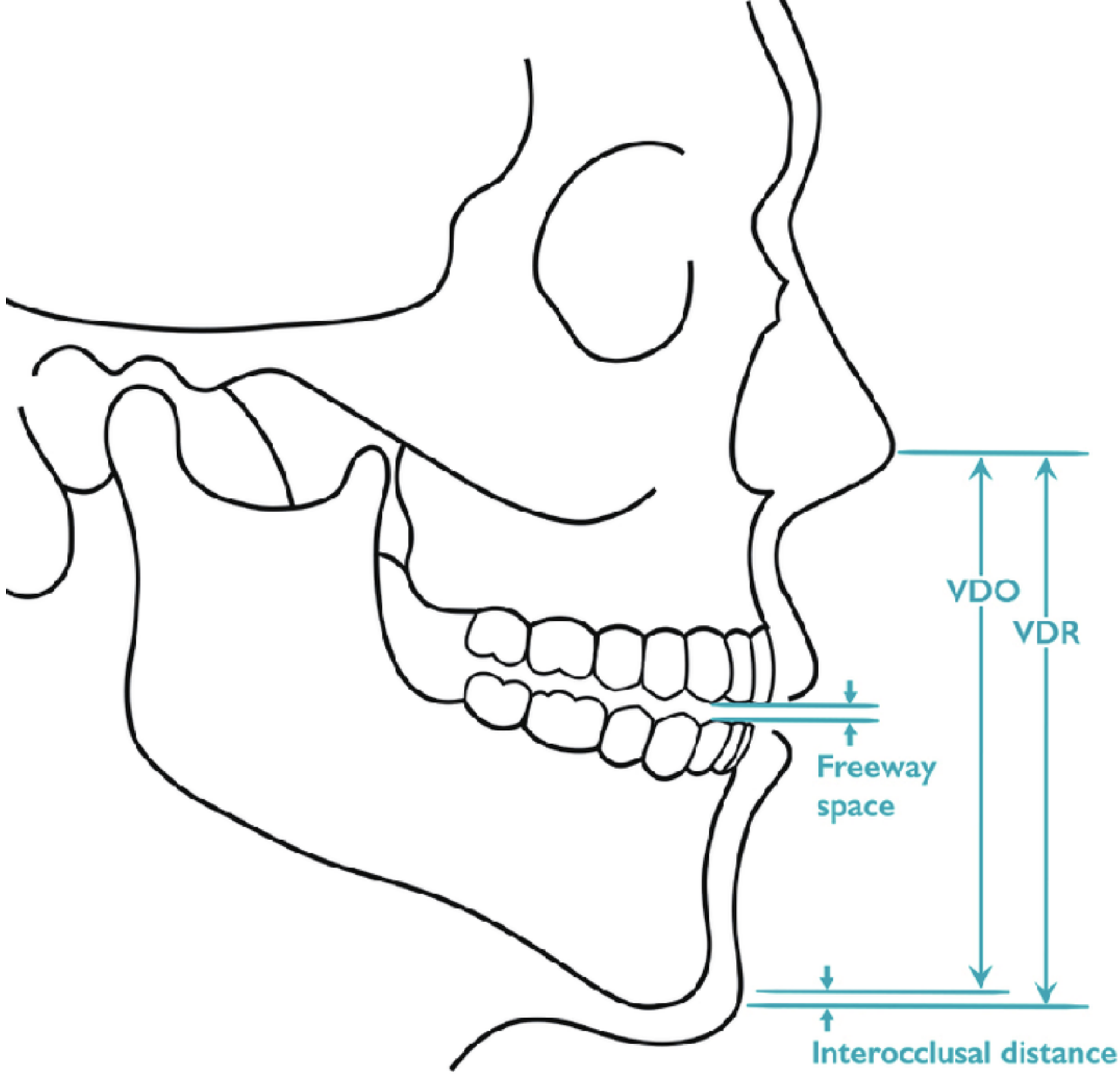
VDO
VDR
Freeway
space
Interocclusal distance

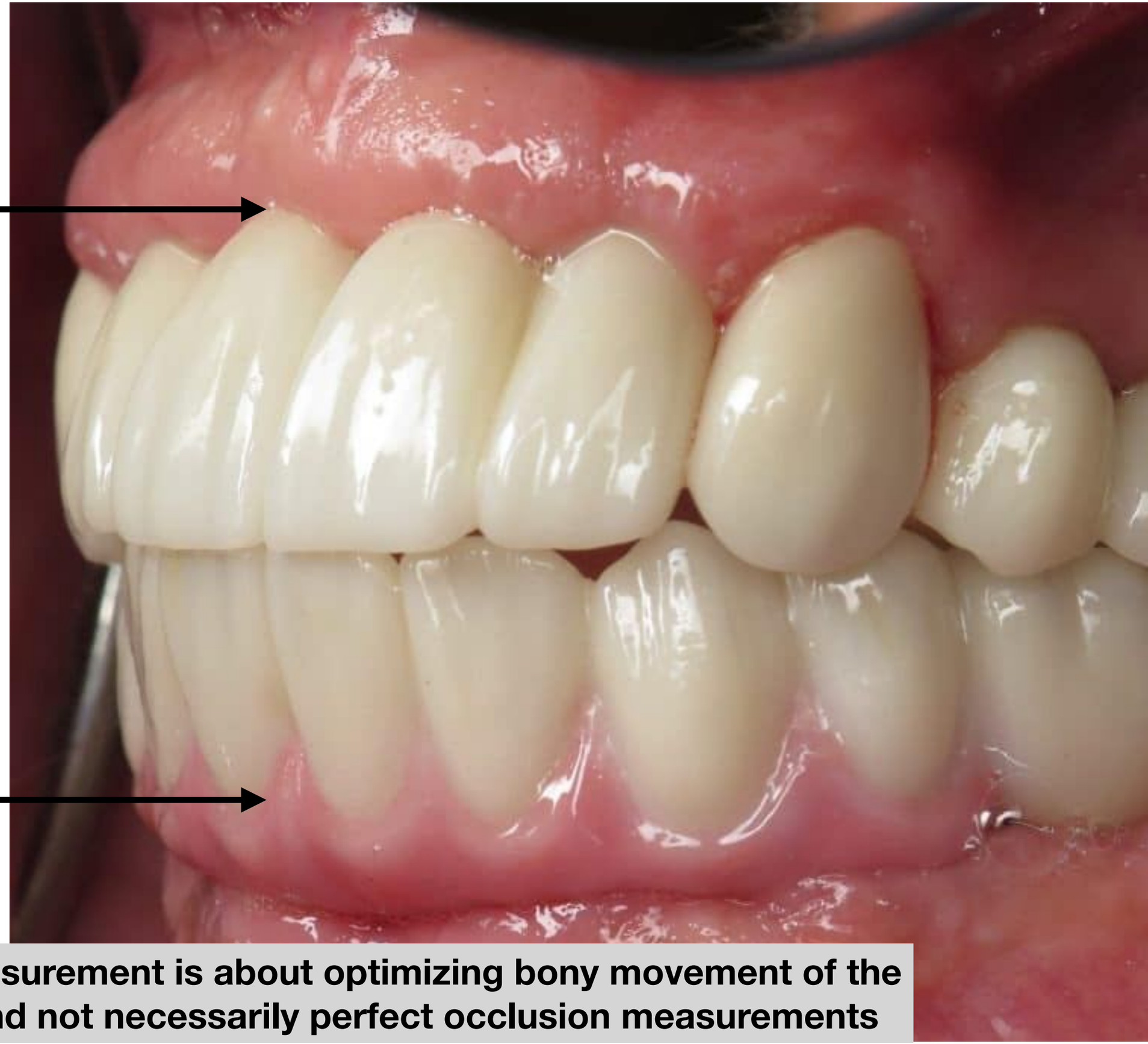

Distance in mm

This measurement is about optimizing bony movement of the head and not necessarily perfect occlusion measurements

Tooth Height

- We can assess by testing the movement of the bilateral mastoid portions of the temporals/occiput in an anterior/posterior motion.
- If they move freely in BOTH directions, then the height of the teeth is optimal for that patent.

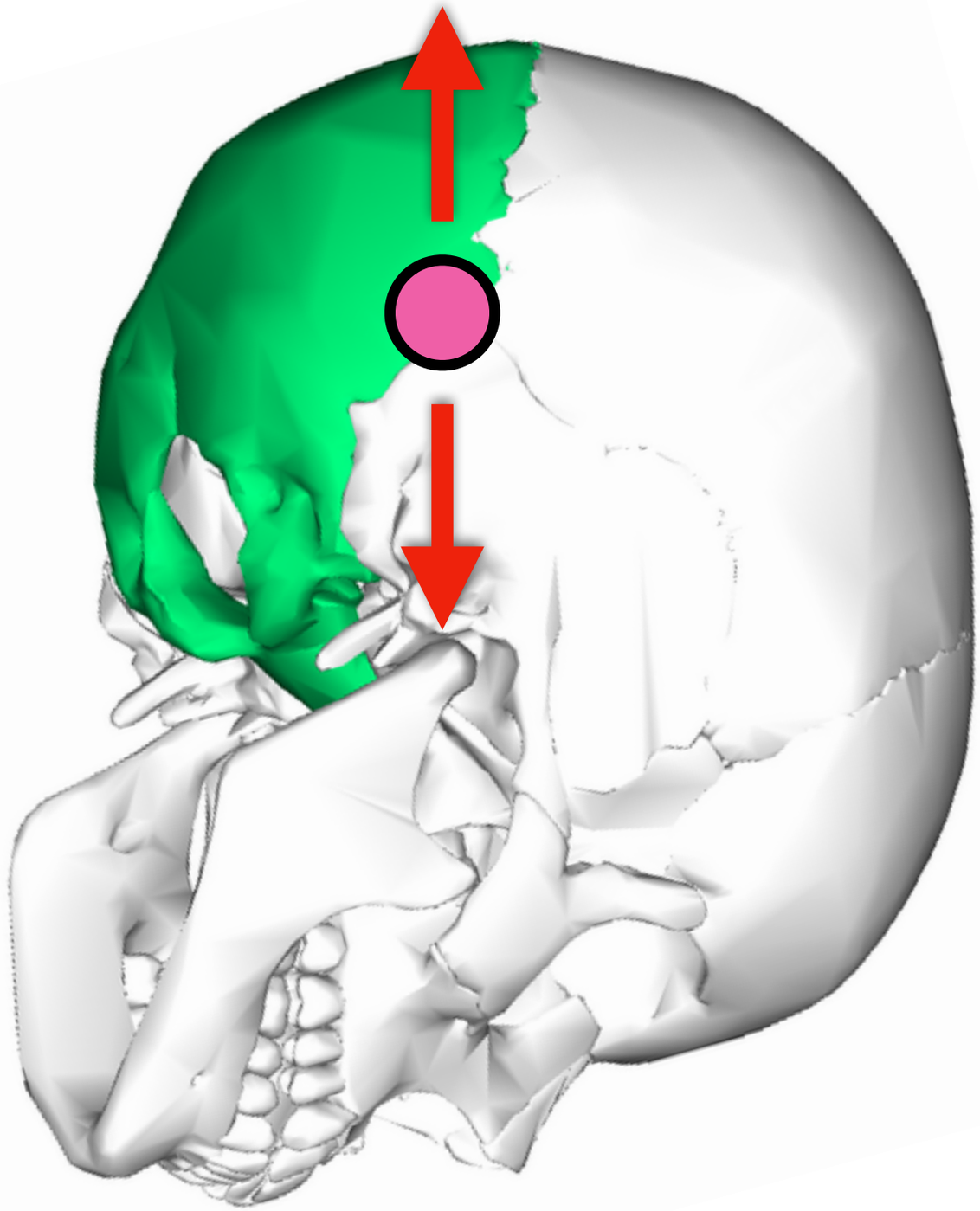

Tooth Height

- If one or both motions are restricted, then, while testing motion, ask “If I increase the tooth stack height by 1mm, what will happen?” Then try 2mm, 3mm, etc. (you can also test tenths of a mm)

- If you receive a wild answer (15mm, for example), that is the body telling you that there is more to do than just the tooth height. Treat appropriately and retest.

Tooth Height

- When the precise measurement is found, the occiput will be in neutral - moving freely into anterior and posterior motion.

- If your answer is in the reasonable range, work with your dentist to get the patient optimized (by extruding/ intruding teeth), retesting often to confirm your hypothesis.

- Again, this is fluid level test.

Mandibular Advancement

Maxillary Advancement

- How do we assess if the how far the maxilla should advance osteopathically?
- If the maxilla is not far enough forward, the airway is compressed/compromised and needs advancement to open the airway and optimize the face.

Maxillary Advancement

- Here we ask “ what happens if we move the maxilla anteriorly 1mm?” Then 2mm, 3mm, etc. (This measurement can be in .5mm increments.)

- When the precise measurement is found, the temporals will move into neutral.

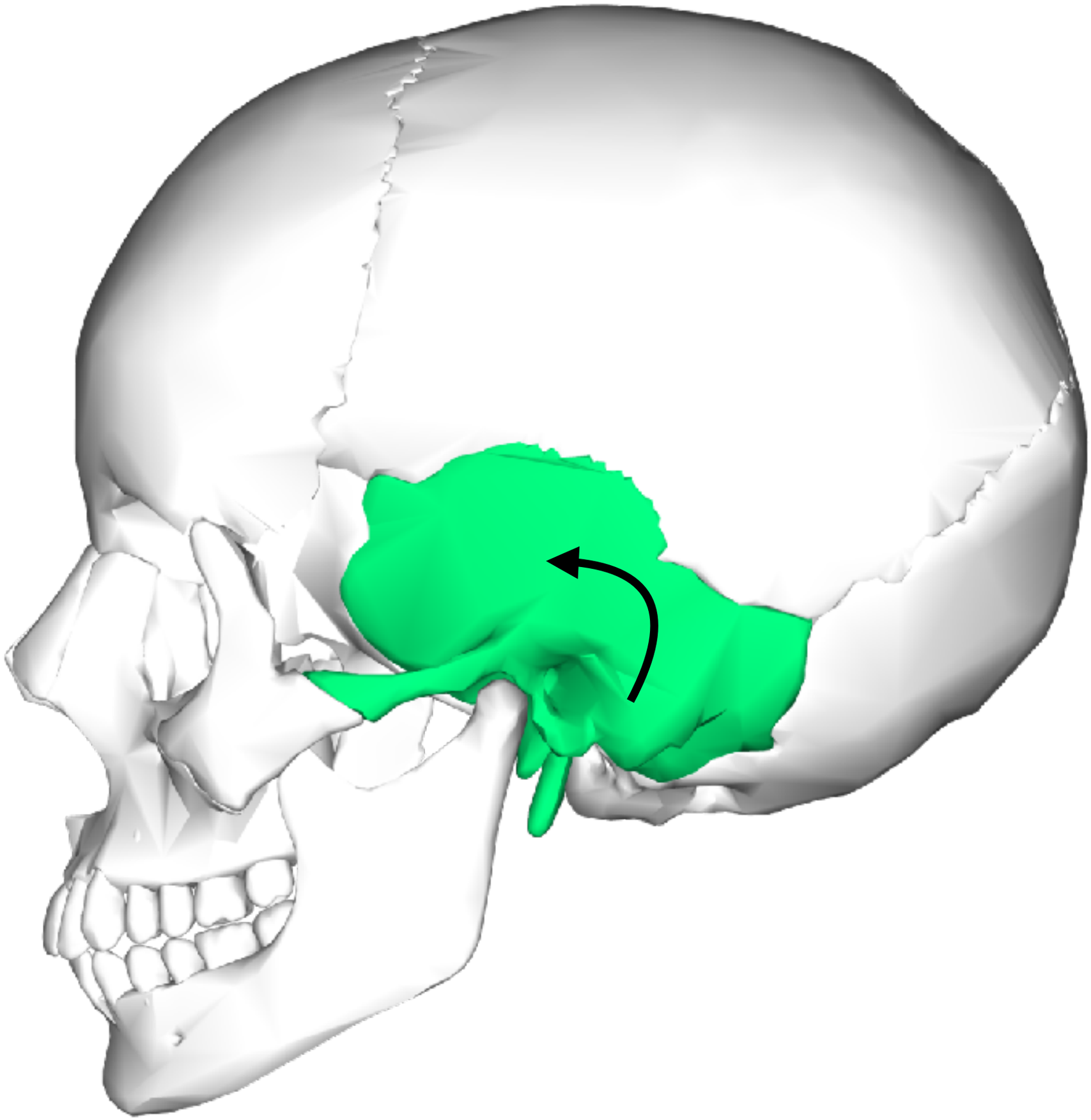

Alternate test

- Another way to get the same measurement is to test movement of the occiput. With the patient supine, the occiput will always move posterior (toward the table). When the maxilla is moved forward enough, the occiput will glide anteriorly.

- This moment seems to be IMPORTANT.

Importance

- When this measurement is correct and applied to the body, C1 and C2 will derotate and come back into midline.
- If the maxilla is too far posterior, it will cause C1 and C2 to rotate (and it will come back repeatedly after treatment).
- This measurement/test is both fluid and bony.

Premaxilla Width

Intercanine Width

- How do we assess if the width between the canines osteopathically?
- When this width is correct, the premaxilla has the room to move normally and not be impinged by either (or both) maxilla laterally.
- Its freedom not only impacts the sympathetic/ parasympathetic balance, but it opens the diaphragm.

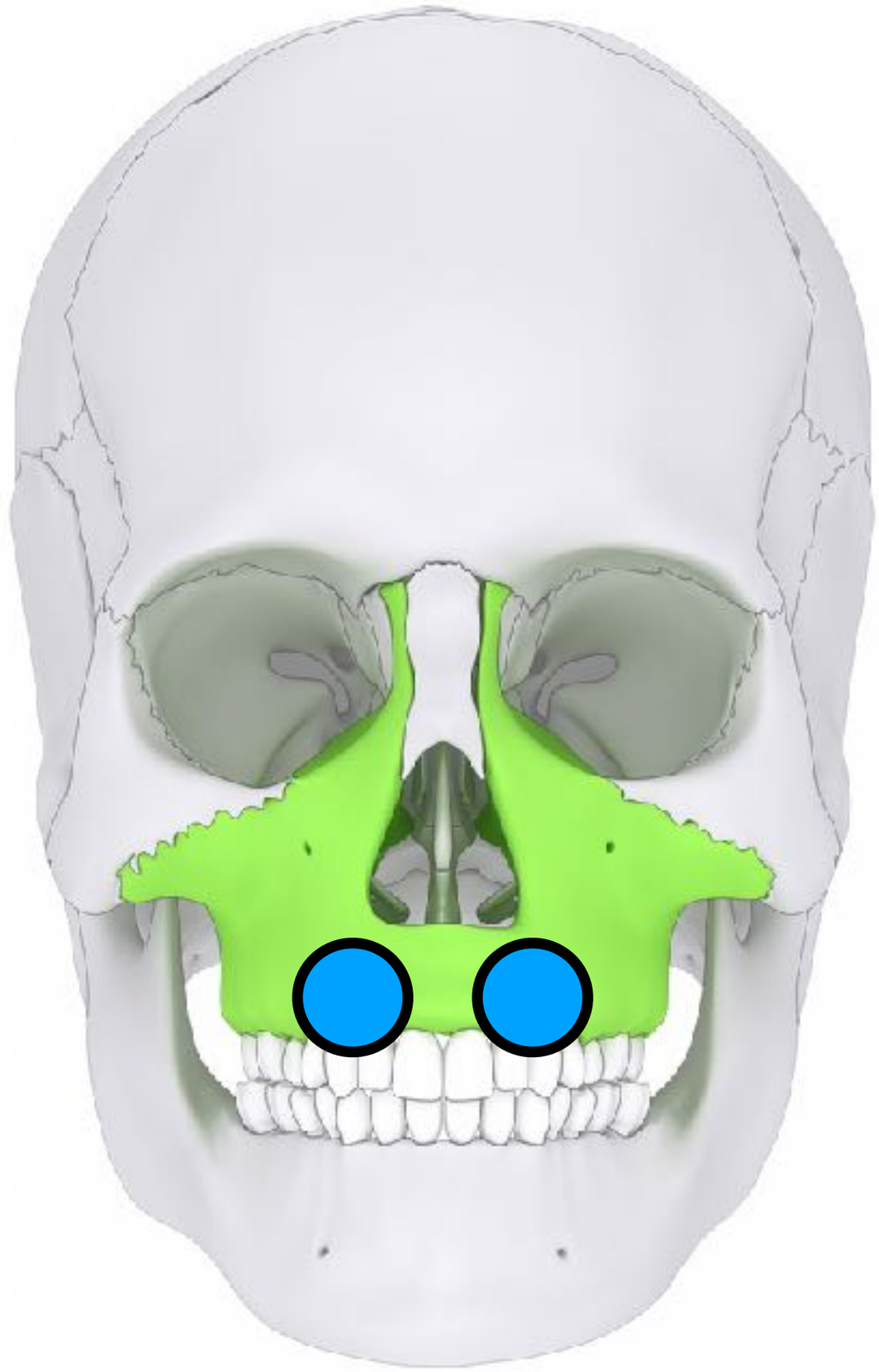

Intercanine Width

- We palpate the premaxilla/maxilla suture bilaterally and ask: “what happens if I increase the intercanine width by 1mm, 1.1mm, etc?”
- The correct measurement will move the premaxilla into neutral.
- This is both fluid and bony.

Bringing it together

Measurements

- Now we have four measurements, that, when achieved, will unlock many of the bones and sutures of the head.
  This improved movement will initially be on the fluid layer. Once placed in appliance, it will transfer to the bony layer.

- These measurements will help the dentist in creating the appliance(s) to assist the patient.

- The measurements and their impact on the body can be rechecked during the process to further refine the treatment.

Principles

- Our concept here is to be able to refine the dental norms to apply specifically to the patient in front of you… and then be able to check that refinement as treatment progresses and alter as necessary.

- We term it patient-specific osteopathic dental treatment.

- This is NOT a stand alone treatment process. Your patient will need support from the dentist (to work with any other issues), an oromyofunctional therapist (to work with the tongue and associated tissues), and an osteopath/chirospractor to address the rest.

Principles

- With our new measurements, we can ask the body which order it needs for this treatment. Do we work with intermolar width first, or maxillary advancement?

- Put hands on the patient and ask the body to show the order.

Concepts

- We can use the same thought process and testing to ask if the teeth need root or tip torque first vs intrusion or extrusion…or rotation, etc.
- Palpate the head and think the question and feel the response.
- This method allows incredible precision with the design of the case and guides the implementation and results.

Concepts

- It takes the things you have already learned as a dentist or oral health professional and allows the development of a patient specific treatment plan - one that stacks the deck in the patients favor because their body (not your left brain knowledge) is guiding the treatment.

Lab

Is What We Are Taught About Reflexes True?

Reflexes

- A “reflex” for our purposes is an expected pattern of movement.
- If I tap your knee cap with a reflex hammer, I expect the knee to move in a certain way…

Reflexes

- That movement pattern can be what we are expecting - and we would term it “normal”.
- Or it can be larger than expected (hyper) or smaller than expected (hypo).

Reflexes

- No matter what the outcome, the movement of the “reflex” is subconscious.

- And it can indicate pathology…

Retained Reflexes

- Most of the reflexes that we have as babies (termed primitive reflexes) serve a purpose during our development.

- When we “outgrow” the need for these reflexes, we should lose the reflex…it will integrate and no longer be obvious when tested.

- However, many of the reflexes remain in us after we should have outgrown them.

Retained Reflexes

- This can be anything from an annoyance to actual pathology.
- We will look at two of the reflexes and how to test for them. For the purpose of our class, we will focus on reflexes that can influence teeth or the cranium.
- We will cover a principle-based way to help integrate these reflexes.

Reflexes

- **Deep tendon reflexes**
  - Biceps reflex C5/C6
  - Brachioradialis reflex C6
  - Triceps reflex C7
  - Patellar reflex L4
  - Achilles tendon S1
- **Plantar response**
- **Reflexes tested in special situations**
  - Spinal cord injury
  - Frontal release signs
  - Posturing
- **Scale**
  - 0 = absent
    1+ = hypoactive
    2+ = normal
    3+ = hyperactive
    4+ = hyperactive with clonus
    5+ = sustained clonus

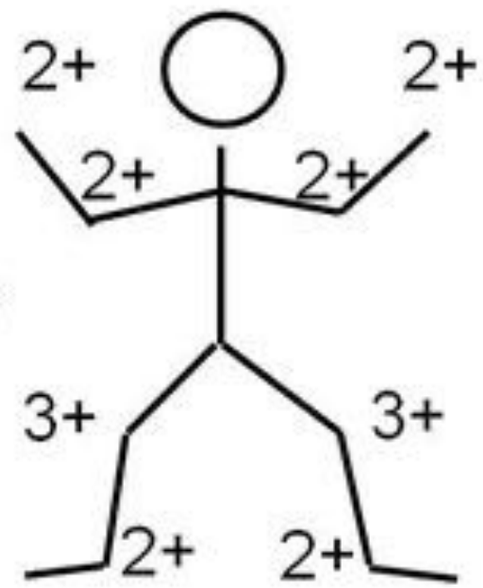

Clinical shorthand to summarize reflex findings

We have certain spots that we test to allow us to "look inside" at the nervous system and see how certain parts are functioning…or malfunctioning

Reflexes

- **Deep tendon reflexes**
  - Biceps reflex C5/C6
  - Brachioradialis reflex C6
  - Triceps reflex C7
  - Patellar reflex L4
  - Achilles tendon S1
- **Plantar response**
- **Reflexes tested in special situations**
  - Spinal cord injury
  - Frontal release signs
  - Posturing
- **Scale**
  - 0 = absent
    1+ = hypoactive
    2+ = normal
    3+ = hyperactive
    4+ = hyperactive with clonus
    5+ = sustained clonus

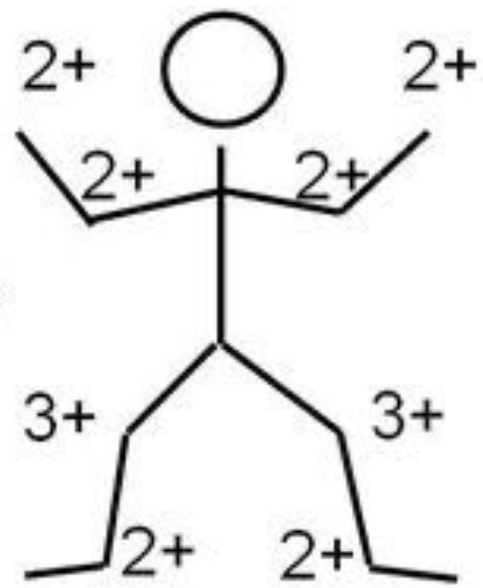

Clinical shorthand to summarize reflex findings

We have a language that describes whether that automatic response is just what we expect…or more or less than we expect.

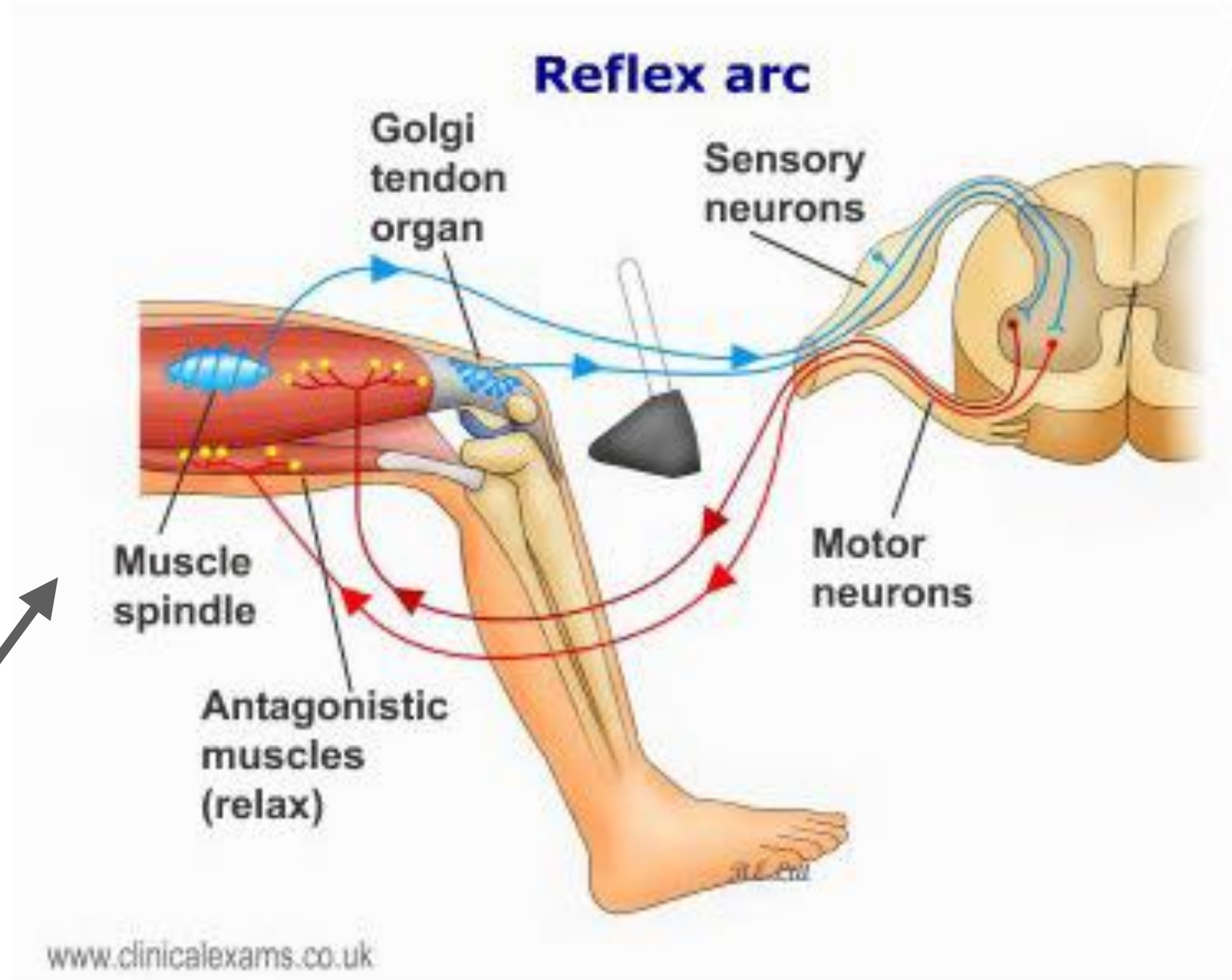

We even have an explanation of how the pattern of motion is supposed to work

Reflexes

- This exam for reflexes is part of our education and is supposed to be part of any patients initial exam.
- And its good information to gather…until you recognize that it is only part of the picture of the patient.

Reflexes

- In my practice, I did this for a few years, then found my first patient who had something that seemed to come before, or be bigger than, the reflex testing.

Reflexes

- Then I found that:
  - I wasn’t taught well enough in school
  - I wasn’t asking the right questions
  - I wasn’t testing the right things
  - The answers in the books didn’t seem osteopathic enough
  - The patient had the answers if I was willing to be the student again…the student of the patient…

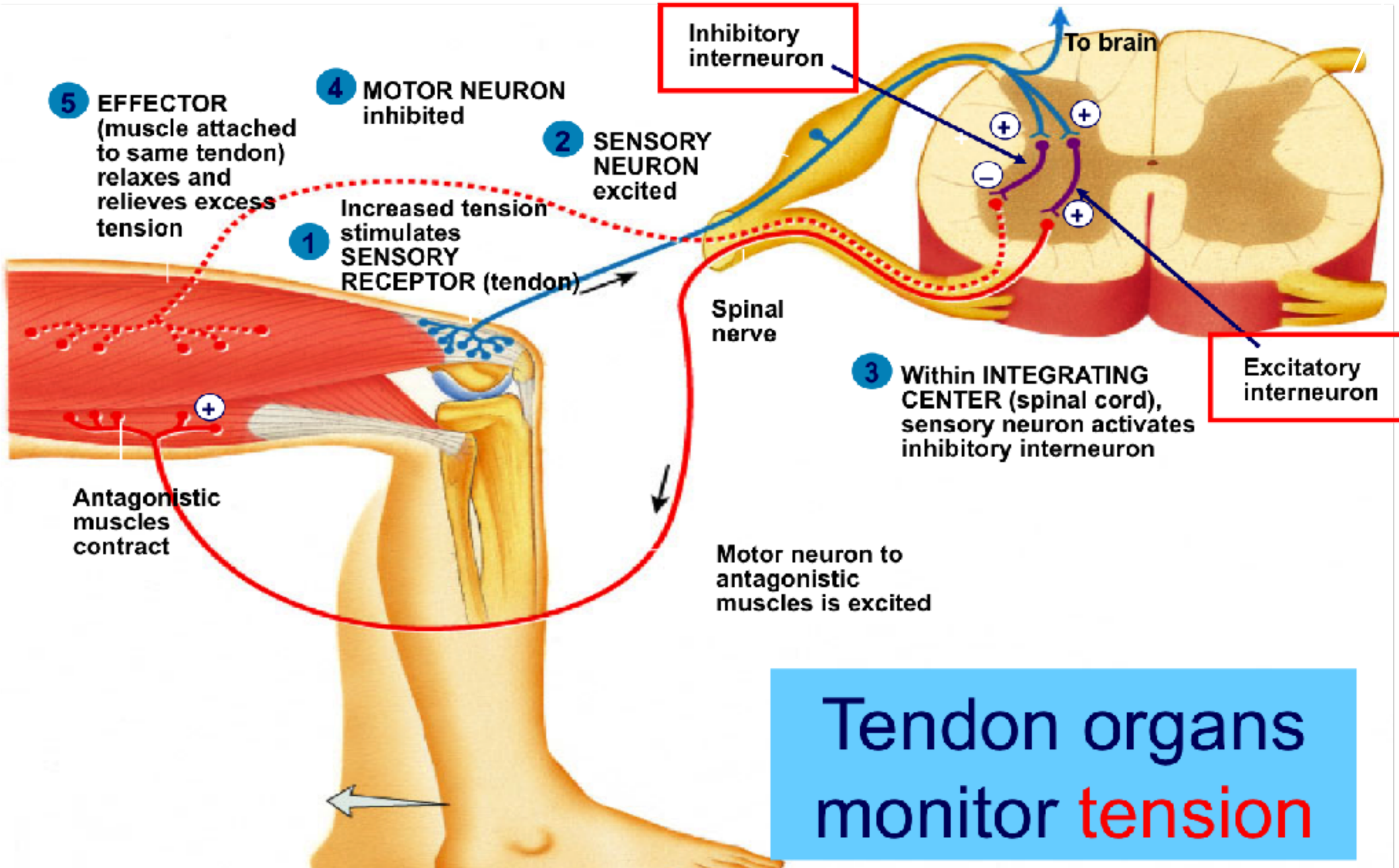

Tendon organs monitor tension

Think about this when any part of the mouth musculature does not work correctly

Reflexes

- In the last picture, the author states that tendon organs monitor tension. Is that 100% true osteopathically?

- Might it also be true that tendons (and ligaments and maybe even all connective tissues) provide a window into the health of their attached nervous system by showing us their tension?

Reflexes

- And thus, a movement pattern that we expect MAY indicate health, but a movement pattern that we don’t expect SHOULD lead us to more investigation?

- And that investigation should be osteopathic in nature… while not leaving behind the allopathy that we know (this is where EBM comes in - but remember EBM is ALWAYS lagging behind the people discovering it (the clinicians)).

There are some things that seem to cloud or hinder accurate reflex testing osteopathically

Shock

- These are all osteopathic indications of shock - anything that happens to the body faster than it can handle.
- This is something to refer to an osteopath for treatment.
- Untreated, it will absolutely hinder our exam (for retained reflexes *and* anything else) AND the outcomes of our treatment !

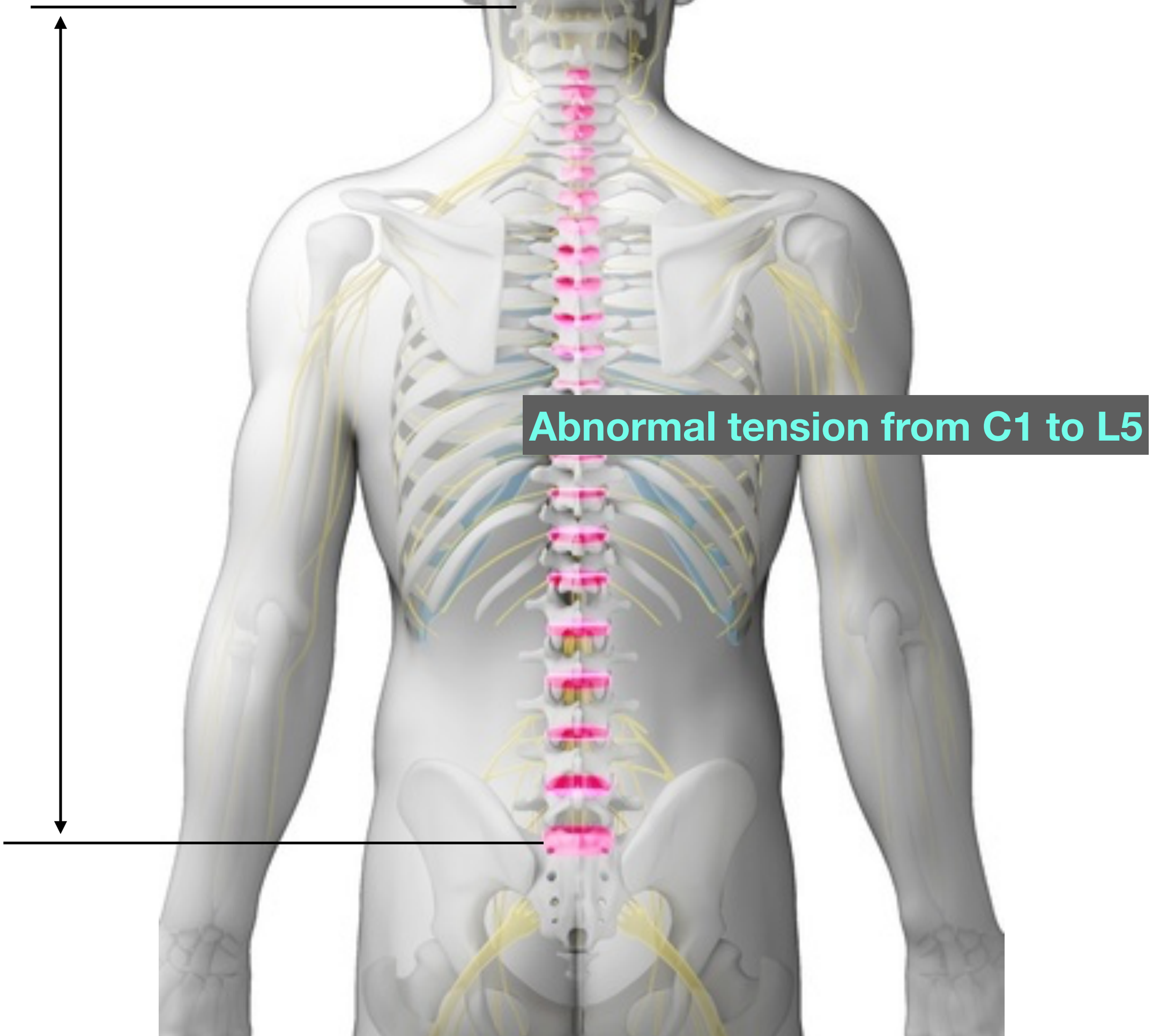
Abnormal tension from C1 to L5

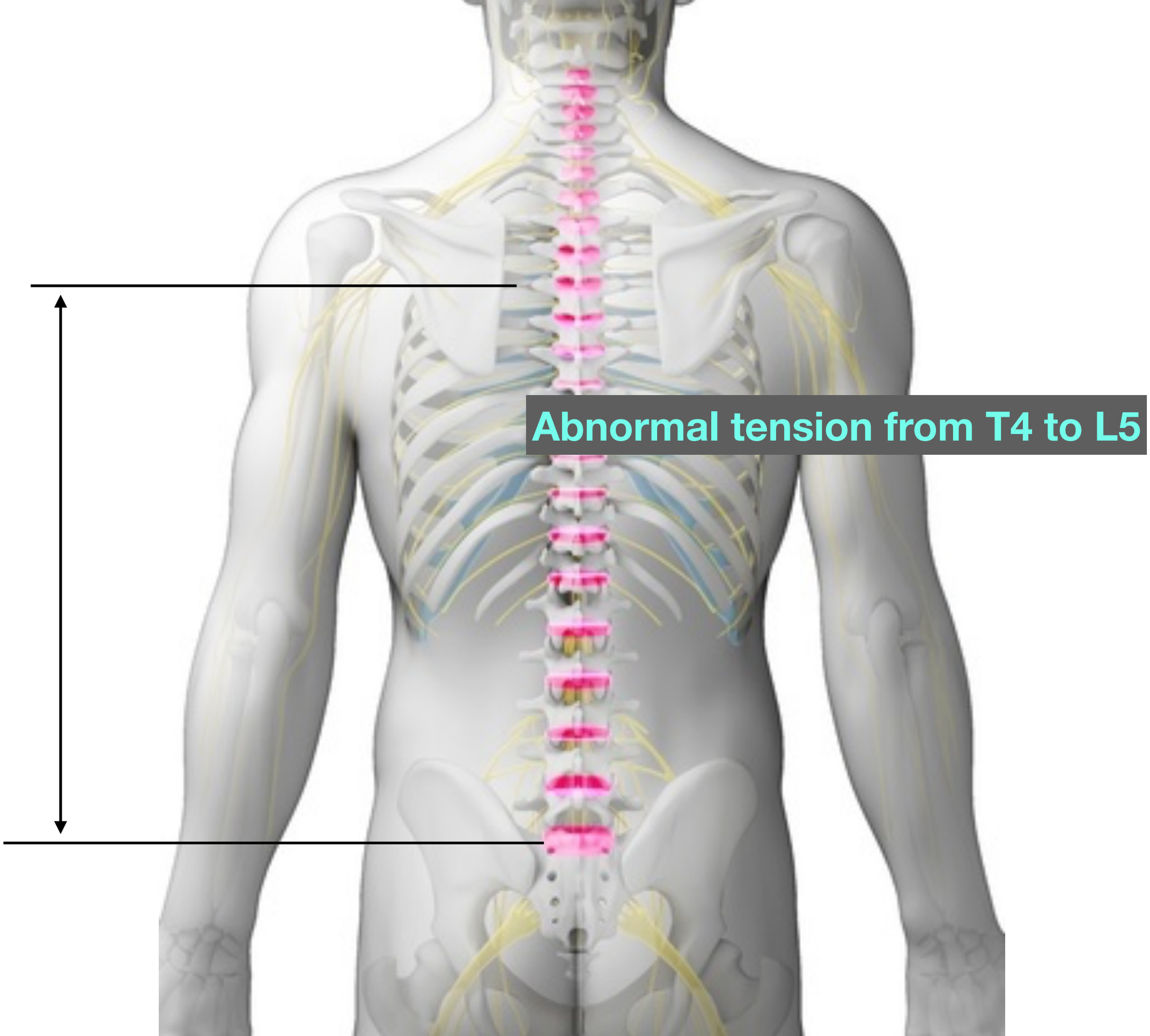
Abnormal tension from T4 to L5

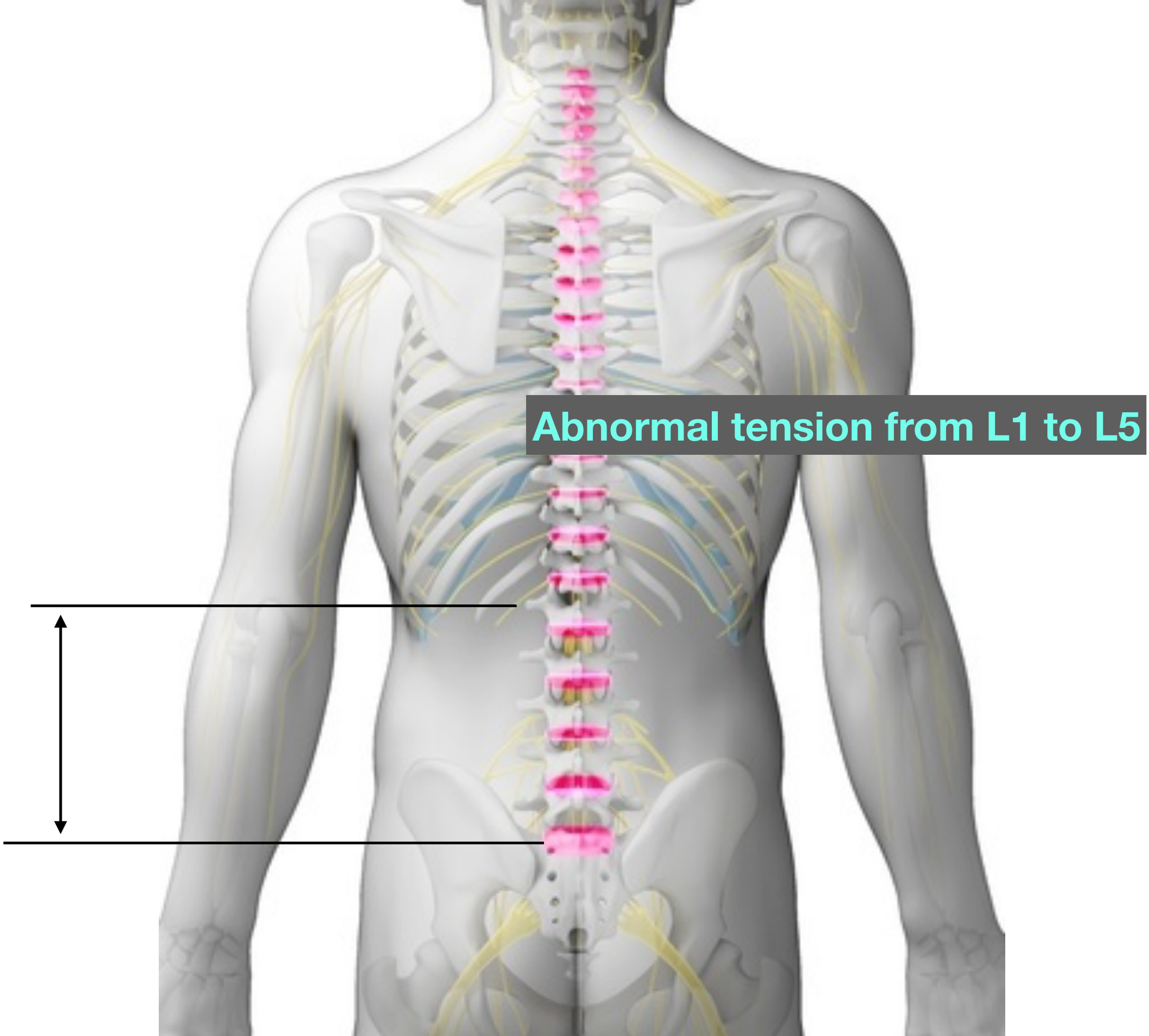
Abnormal tension from L1 to L5

Shock

- Again, this is something to refer to an osteopath for treatment.
- Think about shock when you have a patient that is not progressing…

Retained Primitive Reflexes

“There is a power in nature that man has ignored. And the result has been heartache and pain.”

–Anasazi Foundation

Retained Reflexes

- Most of the reflexes that we have as babies serve a purpose during our development.
- When we “outgrow” the need for these reflexes, we should lose the reflex. (it should integrate)
- However, many of the reflexes remain in us after we should have outgrown them.

Retained Reflexes

- This can be anything from an annoyance to actual pathology.
- We will look at a two of the reflexes today and how to test for them.

Retained Reflexes

- Not all reflexes will be covered due to time constraints (there are 70).
- Other reflexes can be looked up online. (such as: https://www.occupationaltherapy.com/articles/understanding-primitive-reflexes-they-impact-5409-5409)
- They are easy to spot once you know what you are looking for, but take time to integrate fully.

Warnings

- The physical response to the reflex is not always visible.
- But the altered movement pattern is always present.

The Symphony of Reflexes

Bonnie Brandes, MEd

ISBN-10: 150285502X

ISBN-13: 978-1502855022

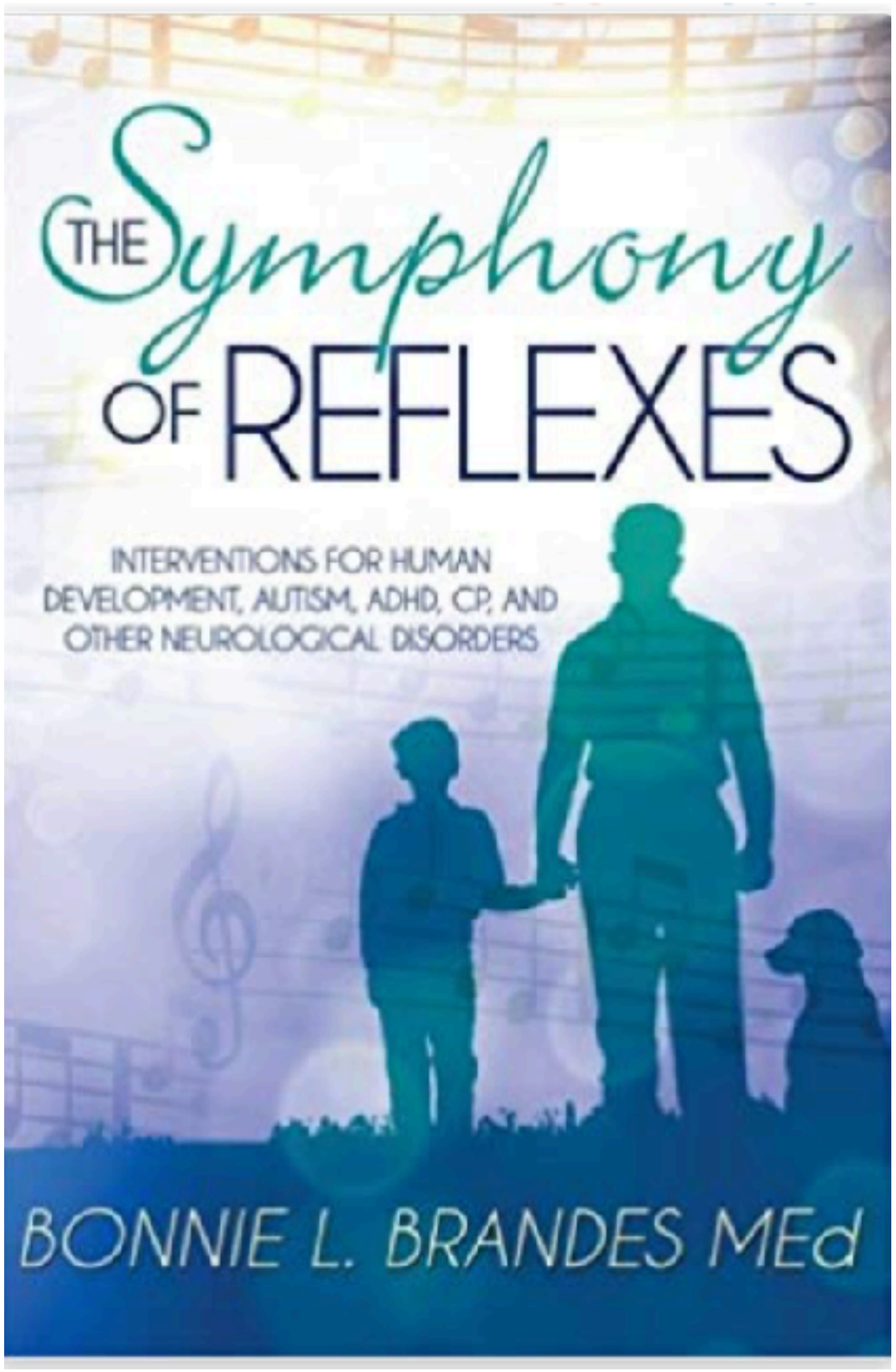

Movement is Key

- In a Canadian study of over five hundred students, those who spent an extra hour each day in gym class scored markedly better on exams than those who spent less time in gym class.

- According to Dr. Joseph Mercola, “Exercise encourages your brain to work at optimum capacity by causing nerve cells to multiply, while strengthening their interconnections, and protecting them from damage.

- Brandes, Bonnie. The Symphony of Reflexes: Interventions for Human Development, Autism, ADHD, CP, and Other Neurological Disorders . Kindle Edition.

Tongue exercises count…

Movement is Key

- Movement not only integrates reflexes but also helps them to remain integrated.

- Lack of movement (watching TV, texting, computer games, etc.) bring stress to the nervous system and can lead to brain shrinkage.

- Brandes, Bonnie. The Symphony of Reflexes: Interventions for Human Development, Autism, ADHD, CP, and Other Neurological Disorders . Kindle Edition.

Fear Paralysis Reflex

“If you hold a cat by the tail you learn things you cannot learn any other way.”

–Mark Twain

Fear Paralysis Reflex

- This is the first reflex to appear in utero. It occurs from 5-7 weeks.
- It is usually integrated by the 12th week of development.
- Testing this reflex may stimulate fear in the patient, so maintain a safe space and therapeutic rapport.

Fear Paralysis Reflex

- It may come about from fear or trauma during pregnancy.
- Its purpose is to cause withdraw from any sign of danger. It triggers a decreased heart rate, decreased respirations, and decreased muscle tone (playing dead) (this is a parasympathetic response).
- It is interconnected with the Moro reflex.

Fear Paralysis Reflex

- If it is activated in someone, they tend to have a low tolerance to stress and be overly sensitive in one or more of their senses.
- Do any of your patients NOT exhibit this?

Fear Paralysis Reflex

- OCD/Inflexible
- Easily Distracted
- Difficulty Sleeping
- Separation Anxiety
- Very Attached to Parent

Fear Paralysis Reflex

- Evaluation:
  - Evaluate closed eyes for a blink or response as you tap the sternum, laterally on both elbows, knees or the bottoms of the feet.
  - Sudden noises will also activate.
  - This activates the patients (and your) sympathetic nervous system.

Osteopathic Finding

- Patient twitches during palpation. Nervous system ramped up (sympathetic activation). Poor sleep.

Lab

Moro Relfex

“Take no one’s word for anything, including mine - but trust your experience.”

– James Baldwin

Moro Reflex

- Begins at the 8-9th week in utero and is fully emerged by the 30th week.

- Should integrated by the 4th month of infancy.

Moro Reflex

- It involves three distinct components:
  1. Spreading out the arms (abduction)
  2. Unspreading the arms (adduction)
  3. Crying (usually)

Moro Reflex

- The Moro reflex may help the infant cling to its mother. If the infant lost its balance, the reflex caused the infant to embrace its mother and regain its hold on the mother's body.

Moro Reflex

- Is a body defense with activated sympathetics and adrenals.
- Triggers can be:
  - Strong unpleasant stimulation with balance, auditory, visual, tactile or proprioceptive factors.

Moro Reflex

- People who do not have an integrated reflex may have:
  - Hypersensitivity to light and sound
  - Difficulty blocking out background noise
  - Can be reactive in situations to great physical or emotional stress
  - Intolerant of routine changes
  - Inflexible

Moro Reflex

- This startle reflex can lead to:
  - ADHD
  - Anxiety

Moro Reflex

- Testing:
  - With patient lying supine, gently lift neck with the 2nd and 3rd fingers.
  - A stiff neck is a positive test.

Moro Reflex

- Testing:
  - With patient lying supine, gently lift the posterior knees with the 2nd and 3rd fingers.
  - A stiff leg is a positive test.

Osteopathic Finding

- Cervical spine relatively rigid. All joints stiffer than normal.
- The Moro reflex does not impact the tongue (it has no joints) and the hyoid is the only free floating bone in the body.

Lab

Reflexes That Impact Dentition

- Juvenile Suck Reflex - causes tongue thrust, immature swallow and anterior open bite (Class 2 Bite).
- Babinski Reflex - causes external rotation of the hips when standing (TMJ issues).
- Palmar Reflex - causes use of the jaw to obtain strength.
- Rooting Reflex - causes tongue to be displaced anteriorly (drooling, anterior open bite).

Reflexes That Impact Dentition

- Babkin Reflex - jaw tension or bruxism.
- Spinal Gallant and Spinal Perez - both impact the movement of the temporal bones (TMJ).
- Asymmetric Tonic Neck Reflex - Scoliosis and altered tongue motion (head must be in a certain position to chew or swallow).
- Neck Righting Reflex - Floor of posterior cranial fossa - Tongue

The Dental Connection to Vision

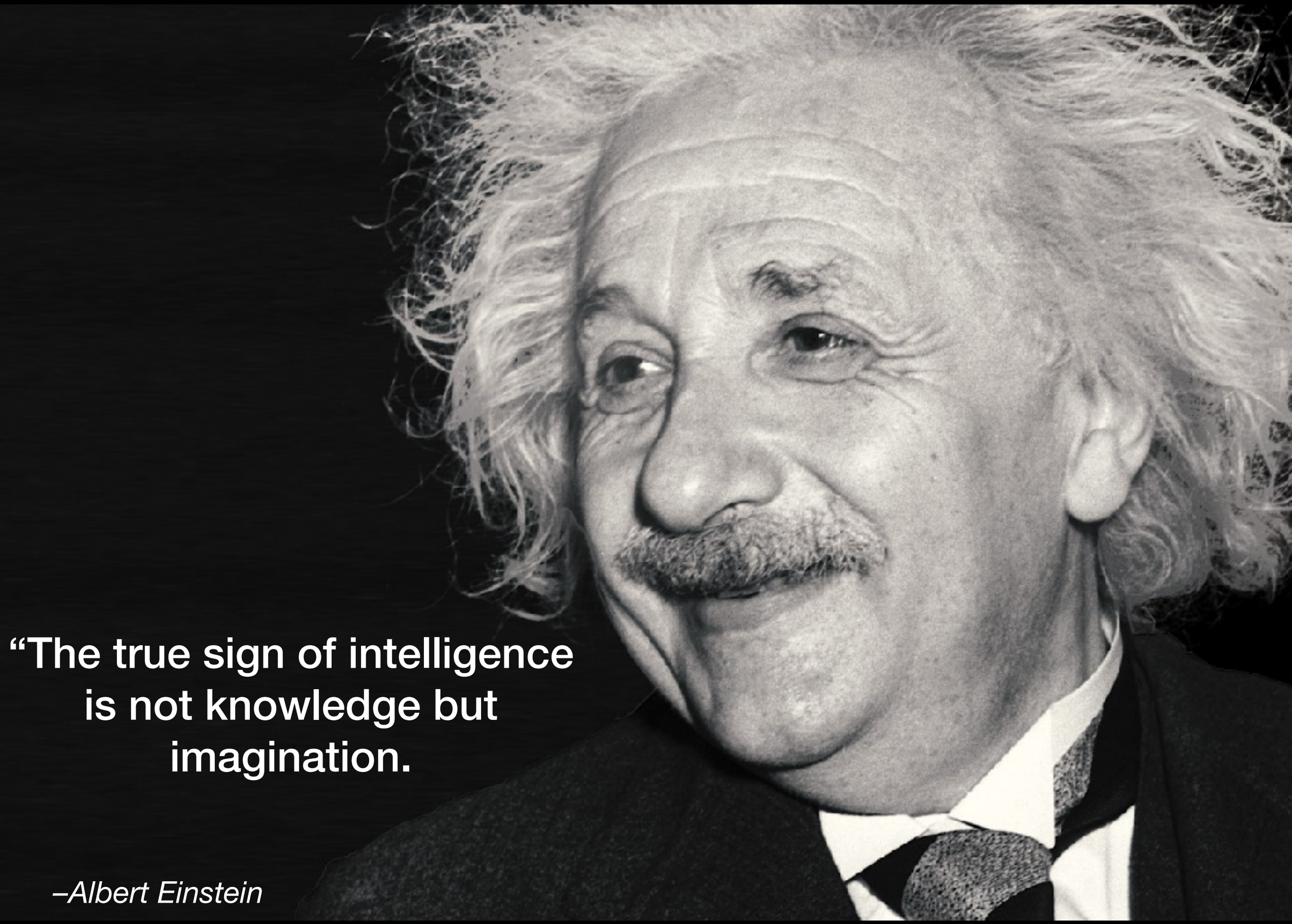
“The true sign of intelligence is not knowledge but imagination.
–Albert Einstein

Dental/Vision Connection

- We should first start by defining some vision terminology (since most of us are not ophthalmologists).
- I am going to lay the foundation for speaking intelligently to someone in the vision field.

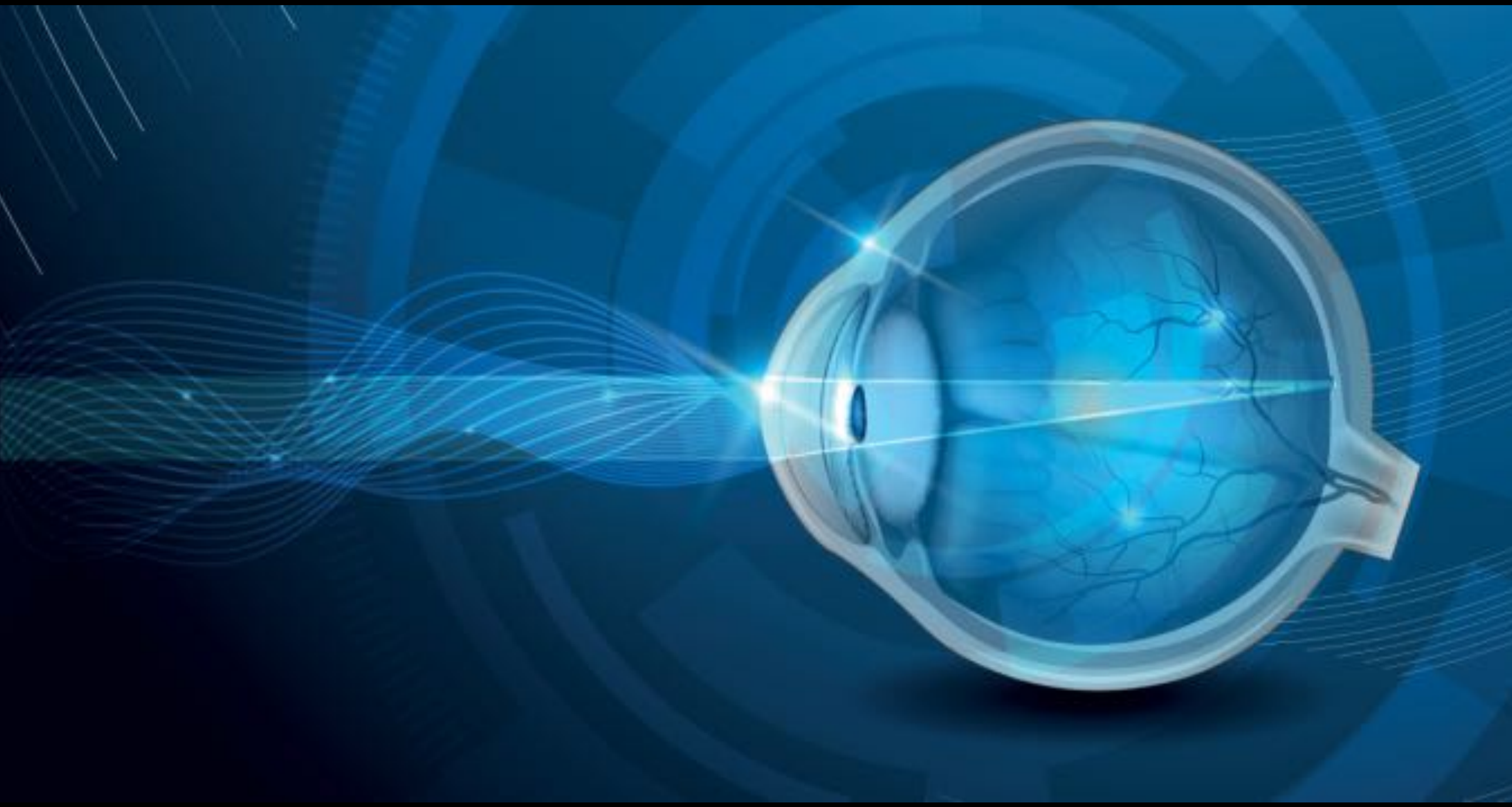

Eye Anatomy

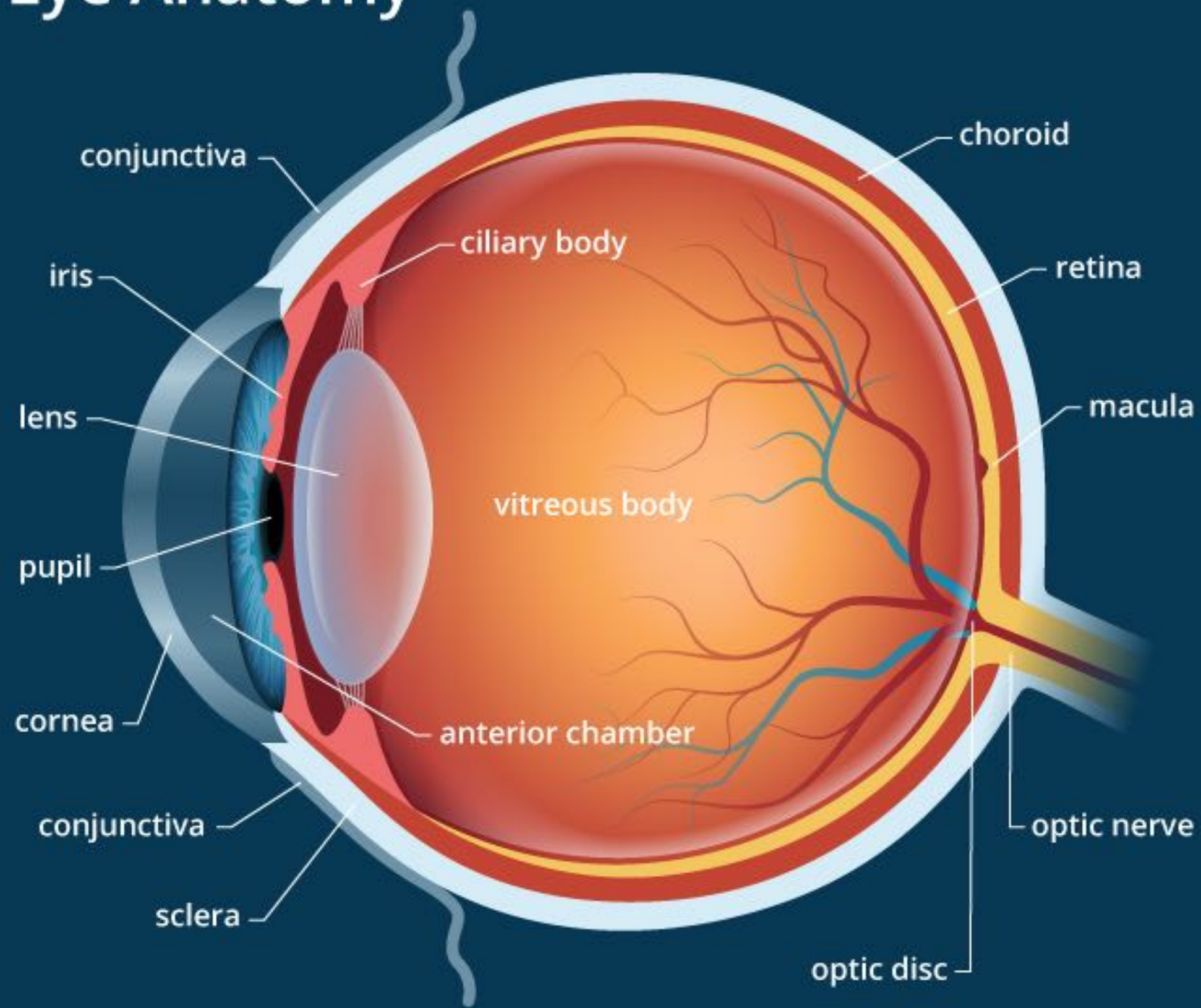
conjunctiva
iris
lens
pupil
cornea
conjunctiva
sclera
ciliary body
vitreous body
anterior chamber
choroid
retina
macula
optic nerve
optic disc

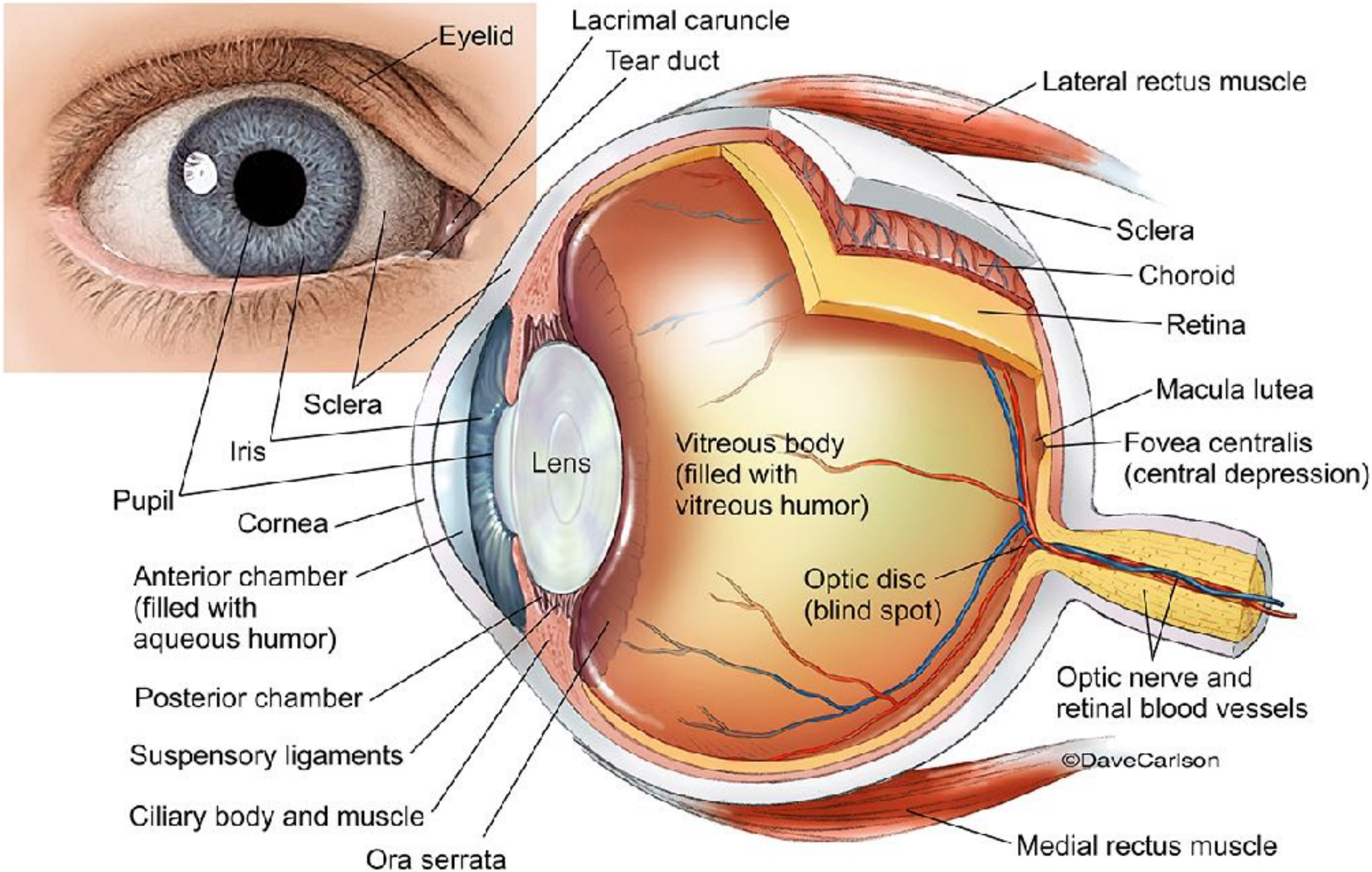

Right Eye (viewed from above)

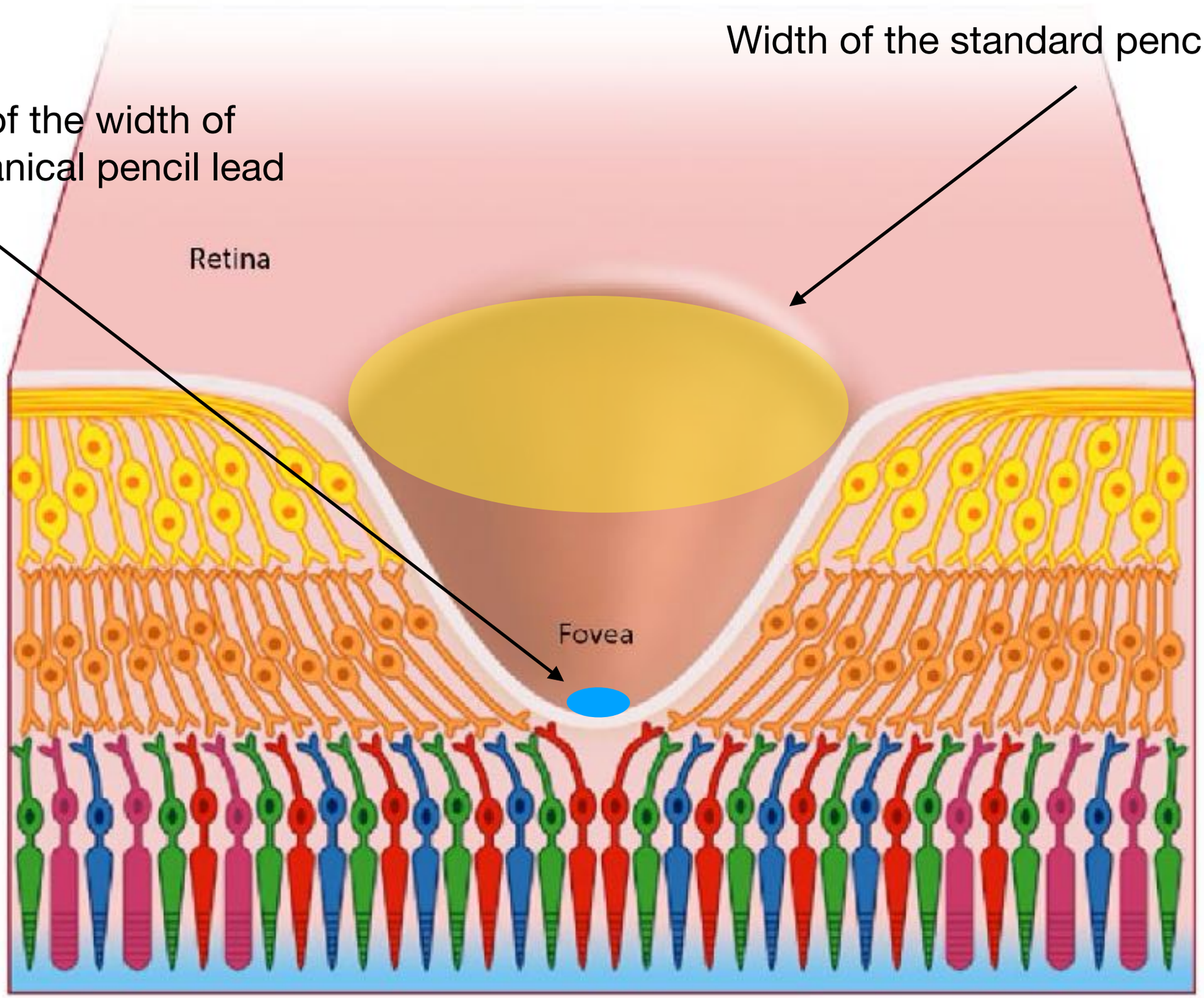

brainHQ
from Posit Science

Figure 11–6a Extrinsic Eye Muscles.

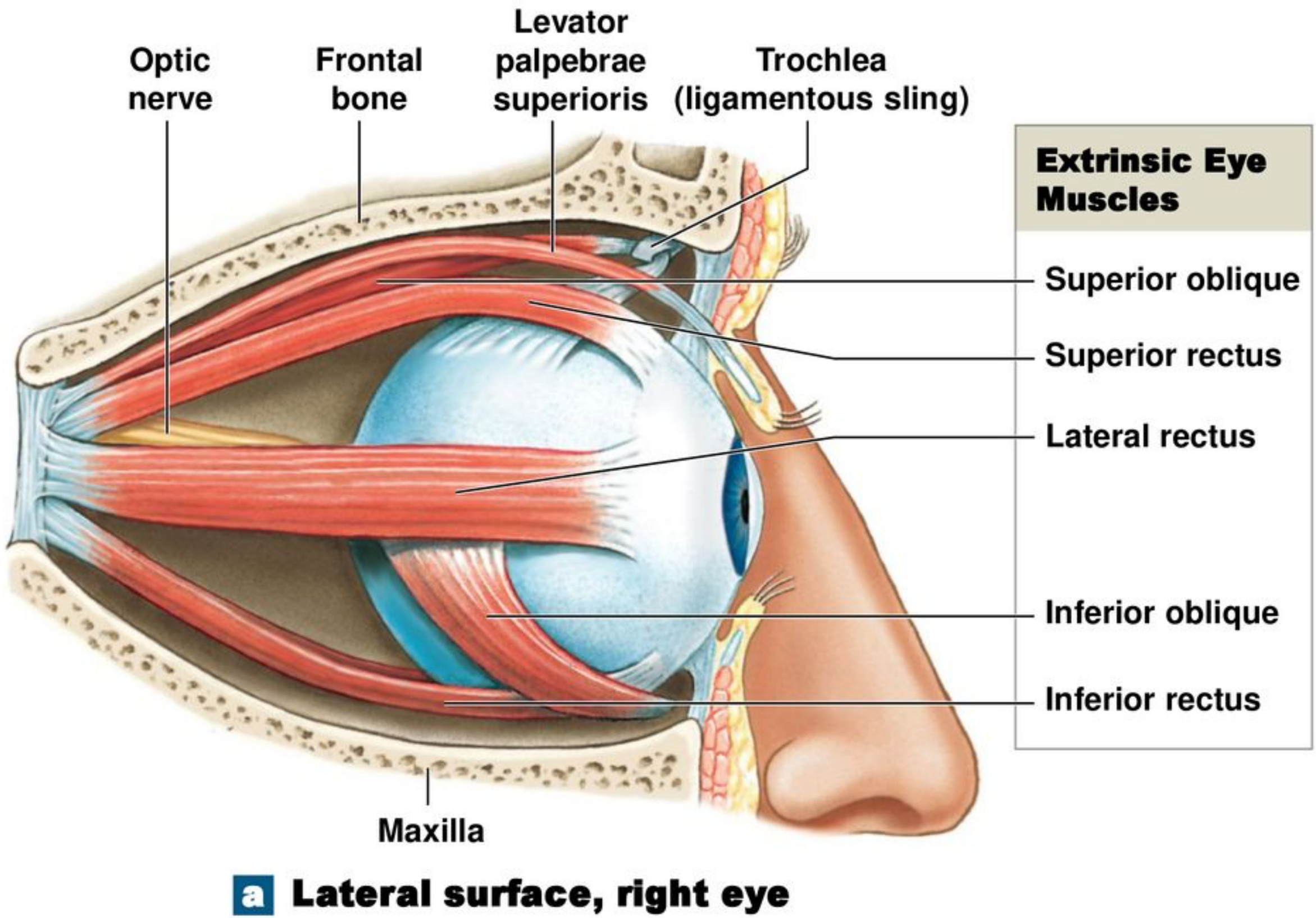

This is perfect vision - the light from
the object we are looking is focused on the macula.



In the vision world, this is called emmetropia.
No vision correction is required.

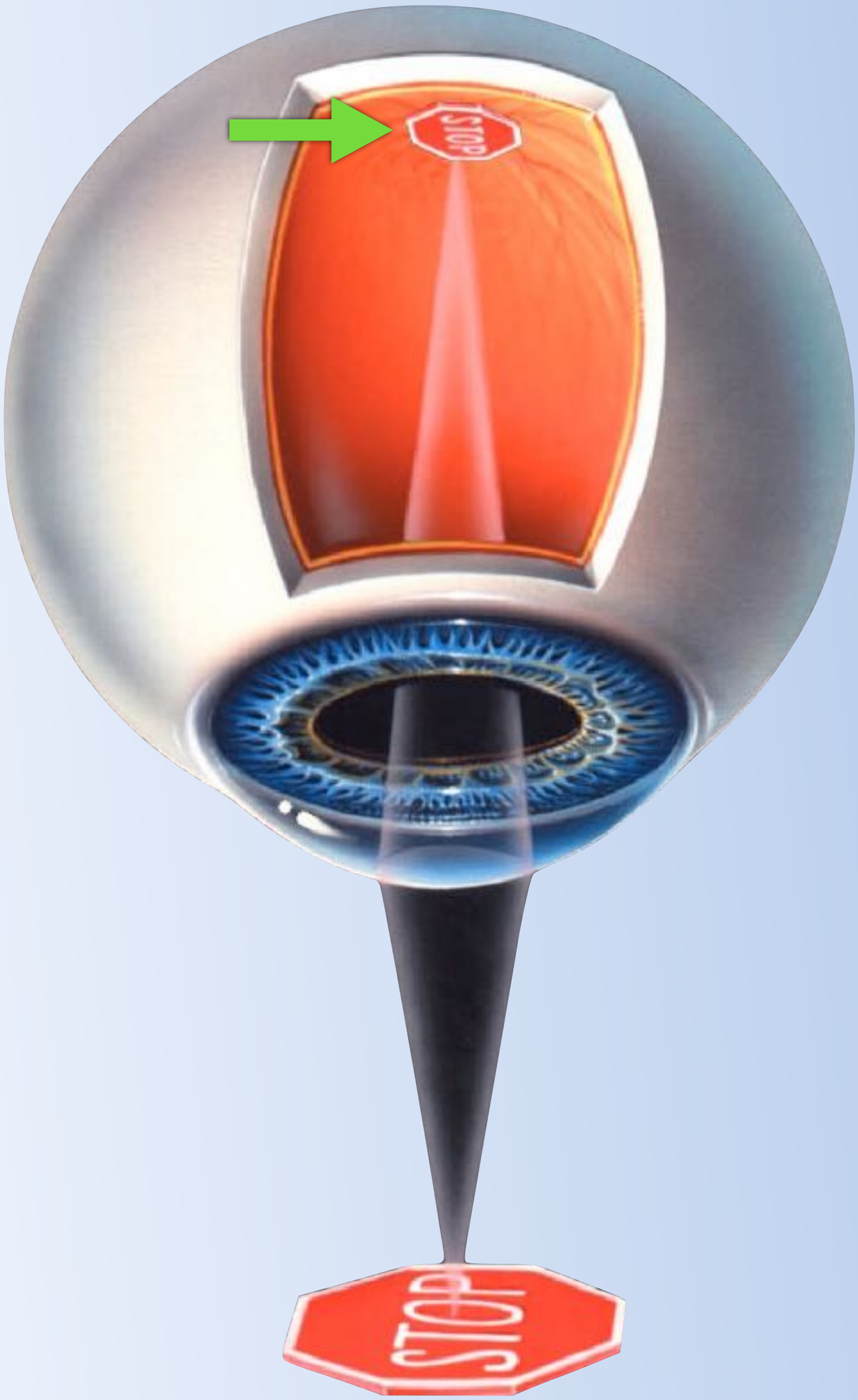
STOP
STOP

Normal Vision

Vision Requirements

- “Perfect” central vision is considered 20/20. (that means that you can see at 20 feet what should be seen at 20 feet clearly (sharp visual acuity)).

- To operate a motor vehicle in most states, your vision has to be 20/40 or better without glasses, or to be corrected to at least 20/40 with glasses/contacts.

Vision Requirements

- 20/40 vision means that you can see at 20 feet what someone with perfect vision could see at 40 feet.
- SO, you need to be closer to see something clearly.
- Let’s look at how that happens in the eye.

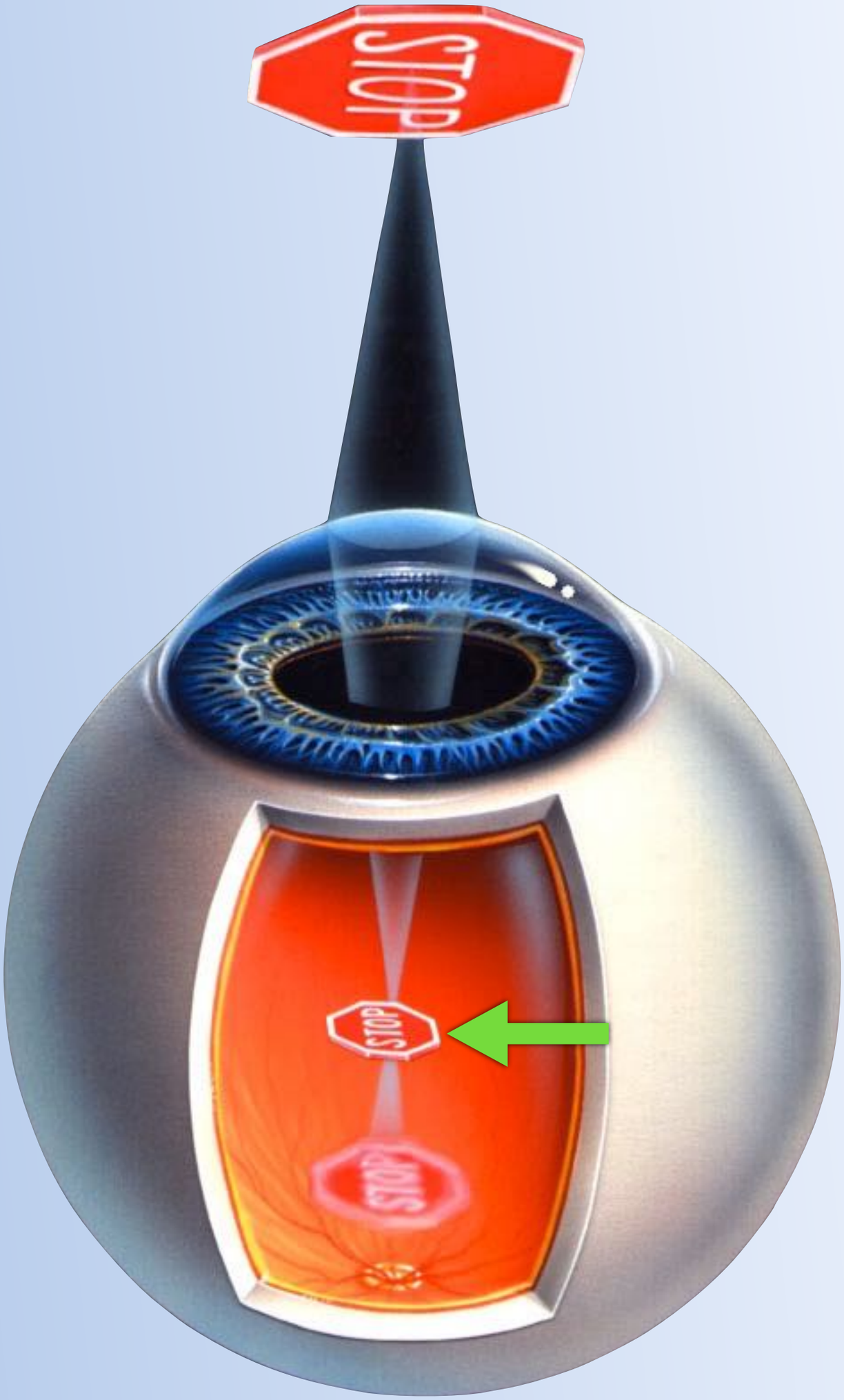
STOP
STOP
STOP

This is nearsighted vision - the light from
the object we are looking is focused in front of the macula

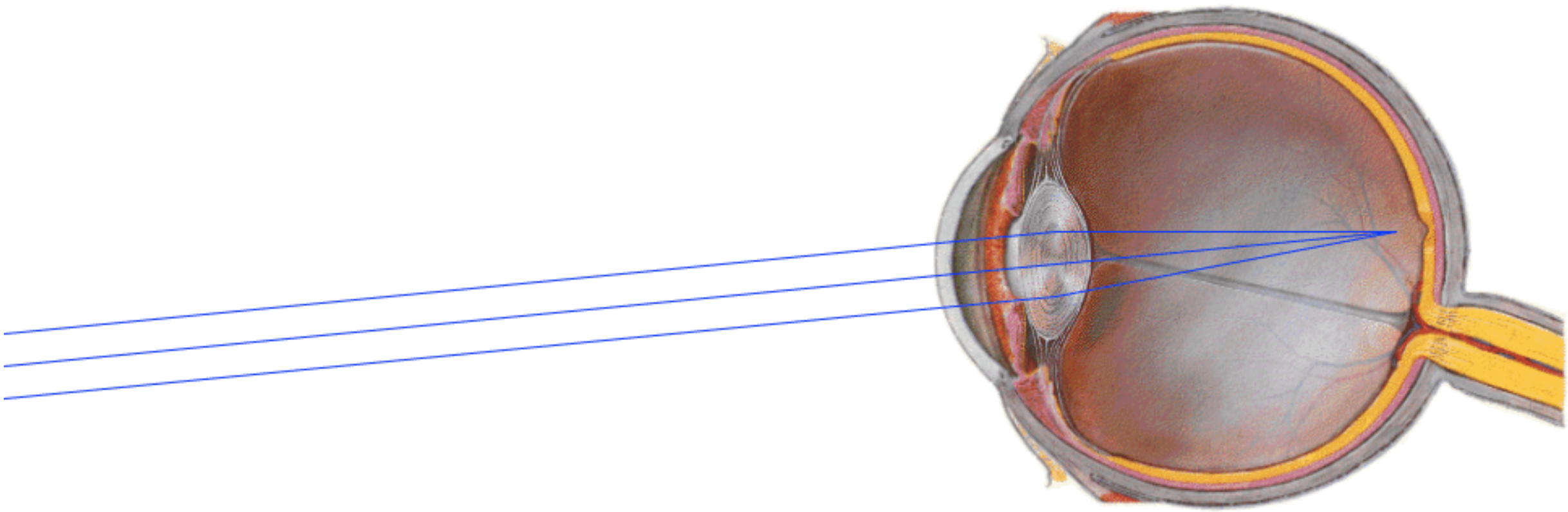

In the vision world, this is called myopia.
Vision correction with a minus spherical lens is required.

Near Sightedness - Myopia

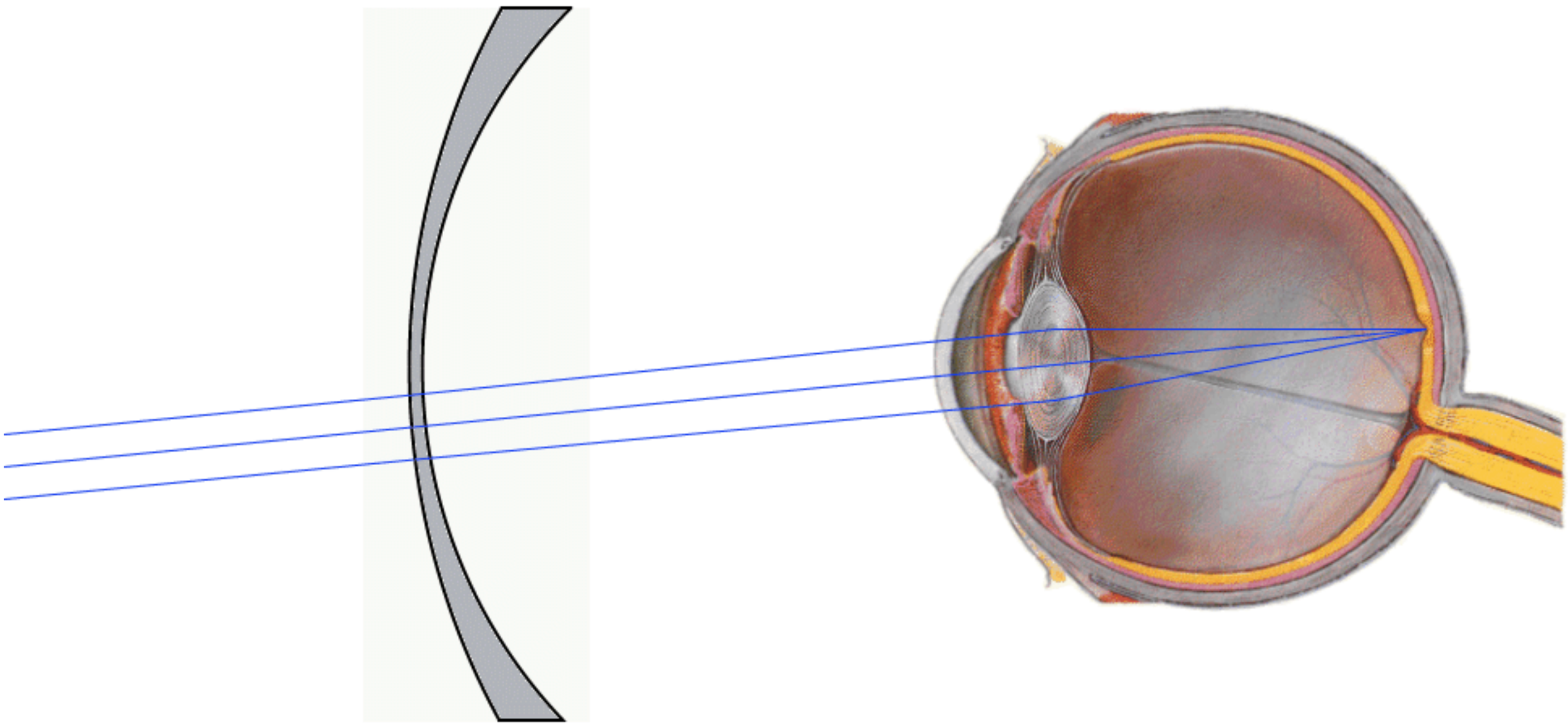

The corrective lens moves the image backwards onto the macula
(when it is prescribed correctly).

Vision Requirements

- Vision that is better than 20/20 is far sightedness.
- 20/15 vision means you can see at 20 feet what someone with perfect vision would need to be at 15 feet to see clearly.
- Let’s look at how that happens in the eye.

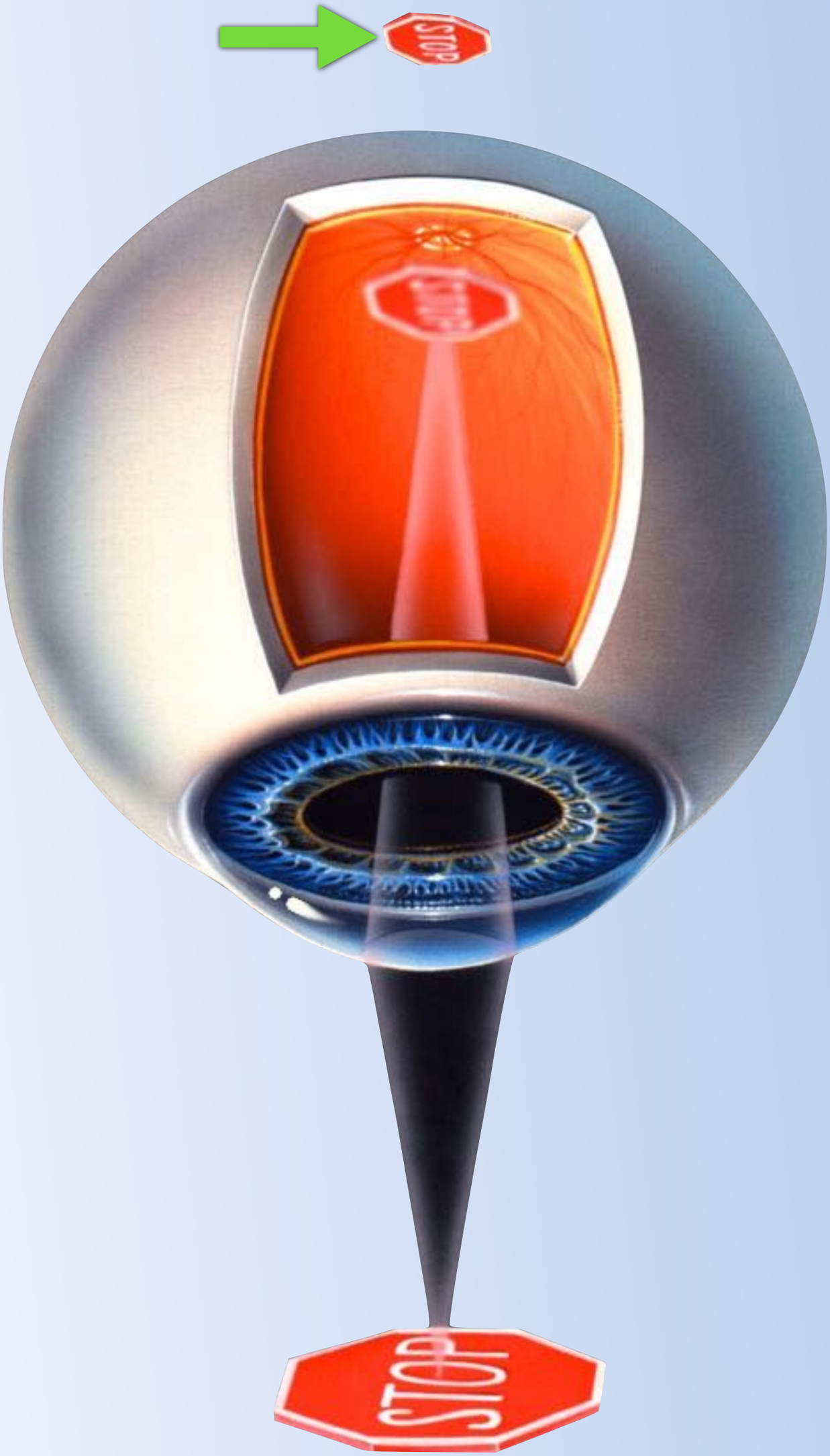
STOP
STOP
STOP

This is farsighted vision - the light from
the object we are looking is focused behind of the macula

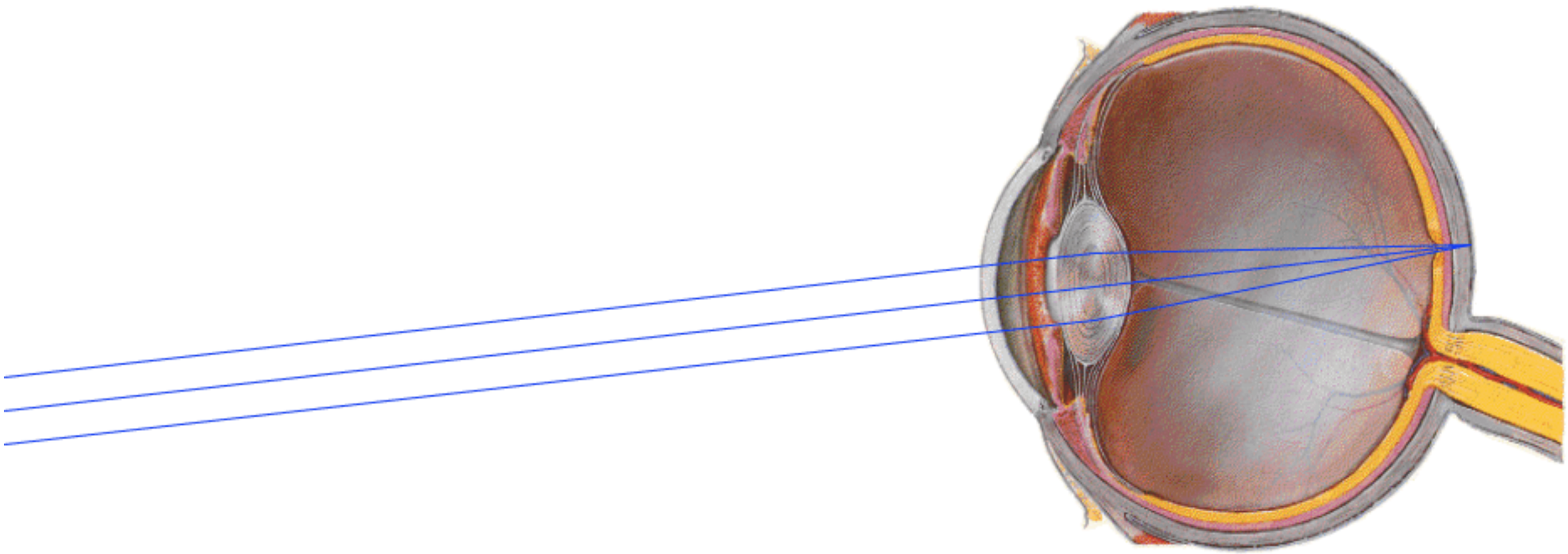

In the vision world, this is called hyperopia.
Vision correction with a plus spherical lens is required.

Far Sightedness - Hyperopia

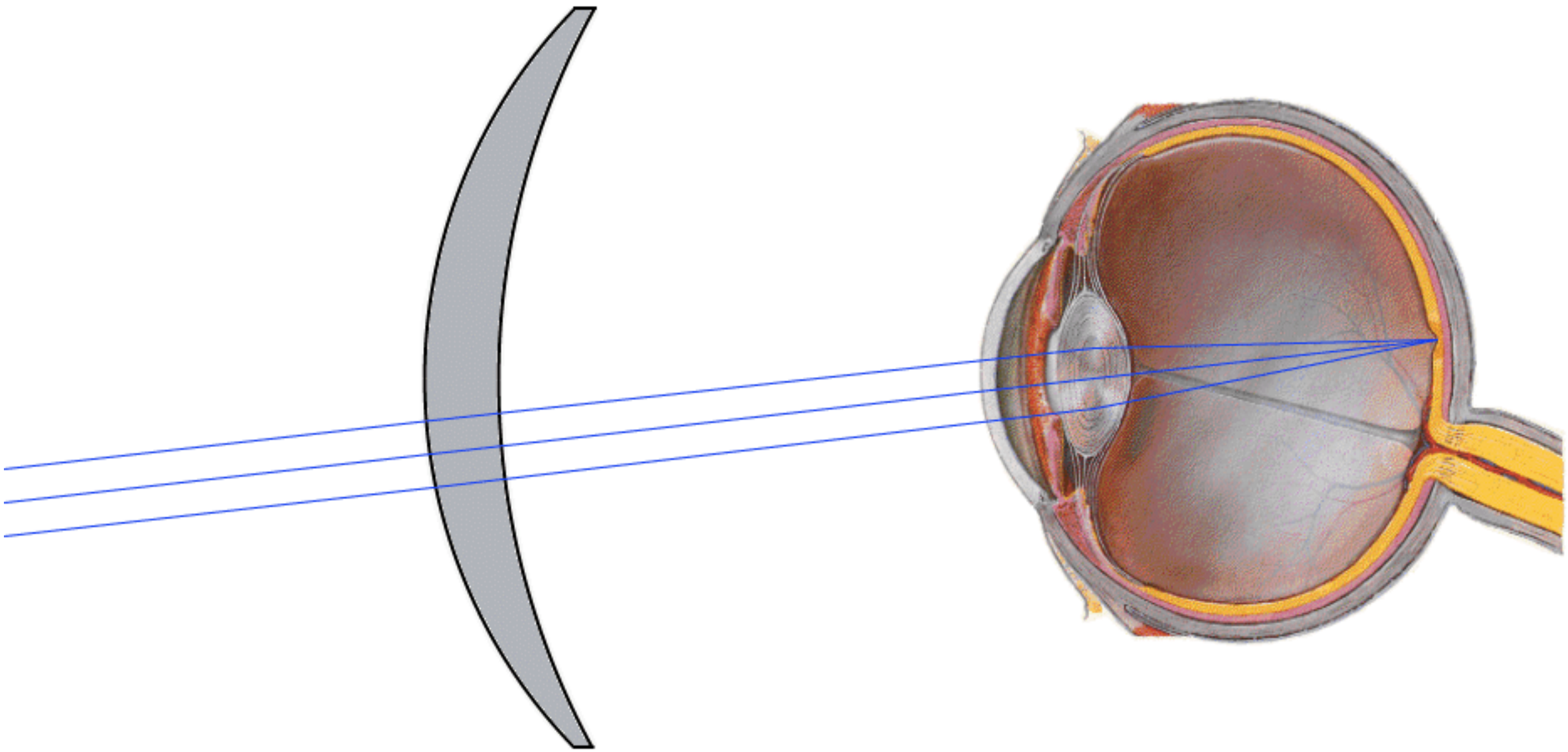

The corrective lens moves the image forward onto the macula
(when it is prescribed correctly).

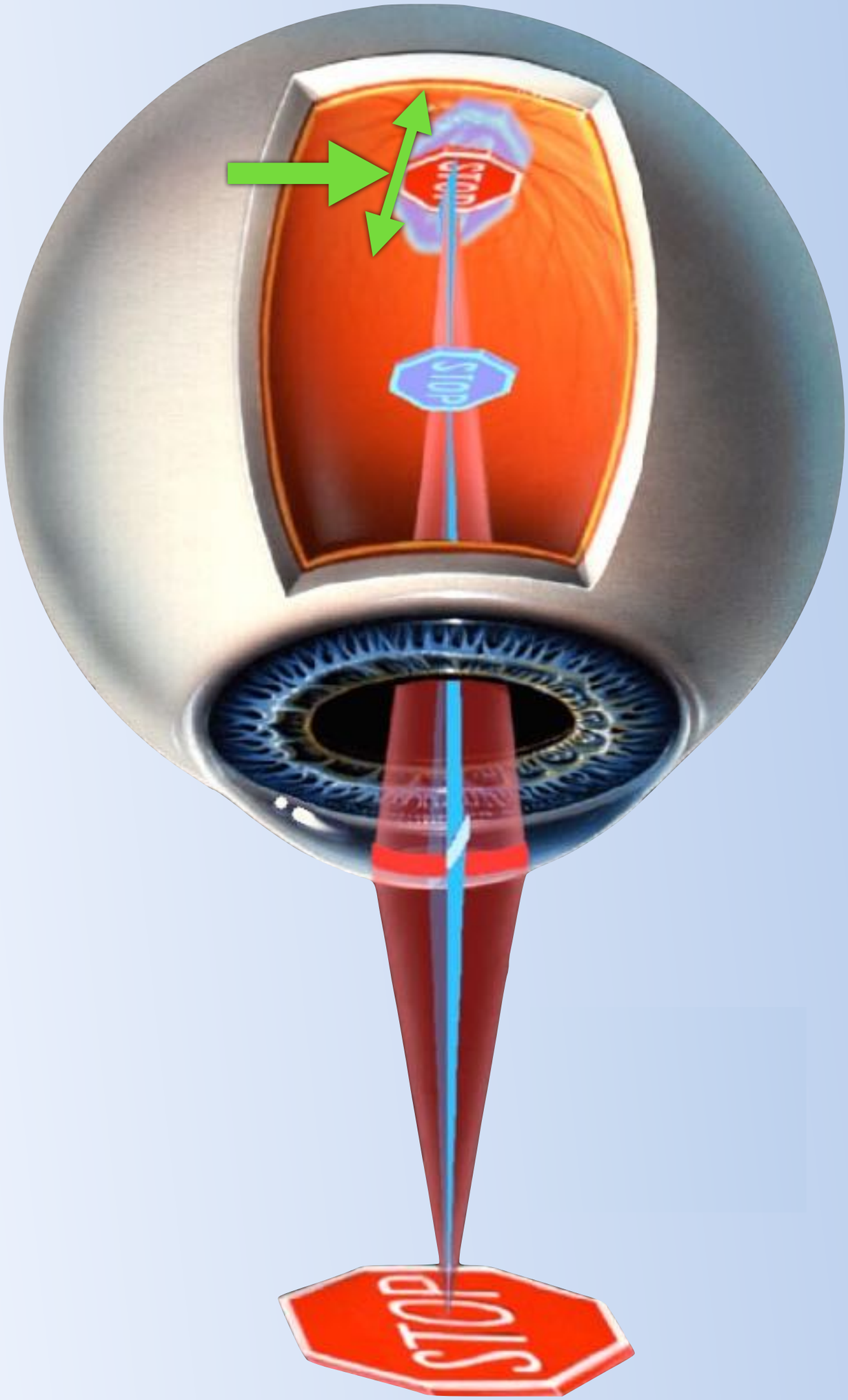
STOP
STOP
STOP

This is astigmatism in a myope - the light from the object we are looking is focused in front of the retina - in two different places!

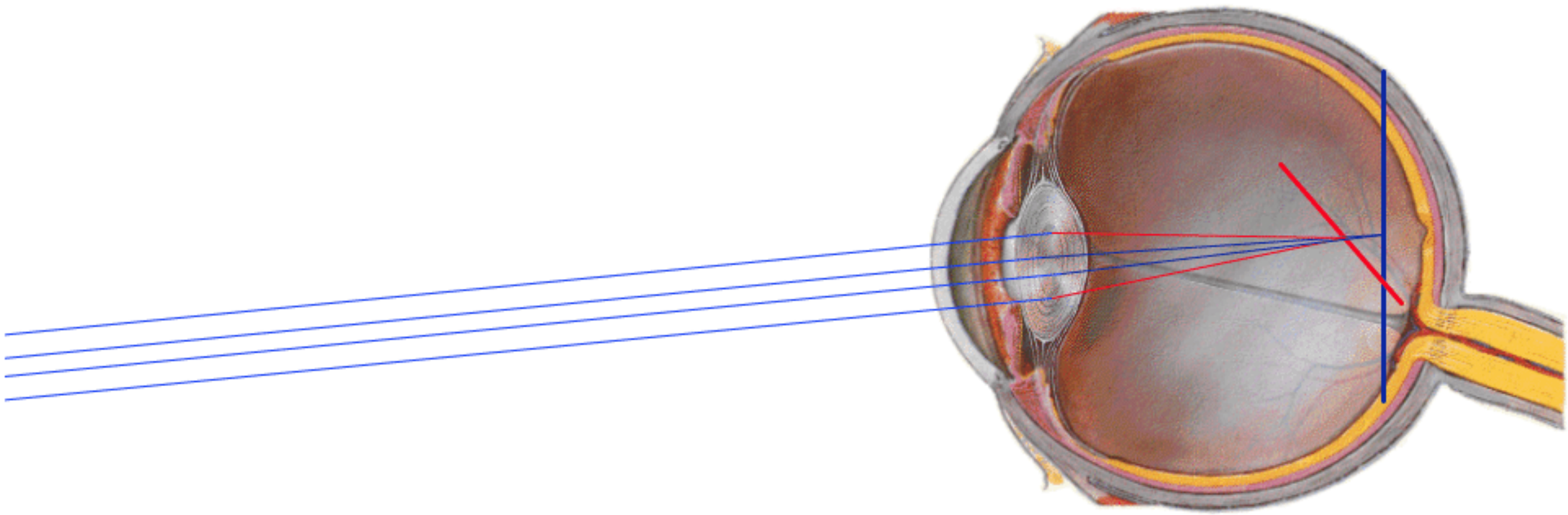

In the vision world, this is called myopic astigmatism.
Vision correction with a minus spherical lens and a cylindrical lens is required.


Horizontal Focus
Vertical Focus

Astigmatism causes blur along one direction

Vertical lines may be more blurred

Horizontal lines may be more blurred

Normal


29
30
31
32
33
34
35
36
37
38
39
40
41
42
43
44
45
46
47
48
49
50
51
test

Vertical Focus Normal

Horizontal Focus Normal

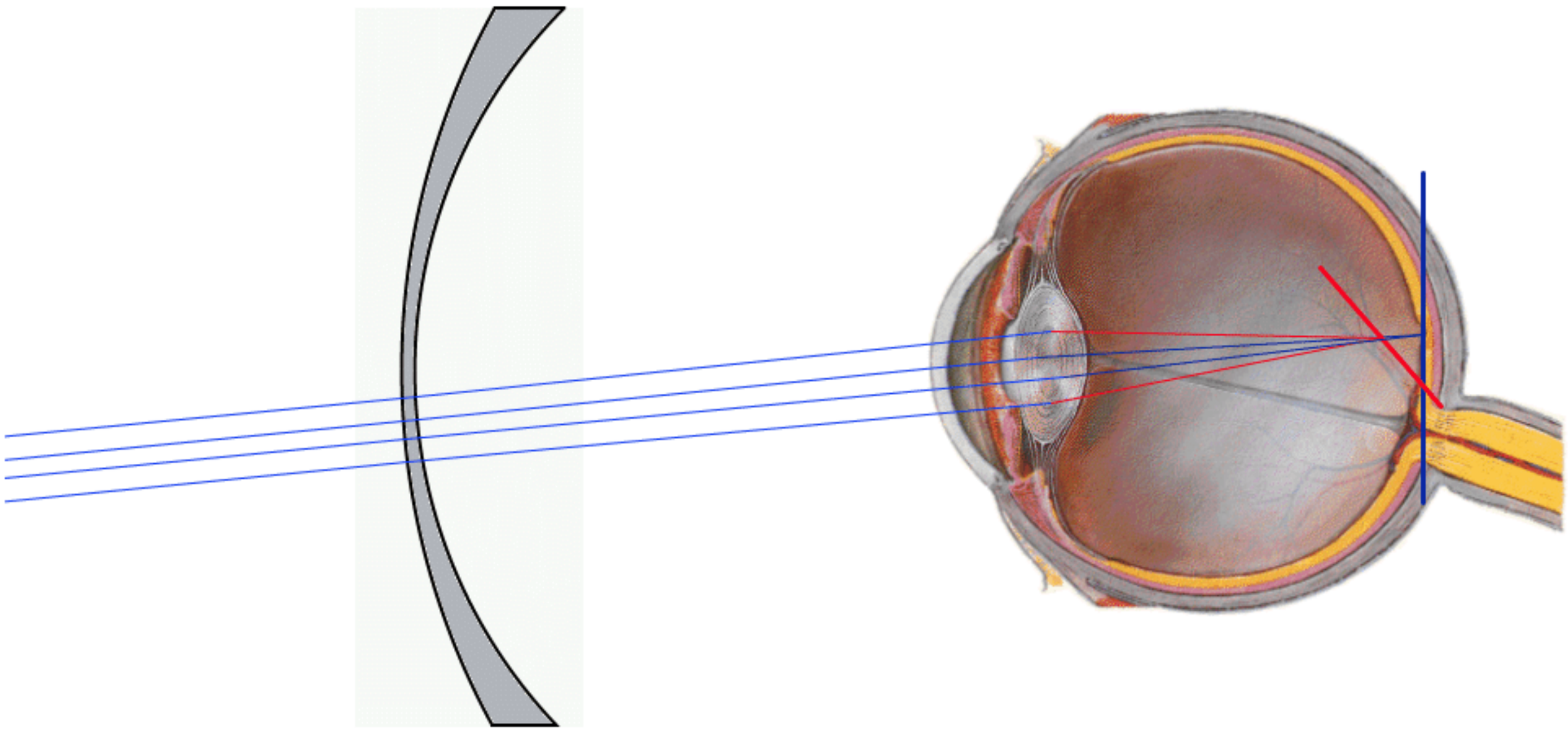

This is the myopic lens portion of the prescription.
It corrects the nearsightedness.

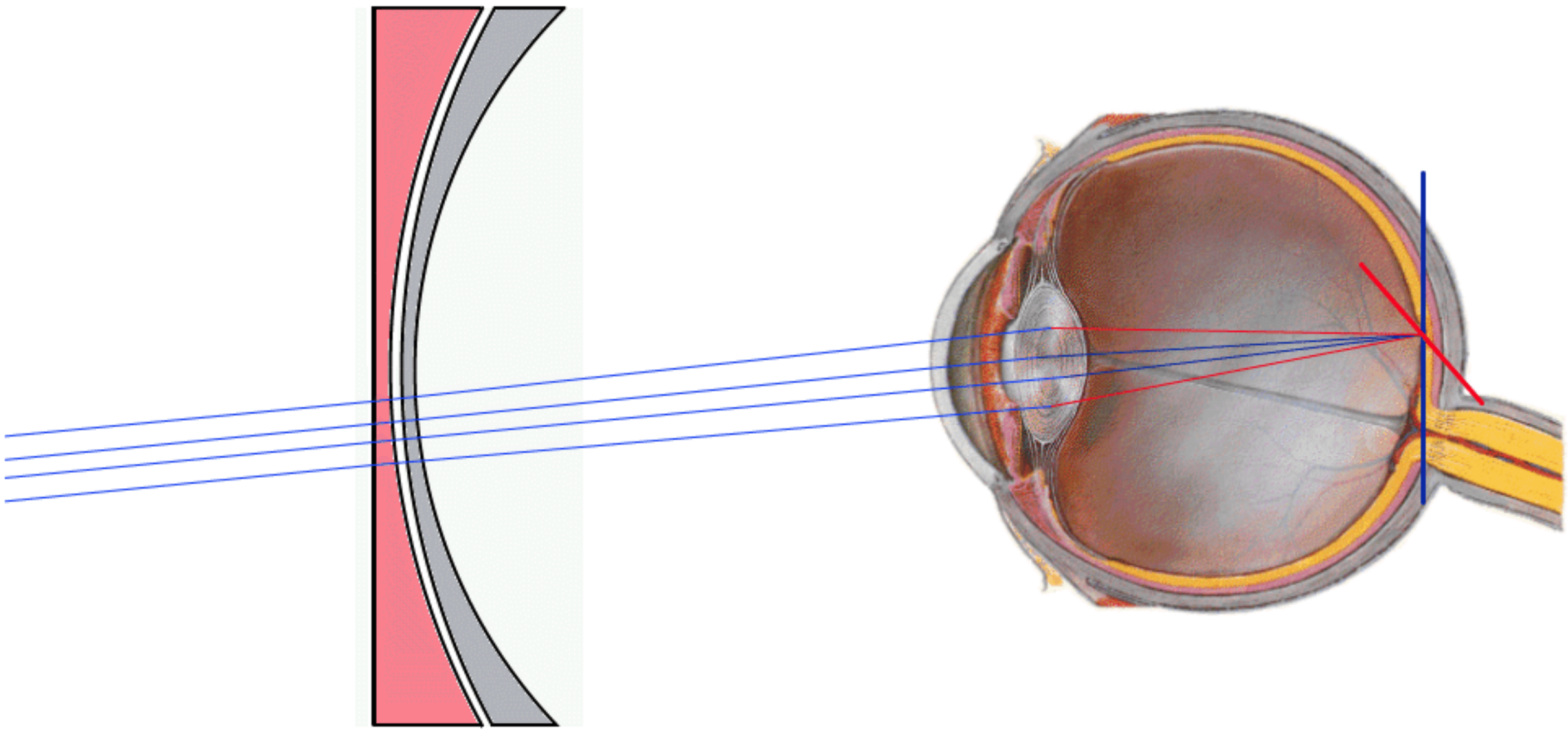

This adds the astigmatism lens portion of the prescription.
It corrects the astigmatism.

This shows how a cylindrical axis corrects astigmatism.
This lens can be rotated to match the patients refractive error.

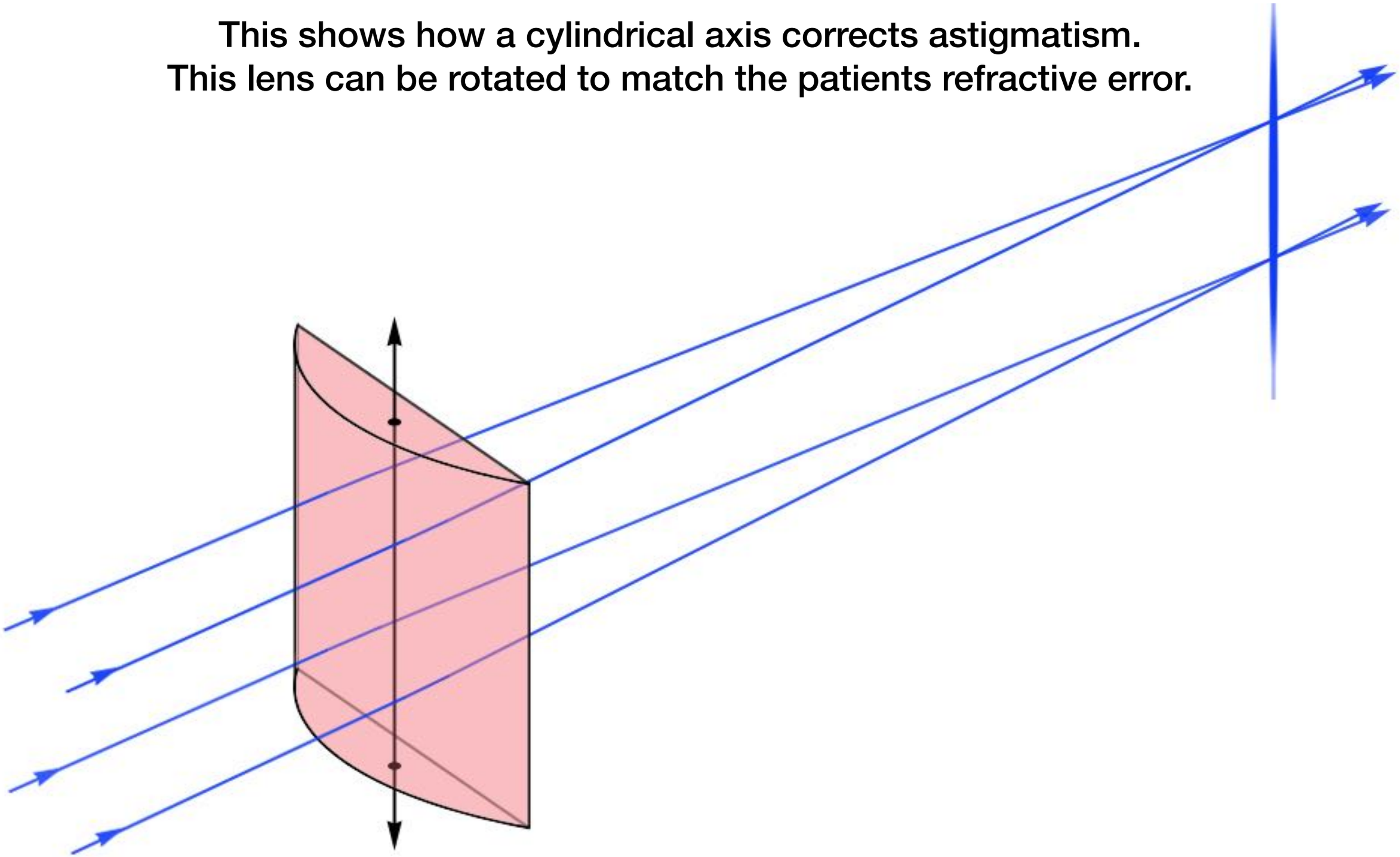

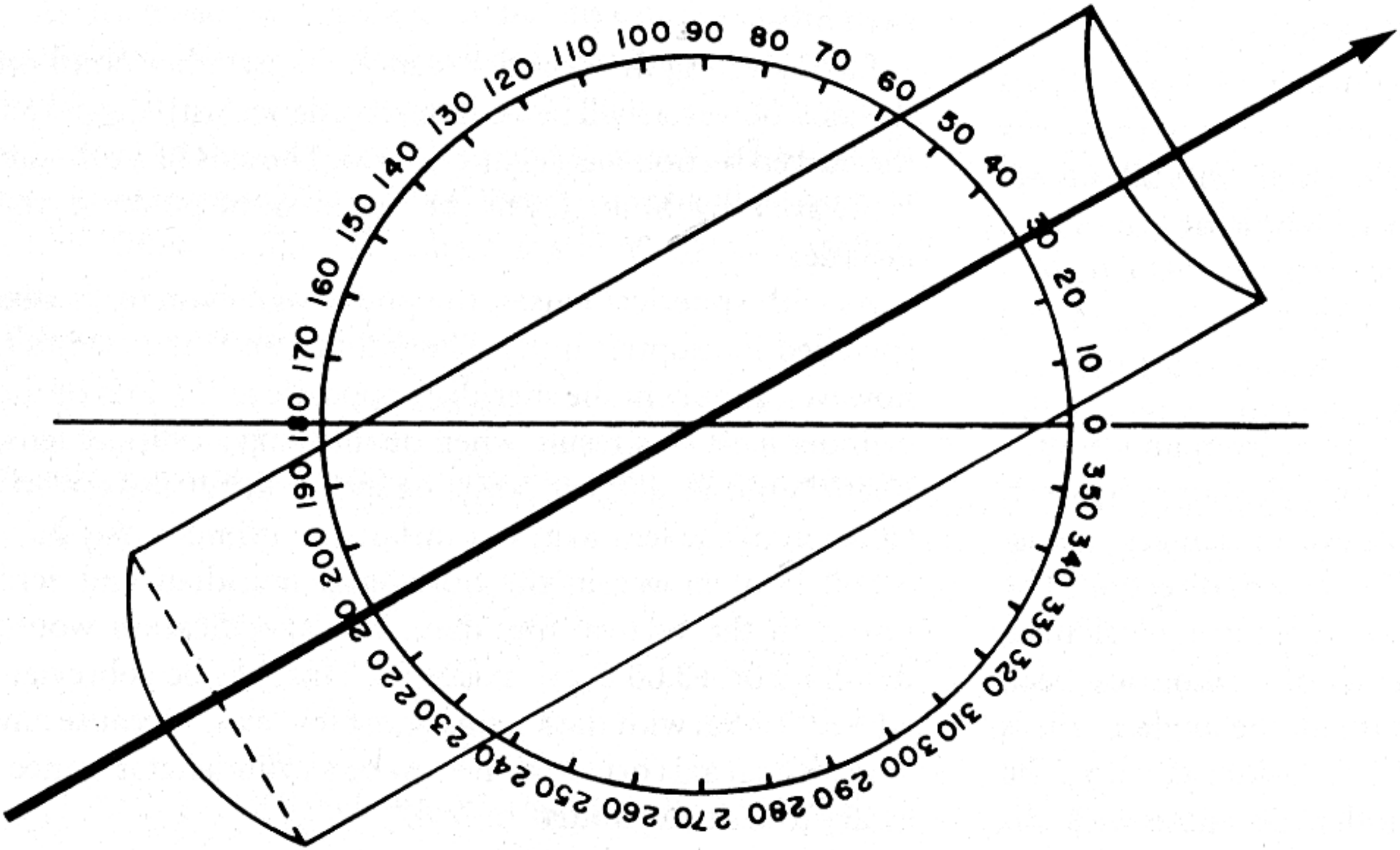
0 10 20 30 40 50 60 70 80 90 100 110 120 130 140 150 160 170 180 190 200 210 220 230 240 250 260 270 280 290 300 310 320 330 340 350

When added to a spherical lens, it can correct near or far sightedness and astigmatism.

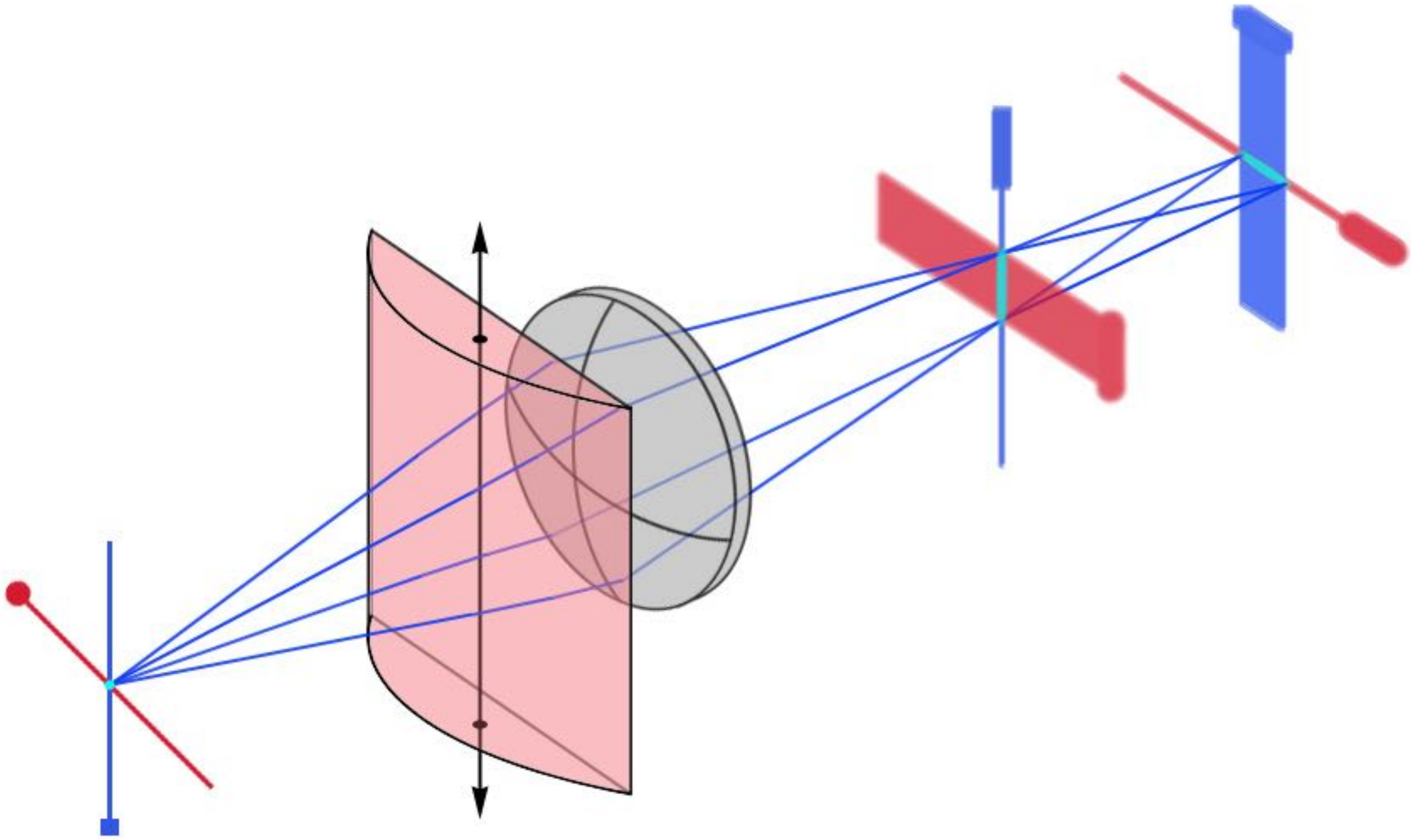

© Just Jobs.com



OK, so now this eyeglass thing is
starting to make the tiniest bit of sense


Only problem is, I can't see how any of this fits with dentistry or the teeth…
That part comes next after the commercial…be patient dear…
©2019 THE AUGUSTA CHRONICLE
caglecartoons.com 6/27

Prisms, and their effects, are the key to understanding how the teeth and eyes fit together.

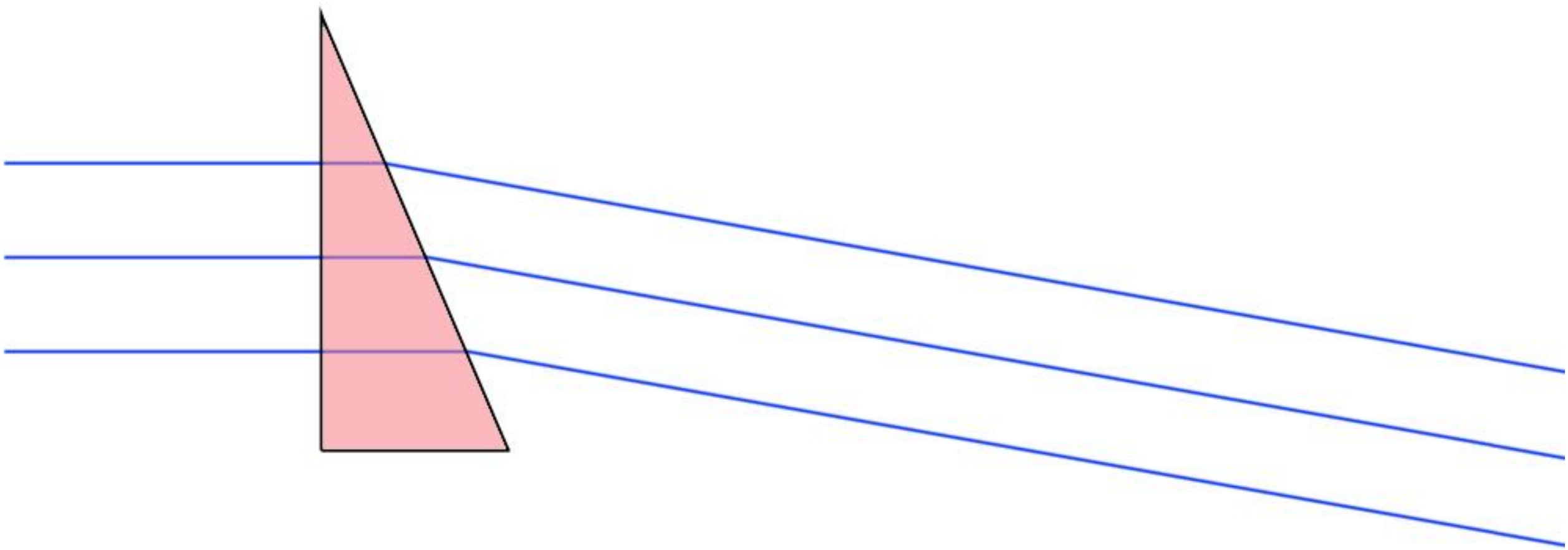

In simple terms, prisms bend light toward their base (the thick part).

Light coming for a far off source produces nearly parallel rays that focus on the macula.

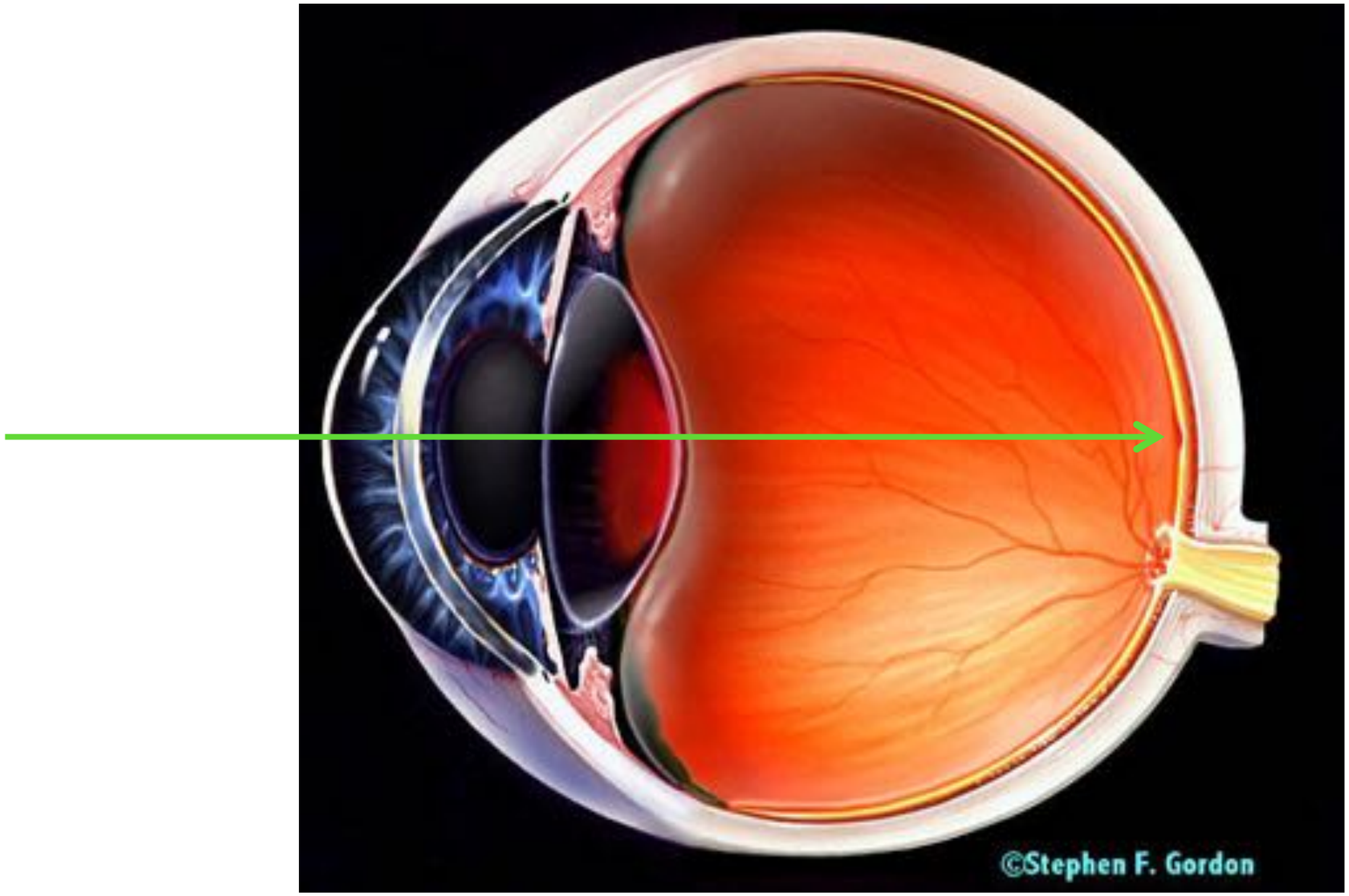

If something happens to move the image
off the fovea, the body will try to correct this error.

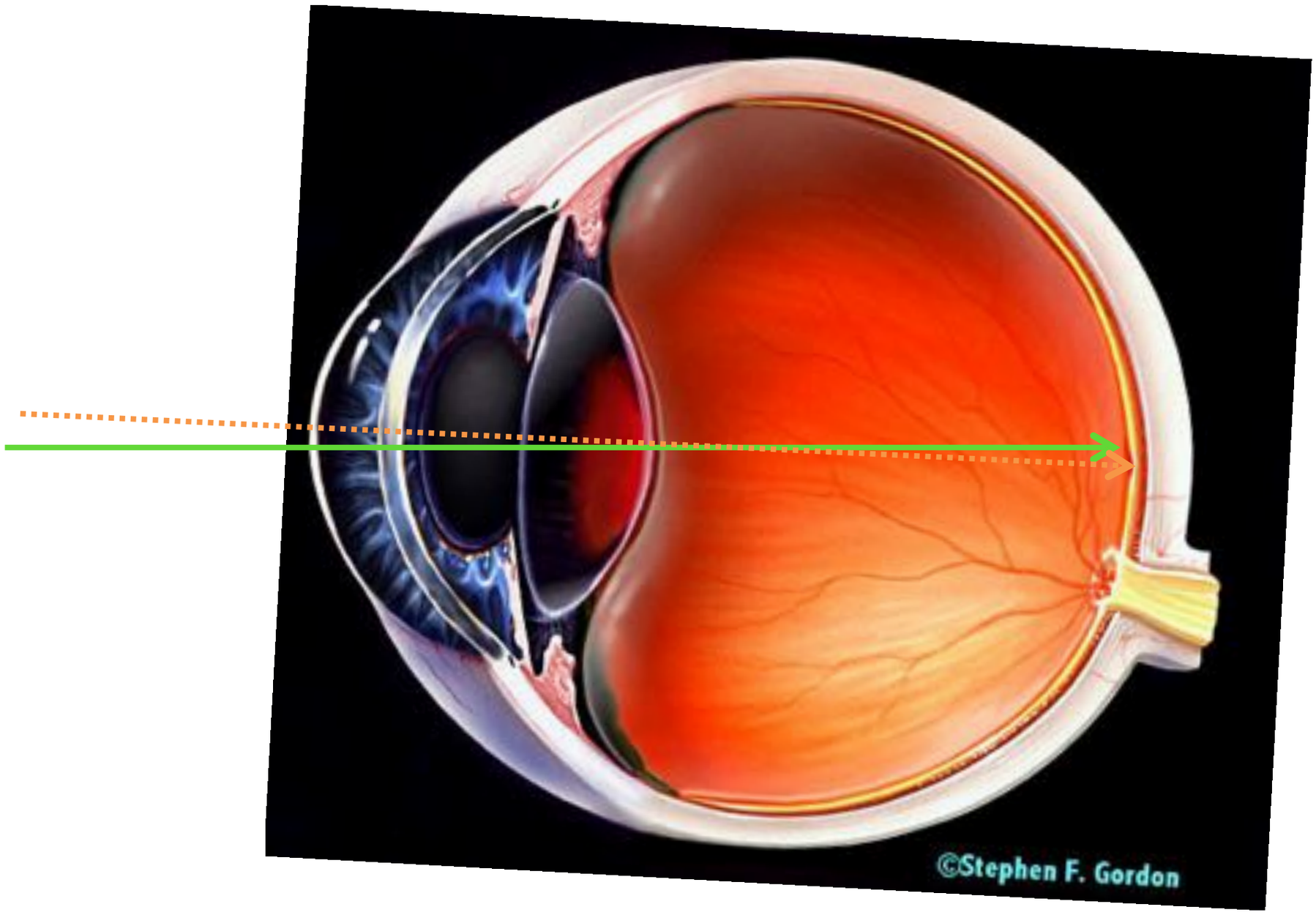

First, it will try to use the muscles that connect to the eye to correct the problem.

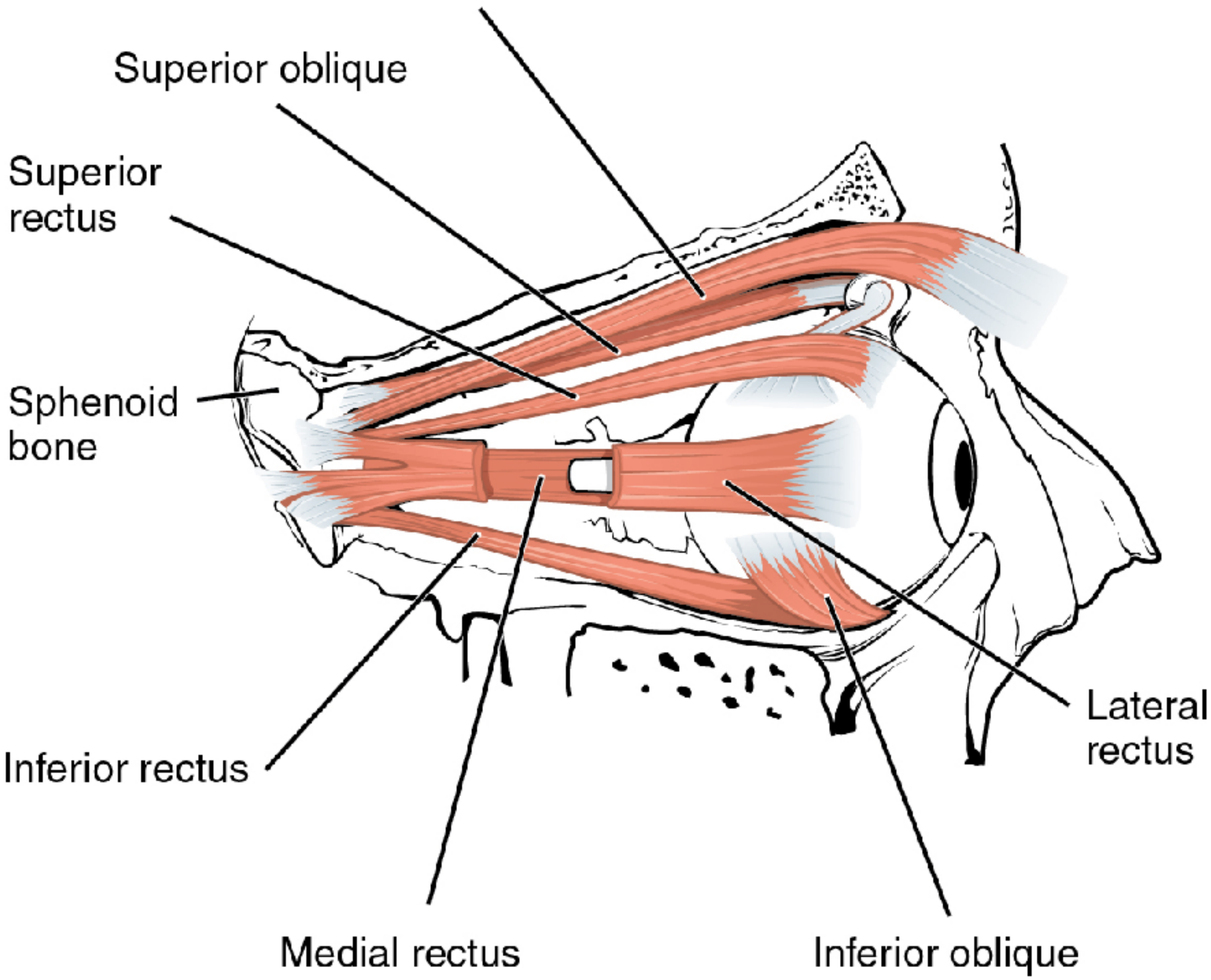
Levator palpebrae superioris
Superior oblique
Superior rectus
Sphenoid bone
Inferior rectus
Lateral rectus
Medial rectus
Inferior oblique

If the eye muscles can correct the problem, great!
There is only a small strain in the head…

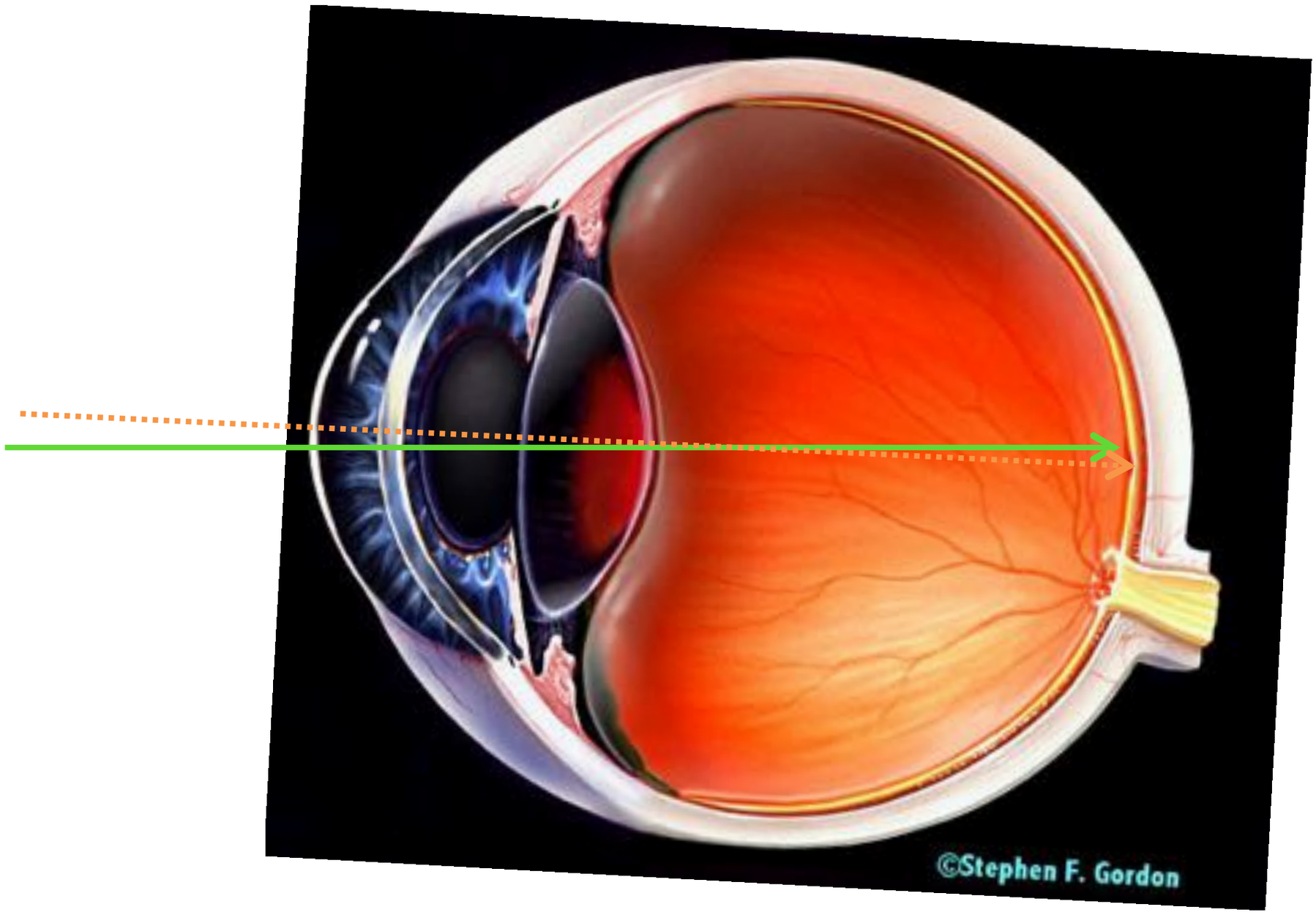

If the eye muscles can't fix the problem, we tip the head first, then the rest of the body…

In the vision world, we can use a prism to shift the light…
and make the image re-center on the macula.

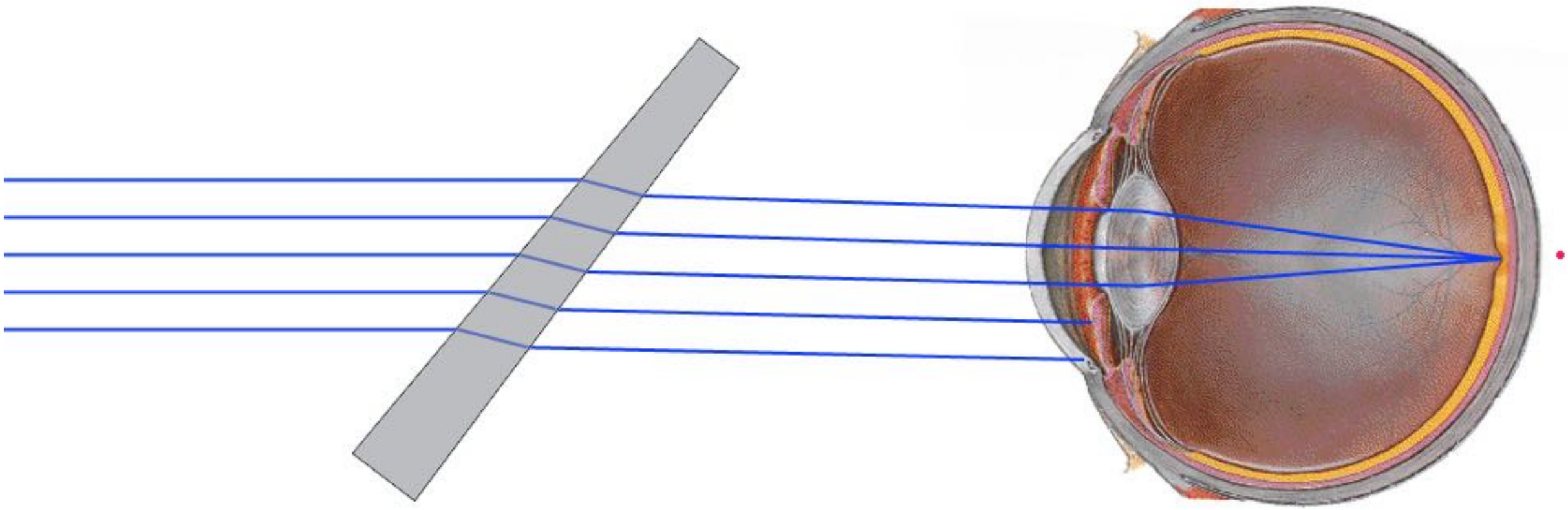

We can place the base of the prism in any of the four compass directions…

A base up prism moves the image up

A base out prism moves the image laterally

A base in prism moves the image medially

A base down prism moves the image down

Extrinsic Eye Muscles

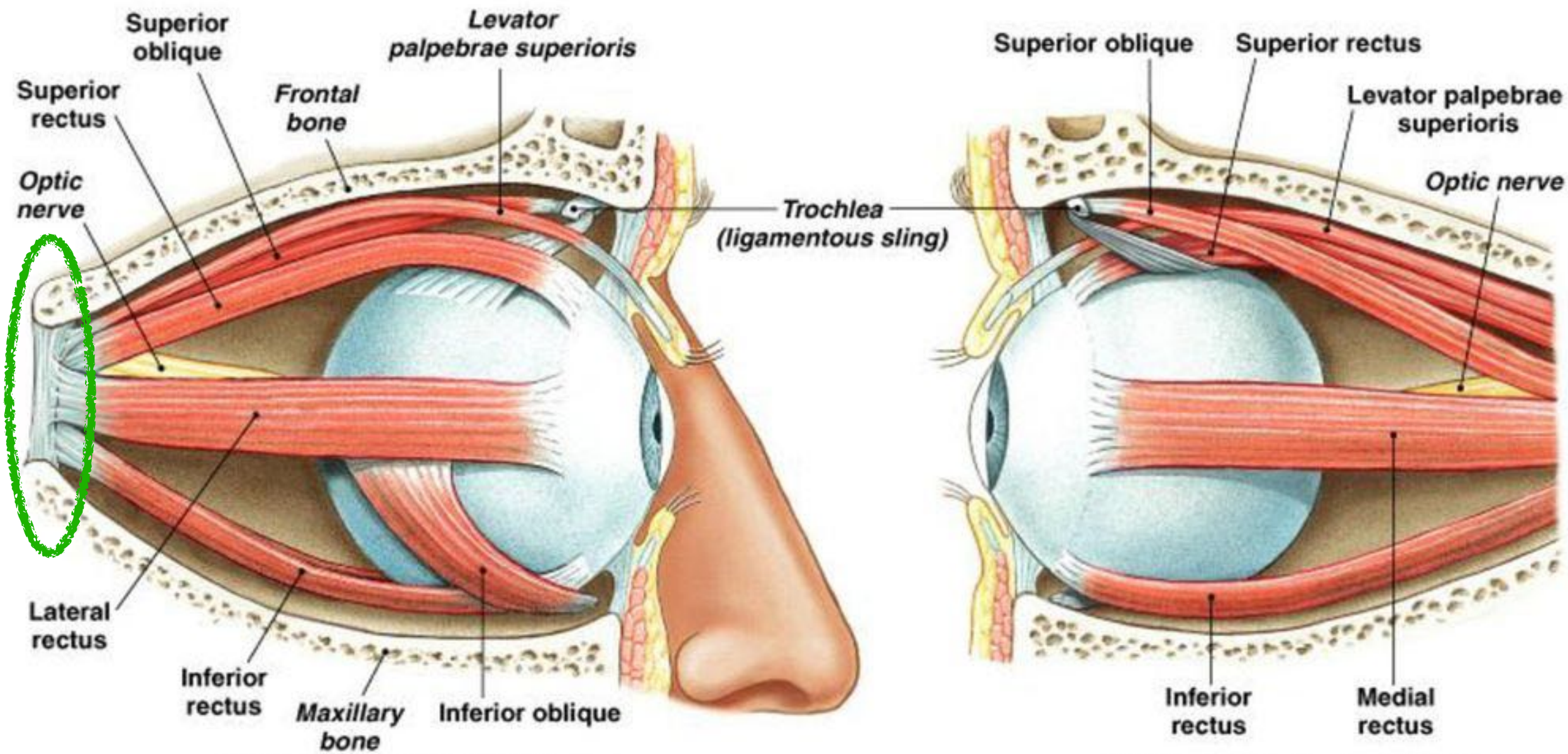

(a) Lateral surface, right eye

(b) Medial surface, right eye

Figure 11–6a Extrinsic Eye Muscles.

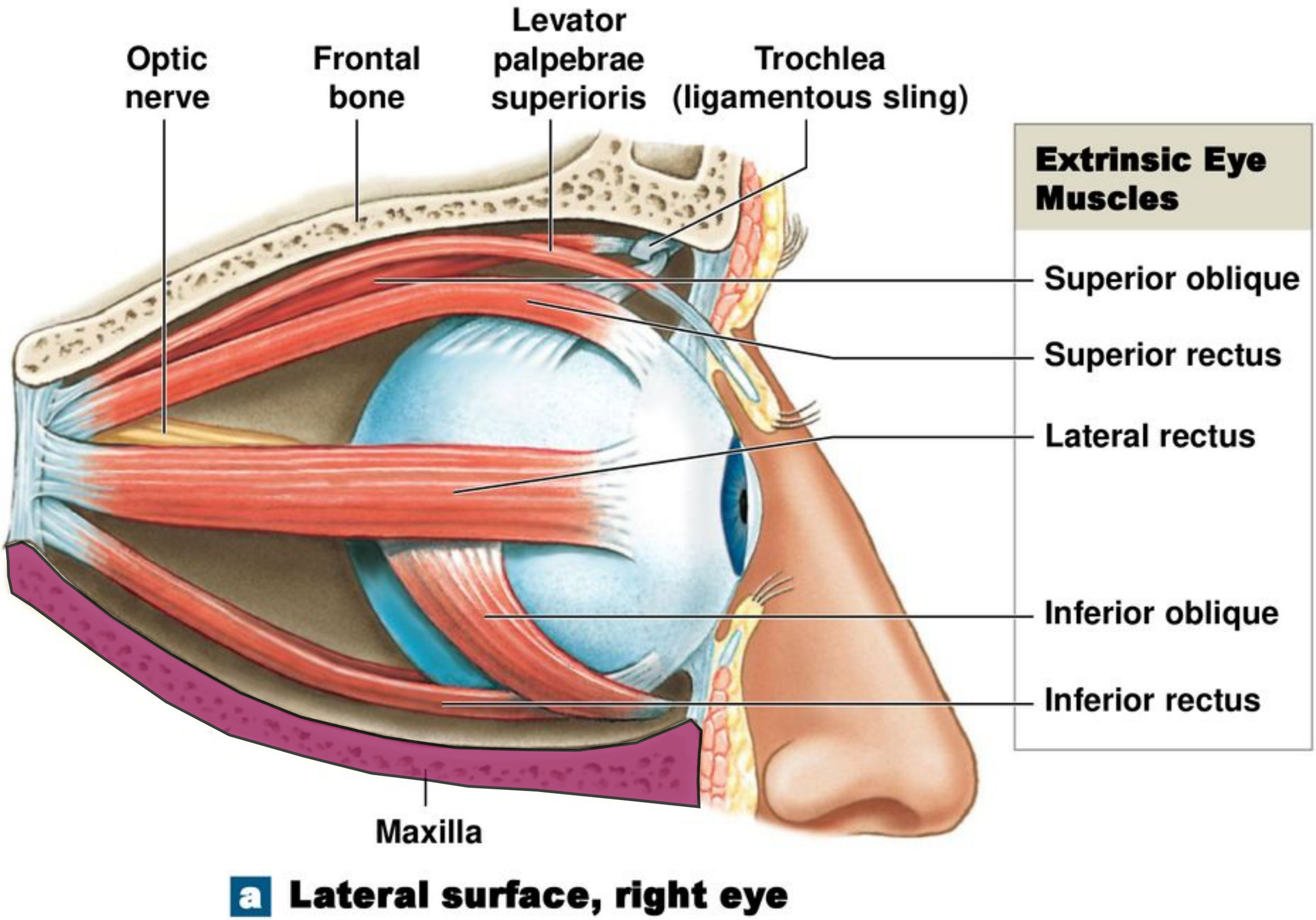

a Lateral surface, right eye

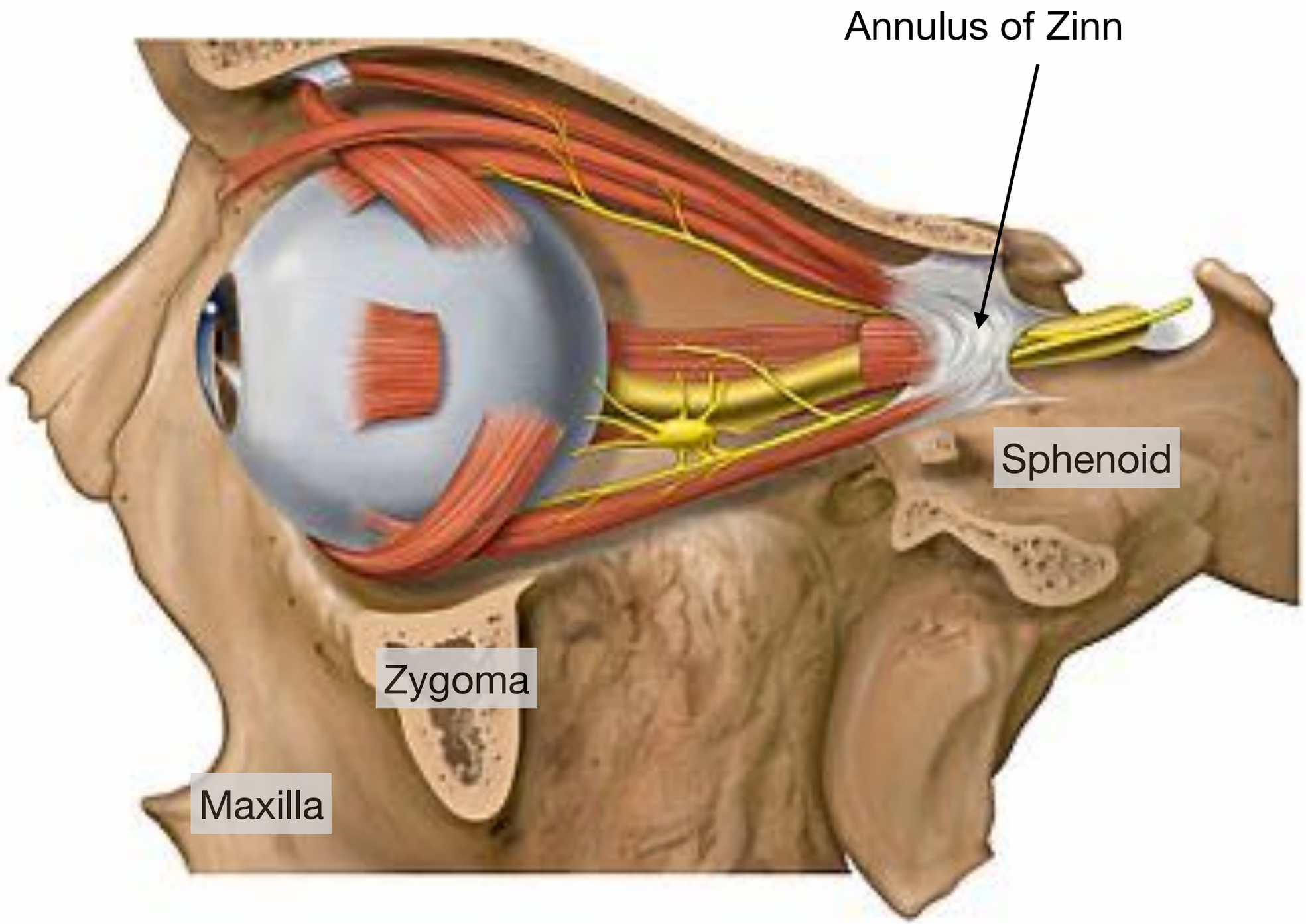
Annulus of Zinn
Sphenoid
Zygoma
Maxilla

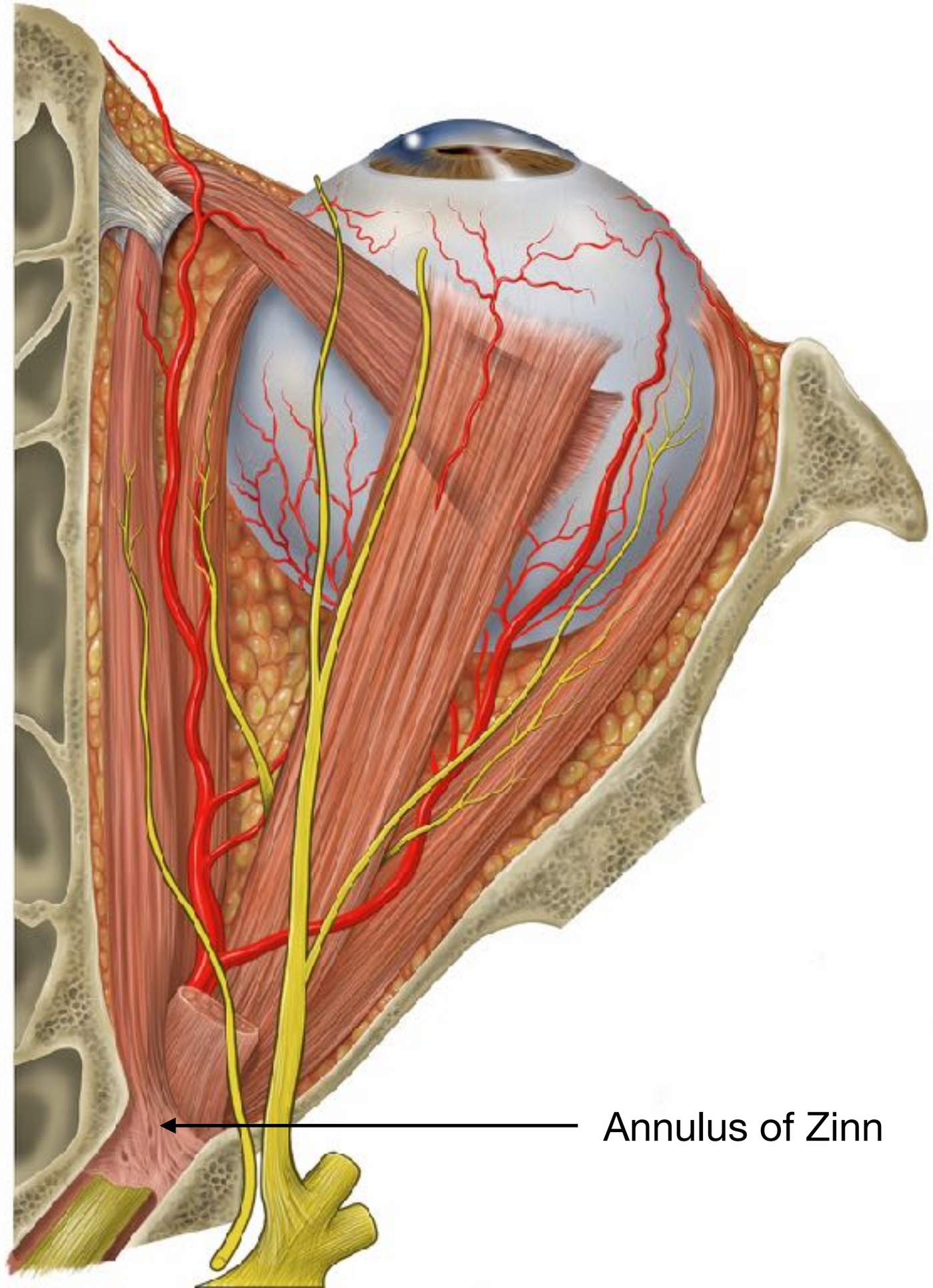
Annulus of Zinn

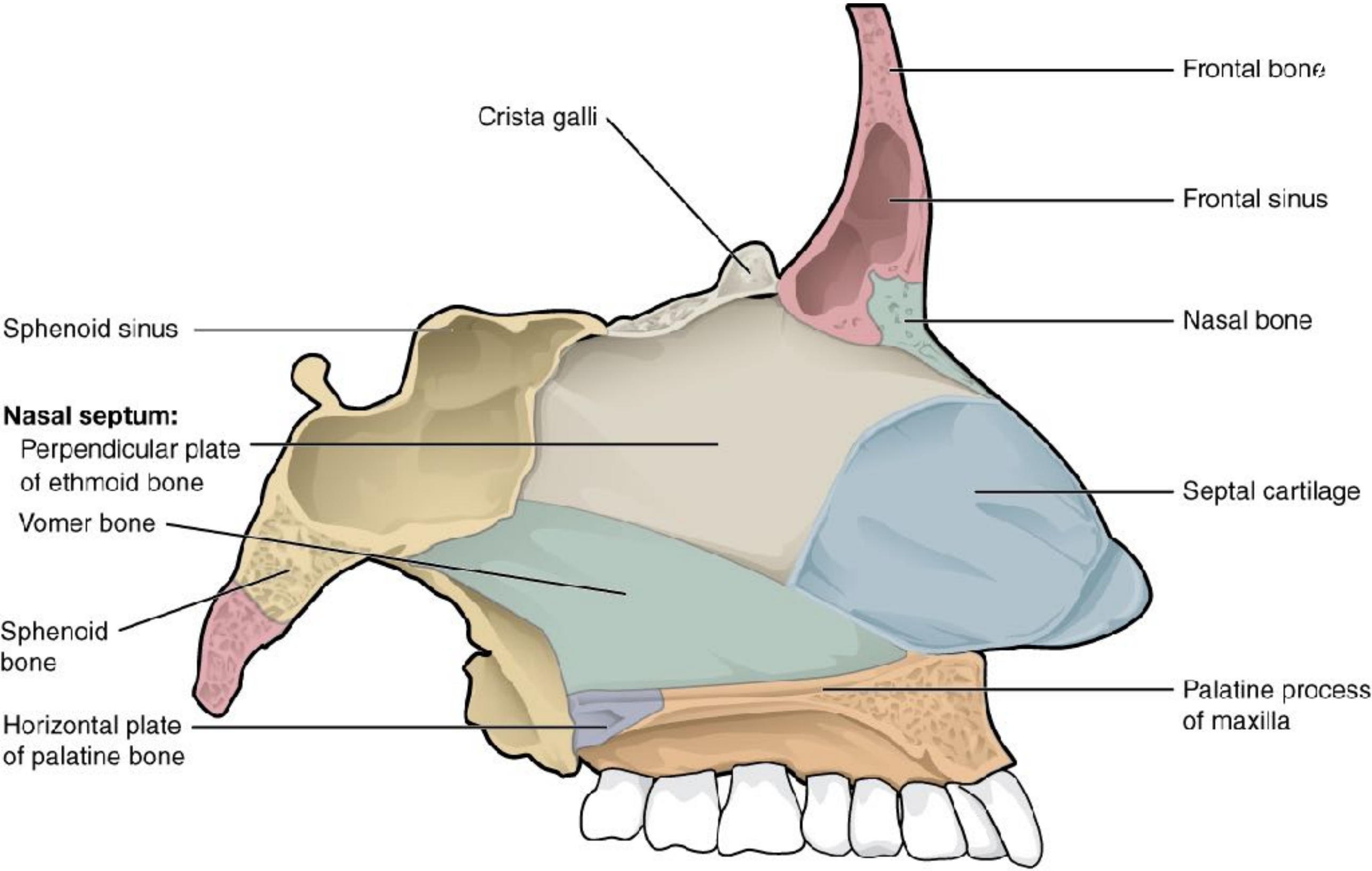

Sagittal section

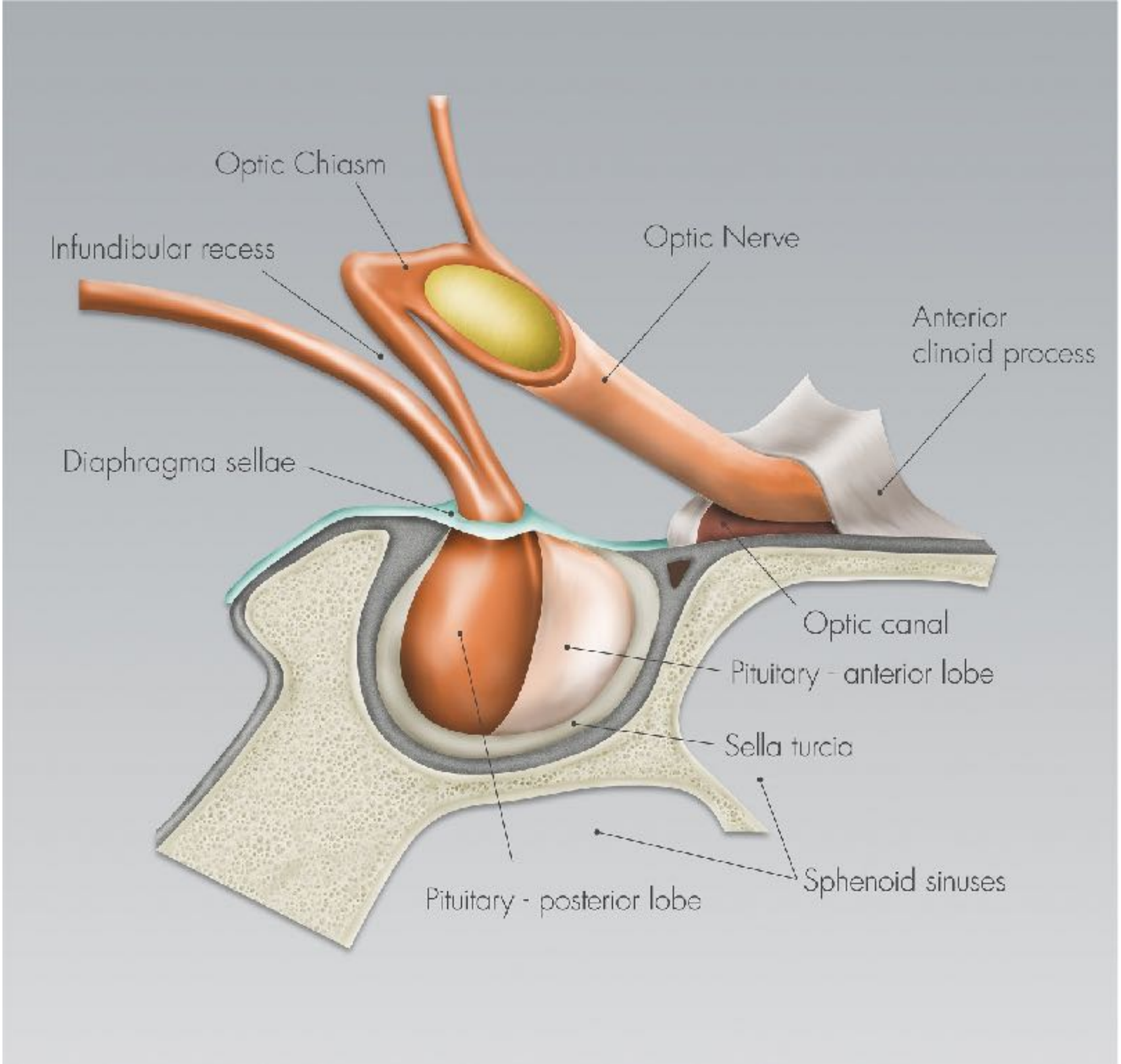
Optic Chiasm
Infundibular recess
Optic Nerve
Anterior
clinoid process
Diaphragma sellae
Optic canal
Pituitary - anterior lobe
Sella turcia
Sphenoid sinuses
Pituitary - posterior lobe

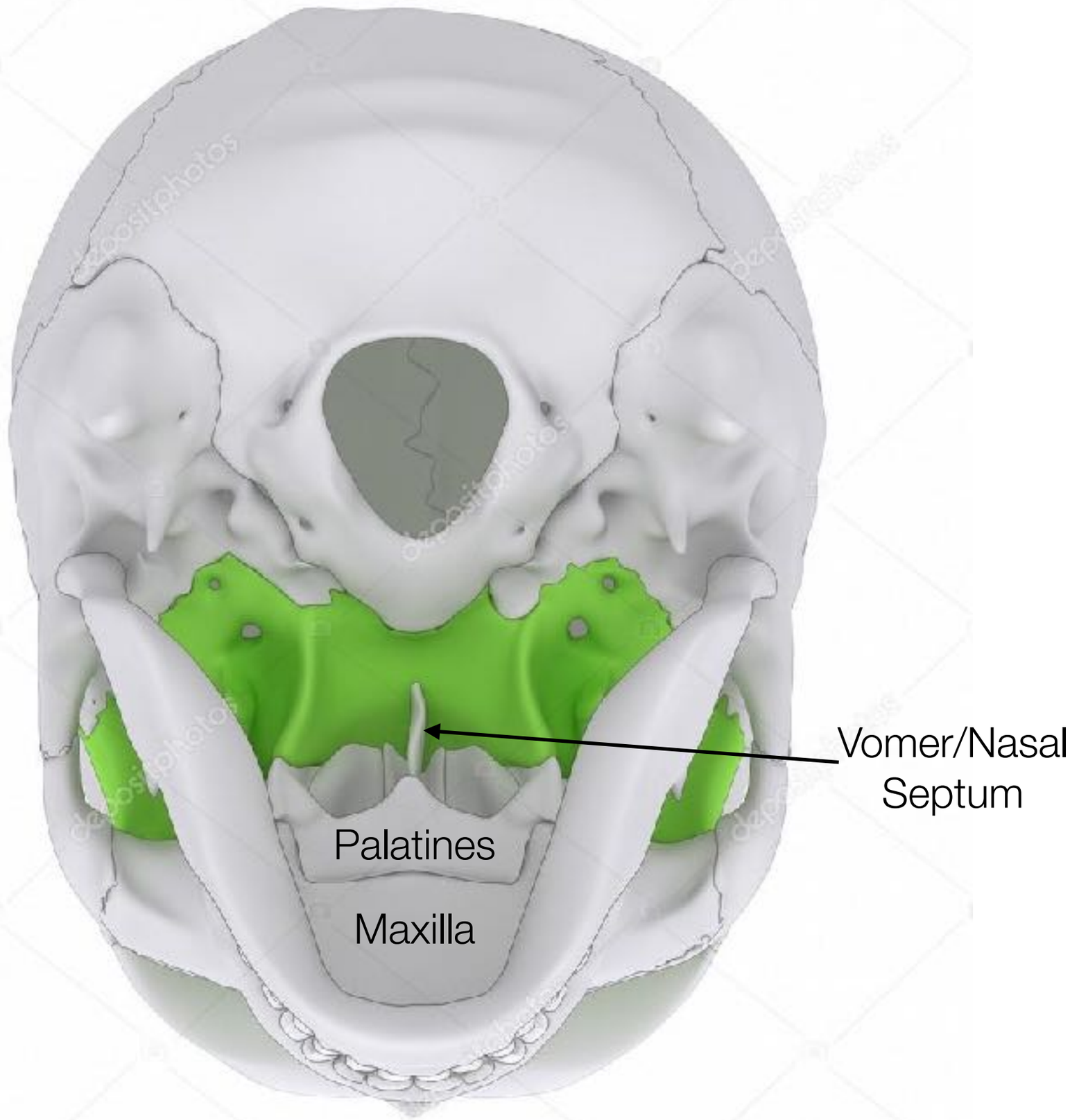
Vomer/Nasal
Septum
Palatines
Maxilla

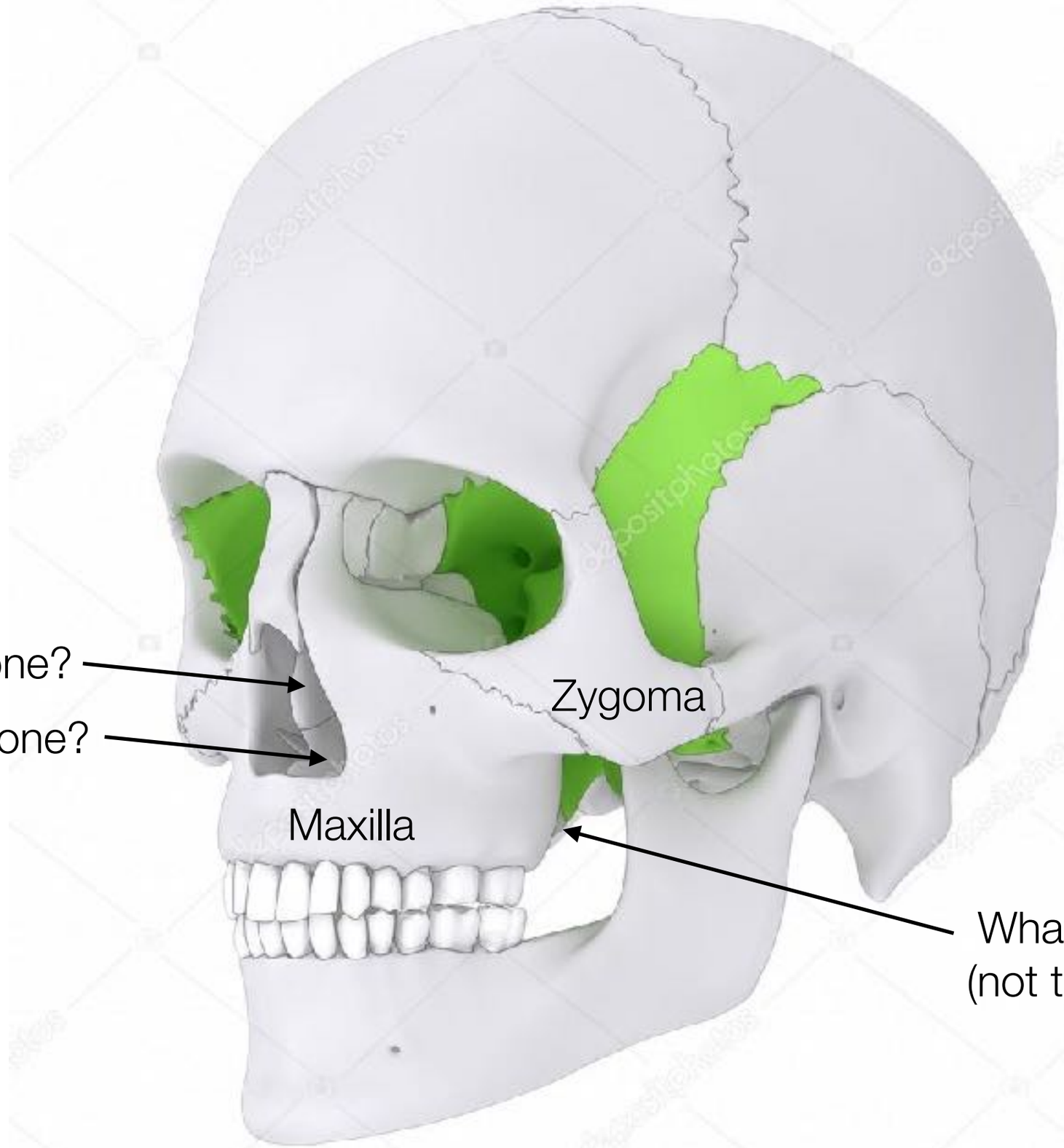
What's this bone?
What's this bone?
Zygoma
Maxilla
What's this bone?
(not the green part)

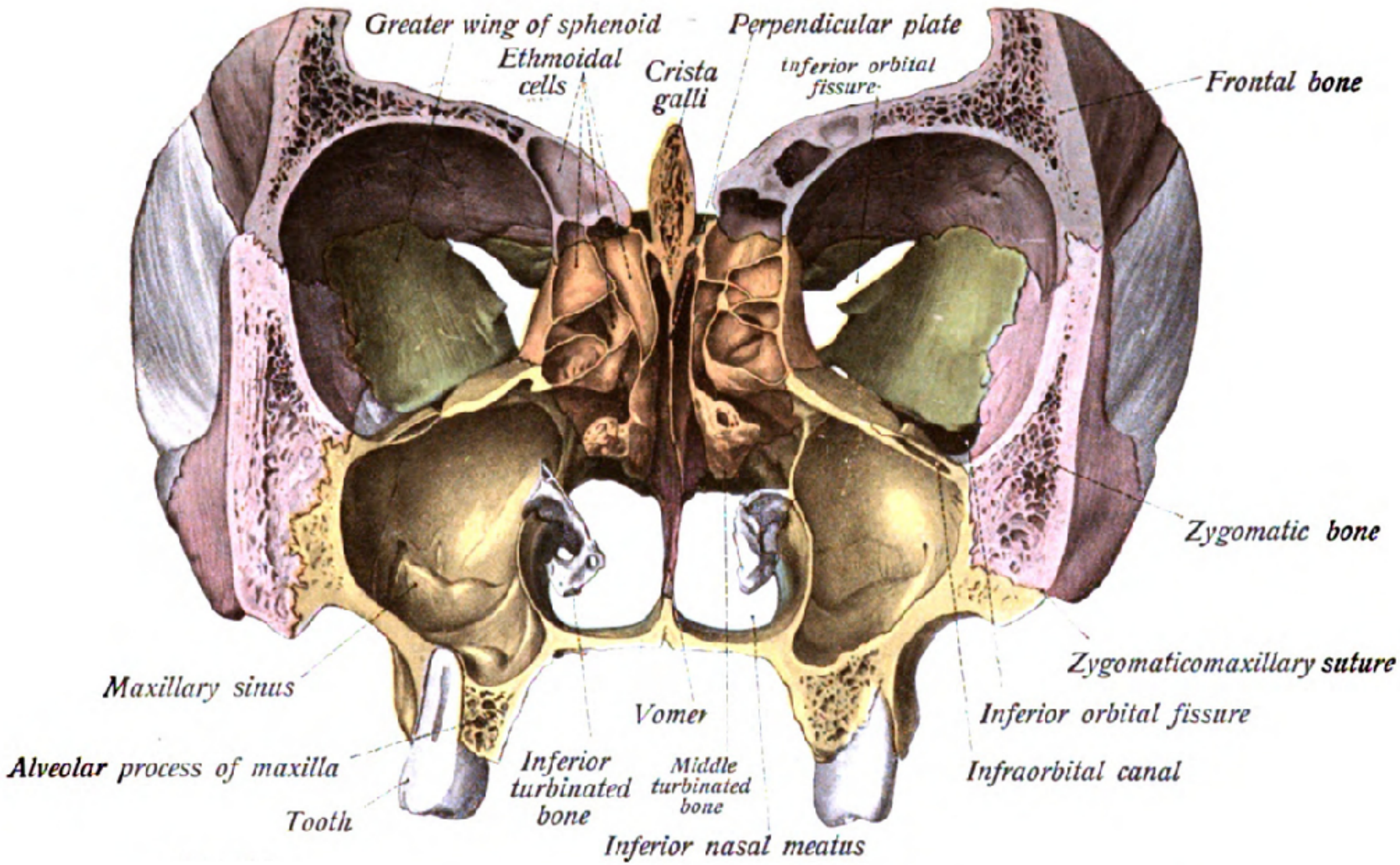
Greater wing of sphenoid
Ethmoidal cells
Crista galli
Perpendicular plate
Inferior orbital fissure
Frontal bone
Zygomatic bone
Zygomaticomaxillary suture
Maxillary sinus
Vomer
Inferior orbital fissure
Alveolar process of maxilla
Inferior turbinated bone
Middle turbinated bone
Infraorbital canal
Tooth
Inferior nasal meatus

Aaaack,
What does it all mean???

We must now understand about the glasses and how they work..

Fitting for the Center of Grind

- Each lens has a vertical height and horizontal width. Somewhere in that space is the optical center of the lens (the center of grind).

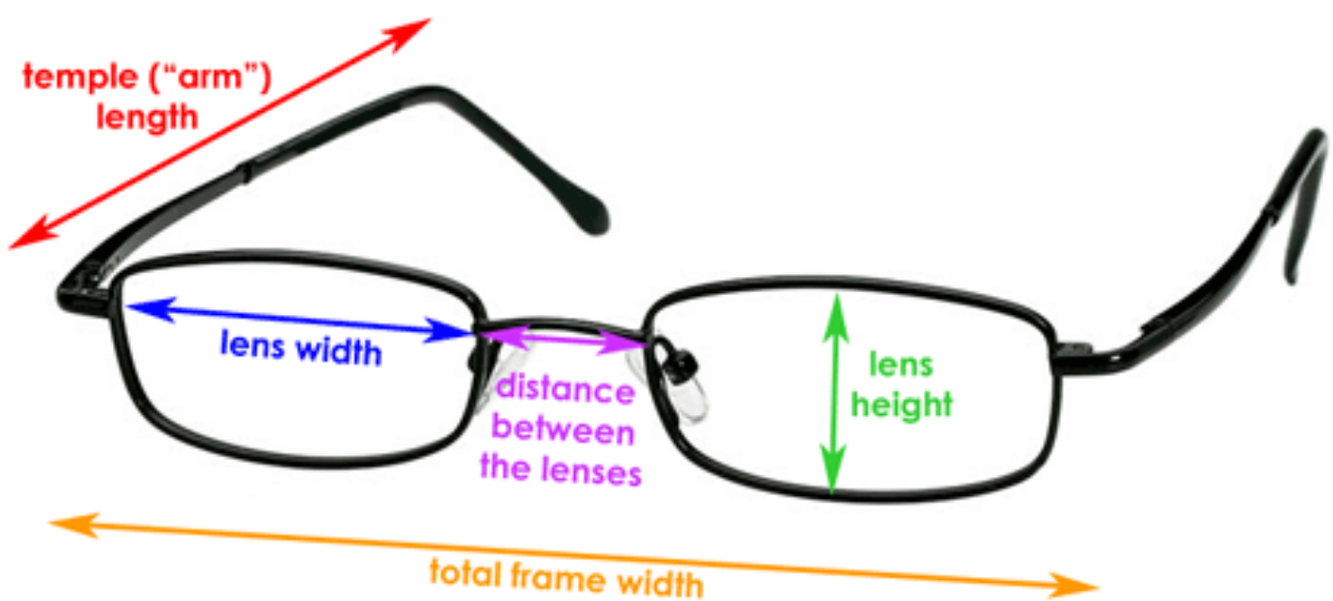

http://www.thefinancialhelpcenter.com/Health-Pics/h003.gif

Fitting for the Center of Grind

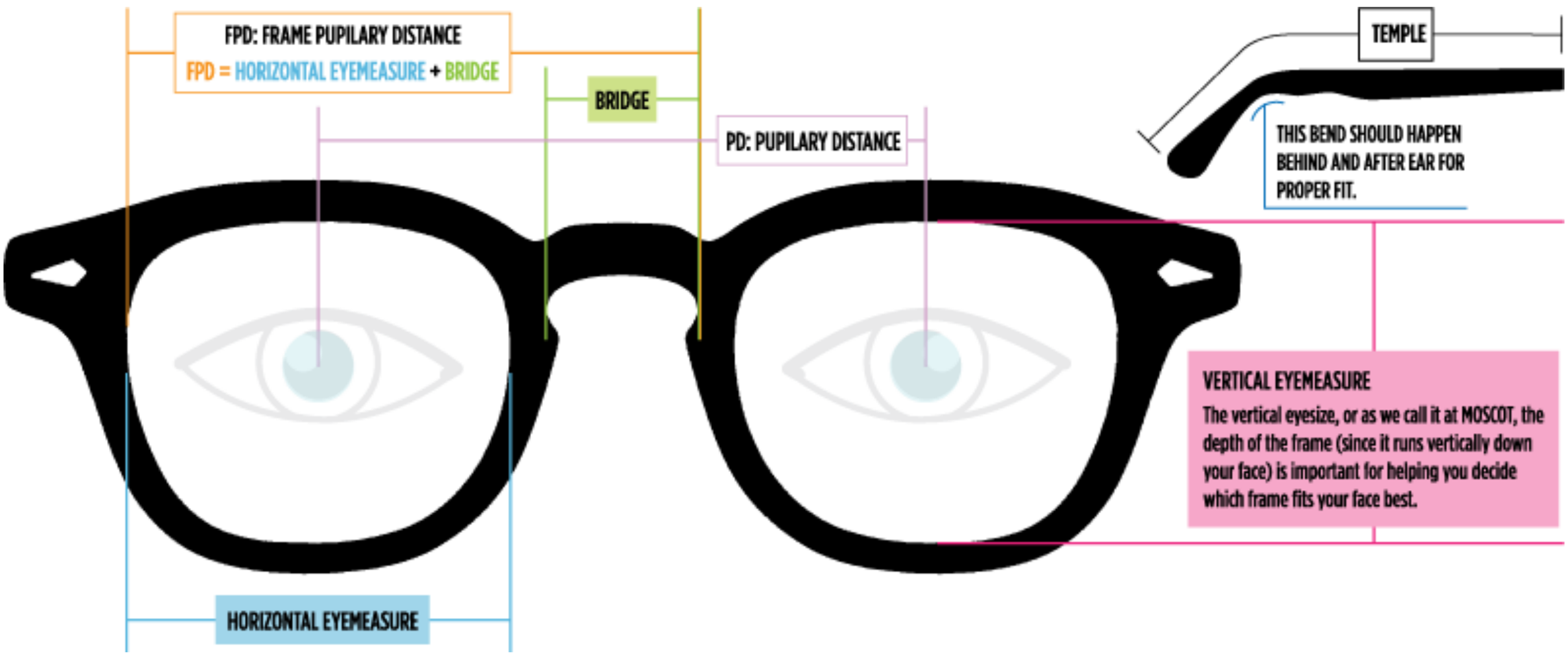

http://www.moscot.com/images/sz_chart.png

Optical Centers

- By convention, the optical center of a single vision lens is place in the middle of the vertical height of the lens.

http://www.eye-care-services.com/uploads/eyeglasses0.jpg

Optical Centers

- The pupillary distance from the midline of the nose is the other measurement that determines the optical center.



Optical Centers

- These measurements together give the lab a precise place to place the optical center of the lens.
- Any viewing outside of this location will generate a prismatic effect.



Any viewing outside the optical center of the lens will generate a prismatic effect

By definition, this will generate a change in the bones of the skull as they try to keep the light focused on the macula.
If the strain is big enough it will trickle down to the body as well.

Oh, yeah, that strain affects in some way all of the bones of the head, including the maxilla, zygoma, mandible and sphenoid…
and don’t forget the tongue…

Cut to the chase sonny…
I ain’t gettin any younger…

When a patient is wearing glasses (or has a prismatic visual strain)

AND they have a dental strain
(that requires some kind of correction)

The eyes always have the right of way
if two strains are competing
(one visual and one dental)

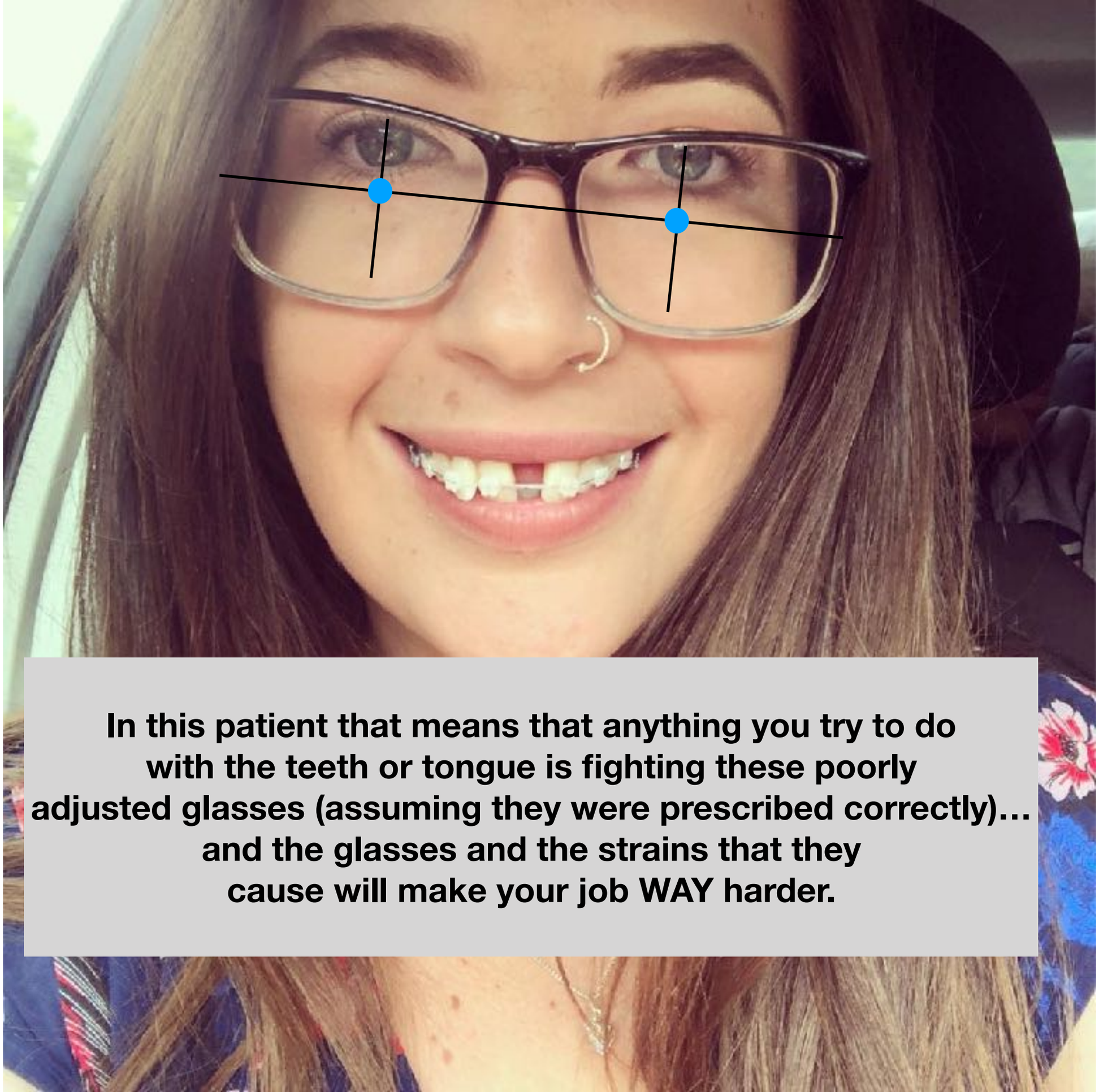

In this patient that means that anything you try to do with the teeth or tongue is fighting these poorly adjusted glasses (assuming they were prescribed correctly)… and the glasses and the strains that they cause will make your job WAY harder.

Let’s revisit a patient from a previous presentation

FaceLiftDentistry.com
© Sam Muslin, DDS
Photo taken 3 years after treatment was completed
Copyright Sam Muslin DDS

FaceLiftDentistry.com
© Sam Muslin, DDS
Photo taken 3 years after treatment was completed
Copyright Sam Muslin DDS

FaceLiftDentistry.com
© Sam Muslin, DDS
Photo taken 3 years after treatment was completed
Copyright Sam Muslin DDS

That means that the teeth were moved, the face straightened, and the cosmetic effect is ascetically pleasing, but the eyes were moved closer together… if this patient were in glasses, it could have spelled trouble…

because it cranially translates into an inferior vertical strain…which can cause headaches, etc…and would have been fighting the glasses.

Let’s look at how…

We can place the base of the prism in any of the four compass directions…
and it has an effect…

A base up prism moves the image up
both eyes done together, will cause a pantoscopic tilt,
done individually, will neutralize a side bending/rotation

A base out prism moves the image laterally
and neutralizes a superior vertical strain

A base in prism moves the image medially
and neutralizes an inferior vertical strain

A base down prism moves the image down done together, will cause a pantoscopic tilt, done individually, will neutralize a side bending/rotation

A brief trip around adjusting eyeglasses…

Just as putting more or less force in one direction on certain teeth can influence the cranium and its strain patterns, so can adjusting eyeglasses…

Optical Center

Fitting for the Center of Grind

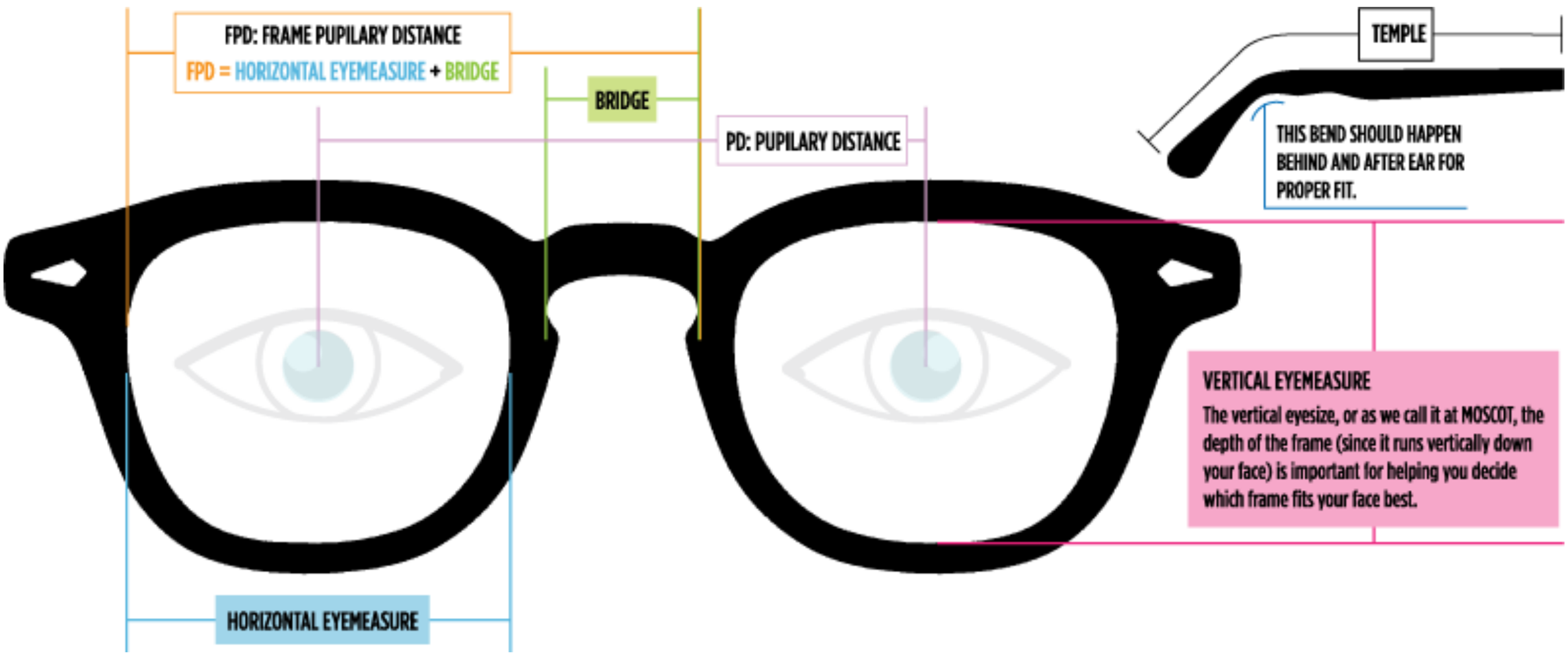

http://www.moscot.com/images/sz_chart.png

Optical Centers

- By convention, the optical center of a single vision lens is place in the middle of the vertical height of the lens.



http://www.eye-care-services.com/uploads/eyeglasses0.jpg

Optical Centers

- Notice in these glasses the center of the vertical height of the lens is not in the center of the vertical height of the pupil.
- These frames are not fitted to the person correctly.
- We will learn how to correct this soon.



http://www.eye-care-services.com/uploads/eyeglasses0.jpg

Optical Centers

- The pupillary distance from the midline of the nose is the other measurement that determines the optical center.



http://www.eye-care-services.com/uploads/eyeglasses0.jpg

Optical Centers

- The pupillary distance is the width (in mm) between the center of the pupils.
- It can be measured as a whole (measuring between the pupils) or as individual sides (between the center of the pupil and the center of the bridge of the nose).



http://www.eye-care-services.com/uploads/eyeglasses0.jpg

Optical Centers

- These measurements together give the lab a precise place to place the optical center of the lens.

- Any viewing outside of this location will generate a prismatic effect.



http://www.eye-care-services.com/uploads/eyeglasses0.jpg

Optical Centers

- Since the center of the prescription is a tiny bit higher than the center of the pupil, this will generate a small prismatic effect.

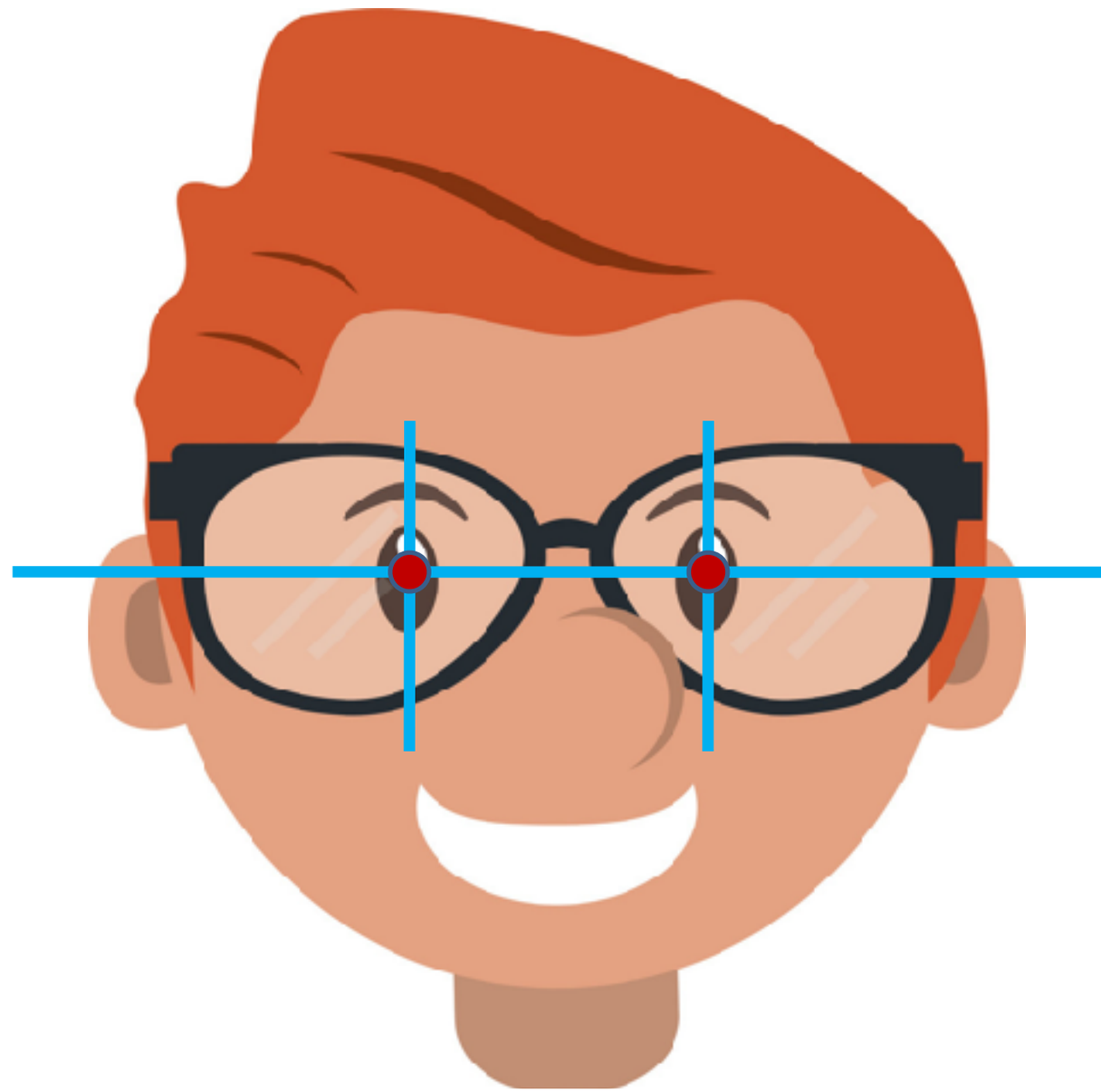

http://www.eye-care-services.com/uploads/eyeglasses0.jpg

Optical Centers

- So the first thing to do it to place the optical centers of the lenses directly in front of the patients pupils.

- The optical centers will not be marked on the lens – the horizontal centers should be in the middle of the vertical height.

- The vertical centers should equal the pupillary distance. Minor adjustments can be made here. Major adjustments require the lens to be reground.

Optical Centers

- Optical center adjustments focus on the nose pieces.
- This can be done with snipe nose pliers or bare hands.
- The following slides show how specific adjustments effect the frames.

https://www.perfect-eyeglasses-guide.com/eyeglass-nose-pads.html

Optical Centers

- To move the frames up (superior) on the face, bring both nose pieces medially.

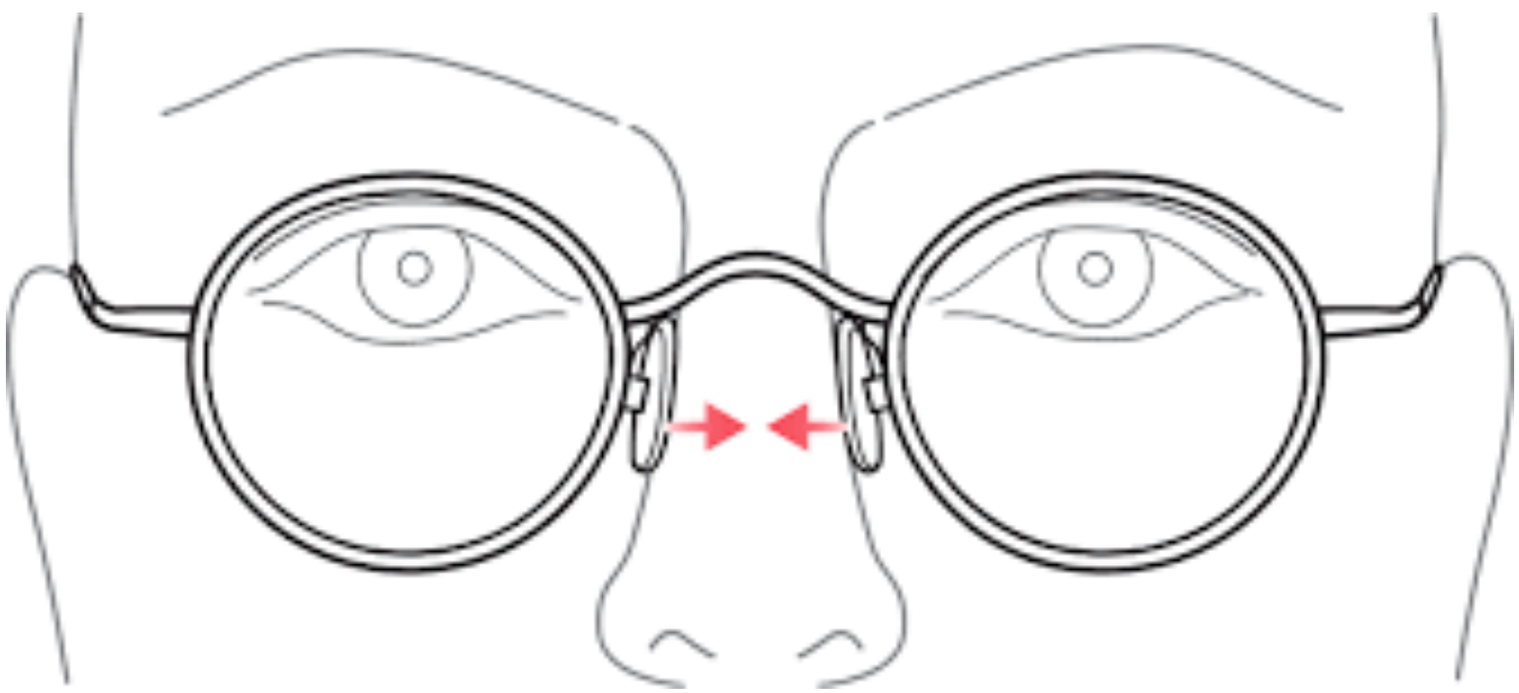

https://www.readingglasses.com/blogs/knowledge-center/adjusting-and-positioning

Optical Centers

- To move the frames down (inferior) on the face, bring both nose pieces laterally.

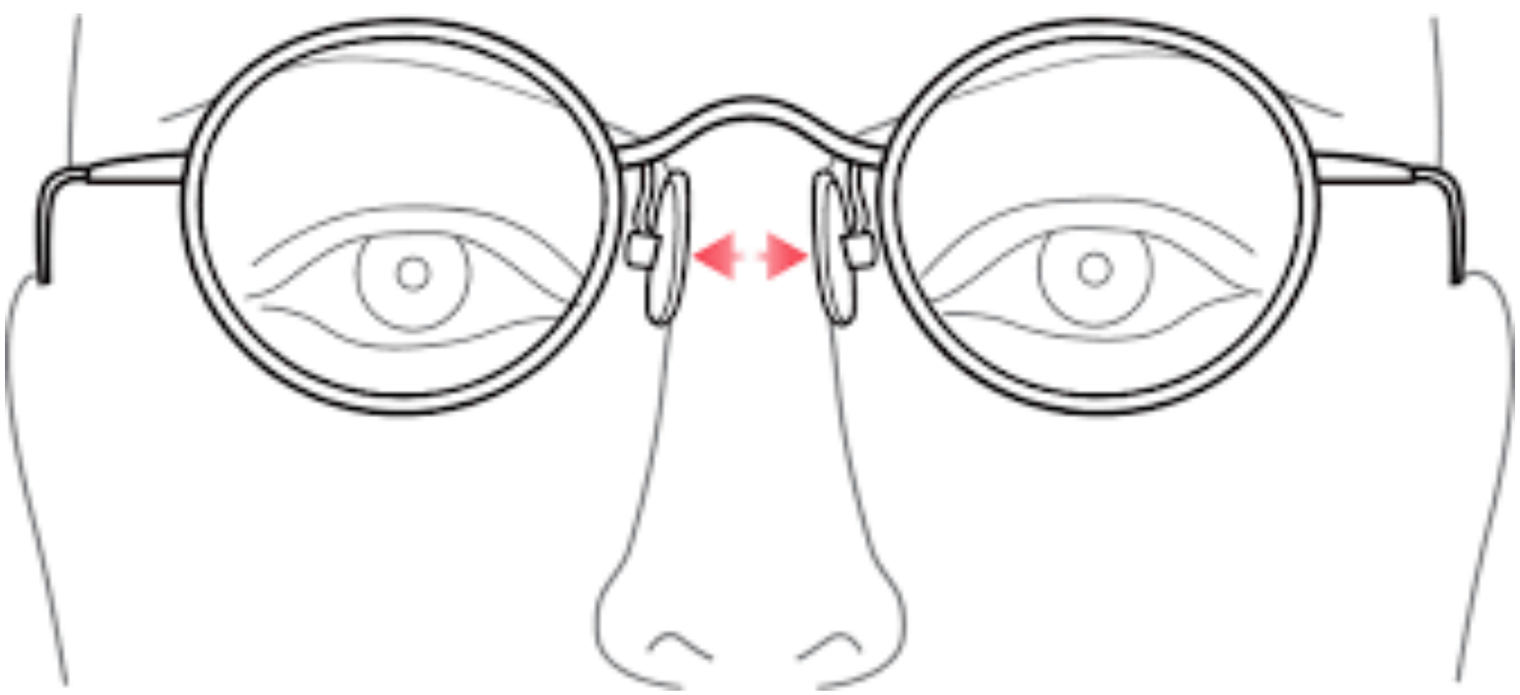

https://www.readingglasses.com/blogs/knowledge-center/adjusting-and-positioning

Optical Centers

- Optical centers that are not precisely over the patients pupils (vertically) will cause the head to rotate (occiput on atlas) when the patient opens their eyes with the glasses on.
- It will also cause the sphenoid to laterally translate upon eye opening.
- Small adjustments can be made to correct this as follows.

Optical Centers

- To move the frames laterally on the face, bring one nose piece medial and one lateral.

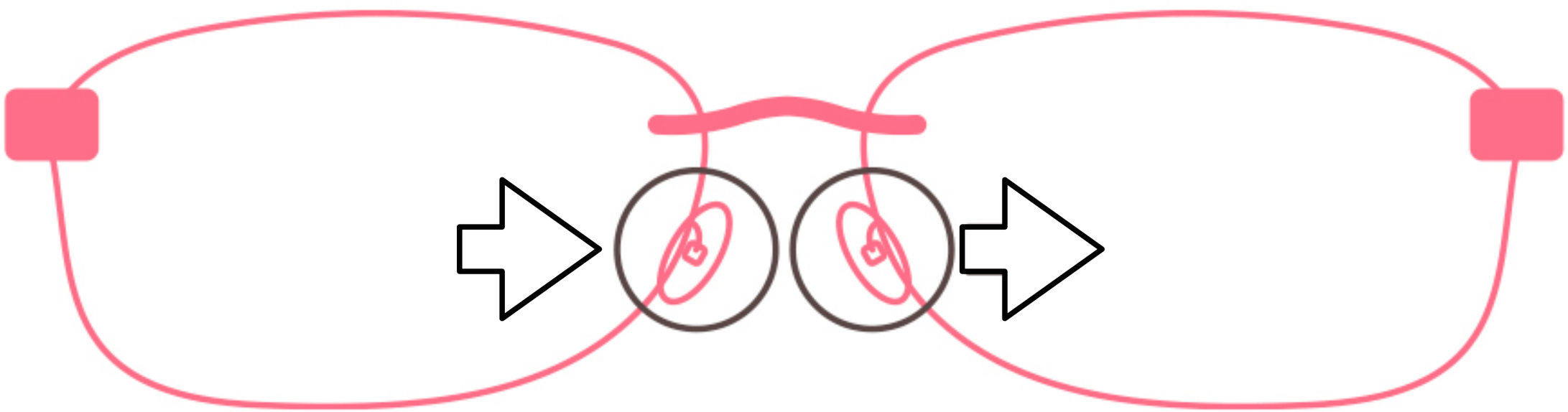

Optical Centers

- When this process is complete, the following criteria should be met:
  - 1) The patient should be looking through the optical centers of each lens.
    - A) Vertically the lenses optical center should be centered over the pupils.
    - B) Each lenses horizontal center should be over each pupil.
      - If this is correct, opening and closing the eyes, either one at a time or both together, will result in no rotation of the occiput upon palpation.

Optical Centers

- These frames are too low on this patients face.
- There are no nose pieces on these frames – thus very little adjustment is possible.
- Frames of this type should be avoided for this reason.

http://www.beautyhobby.com/wp-content/uploads/2006/10/gianfranco-ferre-eyeglasses.jpg

Temple Arms

Temple Arm Adjustment

- Temple “arms” come in a variety of lengths.
- The most common adult lengths are between 125 and 145 mm.

For example:
Size: 47-20-140mm
Lens height: 25mm
Total frame width: 135mm

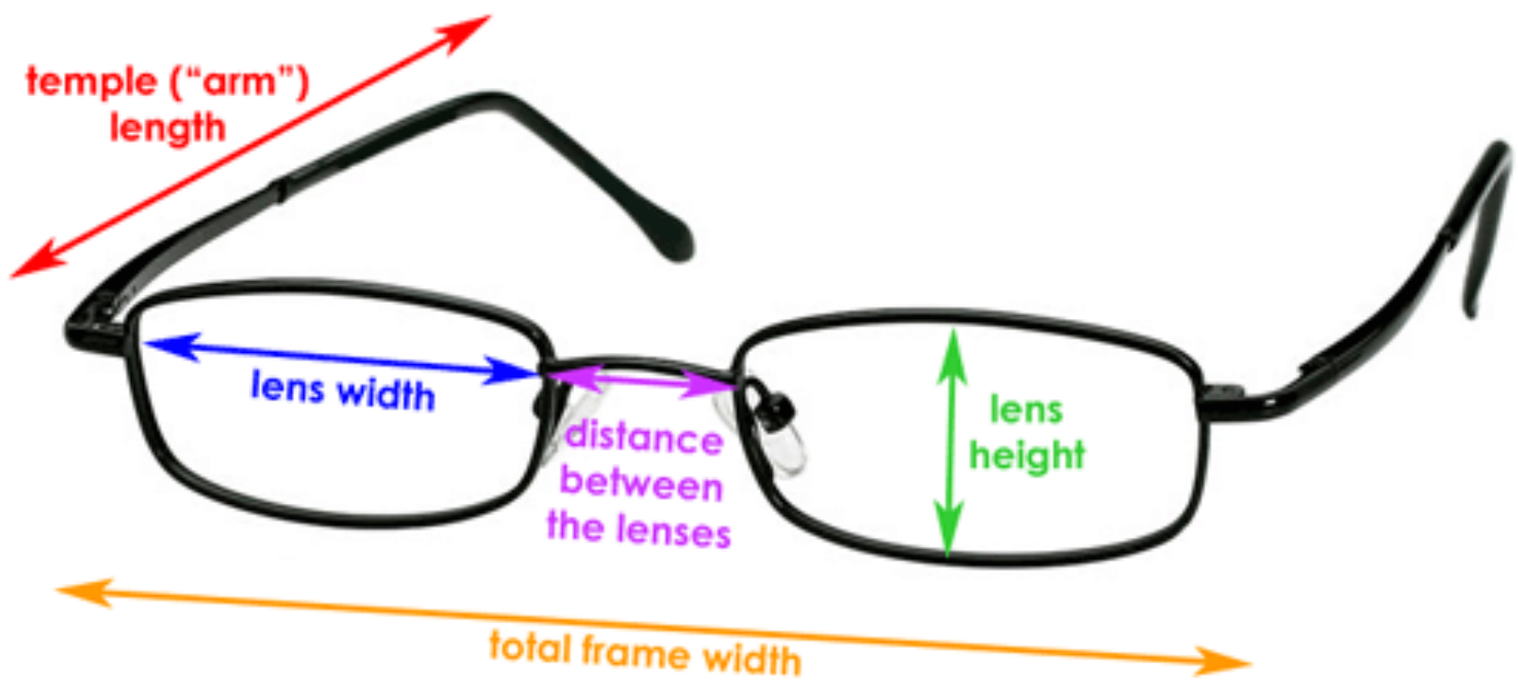

Temple Arm Adjustment

- Temple lengths are measured as shown on the right.





http://www.optometristattic.com/Measure.htm

Temple Arm Adjustment

- There are two ways of fitting the temple arms to the head:

  - 1) To bend the temple wires so that they closely conform to the shape of the posterior pinna.

  - 2) To form the wires to fit the notch at the occipital mastoid suture. This is not an option for patients with long A-P diameter heads as the temple arms will be too short.

Temple Arm Adjustment

- This is the way most glasses are adjusted at the optical shop.

- These glasses can slide down the nose and cause optical strains.

Temple Arm Adjustment

- If the temple arms do not fit the head correctly, sweat and gravity will pull the glasses down the nose.

- This causes cranial strain patterns in the individual due to the prismatic effect of the lenses.

Temple Arm Adjustment

- Temple wires can be adjusted easily with the hands or temple bending pliers.
- Place the glasses on the nose with optical centers over the pupils and then begin to work with the temple arms.
- The following slides show fitting options.

Temple Arm Adjustment

- The temple arm should be bent to hug the posterior pinna without touching it.

- The temple arm should come within 1-3mm of the pinna and conform to the shape of the cranium.

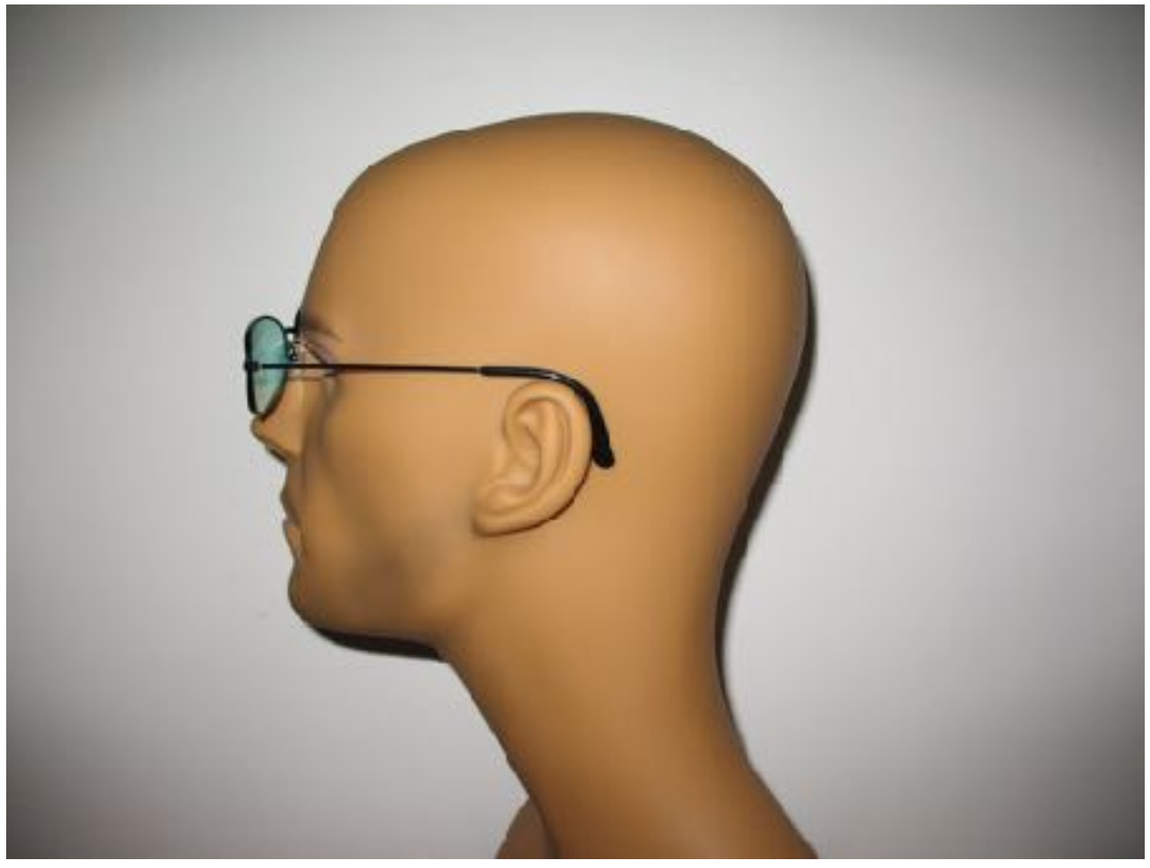

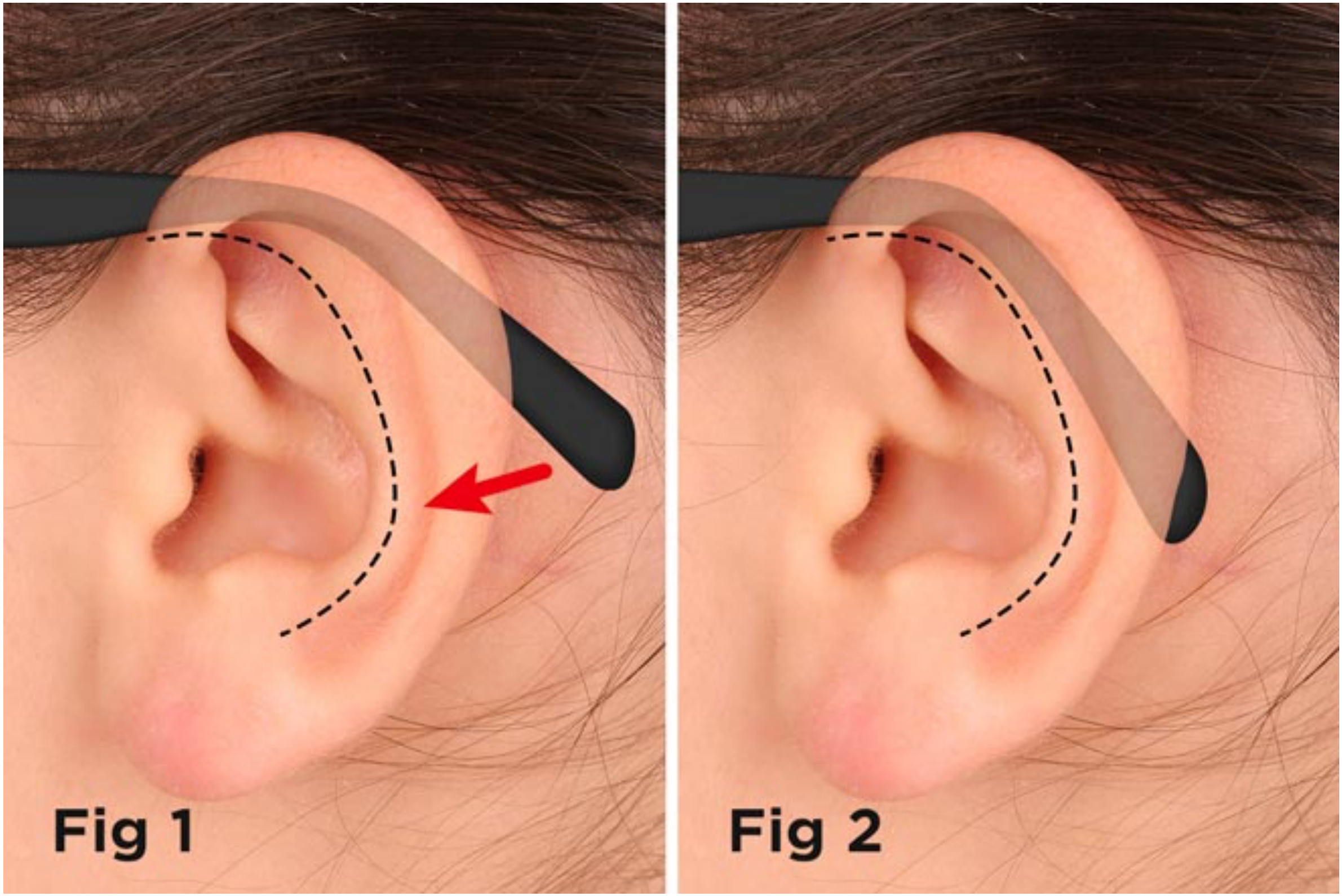

The final product should resemble the picture at right.

https://www.allaboutvision.com/eyeglasses/faq/eyeglasses-temple-size.htm

Alternate Temple Adjustment

- Some frames come with straight temple arms.
- The temple arm here is bent to conform to the notch at the occipitomastoid suture (it is bent inward at the end to conform to the notch in the head).
- This allows the glasses to securely stay on the face.

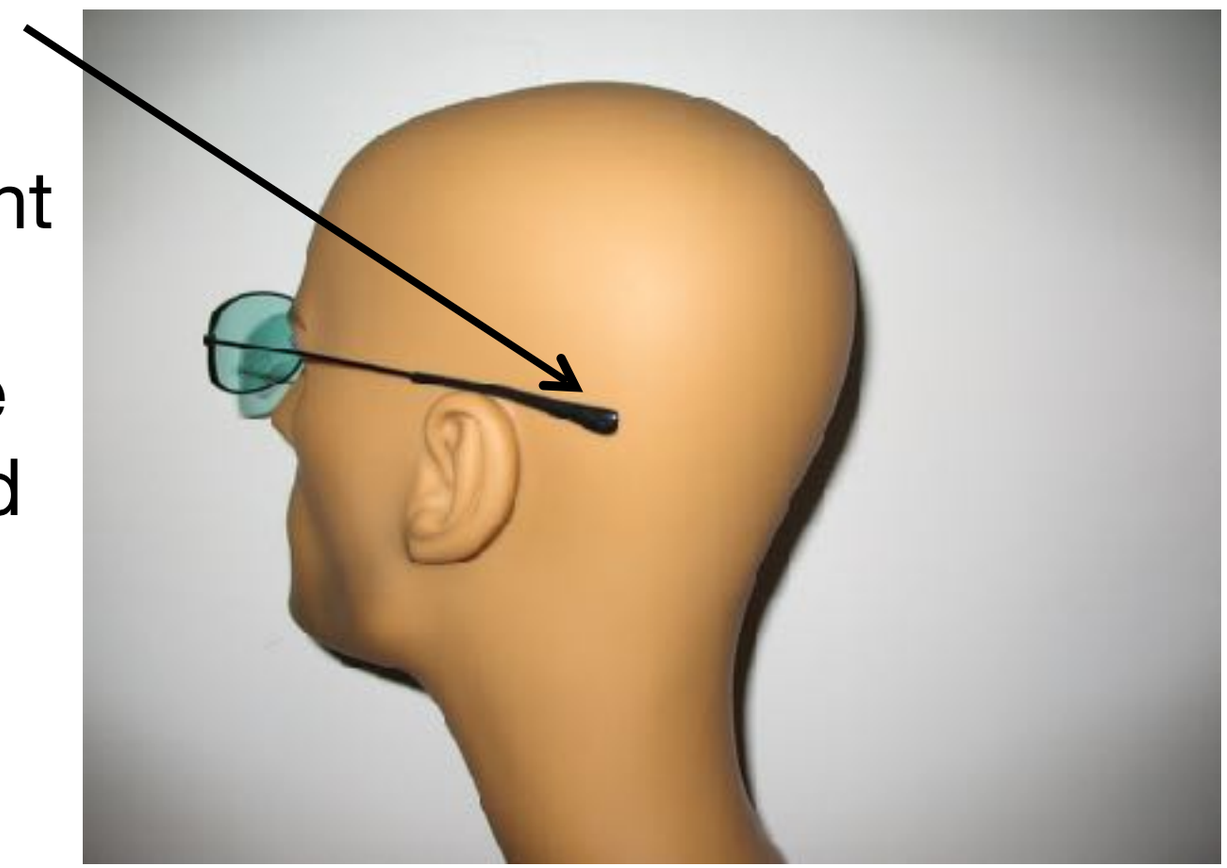

Temple Adjustment

- When complete, if the frames are lifted gently off the nose (red) and pulled forward (blue), they should move no more than 2-3mm anterior (black).

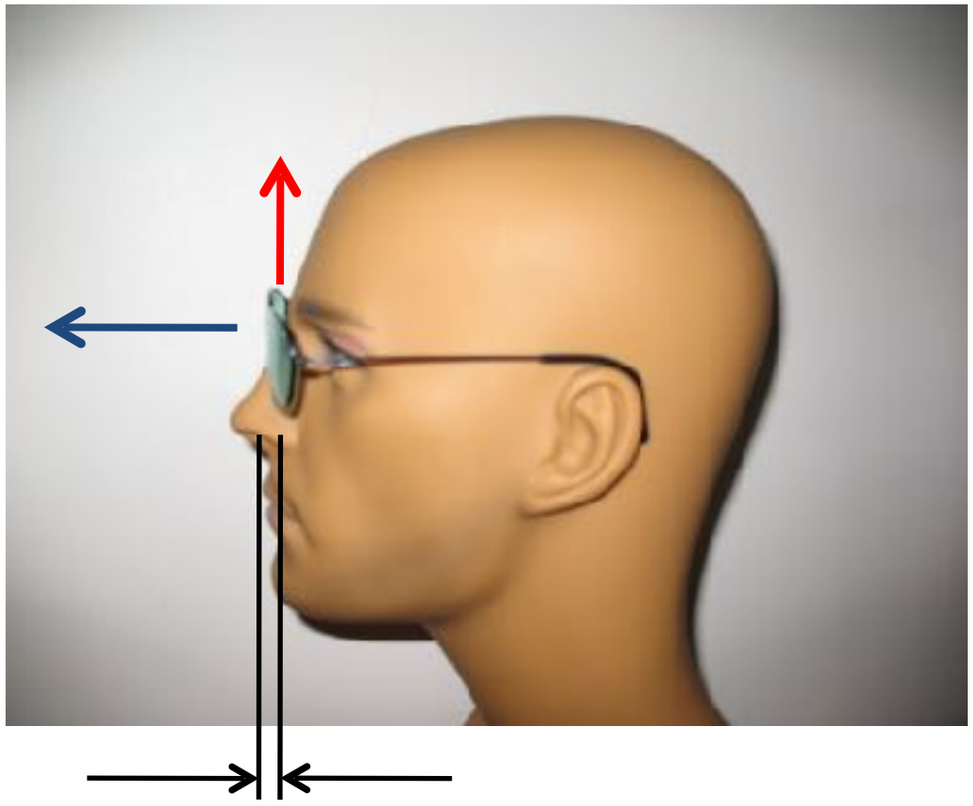

Eyeglass Adjustment

- Thus far we have correctly placed the frames on the face, by ensuring the optical centers are over the pupils and that the temple arms are adjusted to keep the frames in place.

- Next we will use the muscle tension and the cranial rhythm to custom fit the frames to the individual.

Pantoscopic/ Retroscopic Tilt

Lens Tilt

- Next we will adjust the tilt of the frames on the face.
- If the frames are properly adjusted there will be no tissue difference at the OA joint between eyes open and eyes closed.
- If there is a difference here, pantoscopic/retroscopic tilt adjustments will correct it.

Lens Tilt

- To begin the test, have the patient seated or standing so that you can easily monitor the OA junction.
- Begin with the patients eyes closed. The feel here we will call neutral (even if there is muscle tension present).
- Then have the patient open their eyes.
- One of three things will occur.

Lens Tilt

- If we focus just on the OA and suboccipital muscles, it will flex, extend or no change will be noted.

- We can then adjust the frames until any movement caused by the frames on opening the eyes is neutralized.

CHARACTERISTICS OF A PRISM

- A prism has a thickest edge, the base, and a thinnest edge, the apex.
- A prism will displace the incident rays toward the base of the prism.
- A prism will displace the image toward the apex of the prism.

CHARACTERISTICS OF A PRISM

- The further the object is from the prism the more it is displaced.
- A prism does not change the vergence of the rays. It does not magnify or minify the image.
- A prism will disperse an incident pencil of light into its component colors.

Optics Principle

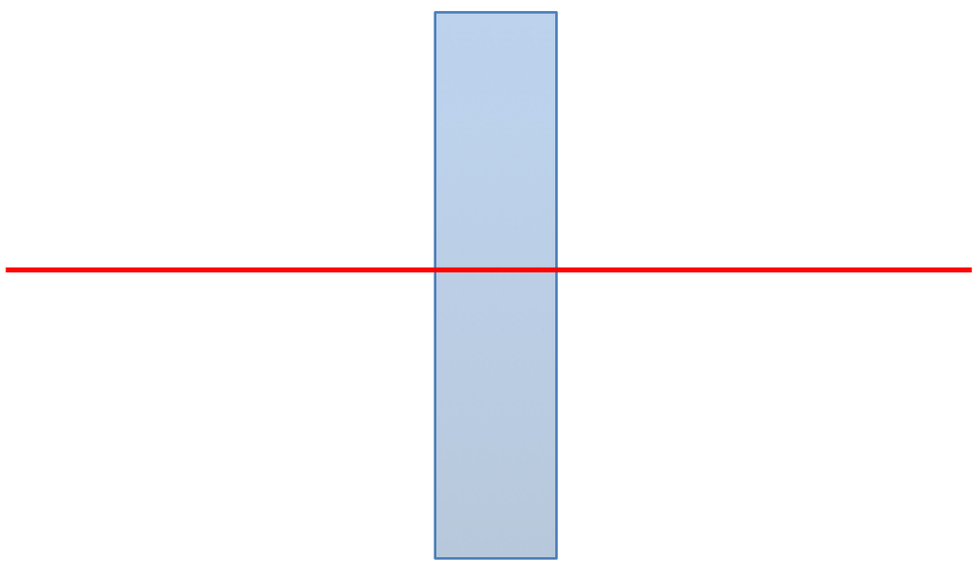

Flat Lens

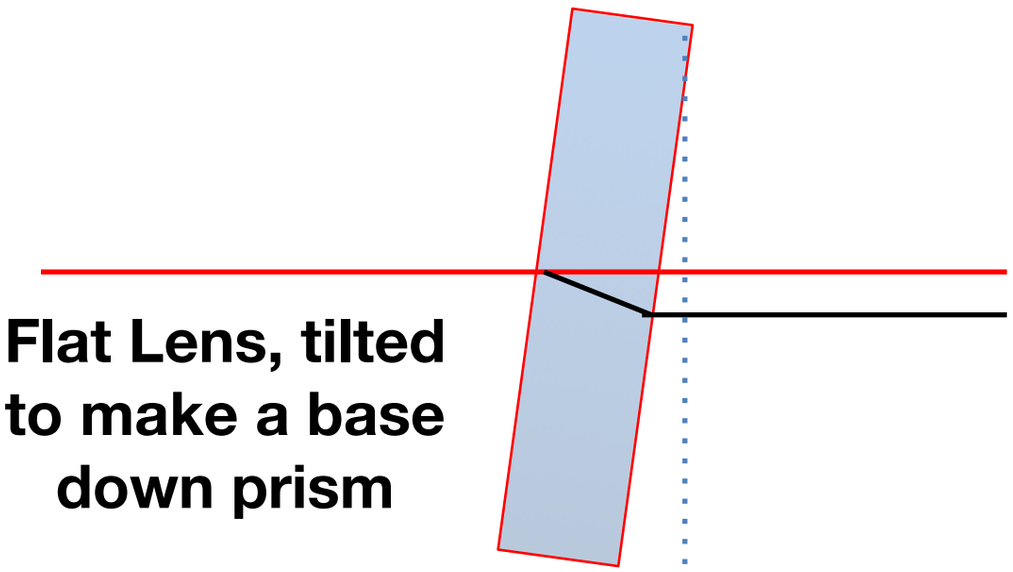

Flat Lens, tilted to make a base down prism

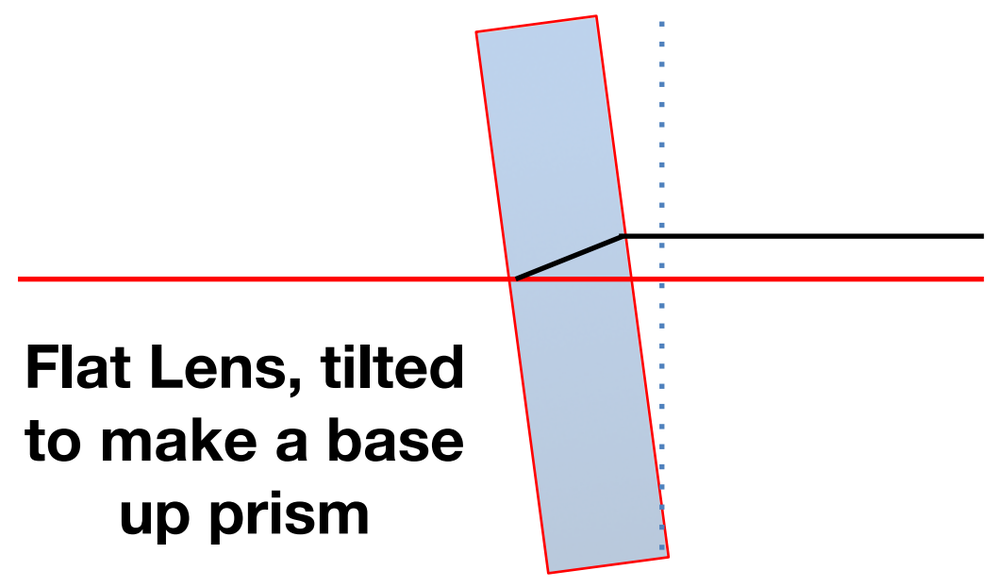

Flat Lens, tilted to make a base up prism

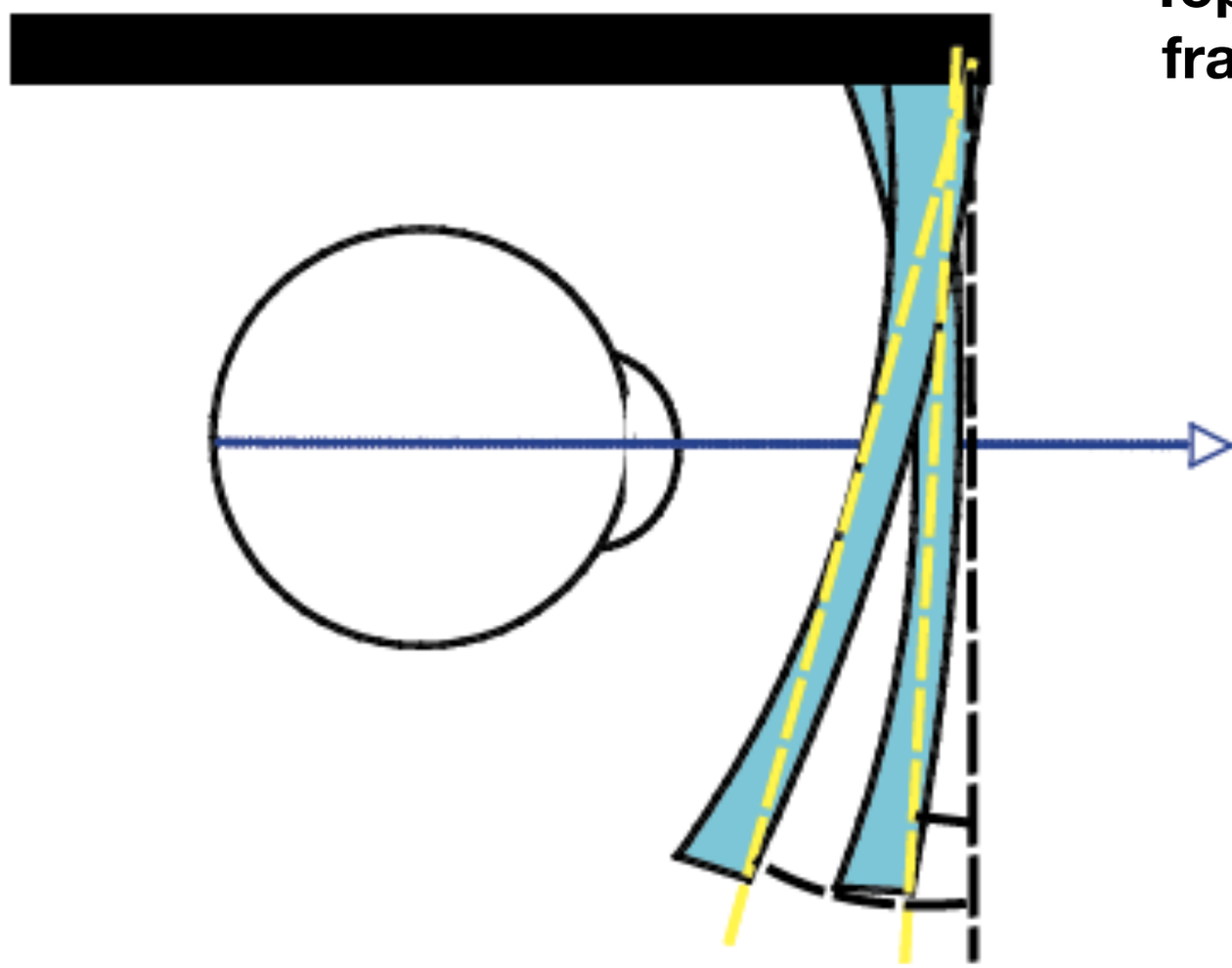

Pantoscopic tilt moves the bottom of the lens toward the face

Retroscopic tilt moves the bottom of the lens away from the face

Each of these create a prism effect that till tilt the head

https://www.2020mag.com/article/pantoscopic-and-retroscopic-tilt

In Relation to the Fovea:

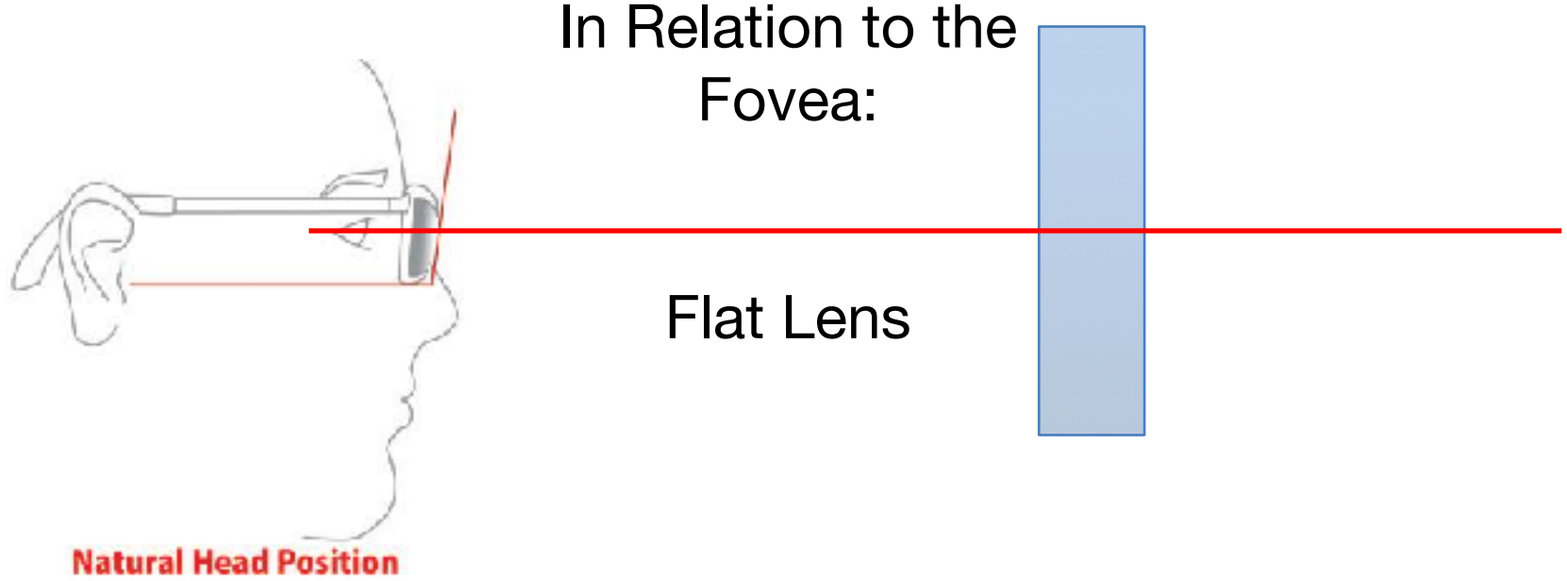

This is proper adjustment and produces no head flexion or extension on eye opening

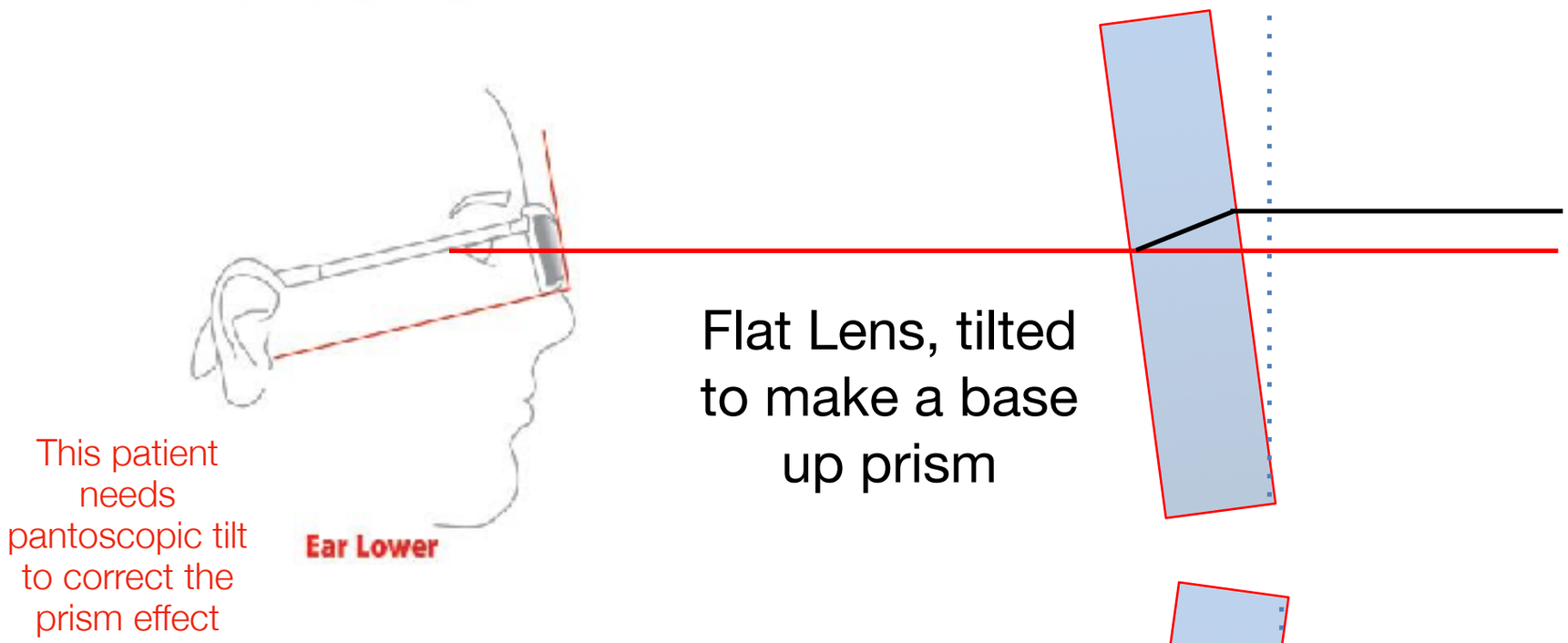

This kind of maladjustment makes the patient tilt their head up (extend) to capture the image on the retina

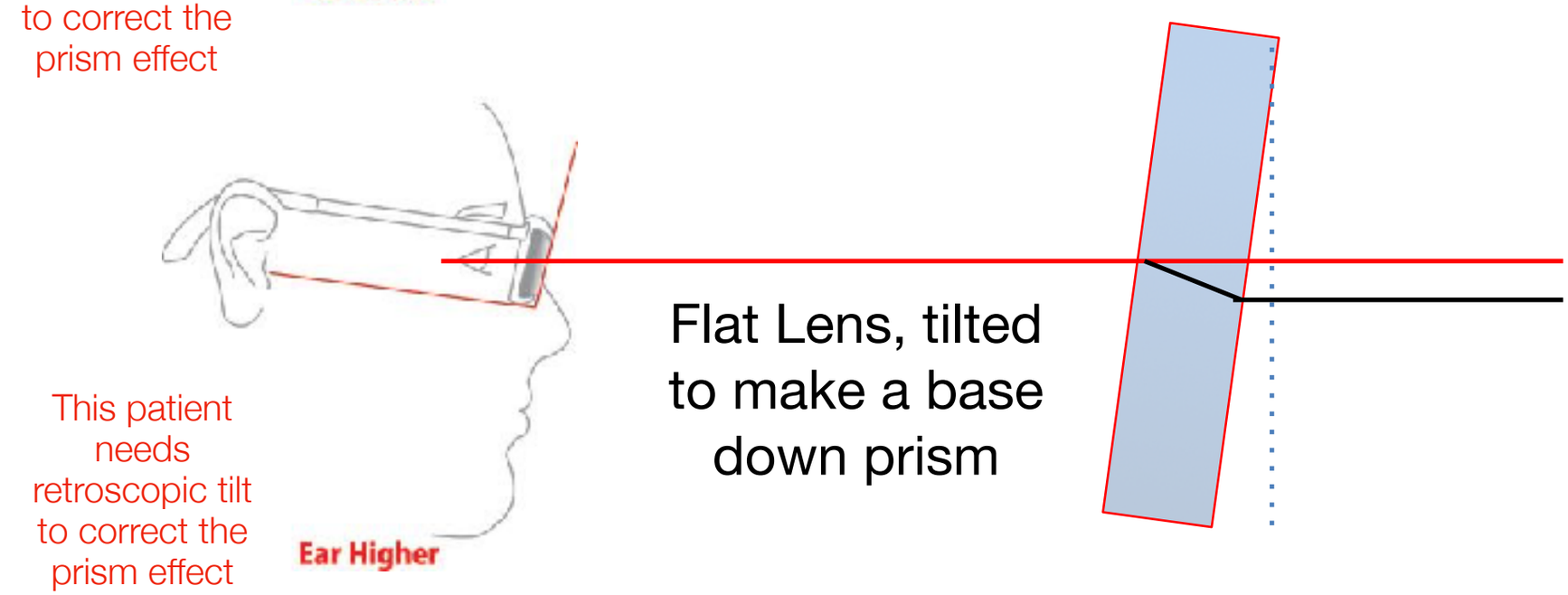

This kind of maladjustment makes the patient tilt their head down (flex) to capture the image on the retina

https://www.eyecarebusiness.com/issues/2011/april-2011/last-word

To adjust pantoscopic/retroscopic tilt, use pliers to angle the temple arms up or down at the hinge.
Be careful with the hinges and they can be fragile.

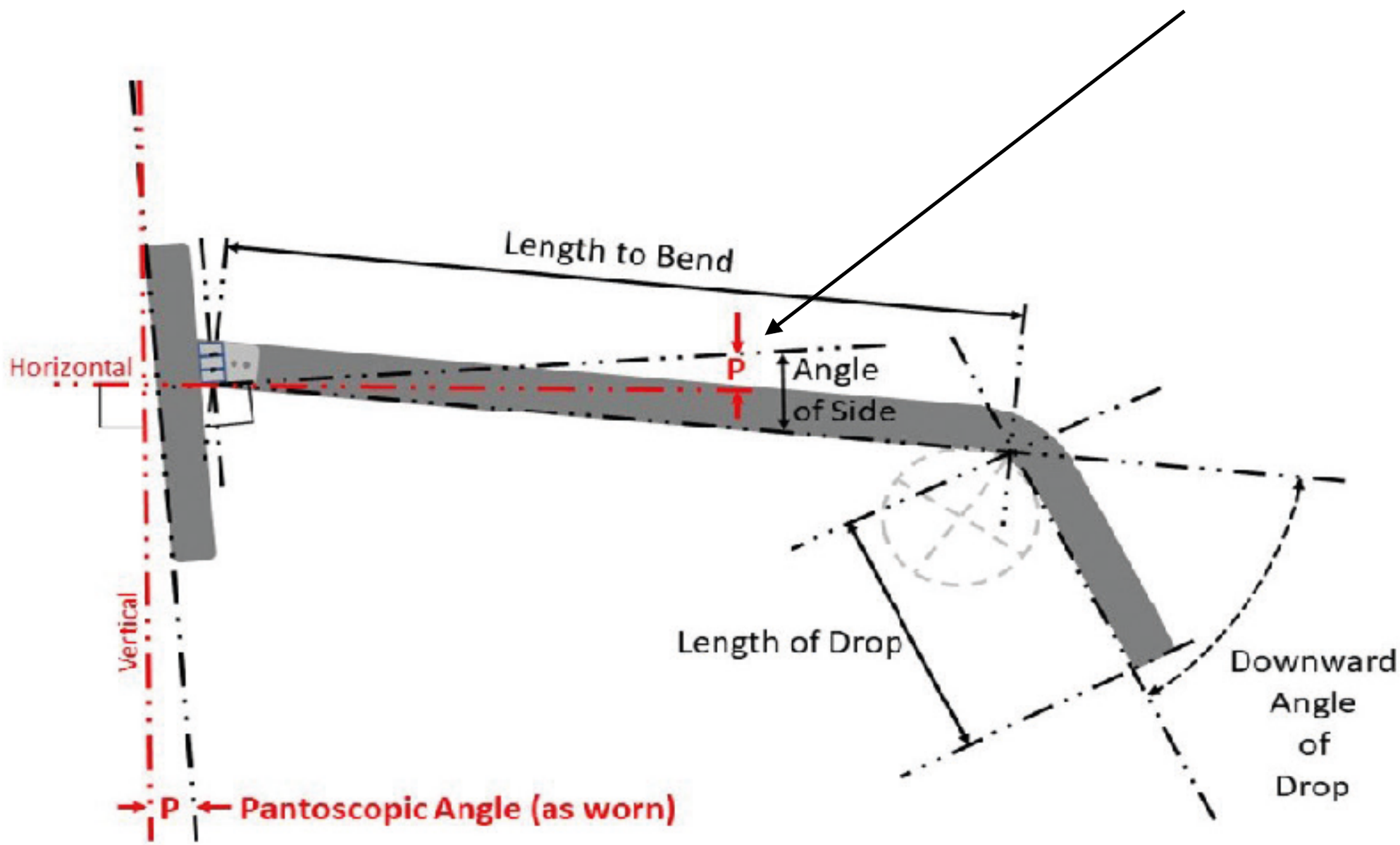

https://www.opticianonline.net/cpd-archive/5410

Eyeglass Adjustment

- Now that we have the frames correctly fitted to the face and the pantoscopic tilt correct we will look at some other aspects of eyeglass fit.

- The next step is to check and adjust, if necessary, the angle of astigmatic correction.

Astigmatic Angle Correction

Astigmatic Correction

- For this next part we will monitor the patient from behind.
- We will palpate the temporals/sphenoid looking for torsional patterns in the cranium.

Astigmatic Correction

- Start with the patients eyes closed and monitor the cranium for strain patterns.
- If no adjustment is necessary, then no cranial torsion pattern will be noted with patients eyes open.

Astigmatic Correction

- If a torsional strain pattern appears when the patient opens the eyes, then frame adjustment to change the astigmatism angle may be able to alleviate it.

Astigmatic Correction

- Here the blue line will represent the axis of astigmatism in the lens.

- Small adjustments can be made by bending the frames.



Astigmatic Correction

- To correct the torsional pattern start by trying to adjust the frames in one direction.

- Recheck the strain pattern as you make small adjustments.

- If the pattern improves, then continue adjusting in that direction until the strain is resolved.



Astigmatic Correction

- If the pattern worsens, then adjust in the opposite direction.

- Continue with small adjustments until the strain is resolved.



Eyeglass Adjustment

- Now the frames are correctly fitted to the face, the pantoscopic tilt is correct and the cranial torsion patterns have been neutralized.
- The next step is to check and adjust, if necessary, the frames to neutralize any sidebending/rotation patterns.

X’ing the Frames

“X”ing the Frames

- The next part is to test for sidebending/ rotation patterns in the cranium.
- Compare the patient with eyes closed vs. eyes open and if a sidebending pattern occurs with the eyes open, use the following adjustments to the frame to neutralize it.

“X”ing the Frames

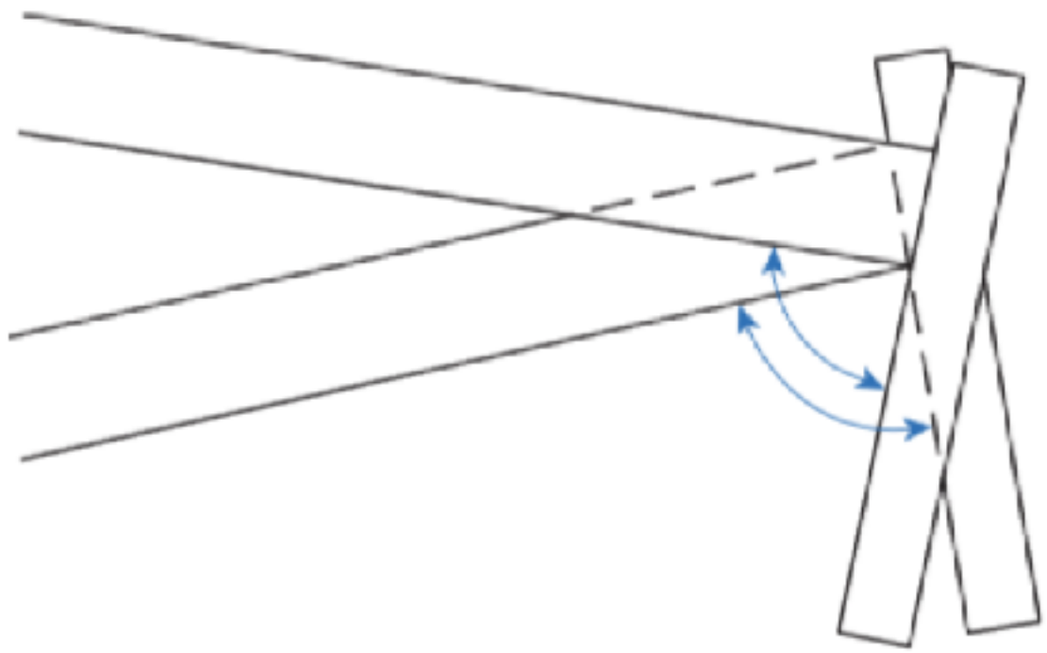

- X’ing is characterized by the “x” the lenses make when looked at from the side.

“X”ing the Frames

- Normally the eyeglass frames are equal on both sides - the lenses are parallel and not bent.

- If you find a side-bending/rotation when the patient opens their eyes, “x”ing the frames is the treatment.

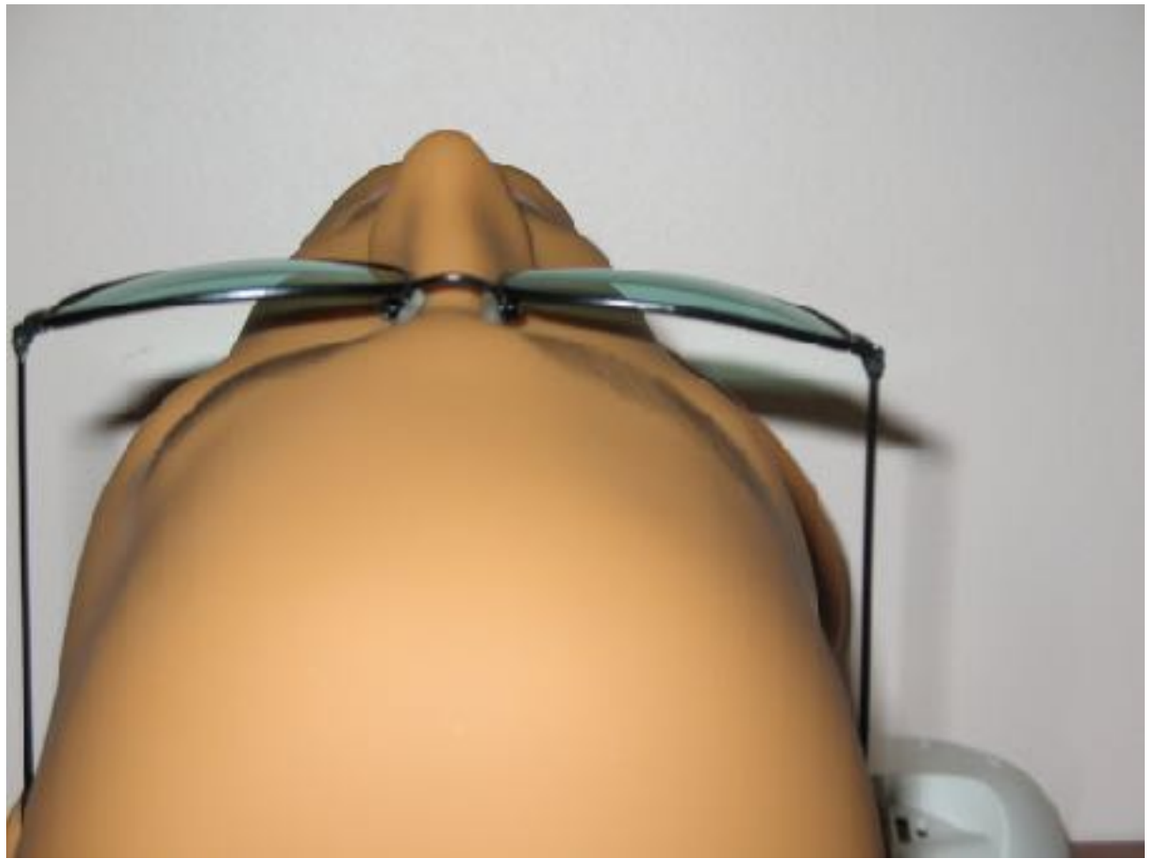

“X”ing the Frames

- Here the right lens base has been moved anterior.
- This will help to correct a left SBR.

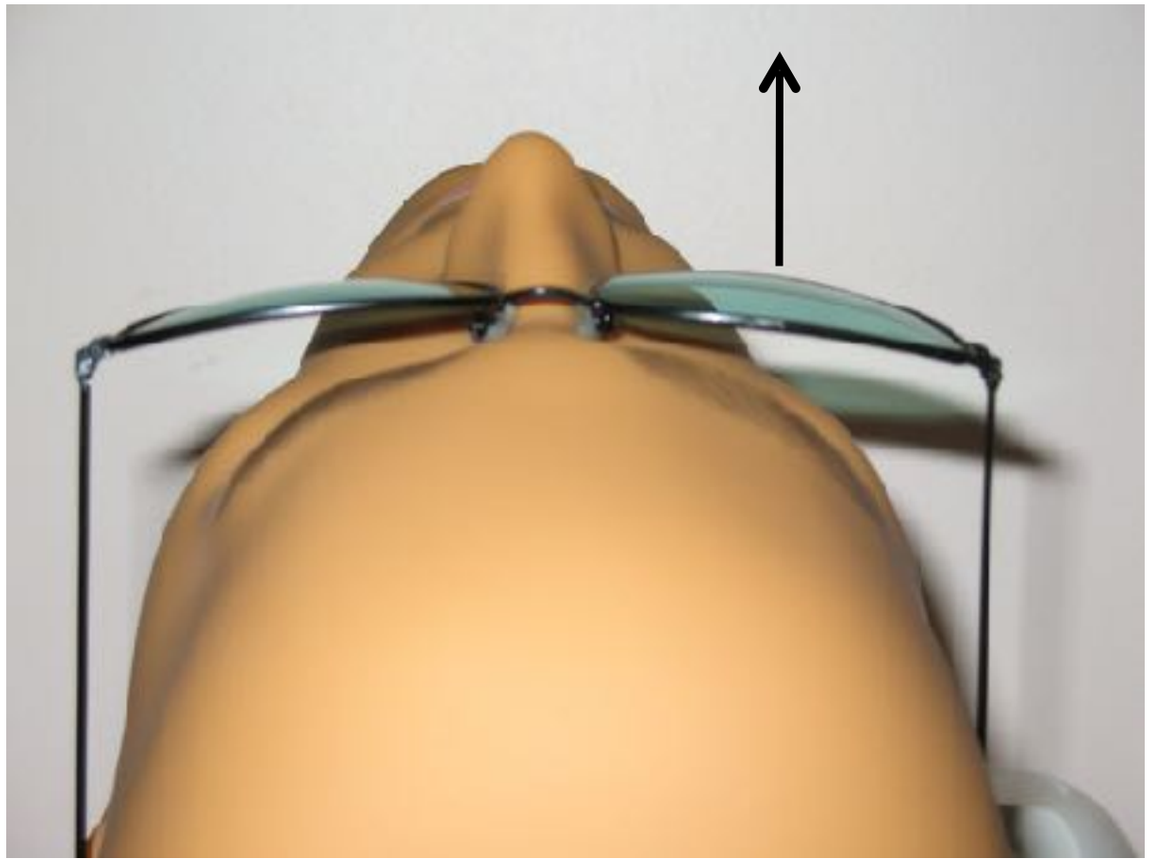

“X”ing the Frames

- Here the left lens base has been moved anterior.

- This will help to correct a right SBR.

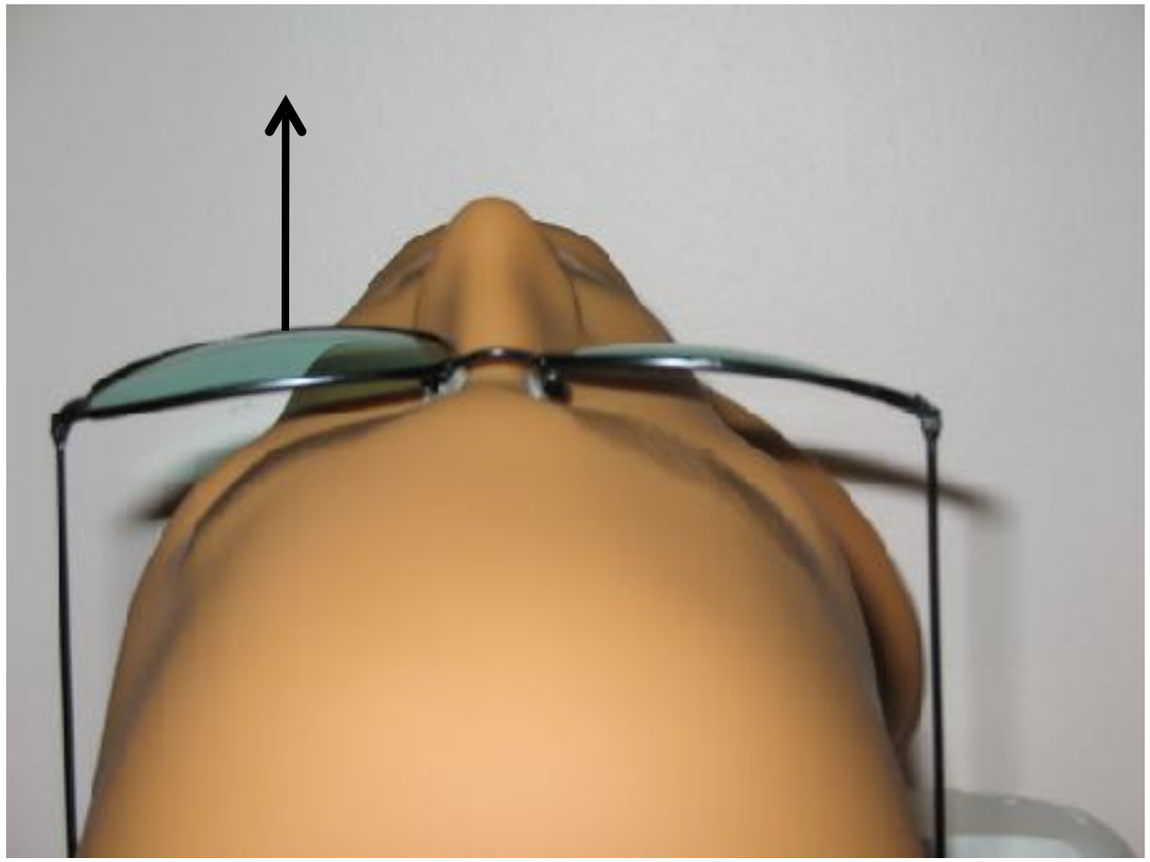

“X”ing the Frames

- Here the left lens base has been moved anterior.

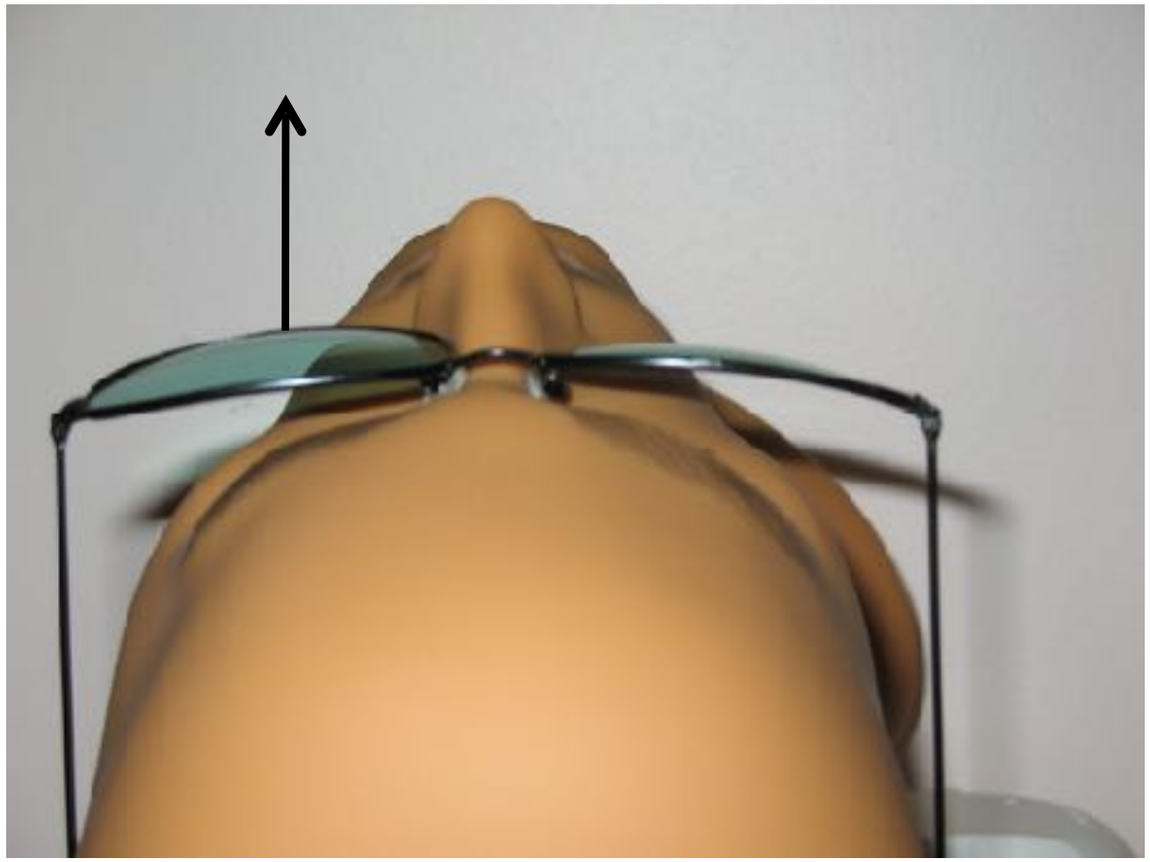

- This is the same as moving the right lens base closer to the face.

Eyeglass Adjustment

- Now the frames are correctly fitted to the face, the pantoscopic tilt is correct, the cranial torsion and sidebending rotation patterns have been neutralized.
- The next step is to check and adjust, if necessary, the frames to neutralize any vertical strain patterns.

Face Form

Face Form

- This adjustment bends the frames to either conform more to the face or less.

- The will correct vertical strains in the patient that are of optical origin.

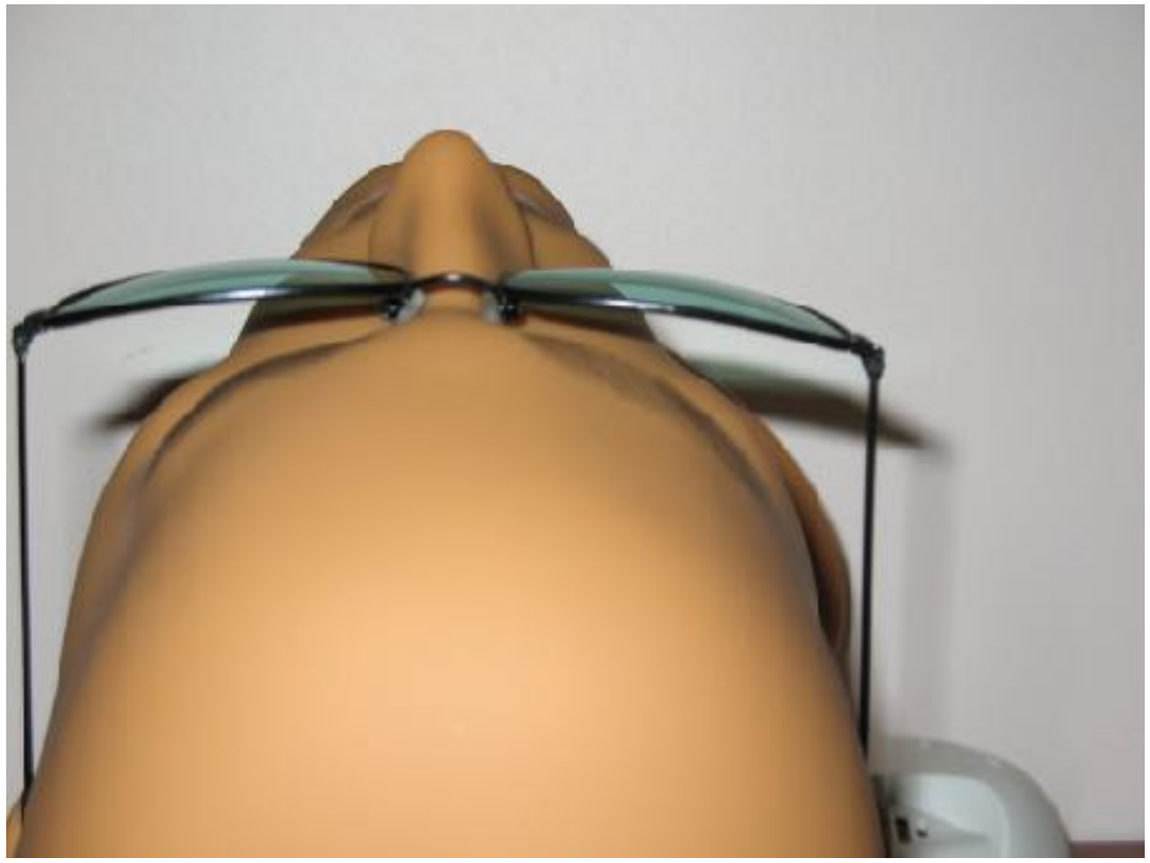

Face Form

- Less face form
- This creates a base OUT prism (lens effectively gets thicker on the outside).
- That moves the object OUT, moving the body more into a superior vertical strain.

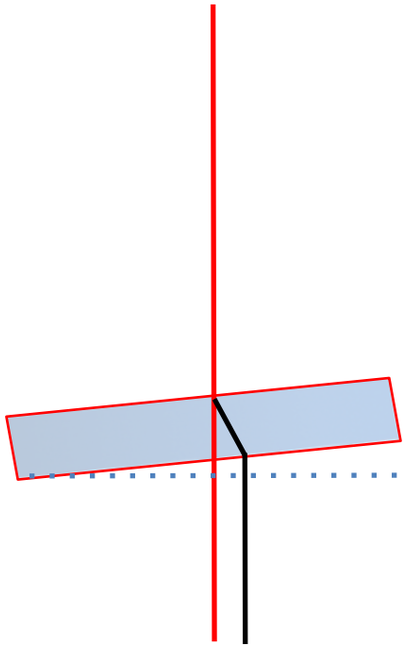

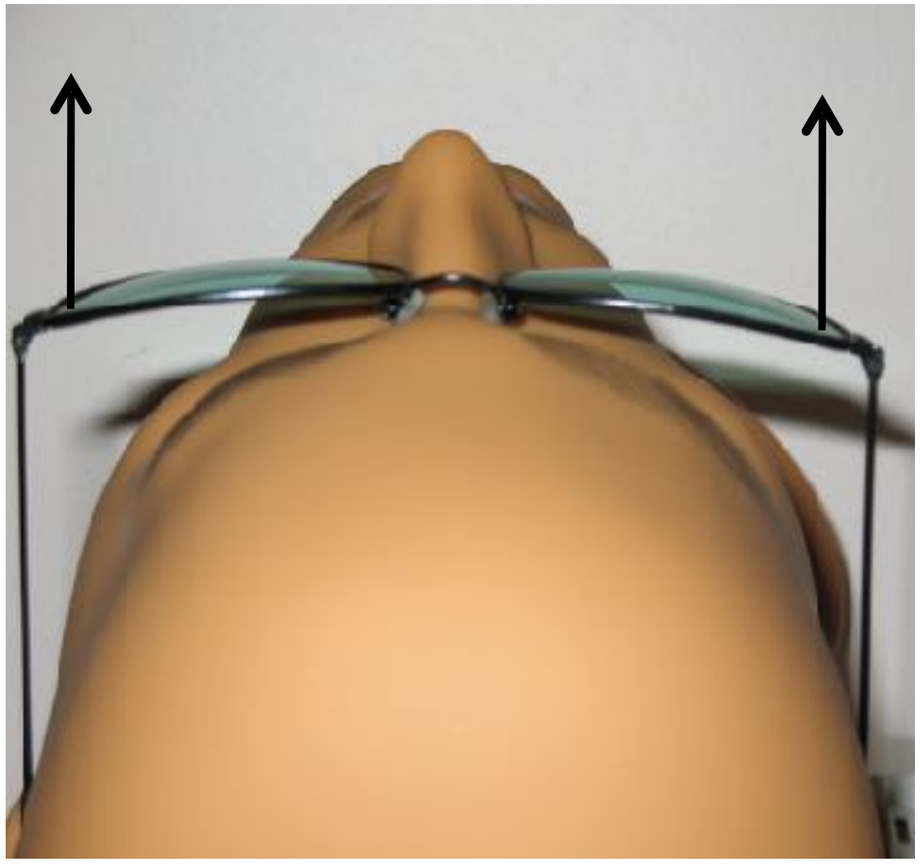

Face Form

- More face form.
- This creates a base IN prism (lens effectively gets thicker on the outside).
- That moves the object IN, moving the body more into an inferior vertical strain.

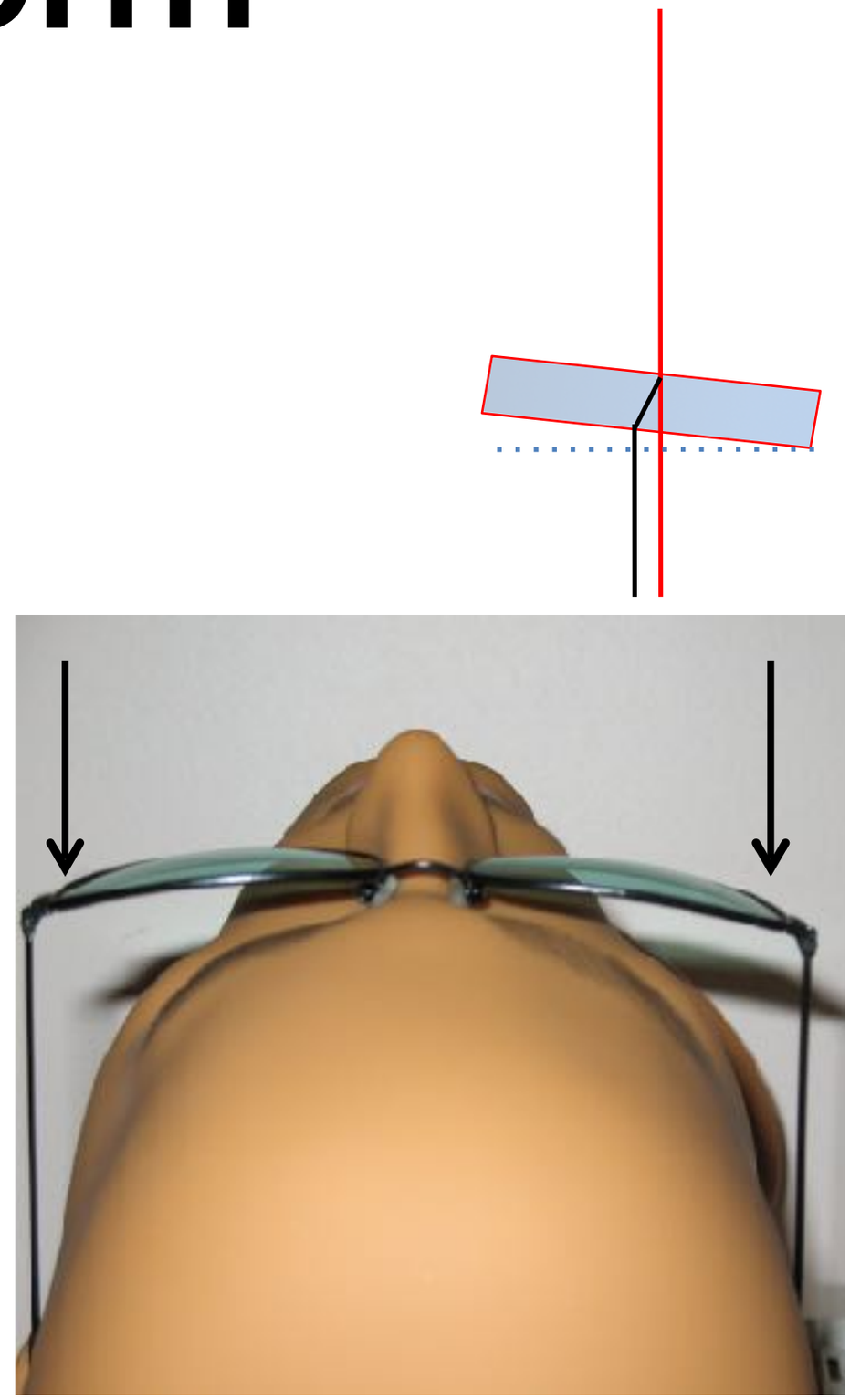

Eyeglass Adjustment

- Now the frames are correctly fitted to the face, the pantoscopic tilt is correct, the cranial torsion, sidebending rotation and vertical strain patterns have been neutralized.

- The next step is to go back and do a quick check of every adjustment made thus far to make certain they are all working together.

- Repeat this process until the patient’s body is balanced.

Wrapping Up

- If everything has been done correctly, there should be no palpable difference between the patients cranium and muscle tension with eyes open vs eyes closed.
- The glasses then should be treated as if they were fragile - because any deviation from your adjustment will create a change in the patient (so try not to drop them, fold them, use two hands to put them on and off, etc.)

Fin

In the end, we have glasses that are correctly adjusted

Now we are going to link
vision and the teeth together
in a different manner…
via shapes and architecture…

The Simple Arch

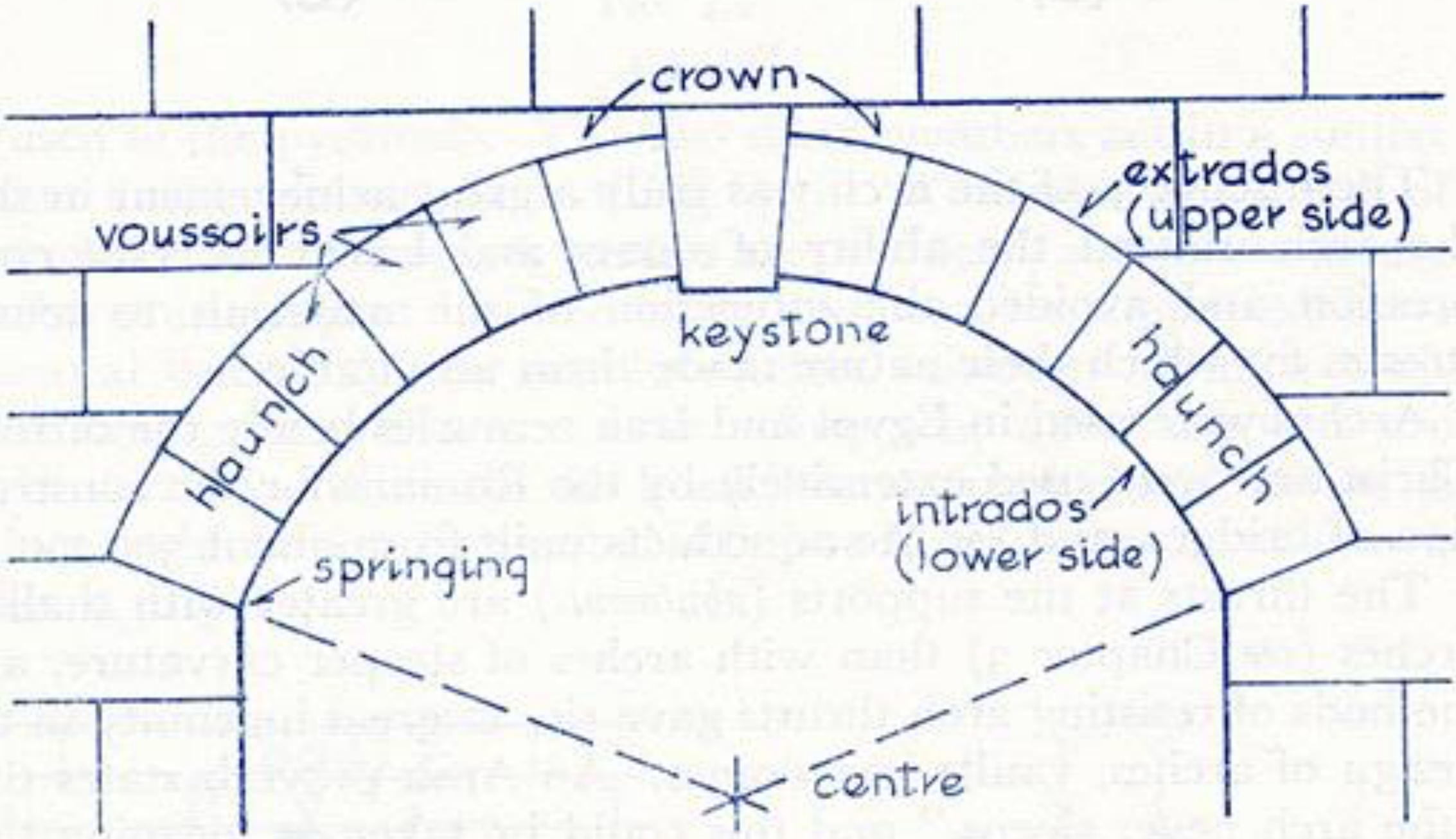
crown
extrados
(upper side)
voussoirs
keystone
haunch
haunch
intrados
(lower side)
springing
centre

FIG. 4.6

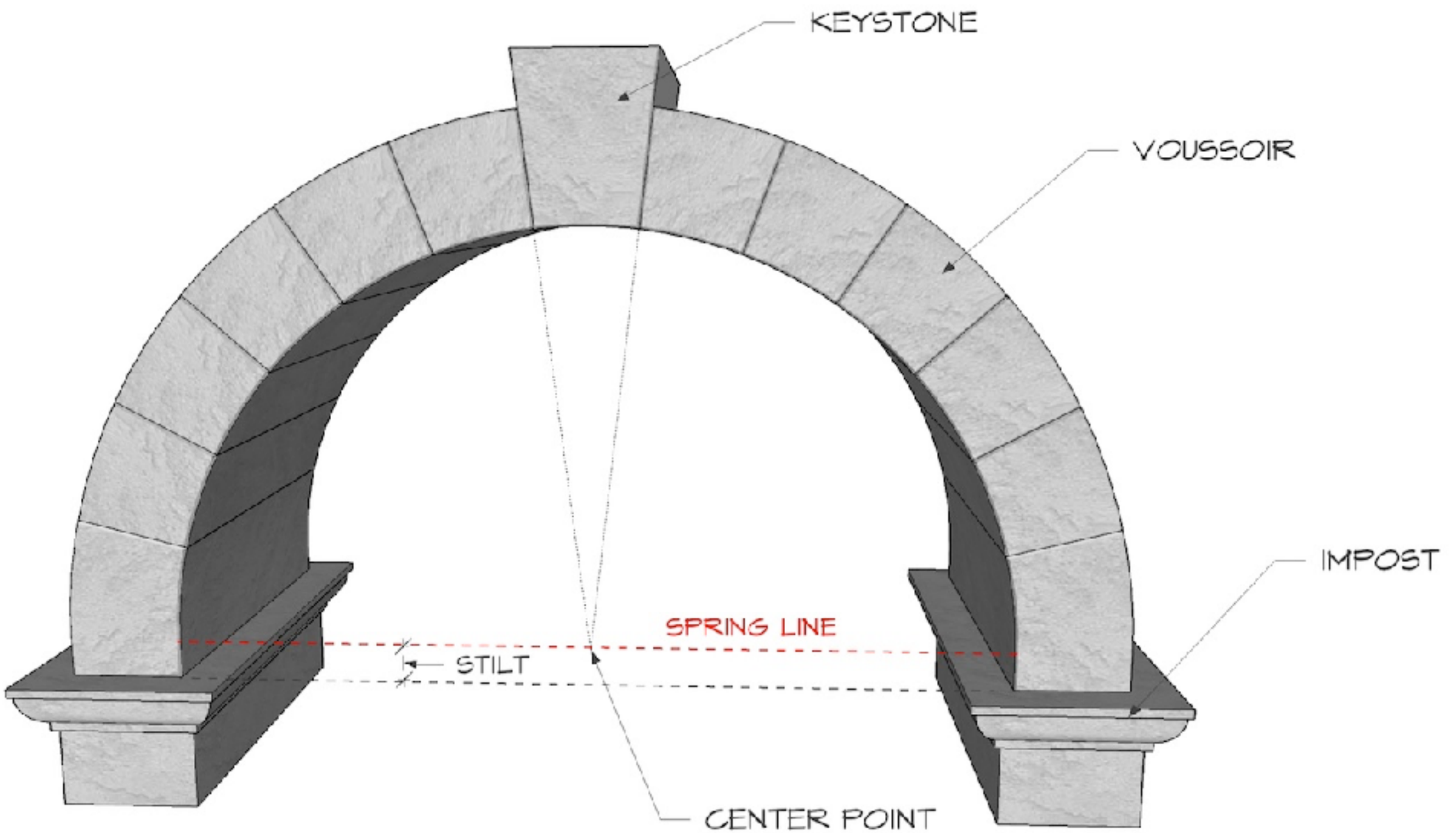

THISisCarpenTry.com

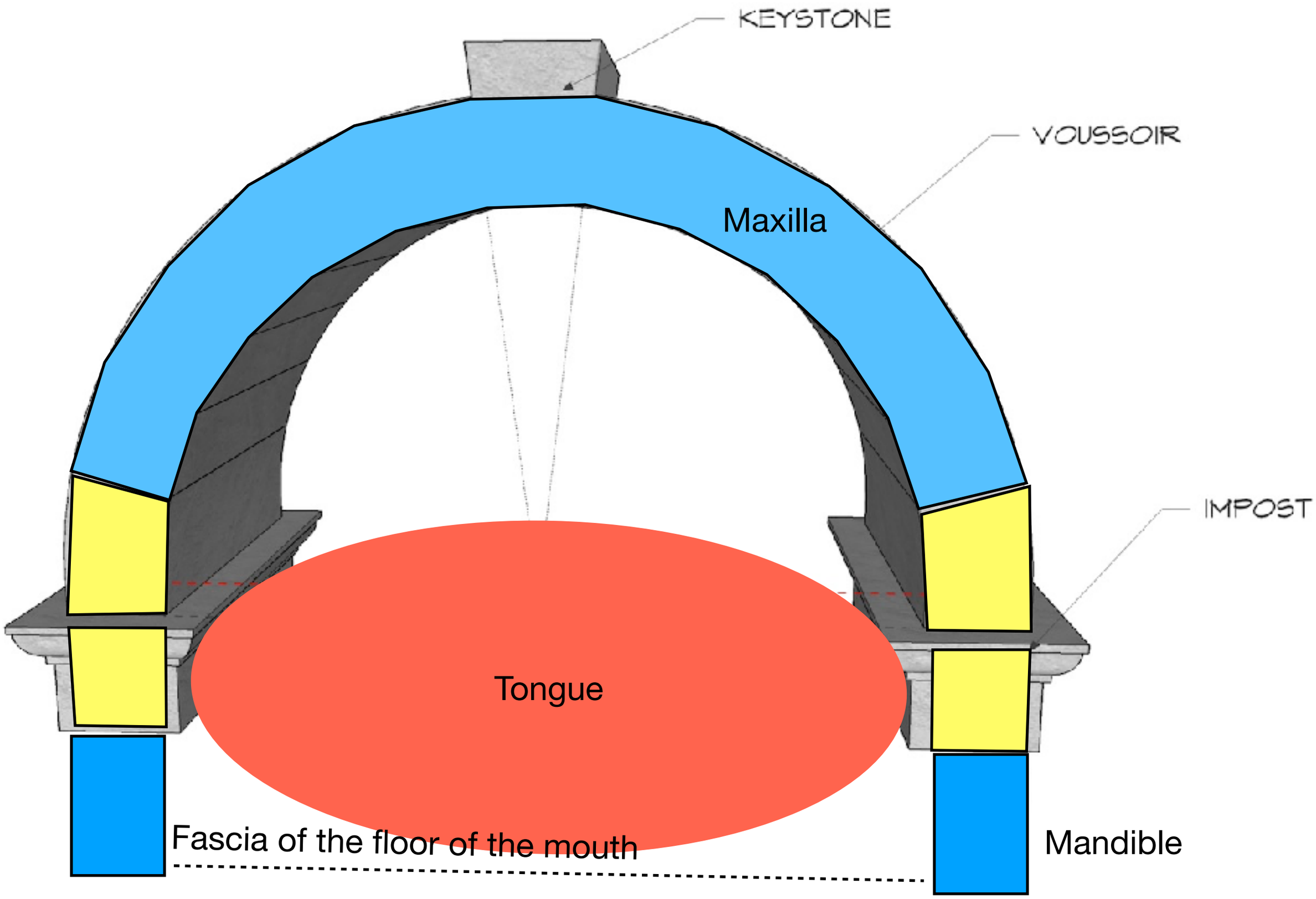
KEYSTONE
VOUSSOIR
Maxilla
IMPOST
Tongue
Fascia of the floor of the mouth
Mandible

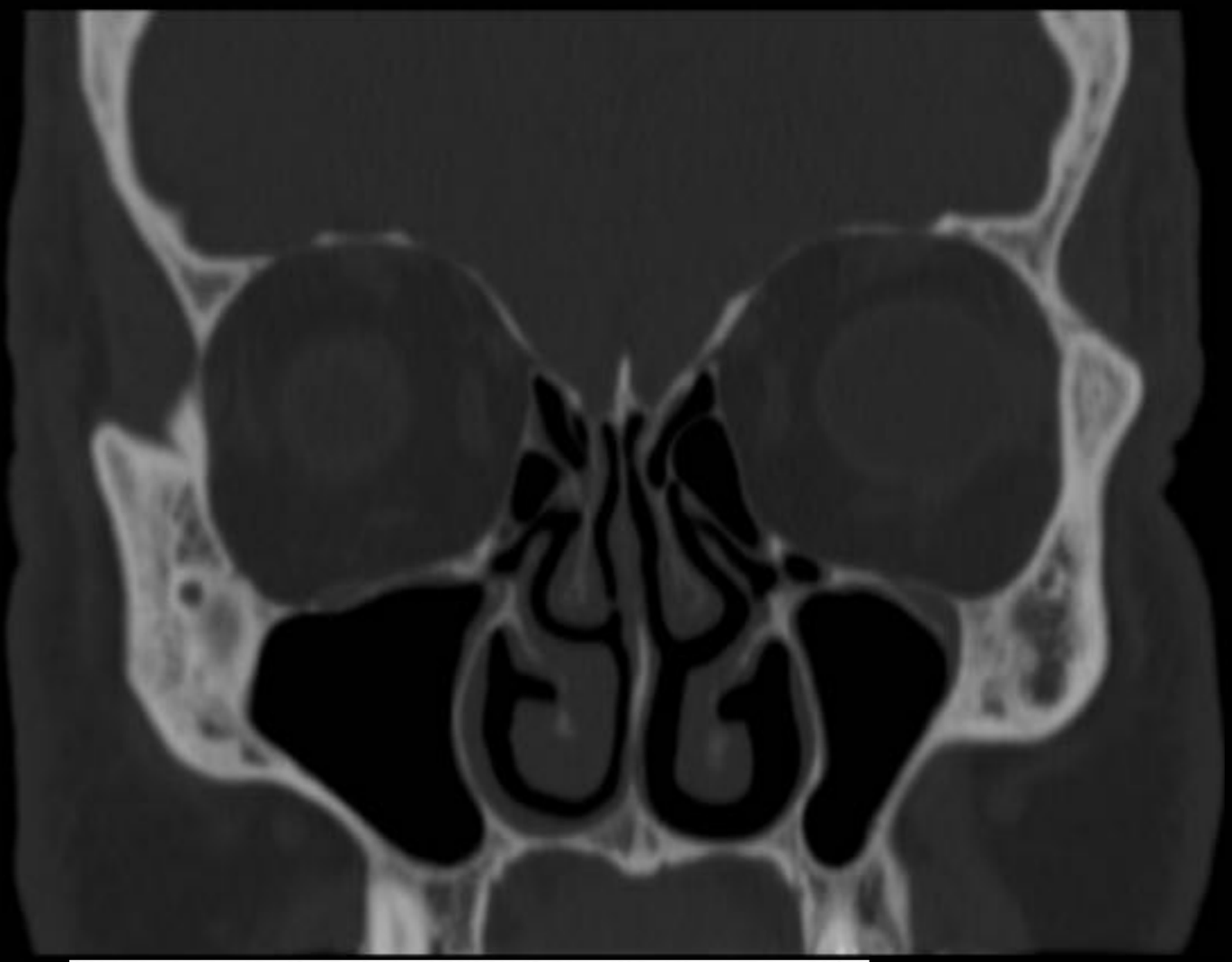

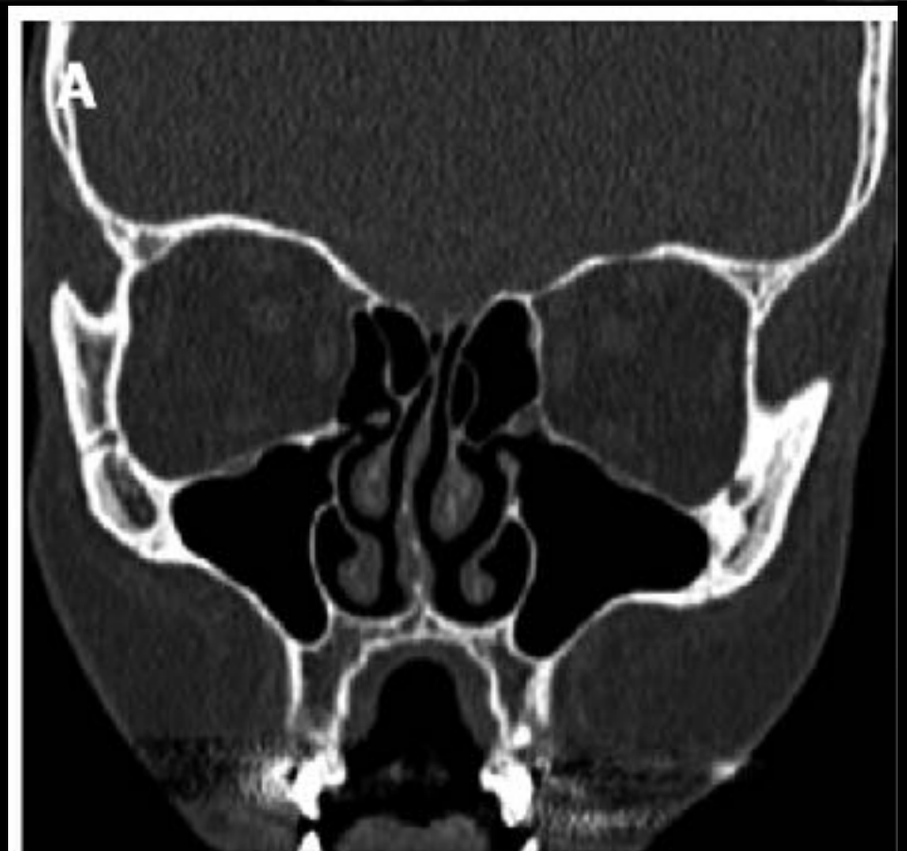
A

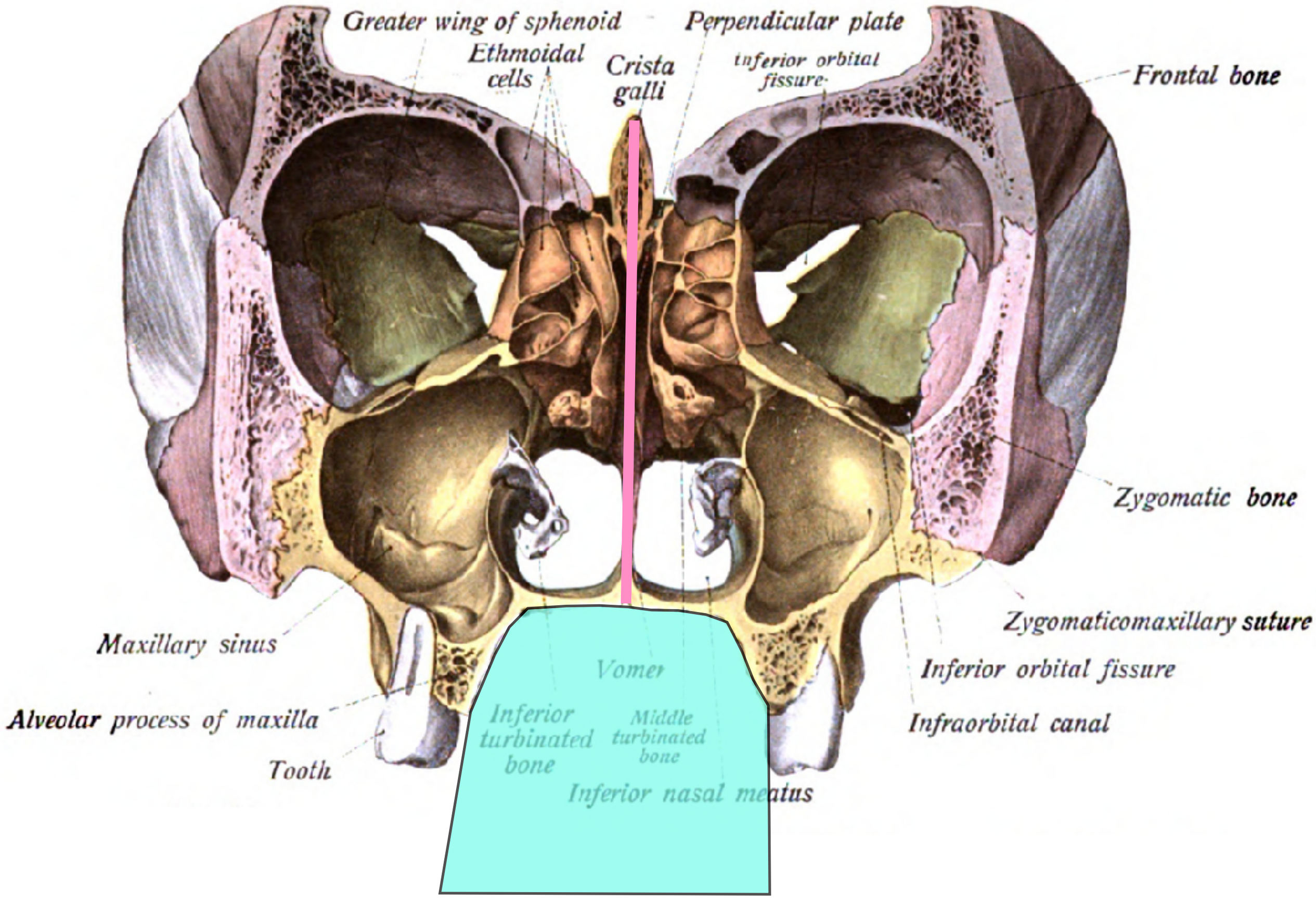
Greater wing of sphenoid
Ethmoidal cells
Crista galli
Perpendicular plate
Inferior orbital fissure
Frontal bone
Zygomatic bone
Zygomaticomaxillary suture
Inferior orbital fissure
Infraorbital canal
Maxillary sinus
Alveolar process of maxilla
Tooth
Vomer
Inferior turbinated bone
Middle turbinated bone
Inferior nasal meatus

Normal

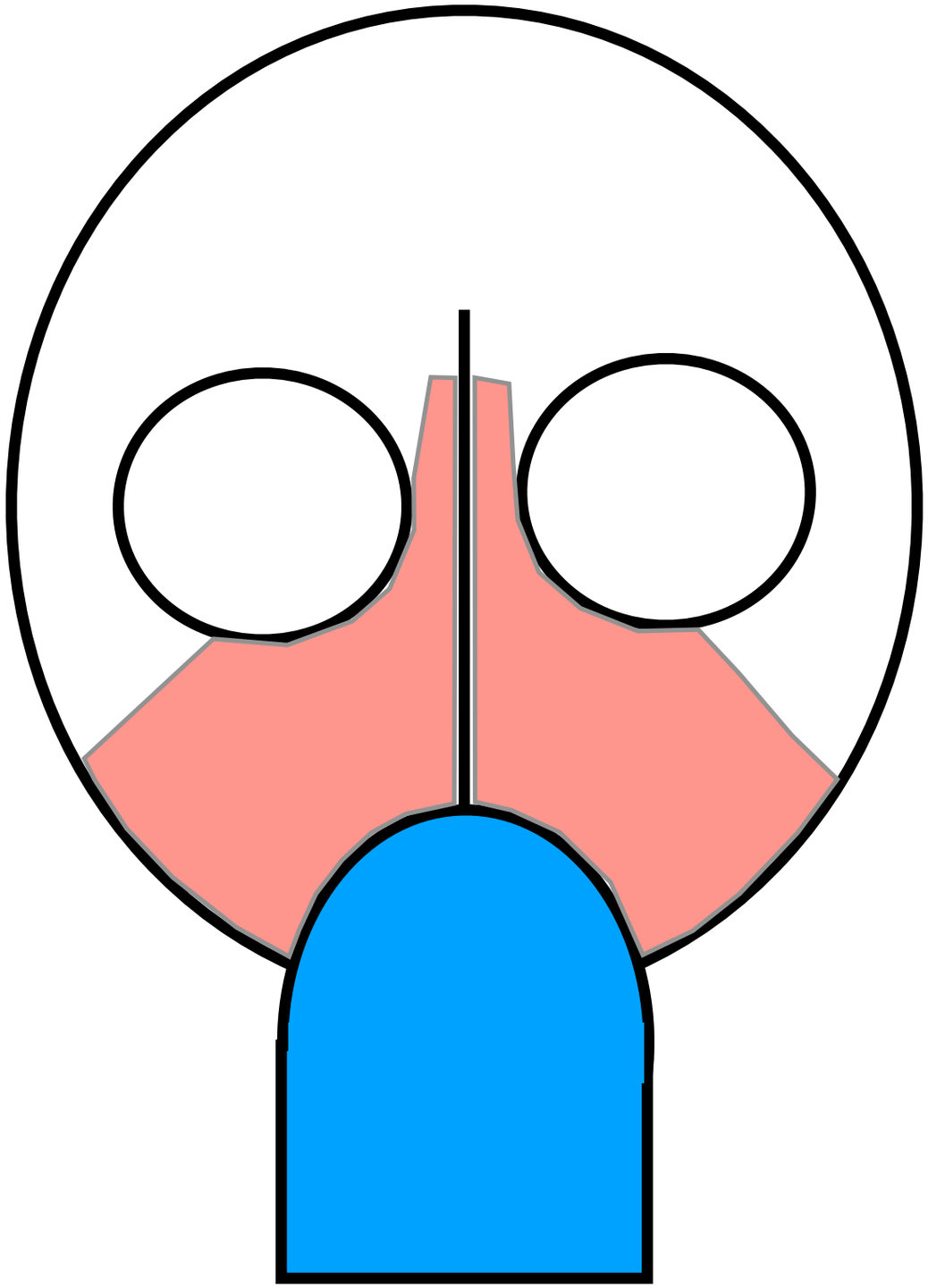

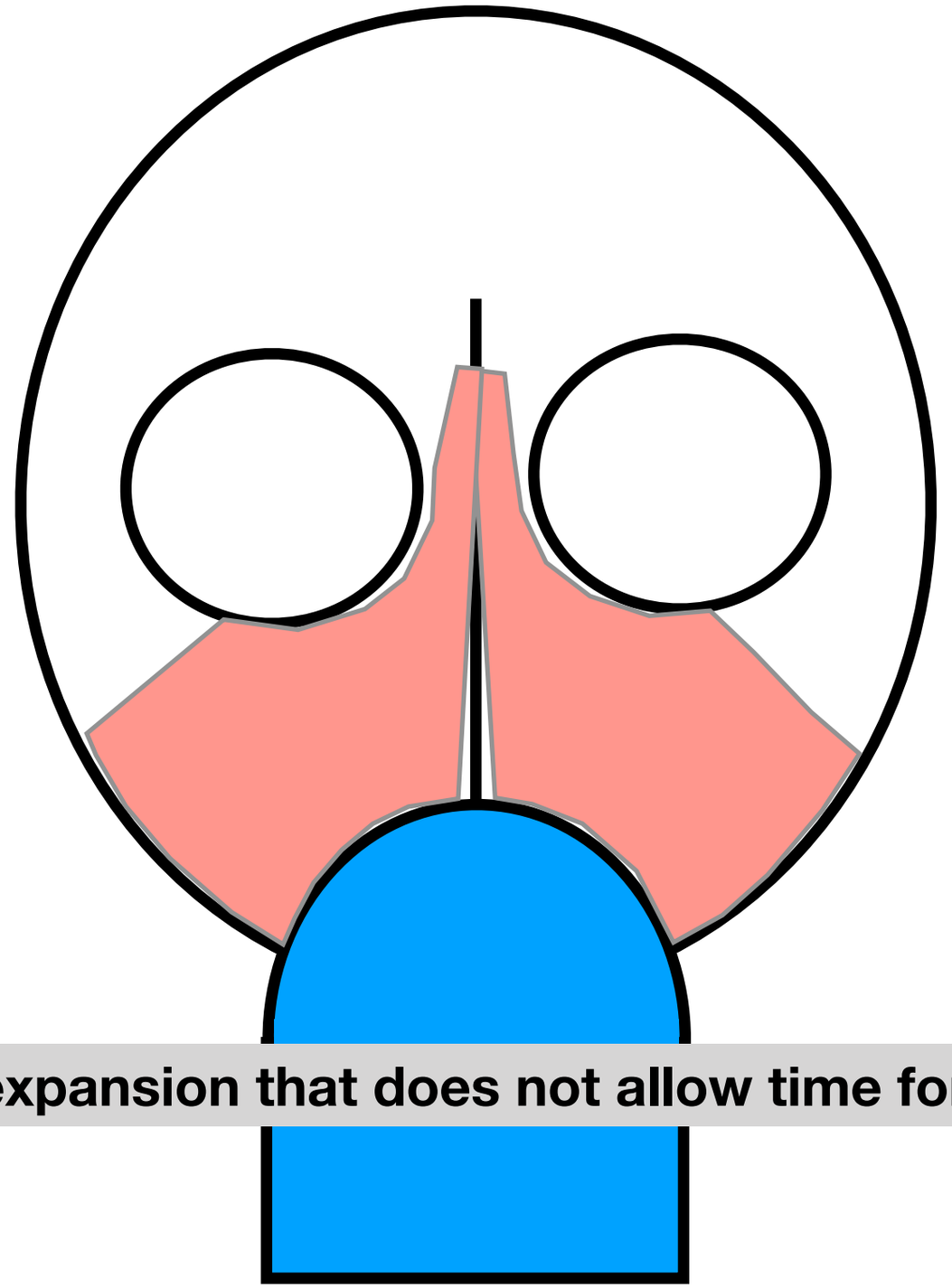

Traditional ortho expansion that does not allow time for bone remodeling

Normal

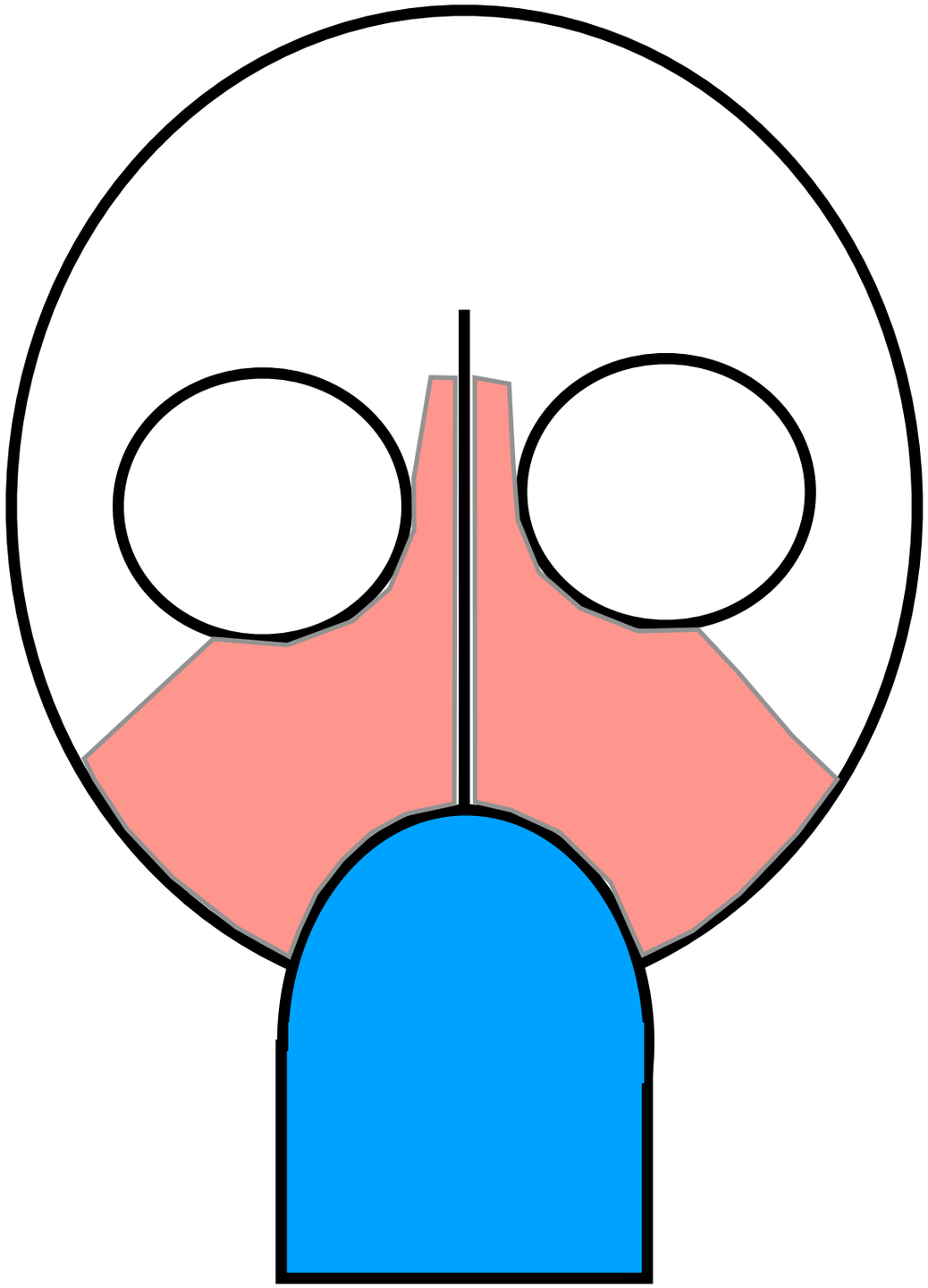

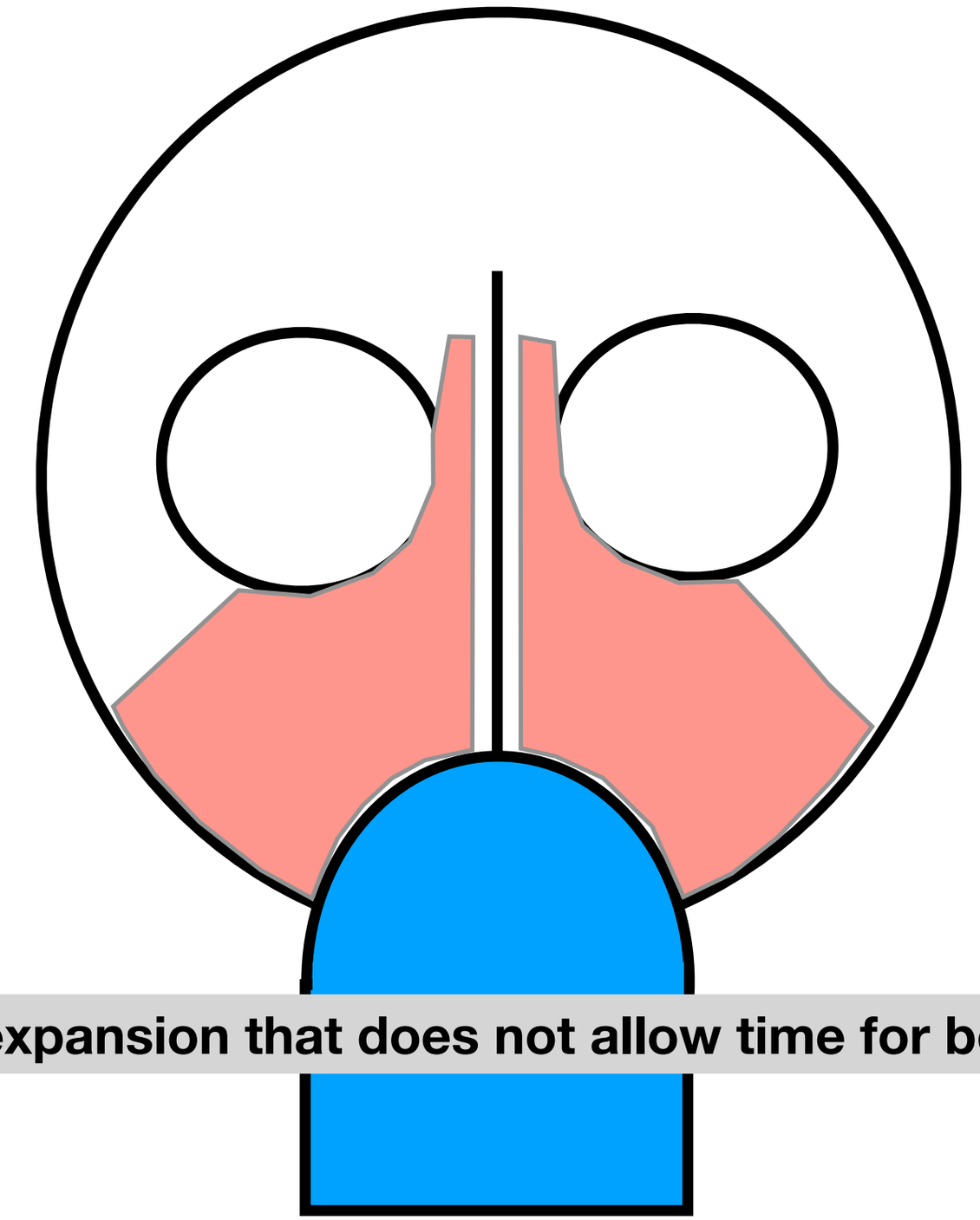

Rapid palatal expansion that does not allow time for bone remodeling

Normal

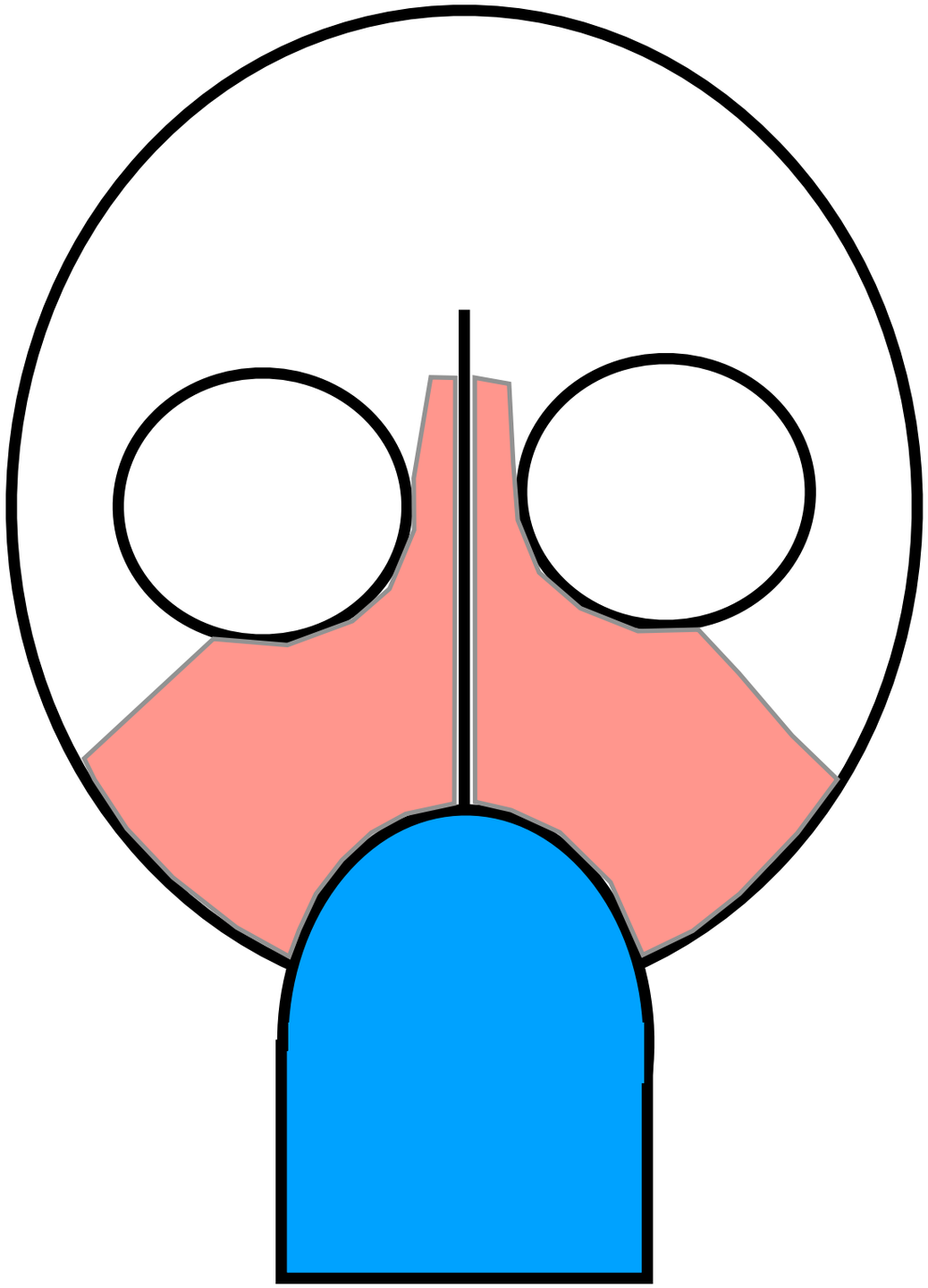

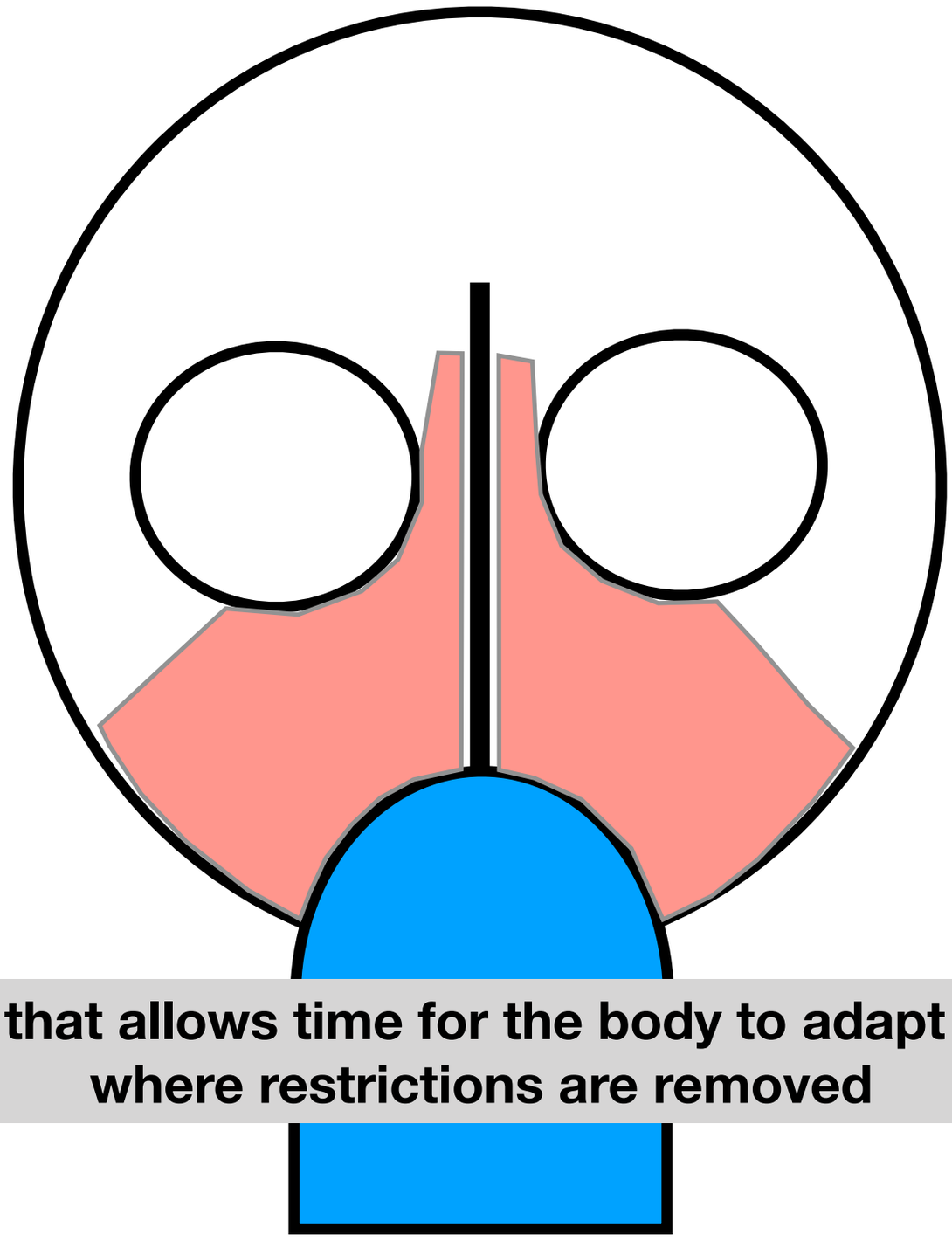

Orthodontia that allows time for the body to adapt and respond where restrictions are removed

Vision Recap

- Glasses have the right of way when it comes to conflicts with teeth or the tongue…
- That allows them to “get in the way” of your oral treatments.
- Moving the teeth can change the shape of the orbit and effect/change vision.

Vision Recap

- Even someone without glasses can have visual somatic strain that affects your treatment.
- But someone with glasses is potentially a bigger issue.
- Moving the eyes anatomically, when the glasses are prescribed for a different anatomical face means we have an optical issue that influences/inhibits the oral structures.

Vision Recap

- The treatment is relatively easy…adjust the glasses and/ or the prescription - and that change needs to be monitored closely and frequently…
  - Once we get the visual strain out of the way, the teeth can move quickly…potentially causing more visual strain (and starting the process over again).

Vision Recap

- Testing is easy if you can feel cranial motion - test the patient with eyes closed and then eyes open…any change with eyes open is visual in origin.

- If you don’t use cranial, you can test the muscles at the base of the skull for a difference in tension with eyes closed verses open.

  - If there is a difference with eyes open here (tighter with eyes open), you have a visual AND a tongue issue (remember that posterior cranial fossa and its connected nerves).

Vision Recap

- If you find a positive finding indicating visual somatic strain for most of us it means a referral to a practitioner qualified to treat vision.

➡ *That may not be every vision professional…you may need to look for a behavioral optometrist or top tier ophthalmologist to get the best results.*

Vision Addendum

Lens Options

- Bifocals
- Progressive Lenses
- LASIK Surgery
- Contacts
- MonoVision
- Polarized

Lens Coatings

Progressive Lenses

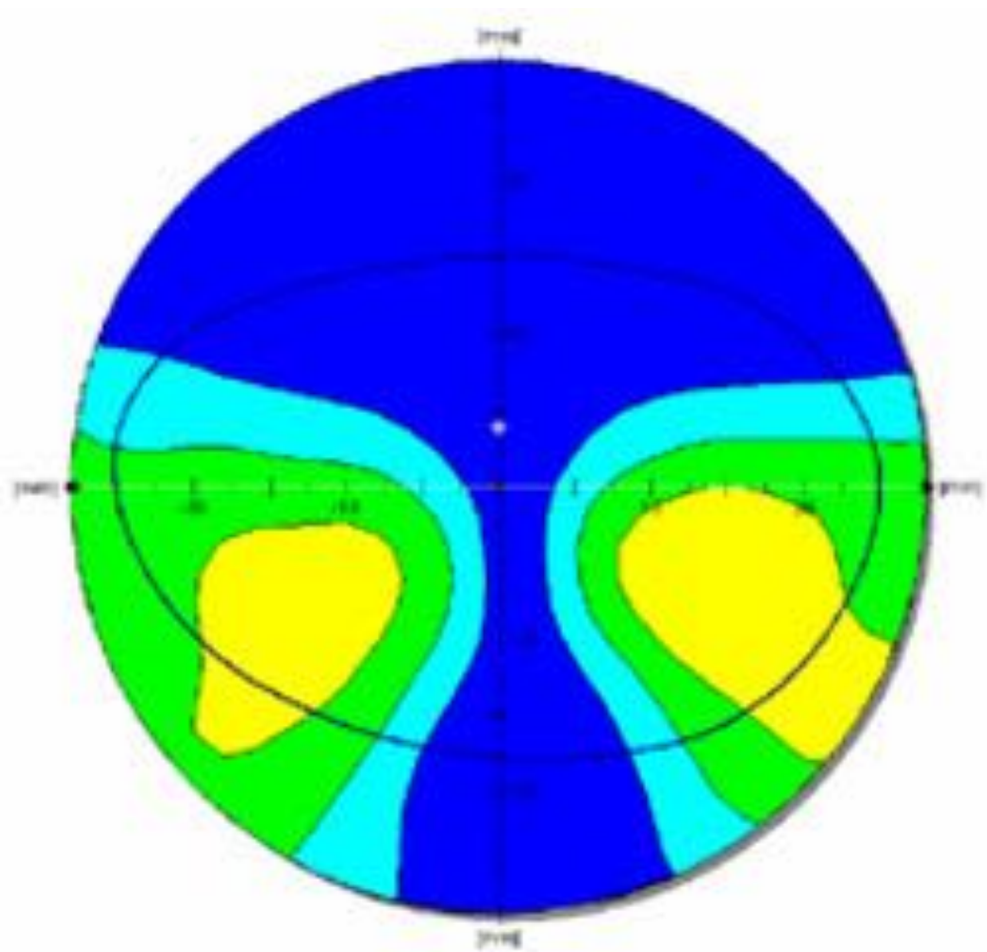

Progressive Multifocal Designs
aka "The No-Line Bifocal"

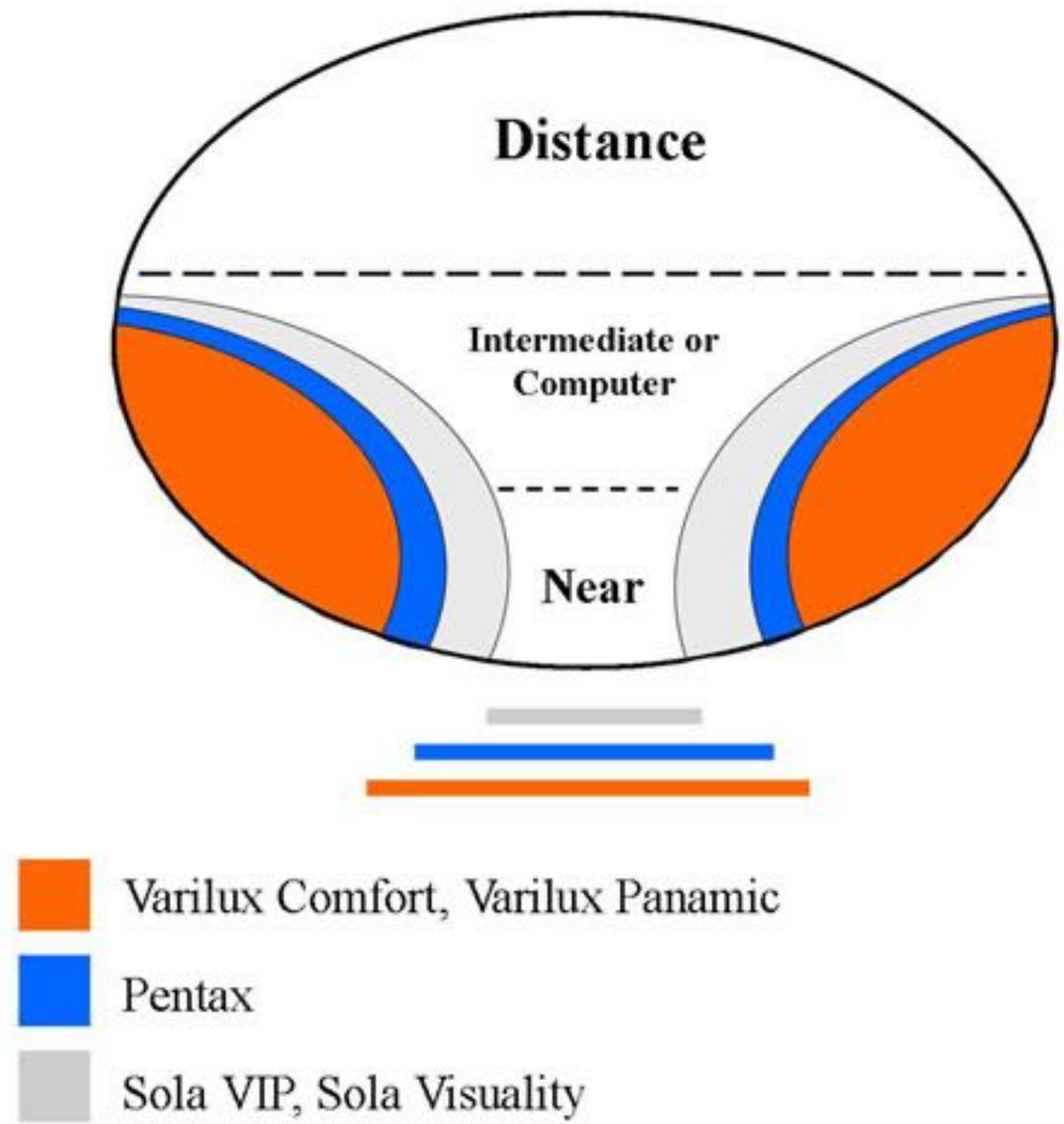

LASIK

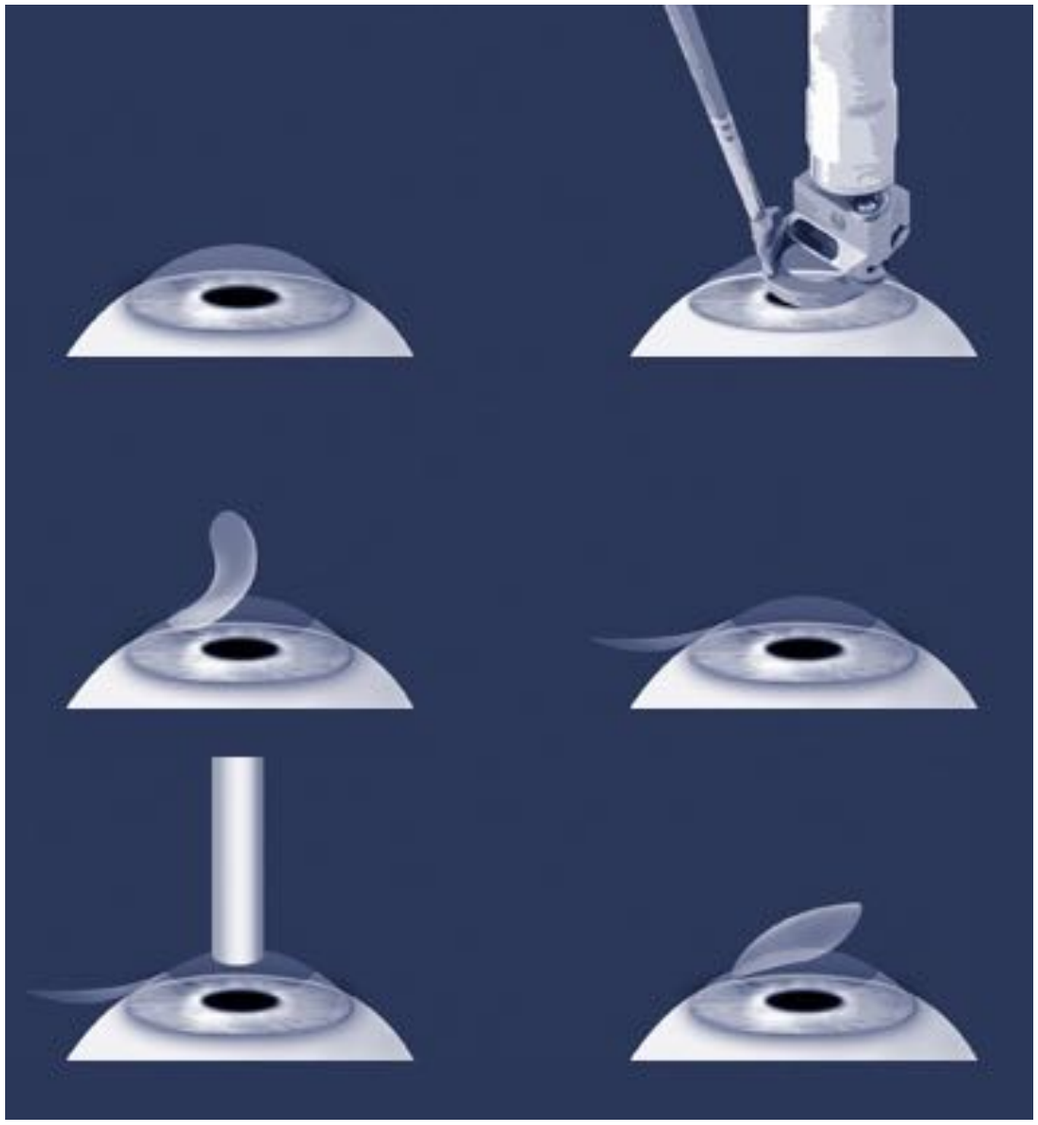



Polarized

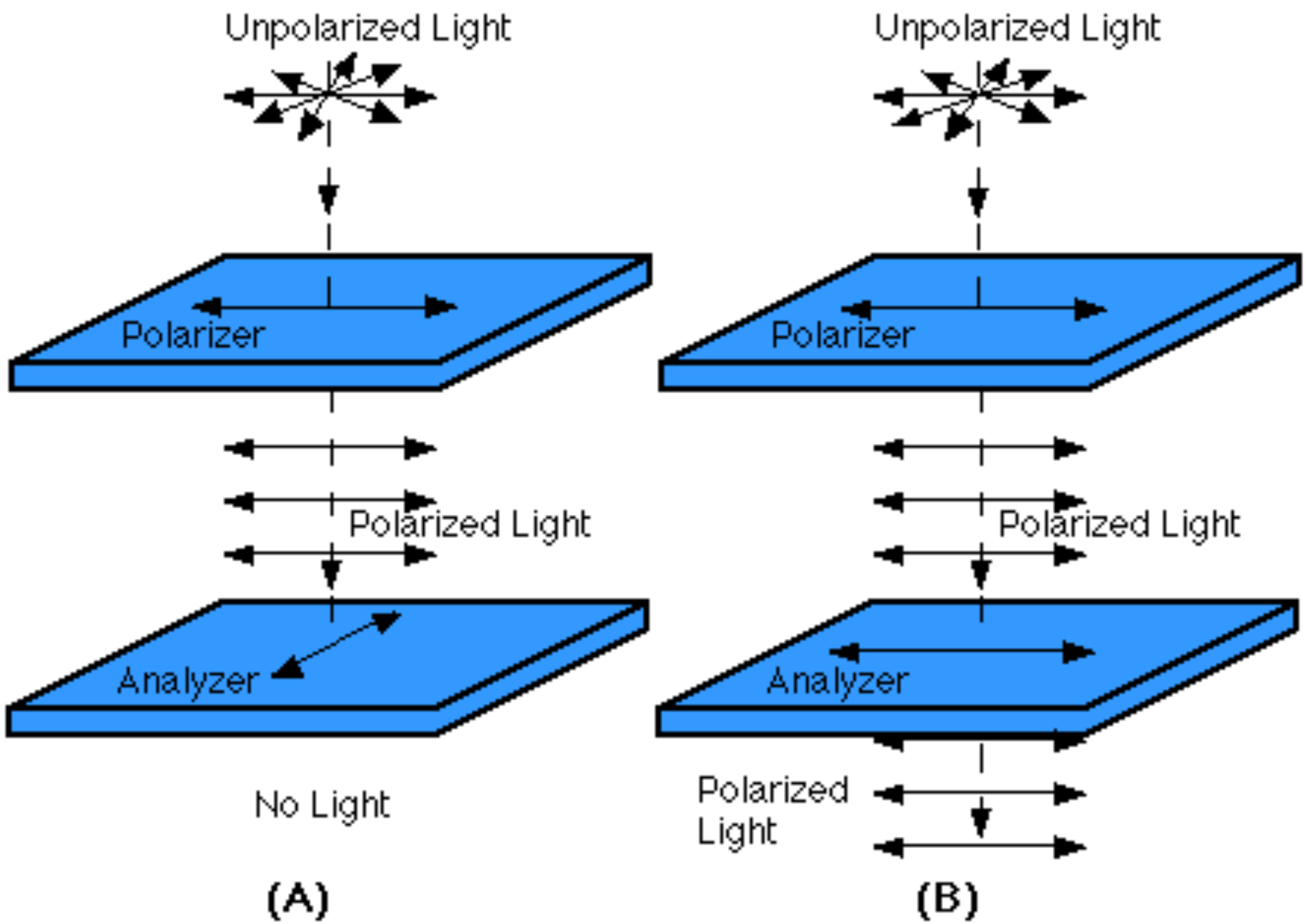
Unpolarized Light
Polarizer
Polarized Light
Analyzer
No Light
(A)
Unpolarized Light
Polarizer
Polarized Light
Analyzer
Polarized
Light
(B)

Whoa, that was a lot of information.


That’s All Folks

Lab